

Clinical Results of Localized Alveolar Ridge Augmentation with Bone Grafts Harvested from Symphysis in Comparison with Ramus

Reza Pourabbas ^{1*} • Saeed Nezafati ²

1. Associate Professor, Department of Periodontics, Faculty of Dentistry, Tabriz University of Medical Sciences, Iran.

2. Assistant Professor, Department of Oral and Maxillofacial Surgery, Faculty of Dentistry, Tabriz University of Medical Sciences, Iran.

* Corresponding author: E-mail: pourabbas@tbzmed.ac.ir

Abstract

Background and aims. Autogenous onlay bone grafting is a common procedure for alveolar ridge augmentation. It has been suggested that the amount of healed bone after this technique would be significantly less than the initial quantity. The aim of this study was to determine the relationship between the various parameters influencing the outcome of ridge augmentation procedures.

Materials and methods. Thirty-two patients, 17 males and 15 females (mean age 40 ± 8.66), requiring lateral ridge augmentation in the anterior maxilla were recruited. Bone grafts obtained from either the mandibular ramus or symphysis were grafted on the recipient site and the buccolingual dimensions of the edentulous ridge before and six months after the procedure were measured and the difference between them was considered as ridge augmentation (RA). Parameters including graft thickness (GT), graft area (GA) and donor site (DS) were also recorded.

Results. Onlay bone grafts, taken from mandibular and symphysis areas, significantly increased the buccolingual dimension of the alveolar ridge (mean 1.98 ± 1.22 mm, $p < 0.001$). However, the mean RA by symphysis grafts was significantly greater than ramus grafts (2.49 mm vs. 1.48 mm). There was also a significant correlation between graft thickness, surface area and the amount of bone augmentation.

Conclusion. Symphysis area provides thicker and larger grafts, which may result in a better clinical outcome in alveolar ridge augmentation.

Key words: Autogenous bone graft, guided bone regeneration, onlay bone graft, ridge augmentation.

Introduction

Insufficient bone width is regarded as a major limitation factor in the placement and/or the esthetic outcome of dental implants. To overcome such difficulties use of autogenous bone block as onlay grafts has been suggested.^{1,2} Mandibular symphysis and ramus areas have been considered two most common donor sites to provide adequate bone for lateral ridge augmentation.³⁻⁵ These areas have various advantages such as intra-oral accessibility and proximity to recipient sites, low morbidity, minimal discomfort, no scar on the skin and maintenance of osseous density.⁶ However, resorption changes which occur in the healing period may affect the final outcome of the procedure and lead to a compromised clinical fate.⁷

From a clinical point of view, the final expected bucco-lingual width of the available bone and its correlations with the influencing parameters would be a subject of interest.

The purpose of this study was to determine the quantitative changes during the remodeling period of buccal onlay block grafts and to describe the relationship between the original size of the grafted bone and its final volume.

Materials and Methods

Patients

Thirty-two patients (17 males and 15 females) who had referred for dental implants in the private practice were included in this study. Mean age was 40 ± 8.66 (ranging from 20 to 62 years of age). All the subjects had a thin crestal ridge on the anterior maxilla and requested to replace one to three missing teeth with dental implants. Individuals who had a history of any relevant systemic diseases, medication or smoking were excluded. The eligible ones were informed of the purpose of the study and surgical procedures. Before the study, they gave their informed written consent to participate. In addition to oral examination, radiographic findings and diagnostic casts were precisely evaluated to determine the extent of ridge defects before the surgical phase of treatment.

Surgical procedures

The subjects were randomly divided into two groups according to the donor site and

operated by one clinician (R.P). Group Ch was assigned to chin and group Ra to ramus. Prophylactic antibiotics were prescribed on the day of surgery and both the donor and recipient surgical sites were anesthetized using an appropriate technique.

A beveled and slightly palatal incision was made at the recipient site to expose the host bone. The bucco-lingual width of residual bone was measured by a pair of crown calipers. To determine the desired size of the graft, the other dimensions of the ridge defects were measured using a periodontal probe. Multiple perforations were made on the cortical bone by a small round bur in order to facilitate the influx of growth factors, platelets and revascularization.^{8,9}

In both of the study groups, the appropriate donor site was exposed surgically and a block bone graft was obtained according to a standard method (as described in Reference 10).

A 1.5-mm hole was prepared through the autograft and all the sharp edges were clipped and smoothed. The grafts were measured in length, width and thickness and then delivered to the recipient site and stabilized in place with mini-screws. No additional bone chips or other bone substitute materials were added to the grafted area.

A type I collagen membrane (Bio-Gide[®], Geistlich Pharma AG, Wolhusen, Switzerland) was applied on the entire graft site in a manner that at least 3 mm of the surrounding native bone was also covered.

In order to have a tension-free flap closure, a periosteal releasing incision was made at the base of the flap.¹¹ Wound closure was carried out by horizontal mattress and interrupted suture techniques using 4-0 chromic catgut suture material (SUPA[®] Medical Devices, Tehran, Iran). At the end of the surgical appointment, the patients were prescribed appropriate medications (including antibiotics, analgesics and antimicrobial oral rinse) and given post-operative instructions.

The sutures were removed after 14 days and monthly follow-up appointments were scheduled. Following a six-month healing period, the grafted sites were re-opened using full thickness flaps and the widths of the alveolar ridge were measured again as described previously. After removal of the bone screws, suitable sized implants (Frialit-2[®] or Xive[®], Dentsply-Friadent GmbH,

Mannheim, Germany) were selected and inserted according to manufacturer's instructions.

Statistical analysis

The difference between the initial and final ridge widths was considered as lateral ridge augmentation (RA). The mean dimensions (including the initial and final ridge widths, RA, length, width, surface area and the thickness of the grafts) were calculated. Data were evaluated for normality by Kolmogorov-Smirnov test and paired sample t-test was used to compare the initial and final ridge widths in each group of the study. In order to compare the RA between the two groups, t-test was used. Additionally, Pearson's correlation test was used to determine any correlation between the initial dimensions of the bone graft and the amount of RA.

Results

All the participants underwent the surgical procedures successfully without any major complications at the recipient or donor sites. Soft tissue healing was uneventful; however, there were some reports of swelling, pain and ecchymosis which subsided within several days after medications were prescribed and/or post-operative instructions were given.

Although there was no significant difference in the initial ridge width, the amount of lateral ridge augmentation in the chin group was significantly greater than the ramus group ($p < 0.05$).

The mean initial and final bucco-lingual widths of the alveolar ridge as well as the mean dimensions of the grafts in each group are shown in Table 1. A significant degree of lateral ridge augmentation was obtained in all the subjects following the bone grafting procedures (mean 1.98 ± 0.21 mm, $p < 0.001$). The clinical appearance of the augmented ridge was firm and resistant to removal by a curette. Figure 1 presents the differences between the initial and final ridge widths in all the groups of the study.

As shown in Table 1, the augmented ridge by symphysis grafts was significantly wider than the ramus grafts ($p < 0.05$) and the symphysis area provided thicker and larger grafts in comparison with the ramus area ($p < 0.01$).

There was also a significant direct correlation between the graft thickness, graft area, and the original ridge width and the amount of ridge augmentation ($r = 0.6$, $r = 0.4$ and $r = 0.38$, respectively). However, we did not find any significant correlation between the age of the patients and the outcome of the procedure. There were no significant differences between male and female patients.

Discussion

Available literature indicates the efficacy and predictability of intra-oral autogenous onlay bone grafts for augmenting the width of the anterior maxilla.^{2,3,12} However, regarding the remodeling events which are involved in the healing process of bone grafts, it has been revealed that the amount of augmented bone following buccal onlay grafts is significantly less than the initial quantity.¹³⁻¹⁵

It has been suggested that various factors might influence the fate of bone grafting procedures. Successful bone grafting requires concurrent revascularization and replacement of the graft.¹⁶ There is substantial evidence that intra-membranous bones (such as mandible) show less resorption and revascularize more rapidly than endochondral bones.¹⁷⁻¹⁹ However, the scientific rationale for this benefit of embryologic origin has never been documented. On the other hand, according to some studies resorption of onlay grafts depends on the relative ratio of cortical to cancellous bone rather than the embryologic origin.^{20,21}

This study confirms that remodeling of bone grafts may affect the fate of lateral ridge augmentation procedures, yet some technical predicting factors may have a role in the outcome of the procedure. According to previous reports, the recipient site (mandible vs. maxilla)¹⁴, smoking and other factors relating to patients' systemic backgrounds may influence the clinical results of augmentation procedures. However, we controlled these confounding variables by defining the inclusion and exclusion criteria in such a manner that ultimately only matched subjects with similar initial ridge widths were included in the study. This enabled us to compare the quantitative changes that depend more on the bone graft than on other parameters affecting the outcome of the procedure.

In the present study there was a statistically significant difference between the initial and final ridge widths in both groups. These findings indicated that either chin or ramus grafts are capable of increasing the width of the alveolar bone. Thus, the results of this study are consistent with the observations made in previous studies indicating the effectiveness of mandibular ramus or chin onlay grafts in lateral ridge augmentation.¹⁴

Whilst the increased failure rate reported for autogenous bone grafts exceeded 12 cm in length and diminished to 17% when the length was < 6 cm²² or < 5cm²³, in the present study a direct correlation was found between the initial size of the bone graft and the amount of ridge augmentation. In our opinion this is the reason why chin grafts were more effective than ramus grafts. However, those lengths of bone grafts are rarely available from intra-oral donor sites and are indicated for more complicated unusual cases. The above-mentioned studies were conducted to evaluate the clinical results of grafting procedures for mandible, which possesses less potential for bone augmentation than maxilla.¹⁵

Within the limits of this study, it can be concluded that in comparison with the ramus, chin area affords more available bone that can be harvested for grafting purposes. The amount of post-operative resorption of larger bone grafts was significantly less than the smaller ones. These findings may be attributed to the fact that larger grafts, compared to smaller grafts, are more resistant to the resorptive phenomenon that is involved in the healing processes of buccal onlay grafts.

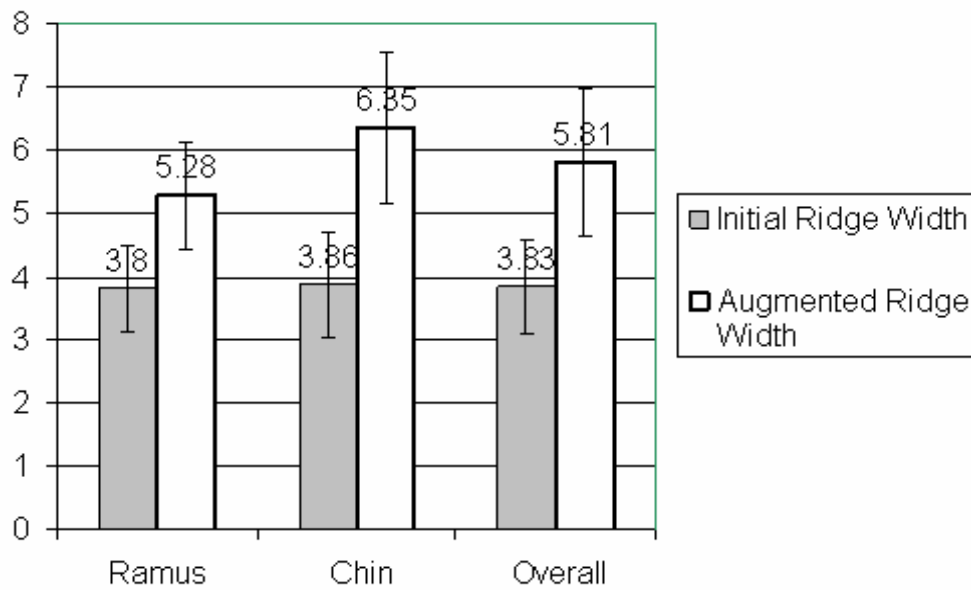


Figure 1. Comparison of the two donor sites and the overall changes in the alveolar width.

Table 1. Characteristics of the study population and the mean values \pm standard deviations of study parameters (mm) by donor sites

| Donor site | N | Gender | Graft thickness | Graft area | Ridge augmentation |
|-----------------|-----|------------|-----------------|-------------------|--------------------|
| Chin | 16 | F=8 M=8 | 4.5 \pm 0.89 | 55.95 \pm 19.47 | 2.49 \pm 1.18 |
| Ramus | 16 | F=7 M=9 | 3.39 \pm 0.56 | 30.36 \pm 13.97 | 1.48 \pm 1.06 |
| p- value | NS* | NS | <0.01 | <0.01 | <0.01 |

*Not significant

References

1. Buser D, Dahlin C, Schenk RK. *Guided Tissue Regeneration in Implant Dentistry*. Chicago: Quintessence; 1994.
2. McCarthy C, Patel RR, Wragg PF, Brook IM. Dental implants and onlay bone grafts in the anterior maxilla: analysis of clinical outcome. *Int J Oral Maxillofac Implants* 2003; 18:238-41.
3. Capelli M. Autogenous bone graft from the mandibular ramus: a technique for bone augmentation. *Int J Periodontics Restorative Dent* 2003; 23:277-85.
4. Zeiter DJ, Reis WL, Sanders JJ. The use of bone block graft from the chin for alveolar ridge augmentation. *Int J Periodontics Restorative Dent* 2000; 20: 619-27.
5. Hunt DR, Jovanovic SA. Autogenous bone harvesting: a chin graft technique for particulate and nonparticulate bone blocks. *Int J Periodontics Restorative Dent* 1997; 19: 165-73.
6. Misch CM, Misch CE, Resnik R, Ismail YH. Reconstruction of maxillary alveolar defects with mandibular symphysis grafts for dental implants: a preliminary procedural report. *Int Oral Maxillofac Implants* 1992; 7: 369-66.
7. Fonseca RJ, Clark PJ, Burkes EJ Jr, Backer RD. Revascularization and healing of onlay particulate autogenous bone grafts in primates. *J Oral Surg* 1980; 38:527-77.
8. Shih MS, Norrdin RW. Regeneration acceleration of remodeling during healing of bone defects in beagle dogs of various ages. *Bone* 1985; 6: 377-79.
9. Glowacki J, Kaban LB, Murray JE, Folkman J, Mulliken JB. Application of the biologic principle of induced osteogenesis for craniofacial defects. *Lancet* 1981; 1(8227):959-62.
10. Simion M. Procedures used to augment the deficient alveolar ridge. In: Lindhe J, Karring T, Lang NP. *Clinical Periodontology and Implant Dentistry*, 4th ed. UK: Blackwell Munksgaard; 2003: 897-914.
11. Tinti C, Banfenati SP, Polizzi G. Vertical ridge augmentation: What is the limit? *Int J Periodontics Restorative Dent* 1996; 16:619-27
12. Van der Meij EH, Blankestijn J, Berns RM, Bun RJ, Jovanovic A, Onland JM, Schoen J. The combined use of two endosteal implants and iliac crest onlay grafts in the severely atrophic mandible by a modified surgical approach. *Int J Oral Maxillofac Surg* 2005; 34:152-7.
13. Maiorana C, Beretta M, Salina S, Santoro F. Reduction of autogenous bone graft resorption by means of Bio-oss coverage: a prospective study *Int J Periodontics Restorative Dent* 2005; 25:19-25.
14. Cordaro L, Amade DS, Cordaro M. Clinical results of alveolar ridge augmentation with mandibular block bone grafts in partially edentulous patients prior to implant placement. *Clin Oral Implants Res* 2002; 13:103-11.
15. D'Addona A, Nowzari H. Intramembranous autogenous osseous transplant of alveolar atrophy. *Periodontol* 2000 2001; 27:148-61.
16. Stevenson S, Davy DT, Klein L, Goldberg VM. Critical biologic determinants of incorporation of non-vascularized cortical bone grafts: Quantification of a complex process and structure. *J Bone Joint Surg Am* 1997; 79:1-16.
17. Zins JE, Witaker LA. Membranous versus endochondral bone: Implication for craniofacial reconstruction. *Plast Reconstr Surg* 1983; 72: 778-85.
18. Linn KY, Barlett SP, Yaremchuk MJ, Grossman RF, Witaker LA. The effect of rigid fixation on the survival of onlay bone grafts: An experimental study. *Plast Reconstr Surg* 1990; 86:449-56.
19. Rabie ABM, Dan Z, Samman N. Ultrastructural identification of intramembranous and endochondral bones. *Int J Oral Maxillofac Surg* 1996; 25:383-86.
20. Buchman SR, Ozaki W. The ultrastructure and resorptive pattern of cancellous onlay bone grafts in the craniofacial skeleton. *Ann Plast Surg* 1999; 43: 49-56.
21. Ozaki W, Buchman SR. Volume maintenance of onlay bone grafts in the craniofacial skeleton: Micro-architecture versus embryologic origin. *Plast Reconstr Surg* 1998; 102:291-99.
22. Pogrel MA, Podlesh S, Anthony JP, Alexander J. A comparison of vascularized and non-vascularized bone grafts for reconstruction of mandibular continuity defects. *J oral Maxillofac Surg* 1997; 55: 1200- 08.
23. Cordeiro PG, Haidalgo DA. Conceptual consideration in mandibular reconstruction. *Clin Plast Surg* 1995; 22:61-9.