



Contents lists available at ScienceDirect

International Journal of Surgery Case Reports

journal homepage: www.casereports.com

Massive intraperitoneal free air induced by pneumothorax and pneumomediastinum

Kei Fujiwara, Hiromichi Ohsaka, Hiroki Nagasawa, Ikuto Takeuchi, Kei Jitsuiki, Akihiko Kondo, Kazuhiko Omori, Kouhei Ishikawa, Youichi Yanagawa*

Department of Acute Critical Care Medicine, Shizuoka Hospital, Juntendo University, Japan

ARTICLE INFO

Article history:

Received 12 April 2018

Received in revised form 21 June 2018

Accepted 22 June 2018

Available online 27 June 2018

Keywords:

Pneumoperitoneum

Nonsurgical

Pneumomediastinum

Pneumomediastinum

ABSTRACT

INTRODUCTION: Pneumoperitoneum (PP), or air within the abdominal cavity, is frequently a harbinger of serious abdominal pathology and often represents visceral perforation. We herein report a case of combined massive intraperitoneal free air, pneumothorax and pneumomediastinum but emergency laparotomy was negative.

PRESENTATION OF CASE: A sixty-seven-year-old man was found unconscious on a road after being hit by a car. On arrival, he showed swelling of the head and flail chest. Computed tomography (CT) demonstrated cerebral contusion, multiple bilateral rib fractures, minute subcutaneous emphysema and a left hemothorax. As his consciousness and respiratory function deteriorated, tracheal intubation with mechanical ventilation with positive end-expiratory pressure was executed on the second day. On the third day, the CT scan revealed the new appearance of pneumomediastinum and massive free air in his intraperitoneal space. Emergency laparotomy was negative.

DISCUSSION: The 'air leak' phenomenon, in which an alveolar air cell ruptures into the perivascular and peribronchial interstitial tissues, is a well-recognized consequence of positive end-expiratory pressure therapy. Accordingly, the deterioration of traumatic pneumothorax and/or the occurrence of pneumomediastinum after mechanical ventilation was the most likely cause of the PP in the present case. However, it remains possible that a minute unrecognized diaphragmatic injury caused the massive PP in the present case.

CONCLUSION: We herein described a case of PP that occurred after mechanical ventilation in a patient with multiple injuries, but which did not originate from perforation of the gastrointestinal tract. It is most likely that the PP had an intrathoracic cause.

© 2018 The Author(s). Published by Elsevier Ltd on behalf of IJS Publishing Group Ltd. This is an open access article under the CC BY-NC-ND license (<http://creativecommons.org/licenses/by-nc-nd/4.0/>).

1. Introduction

Pneumoperitoneum (PP), or air within the abdominal cavity, is frequently a harbinger of serious abdominal pathology and often represents visceral perforation. Most cases of PP ultimately require surgical exploration and intervention. Approximately 85% of patients with a ruptured viscus will present with pneumoperitoneum, most often from a perforated gastric or duodenal ulcer, although patients with perforation of the colon or small bowel, or rupture of the uterus or bladder may also present with pneumoperitoneum [1,2]. While, some cases of nonsurgical PP have also been described in the literature, and it has been suggested that these cases can be managed conservatively [1]. We herein report a case of combined massive intraperitoneal free air, pneumothorax and

pneumomediastinum. This work has been reported in line with the SCARE criteria [3].

2. Case presentation

A sixty-seven-year-old man was found unconscious on the road after being hit by a car, which left the scene of the accident. The patient had hypertension and diabetes mellitus. On arrival, his Glasgow Coma Scale was E3V3M5, and his vital signs were as follows: blood pressure, 94/70 mmHg; a heart rate, 64 beats/min (BPM), and SpO₂, 100% with 10 L/min by oxygen mask. He showed swelling of the head and flail chest at his trunk. Emergency chest roentgenography revealed multiple rib fractures with pneumohemothorax, which was treated by thoracostomy. Subsequently, CT demonstrated skull fracture, cerebral contusion, bilateral multiple rib fractures, minute subcutaneous emphysema and left hemothorax (Fig. 1). A blood analysis revealed no significant abnormalities. At first, the patient was admitted to the intensive care unit for observation. However, his consciousness

* Corresponding author at: 1129 Nagaoka, Izunokuni City, Shizuoka, 410-2295, Japan.

E-mail address: yyanaga@juntendo.ac.jp (Y. Yanagawa).

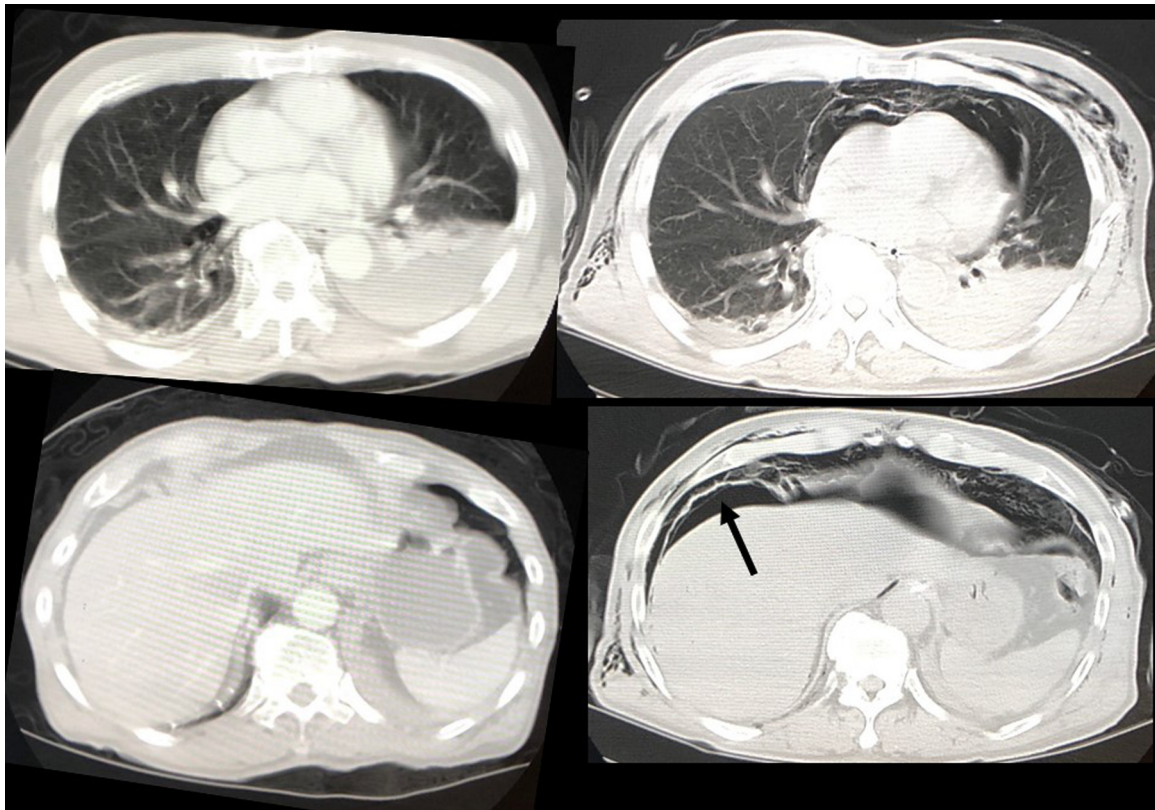


Fig. 1. Truncal CT on arrival (left) and on the 3rd hospital day (right).

The CT scan obtained on arrival does not show free air in the intraperitoneal space. However, pneumomediastinum and pneumoperitoneum (arrow) were observed on the 3rd hospital day.

and respiratory function deteriorated, necessitating tracheal intubation with mechanical ventilation with positive end-expiratory pressure (PEEP) on the second day. On the third day, his subcutaneous emphysema expanded, and a second CT scan was performed. This scan revealed the expansion of subcutaneous emphysema, in addition to the new appearance of pneumomediastinum and massive free air in his intraperitoneal space (Fig. 1). Emergency laparotomy was done which was negative. Post-operative course was no eventful. Finally, he was transferred to other medical facility for rehabilitation after he could breathe on his own without the artificial respiratory.

3. Discussion

Nonsurgical PP has intrathoracic, gynecological, abdominal and idiopathic causes [4,5]. With regard to the gynecological cause, the genital tract in female patients communicates with the peritoneal cavity; this forms the basis upon which tubal patency is laparoscopically assessed in patients being investigated for infertility. Dye insufflated via the external os can be seen emerging from the fimbrial ends of a patent salpinx [4]. This portal therefore provides a route of access to the peritoneal cavity via which air or fluid may enter under various circumstances. However, this mechanism did not explain the PP in the present case because the patient was male.

The common abdominal causes of PP include pneumatosis cystoides intestinalis; PP may also occur after abdominal surgery [4]. Furthermore, intra-abdominal sepsis from gas-forming organisms may produce pneumoperitoneum [4]. The present case had no such complications.

It is most likely that the present case had an intrathoracic cause. Macklin performed basic scientific studies involving the transbronchial placement of a catheter into the lungs of a cat, which

was insufflated with blasts of air at pressures of 25–130 cmH₂O [6]. If the pressure was high and prolonged, then—in addition to subcutaneous emphysema—pneumomediastinum occurred and air was observed around the aorta and in both pleural cavities. Surprisingly, air could also be found in the peritoneal cavity and the retroperitoneum, particularly around the loose perirenal fascia. Post-mortem and microscopic examinations suggested that air had entered into the interstitial tissues through tiny openings in the alveoli and then along the perivascular sheaths of the lung and into the mediastinum. If the pressure is continued, air dissects its way downwards along the esophagus and aorta into the retroperitoneal tissues. Ultimately, rupture of the peritoneum leads to the escape of free gas and the production of pneumoperitoneum. Patients receiving PEEP and continuous positive airway pressure therapy are at risk of spontaneous pneumoperitoneum³; the ‘air leak’ phenomenon, in which an alveolar air cell ruptures into the perivascular and peribronchial interstitial tissues, is a well-recognized consequence of PEEP therapy. Accordingly, the deterioration of traumatic pneumothorax and/or the occurrence of pneumomediastinum after mechanical ventilation was the most likely cause of the PP in the present case. However, it remains possible that a minute unrecognized diaphragmatic injury caused the massive PP in the present case [7].

4. Conclusion

We herein described a case of PP that occurred after mechanical ventilation in a patient with multiple injuries, but which did not originate from perforation of the gastrointestinal tract. It is most likely that the PP had an intrathoracic cause; however, the possibility remains that the PP was caused by an unrecognized minute diaphragmatic injury.

Presentation

None.

Conflict of interest

The authors declare no conflicts of interest in association with the present study.

Funding

This work received funds from Ministry of Education, Culture, Sports, Science and Technology (MEXT)-Supported Program for the Strategic Research Foundation at Private Universities, 2015–2019. Title is [The constitution of total researching system for comprehensive disaster, medical management, corresponding to wide-scale disaster].

Ethical approval

This retrospective case study was approved by the review board of Juntendo Shizuoka Hospital.

Consent

Written informed consent for the publication was obtained from the patient.

Authors contribution

YY is the last authors of this manuscript and the corresponding author. KF, HO, HN, IT, KJ, AK, KO, and KI participated in perioperative management of the patient, and data analysis or interpretation. All authors read and approved the final manuscript.

Registration of research studies

N/A.

Guarantor

Youichi Yanagawa.

References

- [1] M.E. Breen, M. Dorfan, S.B. Chan, Pneumoperitoneum without peritonitis: a case report, *Am. J. Emerg. Med.* 26 (2008) 841–842.
- [2] R.A. Mularski, M.L. Ciccolo, W.D. Rappaport, Nonsurgical causes of Pneumoperitoneum, *WJM* 170 (1999) 41–46.
- [3] R.A. Agha, A.J. Fowler, A. Saetta, I. Barai, S. Rajmohan, D.P. Orgill, for the SCARE Group, The SCARE Statement: consensus-based surgical case report guidelines, *Int. J. Surg.* 34 (2016) 180–186.
- [4] N.M. Williams, D.F. Watkin, Spontaneous pneumoperitoneum and other nonsurgical causes of intraperitoneal free gas, *Postgrad. Med. J.* 73 (1997) 531–537.
- [5] C.B. Gantt, W.W. Daniel, G.A. Hallenbeck, Nonsurgical pneumoperitoneum, *Am. J. Surg.* 134 (1977) 411–414.
- [6] C.C. Macklin, Pneumothorax with massive collapse from experimental overinflation of the lung substance, *Can. Med. Assoc. J.* 36 (1937) 189–195.
- [7] A. Polychronidis, A. Bounovas, B. Didilis, S. Perente, C. Simopoulos, Intraperitoneal air in the diagnosis of blunt diaphragmatic rupture, *J. Cardiovasc. Surg. (Torino)* 42 (2001) 845–847.

Open Access

This article is published Open Access at [sciencedirect.com](https://www.sciencedirect.com). It is distributed under the [IJSCR Supplemental terms and conditions](#), which permits unrestricted non commercial use, distribution, and reproduction in any medium, provided the original authors and source are credited.