

# Continuous Mechanical Chest Compression-assisted Percutaneous Coronary Intervention in a Patient with Cardiac Arrest Complicating Acute Myocardial Infarction

Zhi-Ping Zhang, Xi Su, Cheng-Wei Liu, Dan Song, Jian Peng, Hua Yan

Department of Cardiology, Wuhan Asia Heart Hospital, Wuhan, Hubei 430022, China

**Key words:** Cardiac Arrest; Cardiopulmonary Resuscitation; Myocardial Infarction; Percutaneous Coronary Intervention

Cardiac arrest with ventricular tachycardia or ventricular fibrillation in the catheterization laboratory is not uncommon, but patients who suffered cardiac arrest requiring prolonged cardiopulmonary resuscitation is not infrequent and still a major problem, because it is essentially impossible to perform effective manual chest compressions during percutaneous coronary interventions (PCIs).<sup>[1]</sup> Recently, the use of a novel mechanical chest compression device, Lund University Cardiopulmonary Assist System (LUCAS, Jolife AB, Lund, Sweden), has been shown to sustain both coronary and cerebral circulation despite cardiac arrest and it may be possible to allow for continued PCI despite ongoing cardiac or circulatory arrest with artificially sustained circulation.<sup>[2]</sup> We here report a case who presented with acute myocardial infarction complicated by cardiac arrest undergoing successful PCI while continuous mechanical chest compression with LUCAS device.

A 47-year-old male was admitted to our hospital with a 5 h history of chest pain. His initial vital signs included temperature 36.4°C, heart rate 108 beats/min, blood pressure 74/42 mmHg, respiratory rate 22 breaths/min. The initial electrocardiogram revealed sinus tachycardia with ST-segment elevation in leads V1 through V5. Bedside transthoracic echocardiography showed that hypokinesia of the anterior wall motion and left ventricular ejection fraction was 35%. The blood tests revealed a leukocyte level of  $15.91 \times 10^9/L$  and the serum levels of troponin I of 0.115 ng/ml (normal range 0–0.04 ng/ml). Since the patient was diagnosed as acute ST-segment elevation myocardial infarction complicated by cardiogenic shock, we

decided to emergency PCI. Initial treatment was managed on intravenous dopamine, oral aspirin, clopidogrel, and intravenous unfractionated heparin.

About 20 min after admission, while the patient was transferred from the emergency room to the catheterization laboratory, he had a witnessed cardiac arrest with ventricular fibrillation in the elevator [Figure 1]. Continuous chest compression and electrical defibrillation were performed immediately. The ventricular fibrillation was terminated with defibrillation at first, but in a while he developed repetitive prolonged phases of incessant ventricular tachycardia and ventricular fibrillation. In the catheterization laboratory, repeat defibrillation and intravenous epinephrine, antiarrhythmic drugs such as lidocaine, amiodarone, and magnesium sulfate also could not control the ventricular tachyarrhythmias. His hemodynamic status continued to worsen and required continuous chest compressions and tracheal intubation. Because implantation of extracorporeal membrane oxygenation (ECMO) required surgeons and perfusionists, and they couldn't quickly arrive at the catheterization laboratory, the ECMO could not be performed in the first. LUCAS device was first used for continuous mechanical chest compression to maintain blood pressure about 104/50 mmHg. While continuous automatic mechanical chest compression with the LUCAS device, emergency coronary angiography was performed via the right femoral artery about 42 min after admission (Door to Balloon time), which revealed right coronary artery (RCA) dominance and mild stenosis in the middle portion of the RCA, total occlusion in the proximal left anterior descending artery (LAD), and no stenosis of the left circumflex coronary artery [Figure 2a and 2b]. We performed PCI in the LAD and a stent was deployed to the LAD [Figure 2c and 2d]. An intra-aortic balloon pump (IABP) was inserted via the right

#### Access this article online

Quick Response Code:



Website:  
www.cmj.org

DOI:  
10.4103/0366-6999.152692

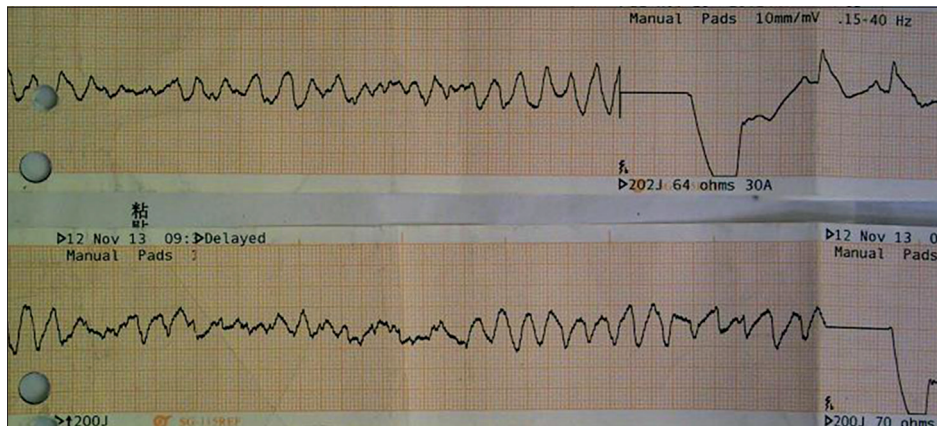
**Address for correspondence:** Prof. Xi Su,  
Department of Cardiology,  
Wuhan Asia Heart Hospital, Wuhan, Hubei 430022, China  
E-Mail: whyxnk@hotmail.com

femoral artery sheath after PCI. The whole procedure took about 13 min. Although the PCI was successful performed, his spontaneous circulation was still not recovered. So, while continuous mechanical chest compression, ECMO was inserted to provide hemodynamic support in a veno-arterial configuration by cannulation on left femoral vessels following cardiac arrest occurred about 75 min [Figure 3]. With the ECMO support for the circulation, the LUCAS device was withdrawn. The patient was transferred to the cardiac care unit to continue to rescue.

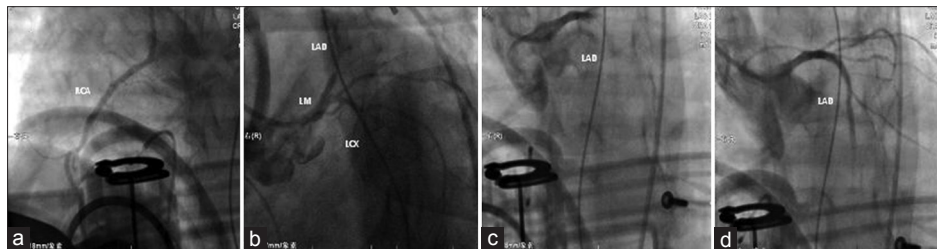
About more than 30 min with the ECMO and IABP support, the patient's rhythm converted to sinus rhythm and his spontaneous circulation was also recovered. His left

ventricular function and hemodynamics obviously improved under the ECMO and IABP assist. The ECMO was removed on the 4<sup>th</sup> day and the IABP weaned off on the 7<sup>th</sup> day after admission. Although the recovery of cardiac function was very well, his consciousness had never recovered. The patient had incurred a serious hypoxic brain injury and later died in the hospital.

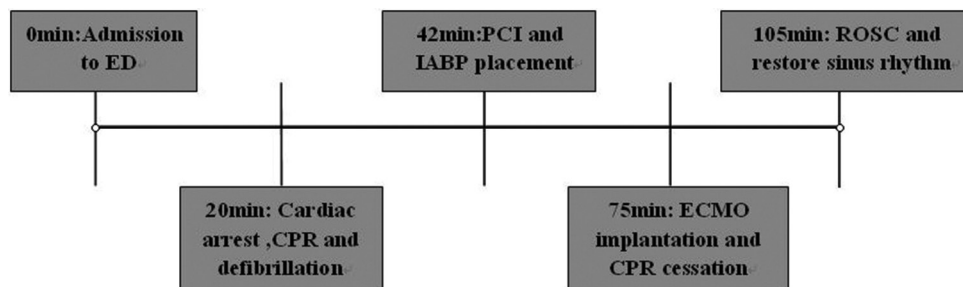
Cardiac arrest in the cardiac catheterization laboratory during PCI, although an uncommon event, is associated with high mortality.<sup>[1]</sup> Immediate chest compression and defibrillation are the most important strategies to improve the outcome in sudden cardiac arrest. However, PCI in the setting of cardiac arrest requiring prolonged resuscitation is a significant



**Figure 1:** This patient suffered sudden cardiac arrest with ventricular fibrillation following arrival in the catheterization laboratory. Electrocardiograph monitoring showed incessant ventricular tachycardia/ventricular fibrillation which could not be controlled by electrical defibrillations and required continuous chest compressions.



**Figure 2:** Emergency coronary angiography and PCI while continuous mechanical chest compression with LUCAS device. (a) Coronary angiography revealed mild stenosis in the middle portion of the RCA; (b) Total occlusion in the proximal LAD, and no significant stenosis of the LCX; (c) PCI was performed in the LAD; (d) and a stent was deployed to the LAD. PCI: Percutaneous coronary intervention; LUCAS: Lund University Cardiopulmonary Assist System; RCA: Right coronary artery; LCX: Left circumflex coronary artery; LAD: Left anterior descending artery.



**Figure 3:** Timeline of events after the patient was admitted to the ED. ED: Emergency department; CPR: Cardiopulmonary resuscitation; PCI: Percutaneous coronary intervention; ECMO: Extracorporeal membrane oxygenation; IABP: Intra-aortic balloon pump; ROSC: Return of spontaneous circulation.

challenge to the interventional cardiologists because it may be difficult to perform efficacious cardiopulmonary resuscitation while continuing the coronary angiography or interventions.<sup>[2]</sup> Mechanical cardiopulmonary resuscitation devices provide chest compressions more reliably at a set rate and depth and thus generate better hemodynamic characteristics than manual chest compressions.<sup>[3]</sup> These devices clearly offer new opportunities for in-hospital cardiac arrest resuscitation as they help to sustain circulation with consistent compressions according to the guidelines during prolonged resuscitation efforts, transportation, and during diagnostics. Mechanical cardiopulmonary resuscitation device, such as the LUCAS has been shown to sustain both coronary and cerebral circulation despite cardiac arrest. The LUCAS device due to its design, which is mostly plastic, not fully radiopaque, and from acceptable size, assures a reliable continuous chest compression during angiography/angioplasty, without significant interferences.<sup>[4]</sup> Utility of the LUCAS device for continuous mechanical chest compressions during PCI has been confirmed to be feasible, safe and highly effective.<sup>[3]</sup> In recent years, ECMO can provide oxygenation and circulatory support and may be the other mean to solve restoration of blood flow in the setting of refractory cardiac arrest in the catheterization laboratory. Several small studies using ECMO in acute coronary syndrome complicated by intractable cardiac arrest have been reported with good results.<sup>[5]</sup>

Compared with continuous mechanical chest compression-assisted PCI, ECMO seems to provide more effective circulatory support than continuous mechanical chest compressions with LUCAS device in cardiac arrest, but implantation of the ECMO usually takes longer and often requires extra staff with special skills, such as a cardiovascular surgeon and a perfusionist. In addition, it may delay revascularization of the occluded infarct-related artery. LUCAS, on the other hand, may be applied quickly (<1 min).<sup>[1]</sup> In the crisis situations, such as in our case, when the refractory cardiac arrest with ventricular tachyarrhythmias could not be controlled by defibrillation and antiarrhythmic drugs, emergency PCI while continuous mechanical chest compressions may be as the preferred option at that time.

Although the patient was treated by successful PCI during continuous mechanical chest compressions and the heart fully recovered under the ECMO and IABP support, serious hypoxic brain injury had caused a poor outcome. There are several potential limitations in our case. First, as the patient

was admitted with acute myocardial infarction complicated by cardiogenic shock, IABP should be immediately inserted in the emergency department. Second, guidelines are somewhat cautious in recommending intravenous  $\beta$ -blockers use in acute myocardial infarction, but in the setting of the electrical storm, whether intravenous  $\beta$ -blockers should be used? Third, therapeutic hypothermia had not be performed as soon as possible in the catheterization laboratory. Finally, also the most important, the ECMO should be immediately used to provide effective circulation perfusion and then to perform PCI under the ECMO support. However, in our institution, implantation of the ECMO usually requires surgeons and perfusionists and could not be performed immediately at that time.

In conclusion, in the setting of acute myocardial infarction complicated by cardiac arrest requiring prolonged resuscitation, it is a significant challenge for the interventional cardiologists to perform PCI. This case, although the finally outcome was poor, illustrates the use of LUCAS device for mechanical chest compressions had made it possible to the continued uninterrupted PCI procedure during ongoing cardiac arrest, especially under the condition of ECMO could not be applied immediately.

## REFERENCES

1. Wagner H, Terkelsen CJ, Friberg H, Harnek J, Kern K, Lassen JF, *et al.* Cardiac arrest in the catheterisation laboratory: A 5-year experience of using mechanical chest compressions to facilitate PCI during prolonged resuscitation efforts. *Resuscitation* 2010;81:383-7.
2. Azadi N, Niemann JT, Thomas JL. Coronary imaging and intervention during cardiovascular collapse: Use of the LUCAS mechanical CPR device in the cardiac catheterization laboratory. *J Invasive Cardiol* 2012;24:79-83.
3. Timerman S, Cardoso LF, Ramires JA, Halperin H. Improved hemodynamic performance with a novel chest compression device during treatment of in-hospital cardiac arrest. *Resuscitation* 2004;61:273-80.
4. Agostoni P, Cornelis K, Vermeersch P. Successful percutaneous treatment of an intraprocedural left main stent thrombosis with the support of an automatic mechanical chest compression device. *Int J Cardiol* 2008;124:e19-21.
5. Lazzeri C, Sori A, Bernardo P, Picariello C, Gensini GF, Valente S. In-hospital refractory cardiac arrest treated with extracorporeal membrane oxygenation: A tertiary single center experience. *Acute Card Care* 2013;15:47-51.

**Received:** 08-12-2014 **Edited by:** Yi Cui

**How to cite this article:** Zhang ZP, Su X, Liu CW, Song D, Peng J, Yan H. Continuous Mechanical Chest Compression-assisted Percutaneous Coronary Intervention in a Patient with Cardiac Arrest Complicating Acute Myocardial Infarction. *Chin Med J* 2015;128:846-8.

**Source of Support:** Nil. **Conflict of Interest:** None declared.