



ELSEVIER

Contents lists available at [ScienceDirect](https://www.sciencedirect.com)

Trauma Case Reports

journal homepage: www.elsevier.com/locate/tcr

Case Report

Successful management of impaled ice-pick stab injury of the suprarenal aorta - lessons learnt

Sivaraman Kumarasamy, Satish Subbiah Nagaraj^{*}, Manish Kumar, Ajay Savlania, Lileswar Kaman

Department of General Surgery, Postgraduate Institute of Medical Education and Research, Chandigarh 160012, India

ARTICLE INFO

Keywords:

Penetrating injury
Aorta
Surgery
Resuscitation
Vascular surgery

ABSTRACT

Penetrating injury of the aorta is rare and lethal. The reported mortality rate is very high. Few patients survive and present to the hospital. Some of these injuries are salvageable if treated in a timely and aggressive manner.

Here we present a case of penetrating injury of the aorta with impalement of the ice-pick, which was successfully managed with laparotomy and primary repair of the aortic injury after adequate resuscitation.

Introduction

Penetrating injury of the abdominal aorta is rare and lethal. Very few survive and present to the hospital. The reported mortality rate is 50–70% [1,2]. Presentation depends on whether the aortic injury has resulted in tamponade (retroperitoneal hematoma) or free rupture into the peritoneal cavity [2–4]. Patient may remain stable on presentation in case of retroperitoneal haematoma due to tamponade effect. In case of free rupture, patients present with hypovolemic shock due to exsanguinating haemorrhage not responding to fluid resuscitation and finally leading to death [2–5]. Some of these injuries are salvageable if treated in a timely and aggressive manner [5–7].

Here, we present a case of through and through impalement of the supra celiac aorta with an ice-pick, which was managed successfully after adequate resuscitation and accurate evaluation of the extent and nature of the injury.

Case report

A 35-year-old male presented to the trauma emergency with a stab injury to the abdomen with an ice pick during a physical assault 6 h back. On admission the patient was conscious, oriented with a blood pressure of 90/60 mmHg, pulse rate of 130/min and respiratory rate of 30/min. The ice pick was in-situ in the abdomen at the epigastric region just to the left of midline and it was pulsating (Fig. 1). On examination, abdomen was distended and diffuse tenderness was present. There were no signs of peritonitis. His Haemoglobin was 6.4 g/dl. One large bore intravenous cannula -16G was secured and a central line was inserted in to the right subclavian vein. Patient was resuscitated initially with 1.5 l of crystalloids followed by 2 units of packed red blood cells, Fresh frozen Plasma and Platelets along with anti-fibrinolytic agent tranexamic acid injection. Oxygen along with analgesics were given by mask and Injection morphine was given for anxiety and pain. No attempt was made to remove the ice pick and it was left in-situ. Major vascular and

^{*} Corresponding author.

E-mail address: drnsatish06@gmail.com (S.S. Nagaraj).

<https://doi.org/10.1016/j.tcr.2022.100663>

Accepted 21 May 2022

Available online 24 May 2022

2352-6440/© 2022 Published by Elsevier Ltd.

This is an open access article under the CC BY-NC-ND license

(<http://creativecommons.org/licenses/by-nc-nd/4.0/>).

visceral injuries were suspected. As the patient got stabilised, Contrast Enhanced Computer Tomography (CECT) and Computed Tomography angiography (CTA) of abdomen was done to delineate the exact site and nature of the injury for surgical planning. CTA showed through and through impaled suprarenal aorta by the tip of the ice-pick (Fig. 2A & B). Adequate blood was arranged and patient was taken up for emergency laparotomy.

Under general anaesthesia and in supine position midline laparotomy was performed just medial to the ice-pick without disturbing it. There was around 400 ml of blood in the peritoneal cavity, which was drained. Significant retroperitoneal haematoma was present in supracolic zone I. The ice-pick was traversing the peritoneal cavity below and to the right of Gastroesophageal junction in the lesser sac and was impaled in to the retroperitoneum. It missed the stomach and the pancreas. Left sided medial visceral rotation (Mattox manoeuvre) was used to expose the retroperitoneum and the suprarenal aorta. After evacuation of the haematoma, supra celiac control was obtained. Ice pick was removed after obtaining the distal aortic control at the supra renal area (Fig. 3A and B) and (Fig. 4). Through and through penetrating injury was present involving both anterior and posterior wall of the suprarenal aorta. Both the defects in the aorta were primarily repaired using polypropylene 4-0 sutures exteriorly. Aortic cross clamping time was 8 min. There was no other associated visceral or solid organ injury. Patient was transfused with 4 units of packed red blood cell (PRBC) and proportionate crystalloids intraoperatively. The patient was shifted to post-operative recovery high dependency unit area. Post-operative recovery was uneventful. He was discharged on 6th postoperative day in stable conditions. He is doing well in 6 months follow-up.

Discussion

Isolated penetrating abdominal aortic injury is very rare and lethal [1–4]. Few cases have been reported about impaled thoracic aortic injuries [5,6]. Most of these injuries do not reach hospital. Because of the nature of the injury, most of these patients succumb to exsanguinating bleeding in the prehospital period.

Penetrating injury accounts for 17% of all abdominal vascular injuries [1,7]. Out of all vascular injuries due to penetrating injury, associated aortic injury has a mortality of 50–70% [1,7,8]. Presence of shock and acidosis on admission, lack of retroperitoneal tamponade and suprarenal aortic injuries were associated with increased mortality [7–9]. The incidence, management and outcome of isolated penetrating injury to the abdominal aorta is not well reported.

In case of isolated abdominal aortic injury with impalement, resuscitative measures should continue side by side with emergency diagnostics procedures. All non-resuscitable and unstable patients should be straight way shifted to the operation theatre for immediate interventions. But if patient is resuscitated and stable, CECT and CTA should be done to assess the complexity and the exact extent of the vascular and visceral injury [5]. This will help in the planning of the surgery and act as a road map. So there is a place for deliberate and planned approach in a selective group of stable patients with penetrating injury of the aorta.

Penetrating injuries to suprarenal aorta are associated with multiple visceral and vascular injuries, difficulties in exposure and vascular control may impose difficulties to the operating surgeon [7,8]. The penetrating weapon and the contained retroperitoneal hematoma pose a tamponade effect thereby preventing exsanguinating haemorrhage. The weapon is to be left in-situ until proximal and distal control of the aorta is obtained to avoid further exsanguination. Those patients with severe shock and difficulties in attaining vascular control can undergo left anterolateral thoracotomy and descending thoracic aorta clamp to reduce intra-abdominal bleed and provides time to correct acidosis and repair of the aortic injury [7–9].

The Mattox manoeuvre is used for exposure of the suprarenal aorta [9]. Left-sided medial mobilization and rotation of the spleen, pancreas, stomach and kidney behind the perinephric fascia exposes the suprarenal aorta in the posterolateral direction [9]. In order to

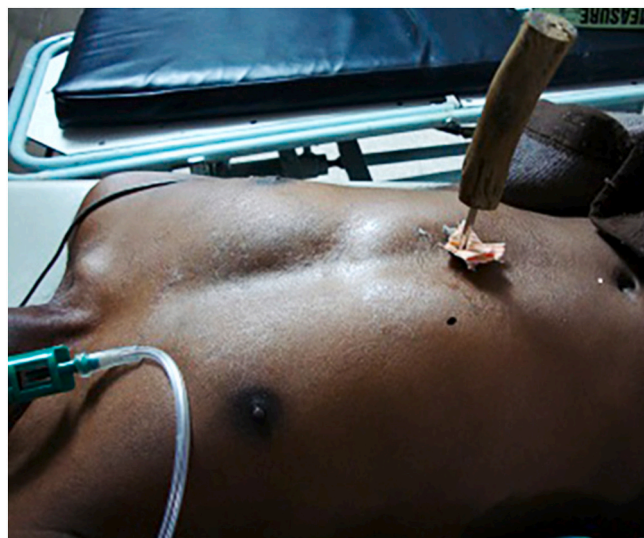

Fig. 1. Stab injury to abdomen with Ice pick in situ.

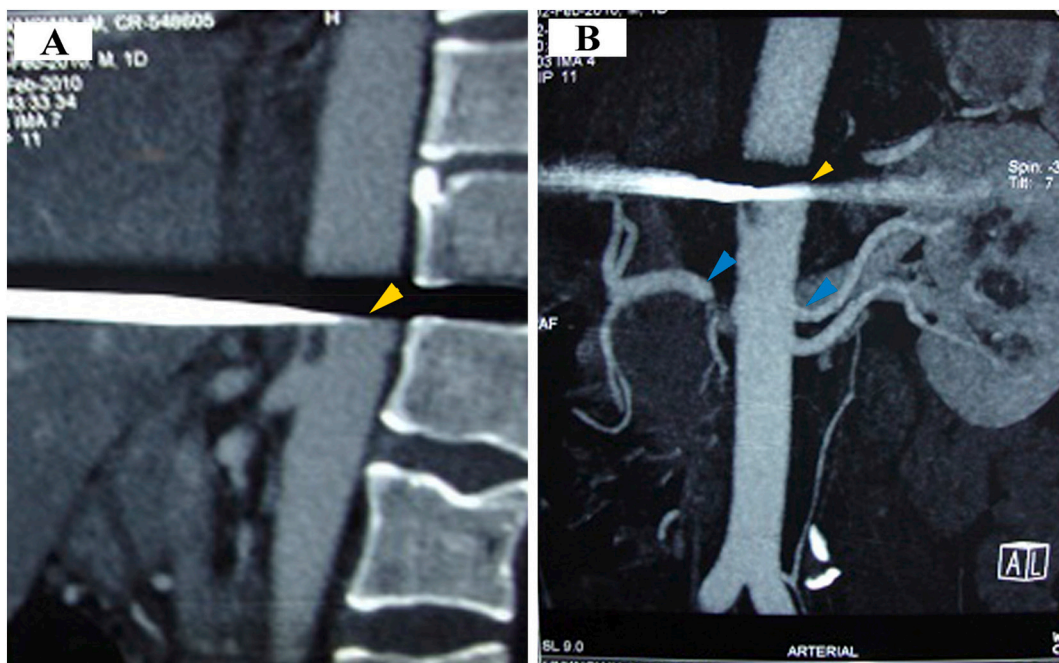


Fig. 2. CT Angiography of abdomen.

Sagittal plane (A) and coronal plane (B) showing impaled supra-renal aorta with ice pick (yellow arrow head) and left and right renal arteries (blue arrow head). (For interpretation of the references to colour in this figure legend, the reader is referred to the web version of this article.)

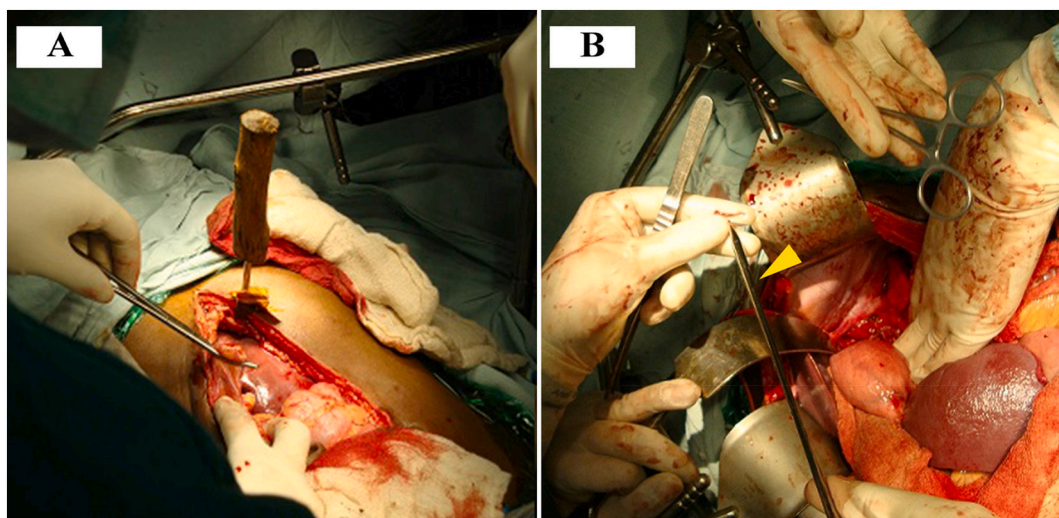


Fig. 3. Intraoperative picture showing laparotomy incision given along the stab wound (A) and ice pick removed (yellow arrow head) after attaining vascular control (B). (For interpretation of the references to colour in this figure legend, the reader is referred to the web version of this article.)

fully expose and visualise the proximal abdominal aorta and to gain vascular control proximal to the celiac artery, division of the left crus of diaphragm might be required. After isolating the injury in aorta, both anterior and posterior walls need to be evaluated for through and through injuries and should be repaired. Another approach to access the supra celiac aorta would be a suprahepatic control which requires less visceral surgery and brings down directly on the subdiaphragmatic aorta. However, Mattox manoeuvre was performed as it provides more access to the posterior aspect of aorta which was needed for repair of posterior wall.

Supra-renal aortic injuries are mostly amenable to primary aortorrhaphy [7–9]. They are repaired with polypropylene 3-0 or 4-0 suture. If defect is large or primary repair results in narrowing of the lumen, patch angioplasty using Dacron or polytetrafluoroethylene (PTFE) can be considered [7–9]. Use of intraoperative anticoagulation during anastomosis to prevent clot embolization

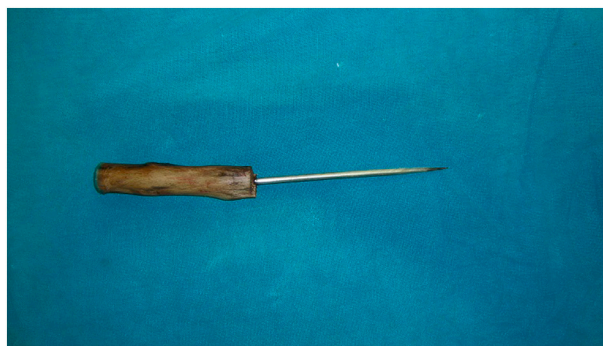

Fig. 4. Removed ice pick.

should be individualised.

In the hospital settings, patients with major abdominal vascular injuries including aortic injury have two mortality peaks. The first peak, occurs in the operating room due to uncontrolled bleeding and the second peak occurs in the post-operative period with increased susceptibility to life threatening complications like systemic inflammatory response syndrome and multiple organ dysfunction syndrome due to prolonged shock, massive blood transfusions, hypothermia, coagulopathy, acidosis, associated injuries, major surgeries and sepsis [7,8].

The lessons we learnt from this index case are many. Impaled ice-pick stab injury of the abdominal aorta is a very rare and dramatic presentation with associated potential mortality. But not every patient should be taken to the operation theatre immediately for a blind laparotomy. Resuscitation is very important including central line access, adequate and appropriate intravenous fluids and blood, pain and anxiety management and stabilization of the patient. If the patient becomes stable, further imaging diagnostics including CECT and CTA should be done for accurate delineation of the nature and extent of vascular and visceral injury for surgical planning. Once the diagnosis is made immediate surgery and repair should be done with all the planning and precautions. The offending object should be removed in the operation theatre under controlled situation. Unstable and non-resuscitable patients will require immediate exploratory laparotomy and needful.

Conclusion

Impaled penetrating abdominal aortic injury is a challenge to surgeons. Aggressive resuscitation with intravenous fluids and transfusion of blood components and utilisation of CECT imaging for early and accurate diagnosis and definitive operative procedure is mandatory to ensure successful simple recovery.

Funding

No grant from any funding agency in the public, commercial, or not for profit sector.

Consent for publication

Informed consent for publication was obtained from the patient.

Author contributions

SK: Drafting the article and final approval of the version published.

SSN: Conception and design, drafting the article, revising critically for important intellectual content, and final approval of the version to be published.

MK: Data acquisition and final approval of the version published.

AS: Drafting the article and final approval of the version published.

LK: Conception and design, drafting the article, revising critically for important intellectual content, and final approval of the version to be published.

Article guarantor

Satish Subbiah Nagaraj MS, MRCS.

Declaration of competing interest

All the authors declare no conflict of interests, both financial and personal.

Acknowledgements

Nil.

References

- [1] J.A. Asensio, W. Forno, G. Roldán, P. Petrone, E. Rojo, A. Tillou, et al., Abdominal vascular injuries: injuries to the aorta, *Surg. Clin. North Am.* 81 (6) (2001) 1395–1416.
- [2] S.S. Bilchod, N.M. Dakhani, D. Arkalgud, Y.P. Lamani, Near-transection of abdominal aorta due to stab injury: a case report, *Int. J. Surg.* 7 (12) (2020) 4212–4216.
- [3] S.C. Chicos, A. Benzenea, R.G. Chebac, Abdominal aorta section caused by abdominal stab wound: discussion of two cases, *Chirurgia (Bucur)* 102 (2) (2007) 237–240.
- [4] M. Kasperczak, Ferenc S. Gnus, Abdominal stab wound with damage to the abdominal aorta and the left lobe of the liver-case report, *Signa Vitae* 14 (1) (2018) 86–87.
- [5] G. Fradet, B. Nelems, N.L. Muller, Penetrating injury of the torso with impalement of the thoracic aorta: preoperative value of the computed tomographic scan, *Ann. Thorac. Surg.* 45 (6) (1988) 680–681.
- [6] F. Eder, F. Meyer, C. Huth, Z. Halloul, H. Lippert, Penetrating abdomino-thoracic injuries: report of four impressive, spectacular and representative cases as well as their challenging surgical management, *Pol. Przegl. Chir.* 83 (3) (2011) 117–122.
- [7] J.A. Asensio, S. Chahwan, D. Hanpeter, D. Demetriades, W. Forno, E. Gambaro, et al., Operative management and outcome of 302 abdominal vascular injuries, *Am. J. Surg.* 180 (6) (2000) 528–534.
- [8] J. Deree, E. Shenvi, D. Fortlage, P. Stout, B. Potenza, D.B. Hoyt, et al., Patient factors and operating room resuscitation predict mortality in traumatic abdominal aortic injury: a 20-year analysis, *J. Vasc. Surg.* 45 (3) (2007) 493–497.
- [9] K.D. Accola, D.V. Feliciano, K.L. Mattox, C.G. Bitondo, J.M. Burch, A.C. Beall Jr., et al., Management of injuries to the suprarenal aorta, *Am. J. Surg.* 154 (6) (1987) 613–618.