

Pathologies of the larynx and trachea in childhood

Abstract

Pathologies in the larynx and trachea in the pediatric age can be characterized in 4 main groups: airway stenosis, acute infections, benign neoplasia and foreign body aspiration. In this review main diagnostic strategies and therapeutic options are presented.

Laryngomalazia is the most frequent condition of supraglottic stenosis. The term supraglottoplasty summarizes all different techniques used for its repair using an endoscopic approach.

Glottic stenosis is rare in children. Usually a compromise between voice preservation and airway restoration has to be sought. Type of reconstruction and timing are varying considerably in individual cases, endoscopic approaches should be preferred.

Subglottic stenosis remains the largest group in paediatric airway pathology, with cicatricial stenosis being predominant. Today, cricotracheal resection is the most successful treatment option, followed by the classical laryngotracheal reconstruction with autologous cartilage. In early infancy subglottic stenosis is particularly demanding. Endoscopic treatment is possible in selected patients, but open reconstruction is superior in more severe cases.

Tracheostomy is not a safe airway in early infancy, its indication should be strict.

Foreign body aspiration needs to be managed according to a clear algorithm.

Recurrent respiratory papillomatosis should be treated with emphasis on function preservation. The role of adjuvant medication remains unclear.

Infectious diseases can be managed conservatively by a pediatrician in the majority of cases.

Keywords: pediatric subglottic stenosis, cricotracheal resection, laryngotracheal reconstruction, pediatric airway stenosis

Christian Sittel¹

1. Klinikum Stuttgart, Klinik für Hals-, Nasen-, Ohrenkrankheiten, Plastische Operationen, Stuttgart, Germany

Laryngotracheal stenosis

Diagnostics

Laryngotracheal stenoses in infants become immediately clinically apparent through the respiratory sounds that are already present at rest or appear in distress. The inspiratory stridor is the leading symptom for all laryngotracheal stenoses. Certainly not all respiratory sounds allow you to define neither the type, nor the location of the stenosis. Nor do they give a correlation to the degree of the stenosis. Oftentimes it is the patient history that leads to the most possible etiology. Most of the acquired stenoses of the upper airway had been caused iatrogenically. The improvements of perinatal intensive care have lead to significantly higher survival rates of extremely premature children. In most of these cases this leads to intubation and long-term intensive care medicine. Even though the relative risk of an intubation-associated stenosis is certainly low today, we continue to deal with a considerably higher number of surviving premature children after long-term intubation through intensive care

medicine. This means that the total number of airway stenosis probably is not declining.

Endoscopy can never be overrated for differential diagnosis of the laryngotracheal stenosis. Only through the endoscopy is it possible to detect the exact location, the degree and the topographic relation of the stenosis to anatomic landmarks.

However, the activity and the consistence of the stenosis as well as the mobility of the arytenoid cartilage and the condition of the surrounding tissue are extremely important parameters.

Rigid telescopes give the most reliable information even though the usage demands an extremely supervised condition of the sedated child with or without spontaneous breathing. This technique requires a certain effort because the presence of an anaesthesiologist is needed, which allows and improves the security in the event of unexpected incidents.

In contrast flexible fibre-optic endoscopy often provides only little informative value. The worse quality of the picture, the changing points of view and the shorter available time for examination do not allow for a detailed analysis.

A sufficient diagnostic of the subglottic area is not possible because of the threat for a laryngospasm when passing the glottis, and this must be avoided.

As a golden rule flexible endoscopy should not be utilized the younger the child is and the stronger the stridor is. However, flexible endoscopy is the most reliable diagnostic method for judging the movement of the vocal cords in patients that are awake.

This standardised and highly qualitative endoscopy represents the basis for any further decision in the therapy. The video documentation should be claimed standard for further comparison with subsequent examinations and for interdisciplinary analysis.

Therapy of laryngomalacia

The instability of the entrance of the larynx is the most common cause for a stridor in newborns, which is referred to as laryngomalacia [18]. Since the respiratory sounds usually tend to decline spontaneously during the first year of life, this is probably based on the immaturity of the larynx of the newborn. In 10% of the affected children the immaturity of the larynx can be so distinct that the normal development of the child is compromised. The expectance of a spontaneous healing leads to a diagnostic and therapeutic restraint that has to be questioned critically in individual cases.

Laryngomalacia functionally results from the underdevelopment of the juvenile larynx which leads to an instability of the epiglottis and a relative hypertrophy of the mucosa of the arytenoid cartilage.

This unstable epiglottis and the hypertrophic mucosa of the arytenoids can be sucked into the glottis through the inspiratory airflow. A short aryepiglottic fold can reinforce this process. In a neonatal larynx with very tight anatomic proportions this can fairly quickly lead to an obstruction. Since this obstruction is located above the superior thoracic aperture, it leads to an obligatory inspiratory stridor.

Even though it is commonly accepted, the term laryngomalacia is inaccurate because it does not describe a specific pathophysiology but rather certain clinical diagnostic findings. To talk about an insufficiency of the supraglottis would be more fitting.

Transnasal flexible pharyngolaryngo(tracheo)scopy generally allows a very good assessment of functional deficiencies because of the sustained spontaneous breathing. Furthermore the deglutition can be assessed in the same examination. The benefits of this method are little effort, the direct availability, and no need for sedation. However, it is often a stressful procedure for the child, the parent and also for the examiner.

Moreover, in a situation where the stenosis is just about compensated or it is an unexpected high-grade stenosis it can quickly turn into an emergency. Therefore, experienced staff and age-appropriate tools for intubation and mechanical ventilation must be absolutely kept.

Other disadvantages are a defensive posture and traumatising of the child, a significantly poorer image

quality in comparison to rigid endoscopy and the lack of a possible immediate therapeutic intervention.

Endoscopy in sedation should always be started with preserved spontaneous breathing. For documentation and a reanalysis of the exam, video recording is highly valuable. For this, high-resolution digital recordings are much easier to interpret because of the small dimensions of the study area. The utilisation of classical ventilation-tracheoscopes is not very useful.

Endoscopy is the only way to determine the location of the obstruction with sufficient certainty. Suppression of mucosal sensitivity through an anesthetic spray is helpful. After such a pretreatment you can easily position the intubation-laryngoscope to see the endolarynx and thus make a video documentation of the supraglottis with a "single" 4.0-mm rod lens endoscope.

Diagnostic endoscopy of the laryngomalacia has to answer 3 questions:

- Does only the collapse of the supraglottis cause the stridor?
- Which anatomic structures of the supraglottis are exactly causing the obstruction?
- Is supraglottoplasty indicated?

The examiner should always assess the upper airway thoroughly as laryngomalacia is associated with other pathologies; for example, congenital subglottic stenosis or vocal cord paralysis in about 10–20% of the cases. Some of these findings may be relevant in planning the therapeutic concept [17], [23], [41], [52].

The endoscopic findings indicate the operative strategy (Figure 1, Figure 2, Figure 3). In practice the examiner will be confronted with a variety of findings that may complicate the exact planning of the operative endoscopic surgery.

This experience prompted Holinger et al. to make a systematization of endoscopic findings in the 1980s [19]. Olney made a more simplified but clinically and practically oriented version in 1999, which we prefer in our daily routine [33] (Table 1).

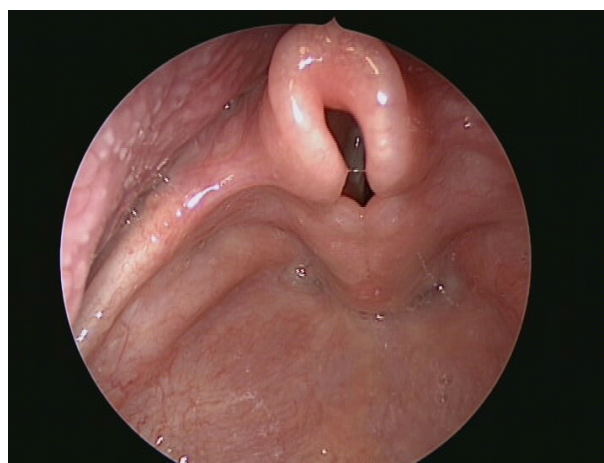


Figure 1: Laryngeal inlet stenosis through shortening of aryepiglottic folds and mucosal hyperplasia of the arytenoids

Table 1: Classification scheme for laryngomalacia according to Olney

Olney Type 1	Mucosal prolapse of the arytenoid region/hypertrophy of the accessory laryngeal cartilages
Olney Type 2	Shortening of the aryepiglottic folds
Olney Type 3	Dorsal displacement of the entire epiglottis
	These three types may present in combination. Each type can be treated with a specific subtype of supraglottoplasty which can also be combined.

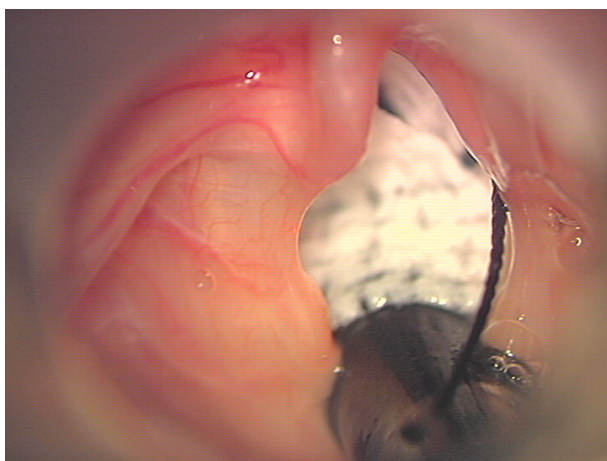


Figure 2: Laser surgical transection of the membranous widened aryepiglottic folds. Exposure with a Benjamin/Lindholm laryngoscope.

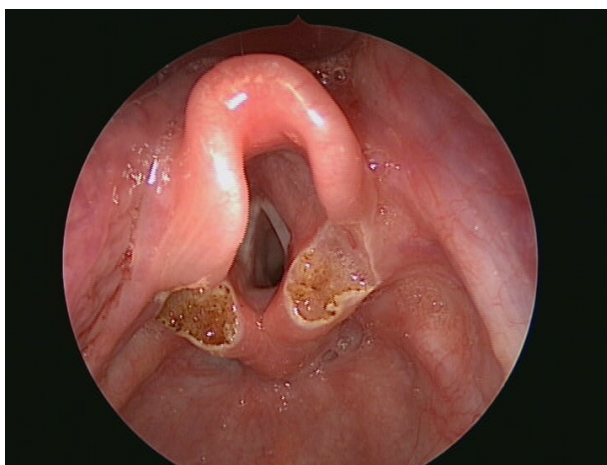


Figure 3: Same situs as in Fig. 1 after laser surgical intervention

The decision for surgical intervention is made according to the overall clinical impression. The following criteria should be applied: stridor with dyspnea at rest, respiration-related nutritional problems, failure to thrive, obstructive sleep disorder hypoxia on distress, hypercapnia on distress, cyanosis [22].

An indication for surgery exists if at least one of the symptoms above are present together with the appropriate endoscopic findings. Regardless of the criteria above, the fear of parents, because of a loud breath sound of their child, should also be taken into account in the indication, even if there is no urgent medical indication.

The procedure of choice is the supraglottoplasty. Three major surgical components can be distinguished, which can be modularly combined: cutting of the aryepiglottic

folds, mucosal reduction of the arytenoids and “trimming” of the epiglottis/epiglottopexy.

In most cases, the tendency of the epiglottis to prolapse into the glottis can be reduced by cutting the membrane-like widened aryepiglottic folds exploiting the natural elasticity of the epiglottis. A reduction of the mucosa in the region of the cuneiform or corniculate cartilage or of the accessory cartilage itself, can be performed under strict protection of the posterior commissure according to the endoscopic findings. Only in rare cases is it necessary to “trim” the epiglottis itself by reduction of mucosa at its free edges.

Epiglottopexy is a special feature, which is rarely necessary. The epiglottis is attached by a suture at the base of the tongue [50]. Since the mobility of the epiglottis during swallowing is thereby significantly reduced, dysphagia has to be expected at least temporarily.

This surgery is performed under general anesthesia and microlaryngoscopically, thus the greatest precision can be reached during the resection of the affected areas. The placement of the laryngeal input succeeds best with the help of a Lindholm laryngoscope, since it allows the simultaneous exposure of the entire area including the epiglottis. Due to the positioning of the tube in the posterior commissure a clamping of the aryepiglottic folds can be managed, which eases to cut them through. We perform the surgery with CO₂ laser in superpulse mode with an intensity of 1 W. This accomplishes bloodlessness while avoiding tissue damage caused by carbonisation. Due to the controlled conditions there is no need for a special laser tube, which is not commercially available in the required small dimensions anyway. The tube is covered for protection from damage by the laser beam with moist gauze.

Alternatively, this intervention can almost equally be performed with cold micro instruments or with a long oscillating microdebrider (“shaver”) [53].

In 90% of the cases a significant improvement or complete regression of obstruction can be expected after supraglottoplasty [6], [47]. However, the prognosis of the procedure deteriorates significantly in relation to the comorbidity. In particular, manifest preoperative aspiration is a high risk factor. But also concomitant diseases like neurological diseases, heart defects and additional effective obstructive malformations may impair the otherwise excellent results.

Classical isolated laryngomalacia is a disease of the infant, but it can also be observed in young children and in exceptional cases in adolescents and adults. In these age groups, laryngomalacia is often associated with

neurological disorders of coordination or a decreased muscle tone as a prognostically unfavorable concomitant disease [6], [10].

Supraglottoplasty is a well reproducible procedure of little difficulty, as long as the very important optimum exposure of the entire supraglottic larynx is guaranteed. Complications primarily result from a too aggressive approach or too imprecise procedure [6], [17], [37]. Postoperative swelling can be avoided with a prophylactic administration of corticosteroids. Extubation is possible immediately after the procedure. Dysphagia or aspiration occurs if at all, only mild and short term, unless there are corresponding comorbidities.

The most serious, but also rarest, complication is the formation of a supraglottic stenosis [6]. The best prevention of such unfavorable scarring lies in a restrained mucosal reduction and strict avoidance of traumatization of the posterior commissure.

Therapy of glottic stenoses

Glottic stenoses can be either congenital or acquired. This very heterogeneous subgroup differs significantly in its characteristics.

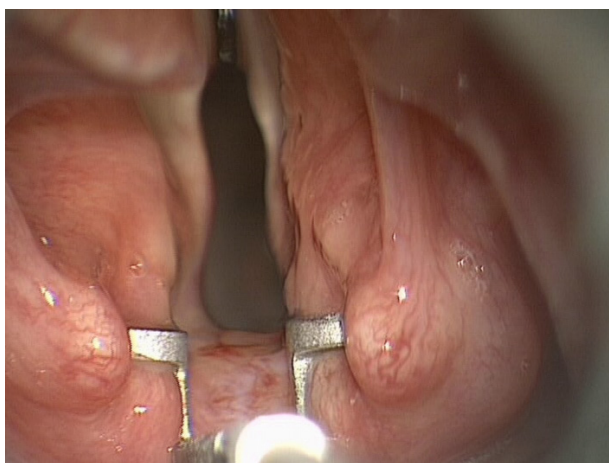


Figure 4: Interarytenoid fibrosis, exposure with a vocal fold spreader in microlaryngoscopy

Interarytenoid fibrosis is a typical, but very little known complication after intubation [3]. By scarring of the posterior commissure a mechanical fixation and/or ankylosis of the arytenoids results (Figure 4). The discrimination from neurogenic vocal fold arrest is clinically difficult. The examination of the passive mobility of the arytenoids in microlaryngoscopy represents the diagnostic gold standard. Operative therapy has to meet a compromise between voice and breathing just like in all glottic stenoses. Although tracheotomy largely avoids this dilemma, it is usually perceived as unacceptable, so that a certain vocal deterioration is approved for avoiding tracheotomy. Numerous individual factors are decisive for the choice of the surgical procedure, usually a subtotal arytenoidectomy is at least required. If this is not enough, an extension of the cricoid plate in terms of a posterior laryngo-tracheal reconstruction has to be performed. Only in

carefully selected cases of mild interarytenoid fibrosis it may be sufficient to only separate the scar tissue with the laser, which then has to be combined with a transient matching laterofixation (Figure 5) [25].

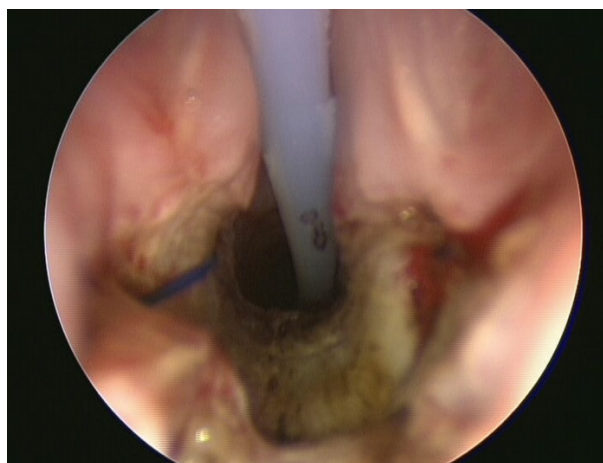


Figure 5: Bilateral temporary laterofixation after laser surgical separation of an interarytenoid fibrosis

The **congenital bilateral vocal fold arrest** is of neurogenic origin. Even for the experienced examiner the evaluation of the vocal fold mobility can be very difficult in the newborn and represents one of the few clear indications for flexible endoscopy in the conscious child. Electromyography is not very useful at this age. The spontaneous onset of motility is described and could be observed several times on our patients [1]. Therefore, ablative enlargements of the glottis should only be considered after 12 month of life. Up to this point a tracheostomy must be performed depending on the clinical symptoms, although this is associated with a significant morbidity and mortality especially in this age group.

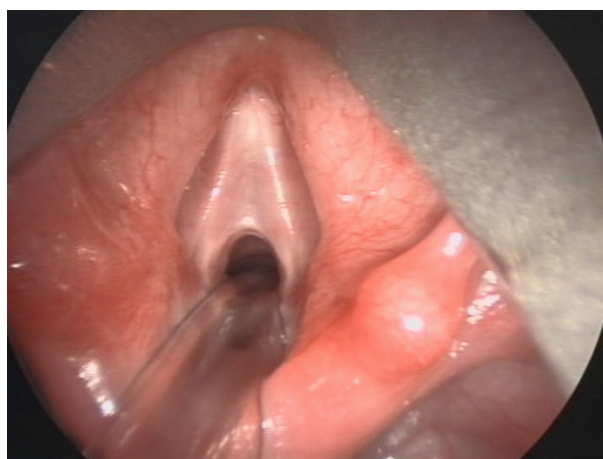


Figure 6: Glottic web in a 4-year-old male

The **congenital web** (Figure 6), in contrast, is easier to diagnose, but to a lesser extent it is often overlooked in flexible endoscopy. Although it usually appears as a delicate and short membrane, it is often a complex malformation varying in degree and always reaching the cricoid cartilage antero-caudally. The sole transection or even puncturing is not sufficient and therefore contraindicated.

The treatment of choice is the endoscopic separation of the synechia with the insertion of a temporary placeholder (Figure 7, Figure 8). A tracheotomy, even if temporary, should be avoided. This procedure is possible with a weight of about 10 kg [32], [48].

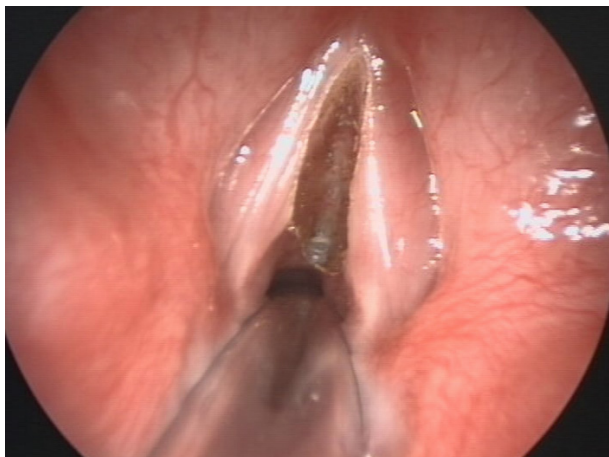


Figure 7: Lasersurgical separation

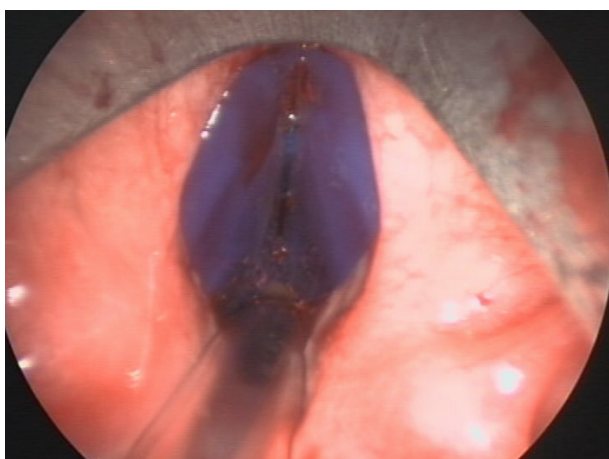

Figure 8: Temporary placeholder in the Lichtenberger technique

Therapy of subglottic stenoses

The cricoid cartilage is the only section in the airway with a complete cartilaginous circumference and has physiologically the smallest cross-section of the airway. Together with numerous other factors this makes the cricoid to a predilection area for the development of stenosis. Accordingly, this is the section for the largest number of all acquired and congenital diseases that can lead to a narrowing of the lumen of the airway. Intubation associated lesions remain the largest group by far. Other important causes are the **congenital cricoid stenosis**, **congenital hemangioma** and other rare benign tumors and malformations such as cysts. For the group of congenital hemangiomas in the airway, a drug therapy with propranolol has been available for some time, which may be sufficient in some cases as a sole intervention [21]. All other stages require non-conservative intervention as soon as a certain level of symptoms is present.

There is consensus among all major centers that the role of laser surgery is considered very limited in the child's subglottic airway. With careful indication and a technically accurate application, mild stenoses can be treated successfully. However, this success is offset by a high recurrence rate, which then should not be treated with repeat laser surgical interventions [27]. Doing so may trigger structural changes in the surrounding cartilage, resulting in an increase of the grade and length of the stenosis. In the worst case, the use of laser may negatively affect the chance for a later successful open reconstruction. Therefore, in case of a restenosis after laser application, an open procedure must be used for treatment. In the past, a variety of laser types have been propagated. The widest experience and the best results have been achieved with the CO₂ laser, which produces the lowest thermal collateral damage and is particularly accurately applicable. Despite the below-described new endoscopic method of high-pressure balloon dilatation, the open reconstructive procedures remain the most important cornerstones in the treatment strategy for infantile subglottic stenosis due to their excellent results and high reproducibility.

In laryngotracheal reconstruction (LTR) the stenotic structures are extended by insertion of autologous cartilage grafts. The frequency of this operation is significantly decreased by the competition of endoscopic ablative techniques. However, especially in multi-level stenosis with inclusion of the glottis, LTR remains the method of choice. A special variation is the laryngotracheal reconstruction with autogenous thyroid cartilage (LTR-S), which may solely be performed up to the age of 12 or maximally up to 18 months of life.

Ever since the introduction of cricotracheal resection (CTR) into pediatric tracheal surgery by Monnier this method has become the method of choice for all high-grade subglottic stenoses without affection of the glottis due to the excellent results and reduced patient stress.

Laryngotracheal reconstruction with autologous thyroid cartilage

The small dimensions of the early infantile airway lead to a very rapid restriction of the airway lumen at a relatively low decrease in diameter. Conversely, however, a slight increase in the circumference results in a considerable increase in the cross sectional area of the airway. A simple calculation can illustrate this: If you take the diameter of the subglottic airway in neonates with 4.5 mm, the result is a circumference of about 14 mm. The area of this cross section is then 15.9 mm². If it is possible to increase the circumference by only 3 mm, this will result in a cross sectional area of 22.9 mm² for breathing. Thus, a slight increase of the circumference by about 3 mm is sufficient, in order to increase the available cross sectional area for breathing by about 44%!

On the basis of this consideration, comparatively minor invasive methods are sufficient to realize a significant effect of airway expansion in infancy. This principle is

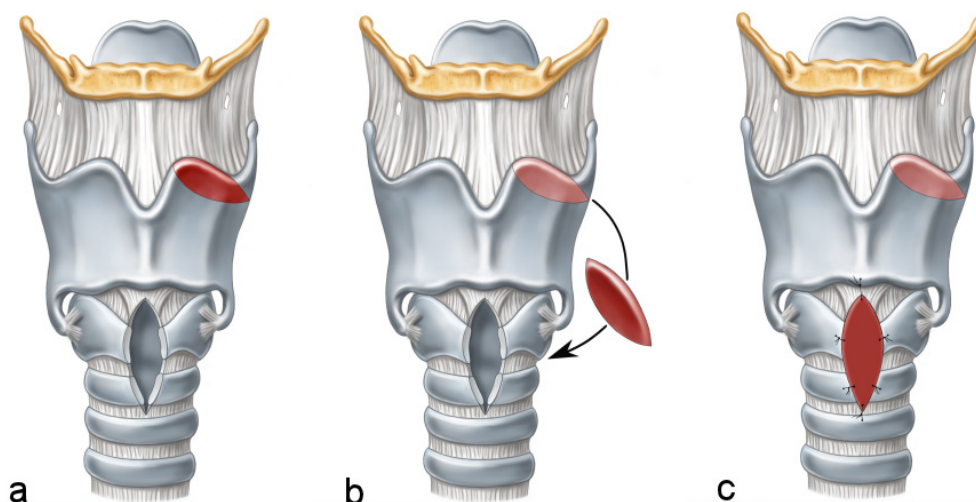


Figure 9: Laryngotracheal reconstruction with autogenous thyroid cartilage
(Illustration: courtesy of Sonja Burger)

taken into account in laryngotracheal reconstruction with autogenous thyroid cartilage (LTR-S), which has been described first by Fraga in 2001 [10]. In this method, the cricoid cartilage, the cranial trachea and caudal thyroid cartilage are exposed via an external access similar to the established procedure of the cricoid split, then the cricoid cartilage, as well as the first and second tracheal cartilage if necessary, are incised. An approximately 2x3 mm wide piece of cartilage is obtained from the free top edge of the thyroid cartilage (Figure 9). This is an elegant way of reconstruction with autologous tissue in the same area of operation and does not require an additional incision. The thickness of the upper edge of the thyroid cartilage is usually equal to the dimensions of the cricoid cartilage in this age group. With careful avoidance of the incisura thyroidea, no functional or cosmetic sequelae will result from this, and the additionally produced morbidity is minimal.

The cartilage obtained is then introduced into the split cricoid cartilage and fixed with sutures. Due to the dimensions it is technically demanding and should be performed with the aid of optical magnification, preferably with loupes. The tracheal tube that is left in situ serves as a scaffold for the integration of the said graft. Postoperatively, the child remains intubated for 2–4 days. Granulations at the site of the inserted graft are not rare, but can easily be endoscopically ablated. In persistent cases, the application of mitomycin C regularly leads to a permanent cessation of granulation.

This procedure can now be considered the gold standard in the treatment of congenital cricoid stenosis [43]. However, the consistently positive experience has also led to the use of this technique for other indications. In the submucosal excision of congenital subglottic cysts LTR-S is a useful prophylactic method to prevent scarring stenosis. In addition, intubation associated scarring stenosis can be treated in infancy with good results (Figure 10, Figure 11).

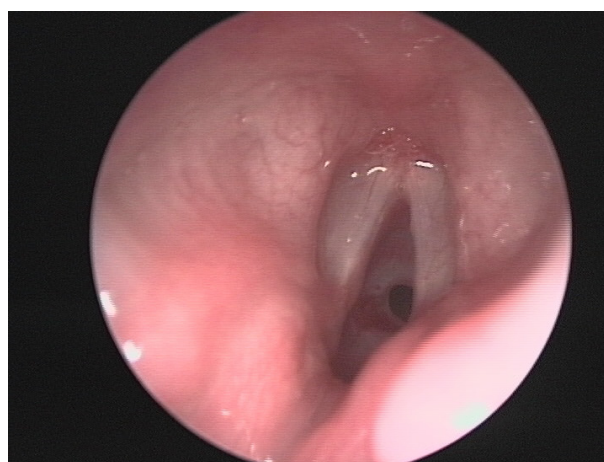


Figure 10: Subglottic stenosis grade III in a 4-months-old female

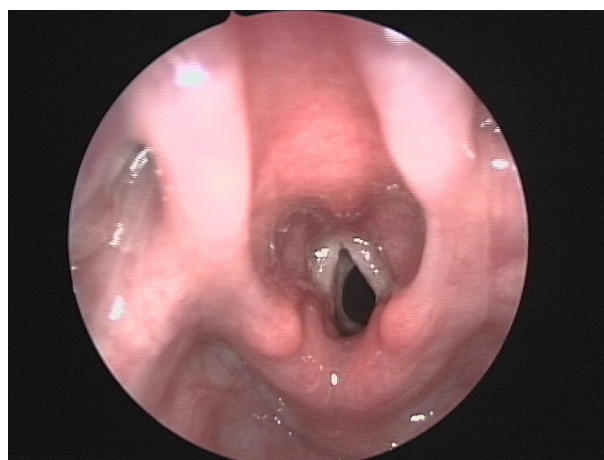


Figure 11: Postoperative endoscopy 10 weeks after LTR-S

The LTR-S offers significant advantages compared to the other methods described: the procedure is associated with minimal additional morbidity and the success rates are high. Of particular importance, however, is that all

reconstruction options are still available: both the classical LTR with autologous rib cartilage as well as the cricotracheal resection. Even if LTR-S does not succeed in reconstructing a permanently adequate airway, the process can still be very valuable to avoid a tracheostomy within the first 12 months of life and helps to bring the child to an age with adequate translaryngeal breathing, when the open reconstructions can be applied with very good prospects of success and an acceptable risk profile. The procedure is only minimally invasive and much less stressful than a complete cricotracheal resection, an important advantage in these young patients that are often multi-morbid, syndromic or unstable for other reasons such as prematurity.

The LTR-S is therefore, almost regardless of the underlying etiology, the method of choice for the treatment of subglottic airway stenosis up to 12 months of life. In many cases, it is sufficient even as the sole procedure to reconstruct a sufficient and durable airway that is growing with age. The earliest we performed this procedure on our patients was on a premature infant in the 22nd week of gestation with a birth weight of 1000 g, which had a congenital cricoid stenosis. In this case, the LTR-S and a high-pressure balloon dilatation, performed in the interval, could arrange a stable, sufficient airway for natural breathing and almost natural growth of the laryngeal reconstruction.

Laryngotracheal reconstruction with autologous rib cartilage

The generic term laryngotracheal reconstruction (LTR) sums up methods, where the stenosis is not resected but augmented by interposition of autologous tissue [42], [49]. Typically, the patient's own rib cartilage is used, which is then placed anterior and/or posterior of the region of the stenosis, typically in the place of the lamina or the band of the cricoid cartilage. In the past years, this treatment method has significantly lost its position for treatment of subglottic stenosis without affection of the glottis compared to cricotracheal resection. However, the LTR still remains the method of choice in complex stenoses with affection of the glottis (Figure 12, Figure 13) and has also continued to be very successful in the therapy of recurrent stenosis after insufficiently successful cricotracheal resection [14]. Furthermore, in complex multi-level stenoses a primary combination of CTR and LTR can be applied [13]. Most authors advocate this application from the 2nd to 3rd year of life. For children younger than 2 years, removing rib cartilage is associated with a significant morbidity. Furthermore, the preparation and fitting of rib cartilage in this age group is often quite problematic, at least in the classic way with transplantation of autologous rib cartilage. LTR is therefore usually unsuitable in the age group up to 12 months. In this situation the LTR-S described above, which has been specially developed for the age group up to 18 months, serves as a great alternative.

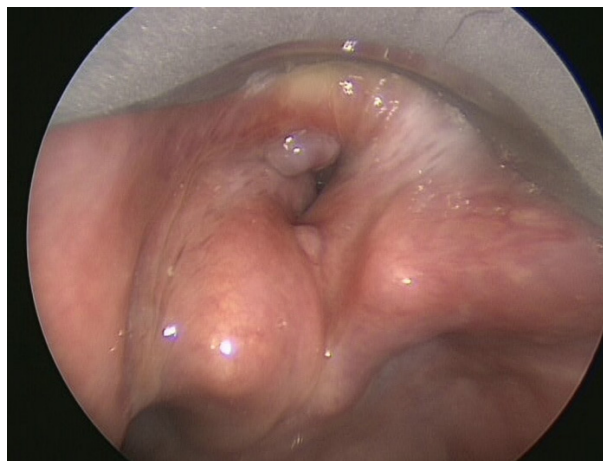


Figure 12: Complex glottic and subglottic stenosis after multiple interventions

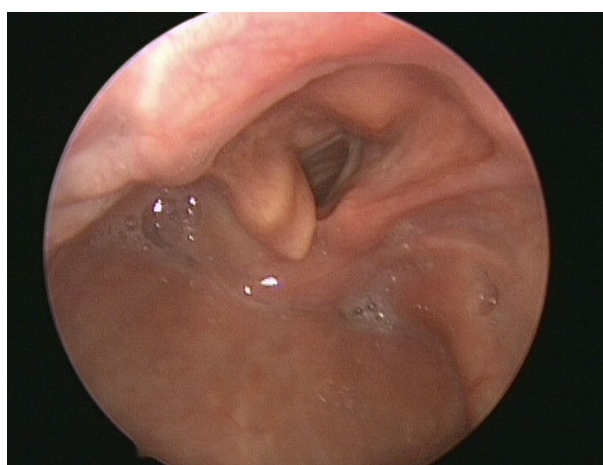


Figure 13: Postoperative result after laryngotracheal anterior and posterior reconstruction

In LTR, a partial laryngofissure is performed, which can be expanded to a complete laryngofissure in far cranially reaching stenoses involving the interarytenoid fold. For posterior LTR, the atraumatic but complete exposure of the cricoid plate is crucial and is greatly facilitated by using a special laryngofissure separator (Figure 14, Figure 15). The cricoid plate is incised vertically in its whole length, whereupon the underlying hypopharynx must be strictly protected. In case of an interarytenoid fibrosis it has to be completely included in the incision. The rib cartilage is taken from the 7th-8th rib and prepared like a deep podium: the "1st place" projects into the lumen and should be covered with perichondrium to prevent granulation. The width should be tailored to the individual situation and the age of the child. The "2nd place" and the "3rd place" serve as flanges that come to lie below the cricoid plate. The graft hold through its internal stress, a fixation with sutures is not required (Figure 15). The anterior LTR is running on the same principle, but the graft is thinner and is fixed precisely with sutures (Figure 16).

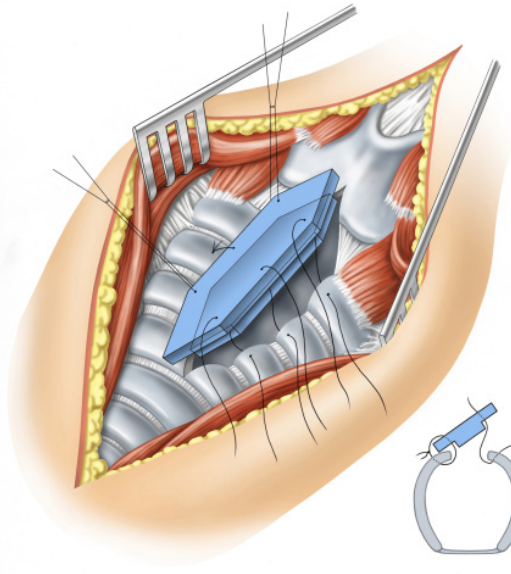


Figure 14: Anterior laryngotracheal reconstruction
(Illustration: courtesy of Sonja Burger)

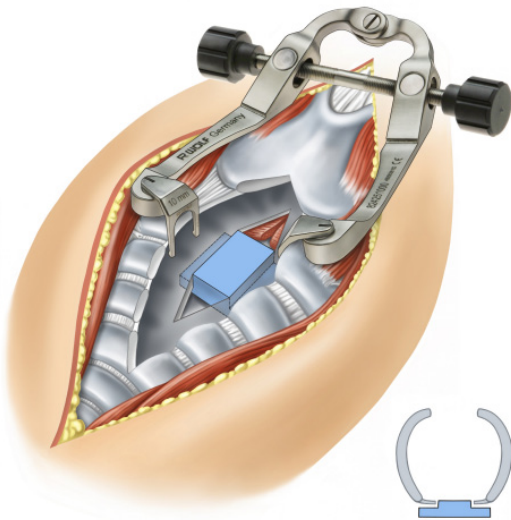


Figure 15: Posterior laryngotracheal reconstruction with laryngofissure-spreader
(Illustration: courtesy of Sonja Burger)

Advantages of the LTR are manageable difficulty and high reproducibility. The potential complication is little dramatic, but usually the vocal function is considerably restricted. In contrast there are some drawbacks. A transient tracheotomy is inevitable, except for the isolated front wall extension in the anterior LTR, but that only comes into consideration in mild stenosis. The process is therefore staged. For post-operative stenting of the destabilized larynx, a placeholder must be inserted, often causing more problems, especially granulation and lesions caused by pressure. This often makes further corrective surgery inevitable. The donor site of the graft on the thorax triggers an additional morbidity, which is often a greater

problem than the cervical wound. Of particular importance, however is, that high-grade stenoses, long stretches of malacia and pronounced granulating scar tissue do not provide good conditions for healing of autologous cartilage grafts in childhood. In these cases the results of LTR are clearly inferior to CTR.

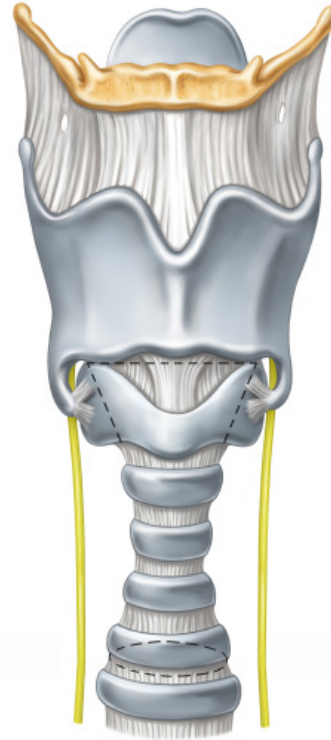


Figure 16: CTR: resection boards
(Illustration: courtesy of Sonja Burger)

Cricotracheal resection

Cricotracheal resection has quickly become the method of choice for treating high grade cricoid stenoses in infancy ever since its introduction to pediatric surgery through Monnier [29]. The main advantages compared to the former method of choice, the LTR, are a higher success rate and a shorter treatment period. Through complete resection of pathologic sections and the primary epithelial reconstruction, postoperative swelling and granulation can be minimized. Leaving pathologic parts in situ, out of the fear of a too extended resection of the trachea, presents with a high risk for restenosis. In the CTR, the anterior cricoid arch is resected with the caudally lying parts of the stenosis. The completely denuded cricoid plate can also be thinned with a diamond drill and is then again completely epithelially covered with the pars membranacea after circumferential mobilization of the caudal trachea by creating a thyrotracheal anastomosis. In a far reaching cranial stenosis (maximally up to the subglottic part of the vocal cords), the trachea may be included into the remaining cricoid cartilage in terms of

an invagination which results in a primary thyrotracheal anastomosis (Figure 17).

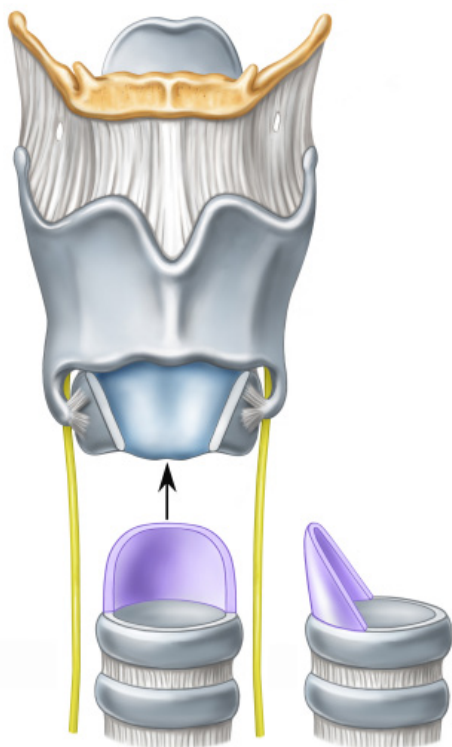


Figure 17: CTR: after removal of the stenosis, before anastomosis

(Illustration: courtesy of Sonja Burger)

However, if the stenosis lies lower in the cricoid, the anterior branch of the cricoid with a caudal slant can be resected. The trachea is then anastomosed obliquely to the massae laterales of the cricoid and to the front of the thyroid, causing a considerable additional lumen gain (Figure 18). The tension free anastomosis is of high importance for the success of the operation, so both the supralaryngeal and the mediastinal release must be executed determinedly and technically accurate.

The primary resection makes the process almost independently applicable from the underlying pathology and thus its usage can be extremely versatile. An essential precondition is a certain distance to the uninvolved glottis from the cranial boarder of the stenosis (Figure 19). However, the technical implementation of the CTR is challenging and is associated with a significant learning curve. The possible complications of a lesion to the recurrent nerve and a dehiscence of the anastomosis are rare but serious. The postoperative extubation phase may be agitated and requires an experienced pediatric intensive care to avoid hasty re-tracheotomy that can undo the reconstruction result. If a good result has been achieved (Figure 20) a restenosis is highly unlikely, because the thyrotracheal anastomosis grows reliably [28].

The application in infants is possible and described [12]. However, this complex resection and reconstruction sets

high technical requirements that involve a significant risk of complications, given the small size of the neonatal airway. In particular, one must keep in mind that the CTR “burns the bridges behind one.” Should there be a restenosis, the further possibilities of reconstruction are highly restricted. For these reasons, the indication for CTR should be made extremely strict in the first 12 months of life and should only be used when alternative, less risky methods are either exhausted or do not appear reasonable in the first place.

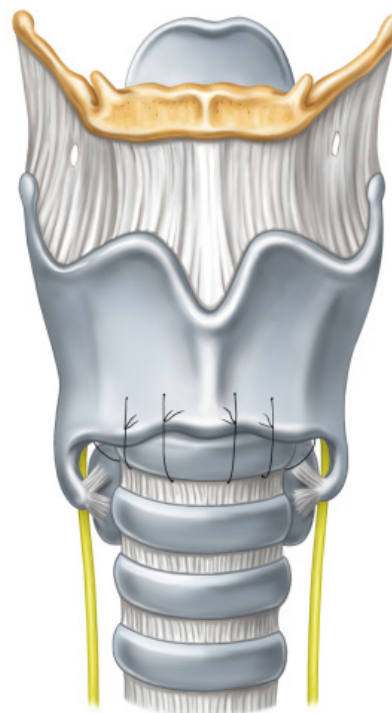


Figure 18: CTR: thyrotracheal anastomosis

(Illustration: courtesy of Sonja Burger)

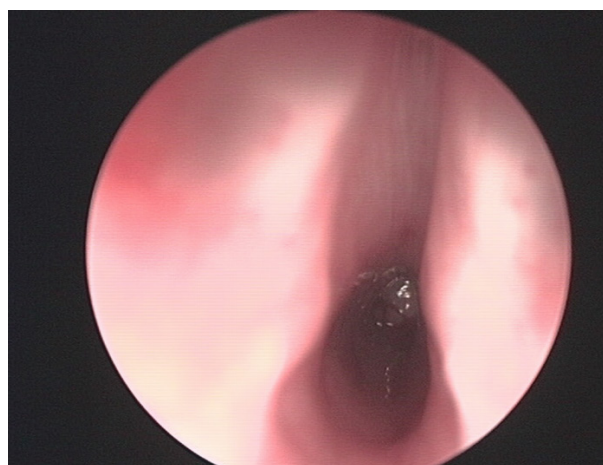


Figure 19: Subglottic stenosis grade III in a 5-year-old girl

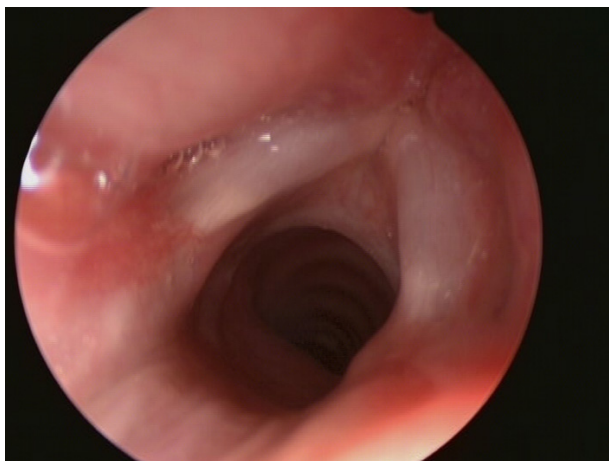


Figure 20: Control endoscopy 6 weeks after CTR

High pressure balloon dilatation

The application of high-pressure balloon dilatation has been internationally widely accepted in pediatric laryngology in recent years [39]. In this method, high pressure balloons, that are available in different lengths and diameters, are microlaryngoscopically positioned on the level of the stenosis and inflated to a pressure of 6–8 atmospheres. Typically, multiple repetitions are recommended to secure the result. The proponents postulate a much higher success rate compared with the classical bougienage, since the balloon exercises a concentric, radiating power, which is considerably more gentle to the surrounding tissue than the application of tangential shear forces in conventional bougienage. In congenital cricoid stenosis sole balloon dilatation is not sufficient and is therefore combined with an endoscopic cricoid split [20]. However, in cicatricial stenoses, the sole, possibly repeated balloon dilatation is recommended.

Our own experiences with this procedure are varied. Due to the high restoring forces and large elasticity of neonatal tissue in our patients, we have not yet succeeded in reproducing the positive effects of high pressure balloon dilatation in scar tissue stenoses. As a supporting procedure for discrete post-therapeutic recurrent stenosis or as a less invasive initial therapy trial in discrete stenosis, however, the application of this method seems permissible and reasonable.

Tracheotomy in infancy

In perinatal medicine, avoiding tracheotomy is a high goal. Unlike in the adult intensive care, longer periods of intubation are accepted in order to avoid tracheotomy. This is not only due to the understandable desire to avoid additional trauma and stigmatization of the child and the family but also that neonatologists are aware that a tracheotomy in early childhood represents a significant risk to the child. This applies not only to the surgical procedure itself, which is technically significantly different from the method in later life and also challenging to even an experienced surgeon. A significant risk remains even

after successful installation and healing of tracheotomy: the combination of low neck dimensions, with well-established subcutaneous adipose tissue and in general only little pulmonary reserve for apnea, leads to a high risk of accidental dislocation of the cannula.

In infants, the tracheotomy canal is immediately functionally closed by the surrounding soft tissue after removal of the tube. Not infrequently, this is only noticed when the compensatory reserve is already depleted. Therefore, it comes to repeat cases of death by laying or dislocation of an otherwise clean tracheotomy [11]. Unlike in any other age a tracheotomy in infants therefore does not represent a reliable airway management. Rather, the need for continuous monitoring is highly required. Because of this increased mortality, a tracheotomy should only be applied in very strict indication limits in infants under 18 months of life. However the incidence of tracheotomy appears to be increasing in this age group [5]. Other, possibly complex treatment options should be intensively considered and used in order to meet the goal of preventing a tracheotomy.

Unlike in adults, dilatation tracheotomy or a bedside implementation on the ICU is contraindicated. Top priority is to affect the stability and structure of the trachea as little as possible. Therefore, excision of portions of the anterior tracheal wall, the construction of a björk-flap and a visor tracheostomy should be avoided. Because of the flexibility of the child's trachea, a sole vertical incision about 1–2 tracheal rings is always sufficient. With 2–6 mucocutaneous sutures tracheotomy is opened and fixed. A proven practice is to leave the thread ends of two lateral sutures long and clearly mark them. In case of accidental tube dislocation, the postoperatively swollen tissue can be spanned by pulling these thread ends. Thus a soft tissue collapse of the airway is immediately avoided and facilitates the safe reinsertion of the tube massively.

Foreign bodies in the child's airway

In infants, a hyperacute asphyxiation is commonly seen after an often unobserved aspiration of a foreign body. A foreign body then leads to an inspiratory stridor when the foreign body is stuck in the glottis or supraglottic. In a tracheal position of the foreign body, it usually presents with a combined inspiratory and expiratory stridor. In peripheral position of the foreign body, side-different findings (clinically and radiologically) with hyperinflation or decreased ventilation are typical. A prolonged course bears the risk for bronchopneumonia. The most dangerous case of a foreign body is acute asphyxia. As long as the patient is conscious, but the cough is inefficient and suffocation is at threat, the head should be kept low in the prone position. After five blows on the back an inspection and possibly removal of the foreign body out of the throat has to be undertaken. If this is not successful, it is recommended to perform 5 chest compressions as in CPR in infants, or in older children, 5 Heimlich maneuvers with abdominal compression. In cases of persistent failure

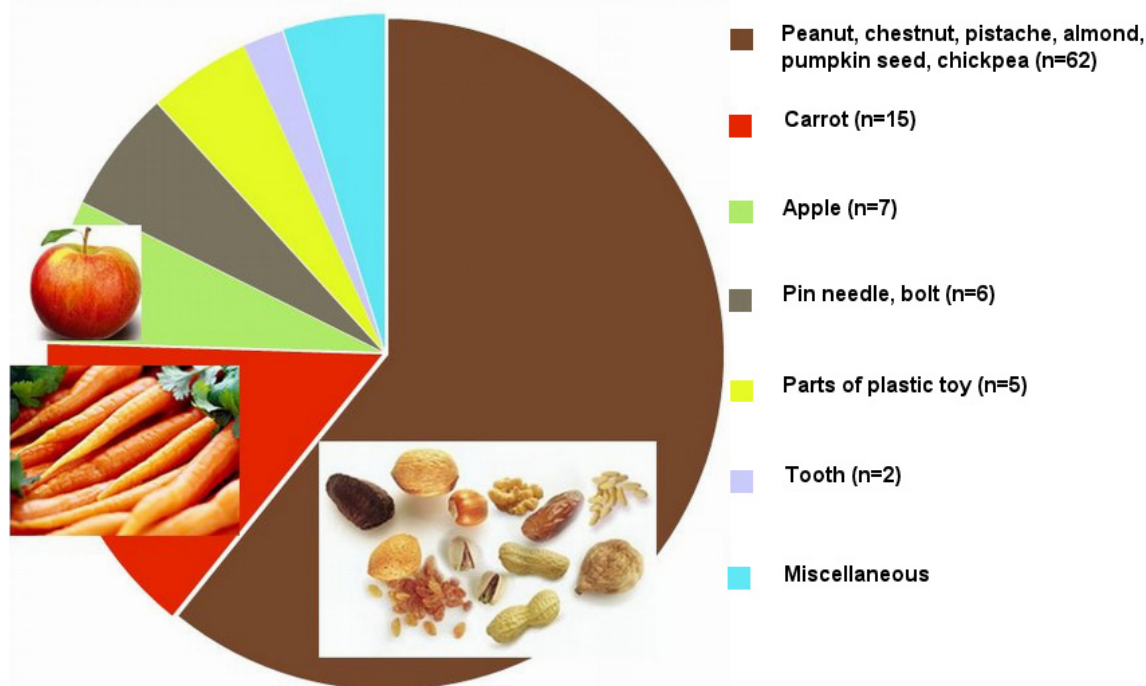


Figure 21: Characteristics of the foreign bodies retrieved at "Klinikum Stuttgart" between 2006–2012

this is followed by an intubation attempt and resuscitation. Every child with foreign body aspiration must be accompanied by a doctor during transportation because coughing can lead to a secondary dislocation of the foreign body and thus a possible life-threatening obstruction [31].

The majority of foreign bodies in the tracheobronchial system is characterized and correctly diagnosed by the triad of sudden coughing or choking, auscultatory wheezing and unilaterally attenuated breath sounds [16]. Thus, collecting a good history from the parents is of particular importance. However, the history is not typical in all cases [26] or the aspiration may have been unobserved. Therefore, in up to 15% of the cases [38] it leads to persistent foreign bodies, which are then correctly diagnosed by bronchopulmonary complications after several days. In addition to auscultation, the chest X-ray is part of the low-threshold primary diagnosis. Most foreign bodies, however, are food related and are not radio-opaque. Of the 106 retrieved foreign bodies in our clinic in the period from 2006 to 2012, only 22 were of a material that was primarily radiologically detectable. Nuts, seeds and carrot pieces in this series were most frequently aspirated (Figure 21). The indications for tracheobronchoscopy should therefore not be too tight. Thorough diagnosis and adequate clinician experience kept the rate of endoscopic interventions without foreign body detection within tolerable limits. Hence in the series mentioned, we detected 106 foreign bodies whereas in only 43 cases we could not prove one.

The removal of a foreign body is still a domain for rigid bronchoscopy under general anesthesia. Basically, the procedure shall be performed independent of the time of day immediately following indication. Only in respiratory

stable children beyond infancy is it acceptable to wait for fasting of the patient when the child is monitored.

The rigid endoscopy offers clear advantages over the flexible techniques on the basis of a clear view in the large bronchi, the possibility for direct removal of the foreign body and the safe hemostasis. The systematic exploration of all sections of the tracheobronchial tree is very important, so as not to miss multiple foreign bodies or dislocated fragments. Indeed, the right main bronchus is considered the preferred site for aspirated foreign bodies. In our series however, of 106 foreign bodies, 43 were left-side and 48 were right-side foreign bodies, a fairly balanced distribution. In 15 cases the findings were retrieved from the trachea. Depending on the size, consistency, and already occurred reaction of the surrounding tissue the extraction can be difficult even for experienced surgeons. Optical pliers, gripping instruments with integrable rod lens system, and the jet ventilation can greatly simplify the process.

Recurrent respiratory papillomatosis

The recurrent respiratory papillomatosis (RRP) is a rare disease affecting both respiration and phonation (Figure 22). The course of the disease is heterogeneous and may require more than 100 surgical procedures in one particular individual. Boys are more often affected than girls. In case of condylomata acuminata in the mother, the risk of disease is 200 times higher. The cause is a viral infection predominantly with HPV 6 and 11, the latter being attributed to a more aggressive course. The

clinically apparent recurrence is based on an activation of DNA in normal-appearing mucosa.

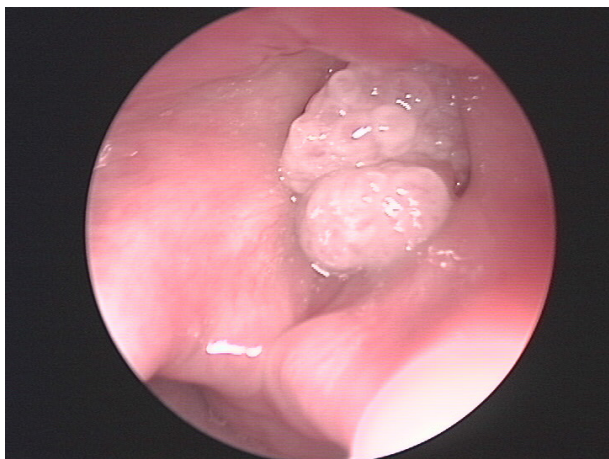


Figure 22: Fluctuating papilloma of the right vocal cord with subtotal laying of the glottis

The most common symptom of the RRP is hoarseness; stridor and dyspnea affect almost exclusively younger children. A curative approach to treating the viral infection is not available. Therefore, the treatment strategy is repeated ablative microlaryngoscopic surgery, but only as little as possible and primarily oriented on the functional aspect of securing both breathing and vocal function as long as possible. Due to the tendency of bleeding and the associated poor visualization, the standard instruments for microlaryngoscopy are not well suited for ablation of papillomas. For a long time the use of a CO₂ laser was considered superior [7]. Thereby a microsurgical removal should be preferred over a mere vaporization to reduce the scarring. Other laser modalities have been used but have not gained widespread acceptance. The use of microdebriders ("shaver") is the de-facto standard as of today. For this, a special design with sufficient length and small diameter is used. The correct rotational speed, not higher than 200–300 U/min, is of particular importance. Thus, a very accurate, bloodless and very gentle removal of the mucosa is guaranteed. The superiority of microdebriders over the CO₂ laser could be proven in numerous studies [34], [35], [40].

In many cases, the sole surgical removal remains unsatisfactory because of the rapid recurrences, therefore the goal has always been to find an adjuvant drug therapy [4].

Interferon- α

The use of interferon- α was advocated particularly for severe progressive courses of the disease after a placebo-controlled double-blind study showed a dose-dependent reduction of papilloma growth [15]. High rebound effects after stopping the drug therapy and partially severe side effects after prolonged use have practically led to a complete dropout of the medical application of interferon- α in the treatment of RRP.

Indole-3-carbinol (I3C)

The positive impact of this side effect-free substance that occurs naturally in many types of cabbage, has been postulated in numerous publications, but its effectiveness could never be verified under controlled conditions [24].

Cidofovir

Cidofovir is an antiviral agent, which acts in the manner of a prodrug as a cytosine analogon by enzymatic activation in the cell. The antiviral effect is produced by inhibition of DNA transcription. Cidofovir is effective against papilloma, herpes and poxy virus. A formal approval is only given for the intravenous treatment of CMV retinitis in HIV-positive patients. It is contraindicated in renal insufficiency.

Positive reports for the off-label use in RRP have existed since the late 90s [44] and have been reproduced in numerous case series thereafter. Some of the RRP could be brought to cessation permanently, with many authors reporting significantly prolonged treatment intervals. However, not all patients respond to treatment [2], [9], [30], [36], [45], [51]. These studies mentioned showed no or only minimal side effects in the intralesional applications, which differed significantly in doses and intervals. Based on this positive experience, intralesional therapy with cidofovir became a de facto standard (mostly in combination with microsurgical removal) in many specialized centers around the world. This treatment has frequently been considered far superior to the sole surgical therapy and the previous adjuvant treatment by both the physicians and the affected patients.

In January 2011 an official warning by the manufacturer, which strictly discouraged from the off-label use, was issued through the European health authorities. It took several months in all countries before the warning reached the operative acting laryngologists. The warning was first issued after serious side effects were observed in applications in ophthalmology and internal medicine. However, in these cases massively higher total doses were administered intravenously or intraocular in contrast to endolaryngeal intralesional application. The warning included unspecified information to nephrotoxicity, neutropenia, carcinogenicity and the note of possible deaths. Since early 2013, the manufacturer has suspended the production of the original preparation Vistide without further comment. For the American market a generic drug is being produced by a different manufacturer, but it is only available in Europe through international pharmacies. The endolaryngeal application was never addressed by the manufacturer, and there is still no evidence of comparable side effects in the treatment of RRP. Under the coordination of the European Laryngological Society (ELS) a Europe-wide data collection was launched to illuminate the question of the safety of an endolaryngeal intralesional cidofovir therapy. 635 records were provided by 16 centers in 11 countries. In no case did nephrotoxicity or leukopenia occur, and still there was no evidence of a

post-therapeutic malignant degeneration. The results of the study were published as a consensus paper [46]. The hope of many users to obtain a weakening of the manufacturer warning for use in the larynx on the basis of this positive data, however, has not been confirmed so far. With events seen in this light, some centers have terminated the treatment of RRP with Cidofovir. As no adequate alternative to Cidofovir as most effective adjuvant treatment of severe cases of RRP is yet available, most laryngologists who have experience with the substance are not willing to forgo this treatment option [8]. However, the indication criteria are set very strictly. The elucidation of the guardians must meet particularly high requirements in the manner, extent and documentation.

Laryngo-tracheitis

Inflammatory caused acute respiratory tract stenoses are mainly caused by pathogens and are divided into three main groups: the acute stenosing laryngotracheitis, bacterial tracheitis and epiglottitis [31].

The acute stenosing laryngotracheitis is usually defined as pseudocroup from genuine croup during diphtheria. Internationally this distinction is no longer common because of the extreme rarity of laryngeal diphtheria. For this a recurrent from a non-recurrent form of "croup" is distinguished.

The treatment is predominantly in the hands of the pediatrician and can mostly be managed on an out-patient basis. Thus, the croup is one of the most common reasons for visiting a pediatric emergency department in the U.S. with 15% of all cases, of which only between 1–8% must be hospitalized. Intubation is required only rarely with 3% of the children hospitalized because of croup [54].

It is a nonspecific inflammation of the subglottic larynx of viral etiology, and many types of virus can be detected. Significant negative contributing factors are tobacco smoke, air pollution and oesophageal reflux. Children between 6 months and 3 years of age are affected the most, with a marked predominance of the male sex. Approximately 10–15% of all children suffer from a viral croup once in their life.

The symptoms are characterized by a dry barking cough and inspiratory stridor and usually occur suddenly at night in previously healthy children.

The diagnosis is made clinically by the pediatrician. A laryngoscopy by an ENT medical is indicated only in exceptional cases and in no way represents a first measure.

The treatment of choice is the single oral, weight adjusted dose of dexamethasone that should be generously indicated even in milder forms. The inhalation of humid air could not be scientifically verified and is therefore no longer recommended. However, many experienced clinicians are nevertheless convinced that the inhalation of cool moist air is a first and effective measure, since the air temperature was not an observed variable in the relevant studies. In cases of higher severity, the inhalation

of epinephrine is recommended. In very rare cases intubation comes into consideration as a last resort.

Bacterial tracheitis is a rare disease, typically following a viral infection in the sense of a secondary infection and developing more slowly. The symptoms are much more distinct than in croup, especially that the fever is higher. The croup treatment does not apply, and intubation may be necessary. Typical pathogens are *Staphylococcus aureus*, streptococci of serological group A or *Haemophilus influenzae*. The treatment of choice is parenteral antibiotic therapy.

Acute epiglottitis is a fulminant clinical picture that is characterized by a hoarseness of voice and shortness of breath. The affected child has high fever and appears acutely ill, strictly avoiding a lying position. Swallowing is painful and is avoided with the result of "drooling". The inflammation is always caused by bacteria and can be caused by beta-hemolytic streptococci, but is predominantly triggered by *Haemophilus influenzae*. Since the introduction of Hib vaccination, acute epiglottitis is found only sporadically.

Notes

Competing interests

The laryngofissure separator mentioned in the text was developed by the author in collaboration with the company Wolf. The company contributed to the travel costs for several congress visits of the author. He does not receive any financial benefit from the sale of the device.

Acknowledgement

The translation of the article was executed with substantial support from Dr. med. Katharina Fischer, Stuttgart.

References

1. Berkowitz RG. Natural history of tracheostomy-dependent idiopathic congenital bilateral vocal fold paralysis. *Otolaryngol Head Neck Surg.* 2007 Apr;136(4):649-52. DOI: 10.1016/j.otohns.2006.11.050
2. Bielamowicz S, Villagomez V, Stager SV, Wilson WR. Intralesional cidofovir therapy for laryngeal papilloma in an adult cohort. *Laryngoscope.* 2002 Apr;112(4):696-9. DOI: 10.1097/00005537-200204000-00019
3. Carrat X, Verhulst J, Duroux S, Pescio P, Devars F, Traissac L. Postintubation interarytenoid adhesion. *Ann Otol Rhinol Laryngol.* 2000 Aug;109(8 Pt 1):736-40.
4. Chadha NK, James A. Adjuvant antiviral therapy for recurrent respiratory papillomatosis. *Cochrane Database Syst Rev.* 2012;12:CD005053. DOI: 10.1002/14651858.CD005053.pub4
5. Corbett HJ, Mann KS, Mitra I, Jesudason EC, Losty PD, Clarke RW. Tracheostomy—a 10-year experience from a UK pediatric surgical center. *J Pediatr Surg.* 2007 Jul;42(7):1251-4. DOI: 10.1016/j.jpedsurg.2007.02.017

6. Denoyelle F, Mondain M, Gresillon N, Roger G, Chaudre F, Garabedian EN. Failures and complications of supraglottoplasty in children. *Arch Otolaryngol Head Neck Surg*. 2003 Oct;129(10):1077-80; discussion 1080. DOI: 10.1001/archotol.129.10.1077
7. Derkay CS. Recurrent respiratory papillomatosis. *Laryngoscope*. 2001 Jan;111(1):57-69. DOI: 10.1097/00005537-200103000-00007
8. Derkay CS, Volsky PG, Rosen CA, Pransky SM, McMurray JS, Chadha NK, Froehlich P. Current use of intralesional cidofovir for recurrent respiratory papillomatosis. *Laryngoscope*. 2013 Mar;123(3):705-12. DOI: 10.1002/lary.23673
9. Dikkers FG. Treatment of recurrent respiratory papillomatosis with microsurgery in combination with intralesional cidofovir—a prospective study. *Eur Arch Otorhinolaryngol*. 2006 May;263(5):440-3. DOI: 10.1007/s00405-005-1013-3
10. Fraga JC, Schopf L, Forte V. Thyroid alar cartilage laryngotracheal reconstruction for severe pediatric subglottic stenosis. *J Pediatr Surg*. 2001 Aug;36(8):1258-61. DOI: 10.1053/jpsu.2001.25788
11. Fraga JC, Souza JC, Krueel J. Pediatric tracheostomy. *J Pediatr (Rio J)*. 2009 Mar-Apr;85(2):97-103. DOI: 10.2223/JPED.1850
12. Garabedian EN, Nicollas R, Roger G, Delattre J, Froehlich P, Triglia JM. Cricotracheal resection in children weighing less than 10 kg. *Arch Otolaryngol Head Neck Surg*. 2005 Jun;131(6):505-8. DOI: 10.1001/archotol.131.6.505
13. George M, Jaquet Y, Ikonomidis C, Monnier P. Management of severe pediatric subglottic stenosis with glottic involvement. *J Thorac Cardiovasc Surg*. 2010 Feb;139(2):411-7. DOI: 10.1016/j.jtcvs.2009.05.010
14. Hartnick CJ, Hartley BE, Lacy PD, Liu J, Willging JP, Myer CM 3rd, Cotton RT. Surgery for pediatric subglottic stenosis: disease-specific outcomes. *Ann Otol Rhinol Laryngol*. 2001 Dec;110(12):1109-13.
15. Healy GB, Gelber RD, Trowbridge AL, Grundfast KM, Ruben RJ, Price KN. Treatment of recurrent respiratory papillomatosis with human leukocyte interferon. Results of a multicenter randomized clinical trial. *N Engl J Med*. 1988 Aug;319(7):401-7. DOI: 10.1056/NEJM198808183190704
16. Heyer CM, Bollmeier ME, Rossler L, Nuesslein TG, Stephan V, Bauer TT, Rieger CH. Evaluation of clinical, radiologic, and laboratory prebronchoscopy findings in children with suspected foreign body aspiration. *J Pediatr Surg*. 2006 Nov;41(11):1882-8. DOI: 10.1016/j.jpedsurg.2006.06.016
17. Hoff SR, Schroeder JW Jr, Rastatter JC, Holinger LD. Supraglottoplasty outcomes in relation to age and comorbid conditions. *Int J Pediatr Otorhinolaryngol*. 2010 Mar;74(3):245-9. DOI: 10.1016/j.ijporl.2009.11.012
18. Holinger LD. Etiology of stridor in the neonate, infant and child. *Ann Otol Rhinol Laryngol*. 1980 Sep-Oct;89(5 Pt 1):397-400.
19. Holinger LD, Konior RJ. Surgical management of severe laryngomalacia. *Laryngoscope*. 1989 Feb;99(2):136-42. DOI: 10.1288/00005537-198902000-00004
20. Horn DL, Maguire RC, Simons JP, Mehta DK. Endoscopic anterior cricoid split with balloon dilation in infants with failed extubation. *Laryngoscope*. 2012 Jan;122(1):216-9. DOI: 10.1002/lary.22155
21. Javia LR, Zur KB, Jacobs IN. Evolving treatments in the management of laryngotracheal hemangiomas: will propranolol supplant steroids and surgery? *Int J Pediatr Otorhinolaryngol*. 2011 Nov;75(11):1450-4. DOI: 10.1016/j.ijporl.2011.08.002
22. Koitschev A, Sittel C. Laryngomalazie. Wann ist eine Operation sinnvoll [Laryngomalacia. When does surgery make sense?]. *HNO*. 2012 Jul;60(7):573-80. DOI: 10.1007/s00106-011-2379-8
23. Krashin E, Ben-Ari J, Springer C, Derowe A, Avital A, Sivan Y. Synchronous airway lesions in laryngomalacia. *Int J Pediatr Otorhinolaryngol*. 2008 Apr;72(4):501-7. DOI: 10.1016/j.ijporl.2008.01.002
24. Lee JH, Smith RJ. Recurrent respiratory papillomatosis: pathogenesis to treatment. *Curr Opin Otolaryngol Head Neck Surg*. 2005 Dec;13(6):354-9. DOI: 10.1097/01.moo.0000186205.91332.46
25. Lichtenberger G. Endoscopic microsurgical management of scars in the posterior commissure and interarytenoid region resulting in vocal cord pseudoparalysis. *Eur Arch Otorhinolaryngol*. 1999;256(8):412-4. DOI: 10.1007/s004050050177
26. Merckenschlager A, Sanktjohanser L, Hundt C, Schneider K, Nicolai T. Diagnostische Wertigkeit der Röntgenthoraxaufnahme bei tracheobronchialen Fremdkörpern im Kindesalter [Diagnostic value of a plain radiograph of the chest in suspected tracheobronchial foreign body aspiration in children]. *Pneumologie*. 2009 Jun;63(6):325-8. DOI: 10.1055/s-0029-1214672
27. Monnier P, George M, Monod ML, Lang F. The role of the CO2 laser in the management of laryngotracheal stenosis: a survey of 100 cases. *Eur Arch Otorhinolaryngol*. 2005 Aug;262(8):602-8. DOI: 10.1007/s00405-005-0948-8
28. Monnier P, Lang F, Savary M. Partial cricotracheal resection for severe pediatric subglottic stenosis: update of the Lausanne experience. *Ann Otol Rhinol Laryngol*. 1998 Nov;107(11 Pt 1):961-8.
29. Monnier P, Savary M, Chapuis G. Partial cricoid resection with primary tracheal anastomosis for subglottic stenosis in infants and children. *Laryngoscope*. 1993 Nov;103(11 Pt 1):1273-83. DOI: 10.1288/00005537-199311000-00011
30. Naiman AN, Ceruse P, Coulombeau B, Froehlich P. Intralesional cidofovir and surgical excision for laryngeal papillomatosis. *Laryngoscope*. 2003 Dec;113(12):2174-81. DOI: 10.1097/00005537-200312000-00024
31. Nicolai T. Akute Atemwegsobstruktion bei Kindern. *Intensivmed up2date*. 2009;5(4):285-96. DOI: 10.1055/s-0029-1214955
32. Nicollas R, Triglia JM. The anterior laryngeal webs. *Otolaryngol Clin North Am*. 2008 Oct;41(5):877-88, viii. DOI: 10.1016/j.otc.2008.04.008
33. Olney DR, Greinwald JH Jr, Smith RJ, Bauman NM. Laryngomalacia and its treatment. *Laryngoscope*. 1999 Nov;109(11):1770-5. DOI: 10.1097/00005537-199911000-00009
34. Pasquale K, Wiatrak B, Woolley A, Lewis L. Microdebrider versus CO2 laser removal of recurrent respiratory papillomas: a prospective analysis. *Laryngoscope*. 2003 Jan;113(1):139-43. DOI: 10.1097/00005537-200301000-00026
35. Patel N, Rowe M, Tunkel D. Treatment of recurrent respiratory papillomatosis in children with the microdebrider. *Ann Otol Rhinol Laryngol*. 2003 Jan;112(1):7-10.
36. Pransky SM, Albright JT, Magit AE. Long-term follow-up of pediatric recurrent respiratory papillomatosis managed with intralesional cidofovir. *Laryngoscope*. 2003 Sep;113(9):1583-7. DOI: 10.1097/00005537-200309000-00032
37. Reddy DK, Matt BH. Unilateral vs. bilateral supraglottoplasty for severe laryngomalacia in children. *Arch Otolaryngol Head Neck Surg*. 2001 Jun;127(6):694-9. DOI: 10.1001/archotol.127.6.694
38. Reilly J, Thompson J, MacArthur C, Pransky S, Beste D, Smith M, Gray S, Manning S, Walter M, Derkay C, Muntz H, Friedman E, Myer CM, Seibert R, Riding K, Cuyler J, Todd W, Smith R. Pediatric aerodigestive foreign body injuries are complications related to timeliness of diagnosis. *Laryngoscope*. 1997 Jan;107(1):17-20. DOI: 10.1097/00005537-199701000-00006

39. Rutter MJ, Cohen AP, de Alarcon A. Endoscopic airway management in children. *Curr Opin Otolaryngol Head Neck Surg.* 2008 Dec;16(6):525-9. DOI: 10.1097/M00.0b013e3283184479
40. Schraff S, Derkay CS, Burke B, Lawson L. American Society of Pediatric Otolaryngology members' experience with recurrent respiratory papillomatosis and the use of adjuvant therapy. *Arch Otolaryngol Head Neck Surg.* 2004 Sep;130(9):1039-42. DOI: 10.1001/archotol.130.9.1039
41. Schroeder JW Jr, Bhandarkar ND, Holinger LD. Synchronous airway lesions and outcomes in infants with severe laryngomalacia requiring supraglottoplasty. *Arch Otolaryngol Head Neck Surg.* 2009 Jul;135(7):647-51. DOI: 10.1001/archoto.2009.73
42. Schultz-Coulon HJ. Management von Postintubationsstenosen bei Kindern [The management of postintubation stenoses in children]. *HNO.* 2004 Apr;52(4):363-77; quiz 378. DOI: 10.1007/s00106-004-1060-x
43. Sittel C. Subglottische Stenosen im 1. Lebensjahr. Besonderheiten und Therapieoptionen [Subglottic stenosis in the first year of life. Characteristics and treatment options]. *HNO.* 2012 Jul;60(7):568-72. DOI: 10.1007/s00106-012-2508-z
44. Snoeck R, Andrei G, De Clercq E. Specific therapies for human papilloma virus infections. *Curr Opin Infect Dis.* 1998 Dec;11(6):733-7. DOI: 10.1097/00001432-199812000-00014
45. Tanna N, Sidell D, Joshi AS, Bielamowicz SA. Adult intralesional cidofovir therapy for laryngeal papilloma: a 10-year perspective. *Arch Otolaryngol Head Neck Surg.* 2008 May;134(5):497-500. DOI: 10.1001/archotol.134.5.497
46. Tjon Pian Gi RE, Ilmarinen T, van den Heuvel ER, Aaltonen LM, Andersen J, Brunings JW, et al. Safety of intralesional cidofovir in patients with recurrent respiratory papillomatosis: an international retrospective study on 635 RRP patients. *Eur Arch Otorhinolaryngol.* 2013 May;270(5):1679-87. DOI: 10.1007/s00405-013-2358-7
47. Toynton SC, Saunders MW, Bailey CM. Aryepiglottoplasty for laryngomalacia: 100 consecutive cases. *J Laryngol Otol.* 2001 Jan;115(1):35-8. DOI: 10.1258/0022215011906966
48. Unal M. The successful management of congenital laryngeal web with endoscopic lysis and topical mitomycin-C. *Int J Pediatr Otorhinolaryngol.* 2004 Feb;68(2):231-5. DOI: 10.1016/j.ijporl.2003.09.018
49. Vollrath M, Freihorst J, von der Hardt H. Die Chirurgie der erworbenen laryngotrachealen Stenosen im Kindesalter. Erfahrungen und Ergebnisse von 1988 bis 1998. Teil I: Die Laryngotracheale Rekonstruktion [Surgery of acquired laryngotracheal stenoses in childhood. Experiences and results from 1988 to 1998. I: Laryngotracheal reconstruction]. *HNO.* 1999 May;47(5):457-65. DOI: 10.1007/s001060050405
50. Werner JA, Lippert BM, Dünne AA, Ankermann T, Folz BJ, Seyberth H. Epiglottopexy for the treatment of severe laryngomalacia. *Eur Arch Otorhinolaryngol.* 2002 Oct;259(9):459-64. DOI: 10.1007/s00405-002-0477-7
51. Wierzbicka M, Jackowska J, Bartochowska A, Józefiak A, Szyfter W, Kędzia W. Effectiveness of cidofovir intralesional treatment in recurrent respiratory papillomatosis. *Eur Arch Otorhinolaryngol.* 2011 Sep;268(9):1305-11. DOI: 10.1007/s00405-011-1599-6
52. Yuen HW, Tan HK, Balakrishnan A. Synchronous airway lesions and associated anomalies in children with laryngomalacia evaluated with rigid endoscopy. *Int J Pediatr Otorhinolaryngol.* 2006 Oct;70(10):1779-84. DOI: 10.1016/j.ijporl.2006.06.003
53. Zalzal GH, Collins WO. Microdebrider-assisted supraglottoplasty. *Int J Pediatr Otorhinolaryngol.* 2005 Mar;69(3):305-9. DOI: 10.1016/j.ijporl.2004.10.009
54. Zoorob R, Sidani M, Murray J. Croup: an overview. *Am Fam Physician.* 2011 May;83(9):1067-73.

Corresponding author:

Prof. Dr. med. Christian Sittel
 Klinikum Stuttgart, Klinik für Hals-, Nasen-,
 Ohrenkrankheiten, Plastische Operationen,
 Kriegsbergstraße 60, 70174 Stuttgart, Germany, Phone: +49 (0)711/ 278-33201, Fax: +49 (0) 711/ 278-33209
 c.sittel@klinikum-stuttgart.de

Please cite as

Sittel C. Pathologies of the larynx and trachea in childhood. *GMS Curr Top Otorhinolaryngol Head Neck Surg.* 2014;13:Doc09. DOI: 10.3205/cto000112, URN: urn:nbn:de:0183-cto0001124

This article is freely available from

<http://www.egms.de/en/journals/cto/2014-13/cto000112.shtml>

Published: 2014-12-01

Copyright

©2014 Sittel. This is an Open Access article distributed under the terms of the Creative Commons Attribution License (<http://creativecommons.org/licenses/by-nc-nd/3.0/deed.en>). You are free: to Share – to copy, distribute and transmit the work, provided the original author and source are credited.