

Autoimmune Hepatitis During Ledipasvir/Sofosbuvir Treatment of Hepatitis C: A Case Report

Giovanni Covini, M.D.,¹ Elena Bredi,² Salvatore Badalamenti,³ Massimo Roncalli,⁴ Alessio Aghemo,⁵ and Massimo Colombo⁵

We report the case of a woman with chronic hepatitis C and idiopathic thrombocytopenic purpura (ITP) who developed autoimmune hepatitis (AIH) during antiviral therapy with ledipasvir (LDV)/sofosbuvir (SOF). The onset of acute hepatitis rose two weeks after starting treatment with LDV/SOF when HCV-RNA tested negative, suggesting a link between rapid HCV clearance and *de novo* autoimmune diseases. *Conclusion:* This case report proposes new immunologic scenarios in patients with hepatitis C virus (HCV) with laboratory or clinical signs of autoimmunity during direct-acting antiviral (DAA) therapy. (*Hepatology Communications* 2018;2:1179-1183).

AIH is a rare disease that in the majority of patients occurs without any identifiable trigger. This is in contrast with patients who develop AIH as a consequence of exposure to medications, such as anti-inflammatory molecules, anti-tumor necrosis factor α monoclonal antibodies, and immune checkpoint inhibitors.⁽¹⁾ In 2013, a coformulated oral regimen consisting of a nonstructural protein 5A (NS5A) inhibitor (LDV) and an NS5B nucleotide analog inhibitor (SOF) of the HCV became the standard of care to treat chronic infection with HCV genotypes 1 and 4 in adults and more recently in adolescents. Studies of antiviral therapy of HCV, while highlighting the safety and effectiveness of DAA regimens, have also reported sporadic episodes of adverse effects associated with immune dysregulation.⁽²⁾ We report the case of a woman with chronic hepatitis C and idiopathic thrombocytopenic purpura (ITP) who developed AIH during antiviral therapy with LDV/SOF.

The Case

A 72-year-old woman with chronic hepatitis C genotype 1b, arterial hypertension, type 2 diabetes mellitus, and ITP, who was diagnosed on the basis of anti-platelet glycoprotein Ia/IIa autoantibodies, was referred following the onset of acute hepatitis 2 weeks after starting treatment with LDV and SOF. Infection with HCV was diagnosed in 2002, but antiviral therapy was deferred to avoid worsening of severe ITP using interferon-based regimens. Since 2002, the patient had been under biannual surveillance with liver enzyme values repeatedly testing normal. In 2016, hepatitis flared with serum alanine aminotransferase (ALT) of 160 U/L and aspartate aminotransferase (AST) of 135 U/L; these were associated with 1.2 mg bilirubin, a low platelet (PLT) count (100,000/mm³), and a low virus load (HCV-RNA 520 IU/mL). Gamma-glutamyltransferase, alkaline phosphatase, and gamma

Abbreviations: AIH, autoimmune hepatitis; ALT, alanine aminotransferase; ANA, anti-nuclear antibody; DAA, direct-acting antiviral; DILI, drug-induced liver injury; HCV, hepatitis C virus; IgM, immunoglobulin M; ITP, idiopathic thrombocytopenic purpura; LDV, ledipasvir; PLT, platelet; SOF, sofosbuvir.

Received February 23, 2018; accepted July 17, 2018.

© 2018 The Authors. *Hepatology Communications* published by Wiley Periodicals, Inc., on behalf of the American Association for the Study of Liver Diseases. This is an open access article under the terms of the Creative Commons Attribution-NonCommercial-NoDerivs License, which permits use and distribution in any medium, provided the original work is properly cited, the use is non-commercial, and no modifications or adaptations are made.

View this article online at wileyonlinelibrary.com.

DOI 10.1002/hep4.1248

Potential conflict of interest: Dr. Colombo advises and is on the speakers' bureau for MSD and AbbVie. Dr. Aghemo is on the speakers' bureau and received grants from Gilead, AbbVie, MSD, and Bristol-Myers Squibb and is on the speakers' bureau for Janssen. The other authors have nothing to report.

globulin levels were within the normal range (15%). A liver biopsy showed moderate portal-based active hepatitis (grade 2) without interface or lobular activity consistent with chronic HCV infection, with moderate fibrosis (stage 3) according to a FibroScan value of 11 kPa. At that time, no signs of AIH were present and serum autoantibodies were not tested. The patient had been receiving insulin and carvedilol 6.25 mg twice a day for more than 15 years. At this point, the caregivers decided to start LDV/SOF therapy for HCV.

After 2 weeks of antiviral therapy, ALT and AST flared to 923 U/L and 752 U/L, respectively, whereas serum markers of cholestasis were within the normal range and HCV-RNA was undetectable. At this point, the PLT count dropped to 11,000/mm³, causing ecchymoses at the sites of insulin injection. The finding of an anti-nuclear antibody (ANA) titer of 1:320 (immunofluorescence pattern not reported) led the caregivers to add on prednisone monotherapy 50 mg/day during the first month of antiviral therapy. Serum HCV-RNA remained undetectable, ALT progressively fell to normal values, and PLTs rose to 210,000/mm³. Prednisone monotherapy was tapered down during the remaining weeks of antiviral therapy. Two weeks after completion of antiviral therapy when prednisone was dosed at 2.5 mg/day, ALT broke through to 250 U/L whereas HCV-RNA remained undetectable and the PLT count fell to 65,000/mm³, a finding that caused prednisone monotherapy to be adjusted to 25 mg/day and led the patient to be referred to our center with a suspected diagnosis of AIH.

On physical examination, the patient showed no hepatosplenomegaly or skin ecchymoses. Serum markers of viral hepatitis, including hepatitis A virus immunoglobulin M (IgM), hepatitis B surface antigen, total hepatitis B core antibody, HCV-RNA, hepatitis E virus IgM, herpes simplex DNA, cytomegalovirus IgM, and Epstein-Barr virus DNA all tested negative; however, serum ANA was 1:80 speckled and the level of peripheral

anti-neutrophil cytoplasmic antibodies (p-ANCA) was strongly positive (Fig. 1). Anti-mitochondrial antibodies, anti-smooth muscle antibodies, and anti-liver/kidney microsome antibodies were negative. Gamma globulin levels were normal (16%), the PLT count was 135,000 /mm³, and the ALT value was 65 U/L. Liver biopsy demonstrated the presence of plasma cells clustering in areas of piecemeal necrosis, which along with an AIH score of 22 was strongly suggestive of AIH (Fig. 2).⁽³⁾ One year after completion of LDV/SOF therapy, the patient was still on 7.5 mg prednisone monotherapy, serum HCV-RNA remained undetectable, and the ALT and PLT count were within the normal range (Fig. 3).

Discussion

Liver injury following exposure to medications, herbs, or other toxic substances stands as one of the most common causes of acute liver damage, yet a differential diagnosis between a drug-induced liver injury (DILI) and an AIH is almost impossible to obtain in many patients.⁽⁴⁾ Differential diagnosis between those conditions is in fact often clouded by the appearance of immunologic markers, such as serum tissue autoantibodies and elevated immunoglobulin G levels, and overlapping histologic patterns of liver injury, particularly in patients with idiosyncratic DILI.⁽³⁾ Several lines of evidence indicate that AIH develops as a consequence of a loss of liver capacity for immune tolerance, an event that allows for an interaction between the liver, drugs, and antigens derived from the gut^(5,6) and ultimately leads to chronic inflammation of the liver. One teaching example of this⁽⁷⁾ is patients with tuberculosis exposed to isoniazid who suffer a transient increase of liver enzymes followed by spontaneous recovery despite continued dosing with the offending drug. While this condition is considered a clinical

ARTICLE INFORMATION:

From the ¹Liver Unit and Center for Autoimmune Liver Diseases; ²Clinical Investigation Laboratory; ³Nephrology and Dialysis Unit; ⁴Department of Pathology, Humanitas Clinical and Research Center, Rozzano, Italy; ⁵Liver Unit and Department of Biomedical Sciences, Humanitas University, Rozzano, Italy

ADDRESS CORRESPONDENCE AND REPRINT REQUESTS TO:

Giovanni Covini, M.D.
Liver Unit and Center for Autoimmune Liver Diseases
Via Manzoni, 56

Rozzano, 20089, Italy
E-mail: giovanni.covini@humanitas.it
Tel.: +39-02-8224-4541

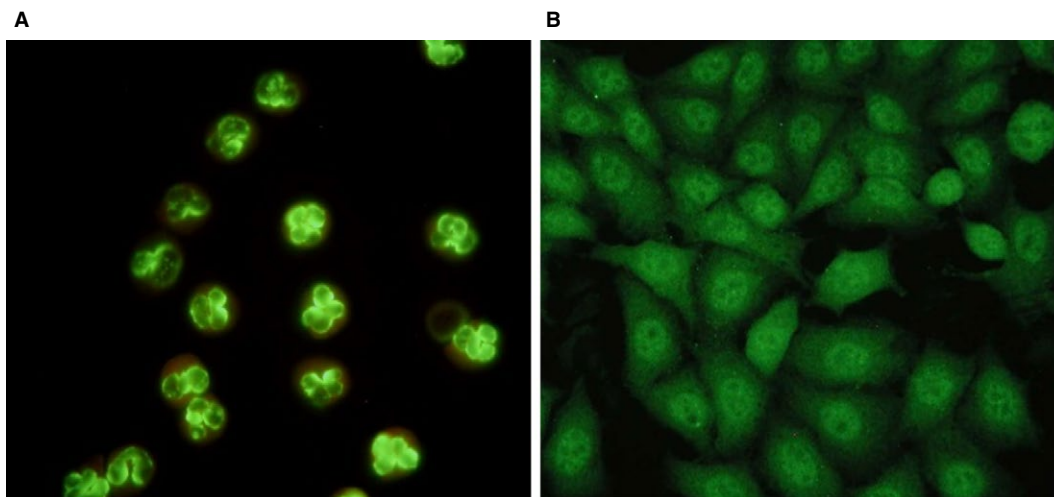


FIG. 1. Neutrophils and HEp-2 cells stained by indirect immunofluorescence with patient serum. (A) Patient serum tested strongly positive for p-ANCA (titer >1:320). (B) Patient serum tested weakly ANA positive (titer 1:80), showing a fine granular staining of nuclei.

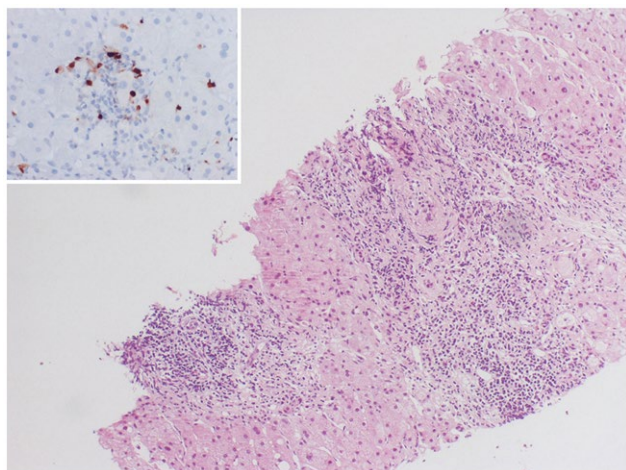


FIG. 2. The liver biopsy is characterized by a moderate to marked portal chronic inflammatory infiltrate with continuous interface hepatitis (hematoxylin and eosin, magnification $\times 10$). The inset (multiple myeloma oncogene 1/interferon regulatory factor 4 immunostaining, magnification $\times 40$) highlights the presence of plasma cells depicted in a cluster in a portal space and as scattered elements spilling over the parenchyma.

adaptation reflecting the development of immune tolerance against isoniazid, some patients may mount a “defective adaptation” to the drug regimen, leading to development of a liver injury with continued exposure to the offending drug.⁽⁸⁾ Although this is particularly true in patients with idiosyncratic DILI who develop

unpredictable, non-dose-related liver injury,⁽⁹⁾ it is worth mentioning that medications, such as oxyphenisatin, statin, nitrofurantoin, minocycline, chlometacin, and alpha-methyl-dopa, may trigger a liver injury that persists after drug discontinuation, suggesting that liver disease is caused by a true autoimmune reaction.^(10,11)

Characteristically, infection with HCV may trigger a variety of immune reactions, including onset of non-organ-specific autoantibodies, cryoglobulins, autoimmune dysthyroidism, arthralgias, myalgias, and lichen planus.⁽¹²⁾ Such a link between HCV and immune reactions has been a reason for deferring therapy with interferon of patients at risk of exacerbating a latent autoimmune disorder; this barrier has recently been lifted following the arrival of DAAs, which offered the opportunity to safely treat patients infected with HCV who present with various autoimmune phenomena.^(13–16) Recently, a multidisciplinary consensus and evidence-based recommendations on the management of HCV extrahepatic manifestations have been proposed that suggest considering DAA as first-line treatment for HCV-mixed cryoglobulinemia.⁽¹³⁾ Furthermore, many reported cases suggest that HCV eradication is often associated with the improvement of lichen planus,⁽¹⁷⁾ another HCV-associated immunologic condition. The impact of DAA on other rheumatologic manifestations, such as Sjögren’s syndrome and arthralgia/myalgia, is lacking. Few reports show a DAA treatment for patients with HCV and autoimmune liver diseases. Interestingly, Sugiura et al.⁽¹⁸⁾

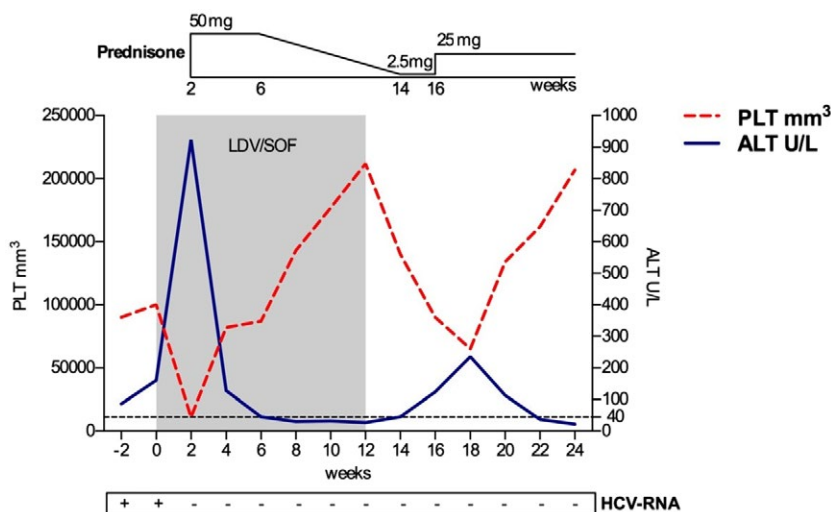


FIG. 3. ALT levels and PLT count during 12 weeks of LDV/SOF therapy and 12 weeks of follow-up. At the end of week 2 of LDV/SOF, ALT flared to 923 U/L, PLT count decreased to 11,000/mm³, and HCV-RNA was undetectable. Following addition of prednisone 50 mg/day, ALT progressively normalized and HCV-RNA remained undetectable. Two weeks after completion of antiviral therapy as prednisone was down-dosed to 2.5 mg/day, ALT broke through to 250 U/L and PLT count decreased to 65,000 /mm³, requiring prednisone to be adjusted to 25 mg/day. Eight months from antiviral therapy cessation, ALT was normal and HCV-RNA was undetectable while the patient was still being dosed with 7.5 mg prednisone daily.

achieved a sustained virologic response (SVR) in a patient affected by HCV-AIH overlap syndrome. In this scenario, DAA seems to be a safe and effective treatment in patients with HCV and immunologic disorders. However, some evidence suggests alterations of immune status are DAA induced. Kanda et al.⁽²⁾ treated 5 patients with HCV plus primary biliary cholangitis and 7 patients with HCV-AIH overlap syndrome and achieved a 100% rate of SVR. Of the 7 patients with HCV-AIH overlap syndrome, 3 received prednisone at baseline and 3 did not receive prednisone during DAA therapy; in 1 female patient with HCV-AIH overlap syndrome plus cirrhosis who was treated with LDV/SOF, prednisone was not administered at baseline but was given after 8 weeks of liver chemistry abnormalities. Kanda et al. concluded that, in this category of patients, clinicians should pay special attention to acute exacerbation of liver diseases. Another example of immune imbalance induced by DAA therapy of HCV is the unexpected high rate of *de novo* or recurrent hepatocellular carcinoma (HCC) that has been reported in patients with HCV after DAA therapy^(19,20) despite the co-occurrence of such relevant confounding factors as heterogeneity of follow-up, starting point of analysis, time lag between DAA initiation and HCC onset, and modalities of cancer therapy. To reconcile the anti-HCV activity of DAAs with their potential

to stimulate host immunity, it has been suggested that rapid elimination of HCV might favor a dysregulation of immune surveillance through a variety of mechanisms,⁽²¹⁻²³⁾ with some evidence that HCC might preferentially develop in patients whose immune backgrounds are already affected prior to DAA exposure.

Considering that before DAA administration, the patient in this case report had persistently normal values of serum aminotransferases during 15 years of surveillance at biannual intervals, the onset of acute hepatitis 2 weeks after starting treatment with LDV/SOF when HCV-RNA tested negative points to drug-induced AIH as a culprit. Furthermore, even if serum autoantibodies were not tested before LDV/SOF therapy for HCV, baseline liver biopsy and blood tests ruled against the coexistence of chronic hepatitis C with AIH. On the other hand, the fact that our patient developed a concurrent ITP is consistent with AIH being frequently associated with extrahepatic autoimmune disorders, such as rheumatoid arthritis, Sjögren's syndrome, and chronic thyroiditis. The association of ITP with AIH has been reported at a prevalence of around 2%,⁽²⁴⁾ whereas it is a well-documented complication of HCV infection, ranging from 3% to 20% depending on the geographic area.⁽²⁵⁾ While the true origin of thrombocytopenia seen in our patient remains elusive, i.e., autoimmune-associated versus

virus-associated ITP,⁽²⁵⁾ we outline that its presence stands as a marker of autoimmunity that may herald development of autoimmune disease following a DAA-driven imbalance of the immune system.

Although firm experimental evidence supporting a link between rapid HCV clearance and *de novo* autoimmune diseases is still lacking, the patient described here with chronic hepatitis C associated with ITP might well represent a candidate predisposed to develop AIH with rapid suppression of HCV with DAA therapy. This case report further emphasizes the need for patients with either laboratory or clinical signs of autoimmunity to be carefully monitored for the risk of developing AIH during DAA therapy of HCV.

REFERENCES

- Castiella A, Zapata E, Lucena MI, Andrade RJ. Drug-induced autoimmune liver disease: a diagnostic dilemma of an increasingly reported disease. *World J Hepatol* 2014;6:160-168.
- Kanda T, Yasui S, Nakamura M, Nakamoto S, Takahashi K, Wu S, et al. Interferon-free treatment for patients with chronic hepatitis C and autoimmune liver disease: higher SVR rates with special precautions for deterioration of autoimmune hepatitis. *Oncotarget* 2018;9:11631-11637.
- Alvarez F, Berg PA, Bianchi FB, Bianchi L, Burroughs AK, Cancado EL, et al. International autoimmune hepatitis group report: review of criteria for diagnosis of autoimmune hepatitis. *J Hepatol* 1999;31:929-938.
- Kullak-Ublick GA, Andrade RJ, Merz M, End P, Benesic A, Gerbes AL, et al. Drug-induced liver injury: recent advances in diagnosis and risk assessment. *Gut* 2017;66:1154-1164.
- Knolle PA, Gerken G. Local control of the immune response in the liver. *Immunol Rev* 2000;174:21-34.
- Williams GM, Iatropoulos MJ. Alteration of liver cell function and proliferation: differentiation between adaptation and toxicity. *Toxicol Pathol* 2002;30:41-53.
- Mitchell JR, Long MW, Thorgeirsson UP, Jollow DJ. Acetylation rates and monthly liver function tests during one year of isoniazid preventive therapy. *Chest* 1975;68:181-190.
- Watkins PB. Idiosyncratic liver injury: challenges and approaches. *Toxicol Pathol* 2005;33:1-5.
- Chalasani NP, Hayashi PH, Bonkovsky HL, Navarro VJ, Lee WM, Fontana RJ. Practice Parameters Committee of the American College of Gastroenterology. ACG Clinical Guideline: the diagnosis and management of idiosyncratic drug-induced liver injury. *Am J Gastroenterol* 2014;109:950-966.
- Alla V, Abraham J, Siddiqui J, Raina D, Wu GY, Chalasani NP, et al. Autoimmune hepatitis triggered by statins. *J Clin Gastroenterol* 2006;40:757-761.
- Bjornsson E, Talwalkar J, Treeprasertsuk S, Kamath PS, Takahashi N, Sanderson S, et al. Drug-induced autoimmune hepatitis: clinical characteristics and prognosis. *HEPATOLOGY* 2010;51:2040-2048.
- Zignego AL, Ferri C, Pileri SA, Caini P, Bianchi FB. Italian Association of the Study of Liver Commission on Extrahepatic Manifestations of HCV infection. Extrahepatic manifestations of hepatitis C virus infection: a general overview and guidelines for a clinical approach. *Dig Liver Dis* 2007;39:2-17.
- Saadoun D, Thibault V, Si Ahmed SN, Alric L, Mallet M, Guillaud C, et al. Sofosbuvir plus ribavirin for hepatitis C virus-associated cryoglobulinaemia vasculitis: VASCUVALDIC study. *Ann Rheum Dis* 2016;75:1777-1782.
- Ramos-Casals M, Zignego AL, Ferri C, Brito-Zeron P, Retamozo S, Casato M, et al. International Study Group of Extrahepatic Manifestations related to HCV (ISG-EHCV). Evidence-based recommendations on the management of extrahepatic manifestations of chronic hepatitis C virus infection. *J Hepatol* 2017;66:1282-1299.
- Sise ME, Bloom AK, Wisocky J, Lin MV, Gustafson JL, Lundquist AL, et al. Treatment of hepatitis C virus-associated mixed cryoglobulinemia with direct-acting antiviral agents. *HEPATOLOGY* 2016;63:408-417.
- Graggiani L, Visentini M, Fognani E, Urraro T, De Santis A, Petracca L, et al. Prospective study of guideline-tailored therapy with direct-acting antivirals for hepatitis C virus-associated mixed cryoglobulinemia. *HEPATOLOGY* 2016;64:1473-1482.
- Ansari U, Henderson LI, Stott G, Parr K. Treatment with ledipasvir-sofosbuvir for hepatitis C resulting in improvement of lichen planus. *JAAD Case Rep* 2017;3:67-69.
- Sugiura A, Wada S, Mori H, Kimura T, Matsuda Y, Tanaka N, et al. Successful treatment for chronic hepatitis C-autoimmune hepatitis overlap syndrome due to daclatasvir and asunaprevir. *Case Rep Gastroenterol* 2017;11:305-311.
- Reig M, Marino Z, Perello C, Inarrairaegui M, Ribeiro A, Lens S, et al. Unexpected high rate of early tumor recurrence in patients with HCV-related HCC undergoing interferon-free therapy. *J Hepatol* 2016;65:719-726.
- Conti F, Buonfiglioli F, Scuteri A, Crespi C, Bolondi L, Caraceni P, et al. Early occurrence and recurrence of hepatocellular carcinoma in HCV-related cirrhosis treated with direct-acting antivirals. *J Hepatol* 2016;65:727-733.
- Tatsumi T, Takehara T. Impact of natural killer cells on chronic hepatitis C and hepatocellular carcinoma. *Hepatol Res* 2016;46:416-422.
- Grandhe S, Frenette CT. Occurrence and recurrence of hepatocellular carcinoma after successful direct-acting antiviral therapy for patients with chronic hepatitis C virus infection. *Gastroenterol Hepatol (N Y)* 2017;13:421-425.
- Debes JD, van Tilborg M, Groothuisink ZMA, Hansen BE, Schulze Zur Wiesch J, et al. Levels of cytokines in serum associate with development of hepatocellular carcinoma in patients with HCV infection treated with direct-acting antivirals. *Gastroenterology* 2018;154:515-517.e3.
- Omagari K, Kinoshita H, Kato Y, Nakata K, Kanematsu T, Kusumoto Y, et al. Clinical features of 89 patients with autoimmune hepatitis in Nagasaki Prefecture, Japan. *J Gastroenterol* 1999;34:221-226.
- Liebman HA, Stasi R. Secondary immune thrombocytopenic purpura. *Curr Opin Hematol* 2007;14:557-573.

Author names in bold designate shared co-first authorship.