



Case report

Ocular adnexal lymphoma: Five case reports and a literature review



Chui-Lien Tsen^a, Muh-Chiou Lin^{a,*}, Youn-Shen Bee^a, Jiunn-Liang Chen^a, Ni-Wen Kuo^a, Shwu-Jiuan Sheu^{a,b}

^a Department of Ophthalmology, Kaohsiung Veterans General Hospital, Kaohsiung, Taiwan

^b School of Medicine, National Yang-Ming University, Taipei, Taiwan

ARTICLE INFO

Article history:

Received 8 January 2014

Received in revised form

15 May 2014

Accepted 20 May 2014

Available online 1 August 2014

Keywords:

extranodal B-cell lymphoma
mucosa associated lymphoid tissue
lymphoma
ocular adnexal lymphoma
ocular manifestations

ABSTRACT

This article reports the clinical course and treatment of ocular adnexal lymphoma based on a retrospective review of five cases with a histologically approved ocular adnexal lymphoma at Kaohsiung Veterans General Hospital over 10 years. Extranodal B-cell lymphoma in the orbit, lacrimal gland, eyelid, or conjunctiva was found in these patients. Four of them were female, and they were aged 45–64 years. All patients were also consulted with hematologists for possible systemic involvement and therapeutic plan. The patient with retrobulbar and orbital apex involvement received systemic chemotherapy. The patient with lacrimal gland involvement experienced tumor recurrence after local excision, and therefore received adjuvant radiotherapy. The remaining three patients had localized lymphoma on the eyelid or bulbar conjunctiva, and they all showed no recurrence after surgical excision. The incidence of ocular adnexal lymphoma has risen worldwide over the last few decades. Although most cases are confined to ocular adnexal, some may also be associated with disseminated lymphoma. Accurate diagnosis and staging is mandatory for appropriate treatment. Generally speaking, localized and low-grade ocular adnexal lymphoma involved eyelid or conjunctiva seem to have good outcome after surgical excision only. Systemic chemotherapy should be considered in patients with advanced disease or systemic manifestations, and radiotherapy also offers a good choice for lacrimal gland lymphoma.

Copyright © 2014, The Ophthalmologic Society of Taiwan. Published by Elsevier Taiwan LLC. All rights reserved.

1. Introduction

Lymphoma of the ocular adnexa is a heterogeneous group of malignancies, accounting for approximately 1–2% of non-Hodgkin lymphomas and 8% of extranodal lymphomas.¹ In the recent past, there have been significant advances in our understanding of the clinical characteristics, morphology and phenotype, etiology, pathogenesis, diagnosis, natural history, treatment approaches, outcome, and prognostic factors of this disease entity.

Ocular adnexal lymphomas are mostly seen in the 5th to 7th decade of life with female predominance. The most frequently involved site is the orbit (40%), followed by conjunctiva (35–40%), lacrimal gland (10–15%), and eyelid (10%).² A large majority of reported cases correspond to the B-cell type, low-grade type and

localized disease (Stage I). Five cases of extranodal B-cell lymphoma involved in different part of ocular adnexa are reviewed in this article.

2. Case reports

2.1. Case 1

A 49-year-old man presented with right proptosis with decreased vision (VA: OD: CF/20 cm; OS: 6/5), limited eye movement and afferent pupillary defect in the right eye (Fig. 1A). Orbital magnetic resonance imaging revealed prominent retrobulbar mass involving apical region in the right orbit (Fig. 1B and C). Orbitotomy was performed and the histologic features of inferior orbital tissue demonstrated high-grade extranodal marginal zone B-cell lymphoma. Neither laboratory analysis nor image study showed evidence of systemic involvement (Stage IE). After discussion with hematologists, a combination regimen of chemotherapy (cyclophosphamide, epirubicin, vincristine, and prednisone) was applied. His symptoms improved significantly without complications in the following 5 years (Fig. 1D).

Conflicts of interest: The authors do not have any financial conflicts or interests in the subject matter in the manuscript, and do not have any commercial or propriety interests in any products or companies.

* Corresponding author. Department of Ophthalmology, Kaohsiung Veterans General Hospital, 386, Ta-Chung 1st Road, Kaohsiung 813, Taiwan, ROC.

E-mail address: chiouoph@gmail.com (M.-C. Lin).

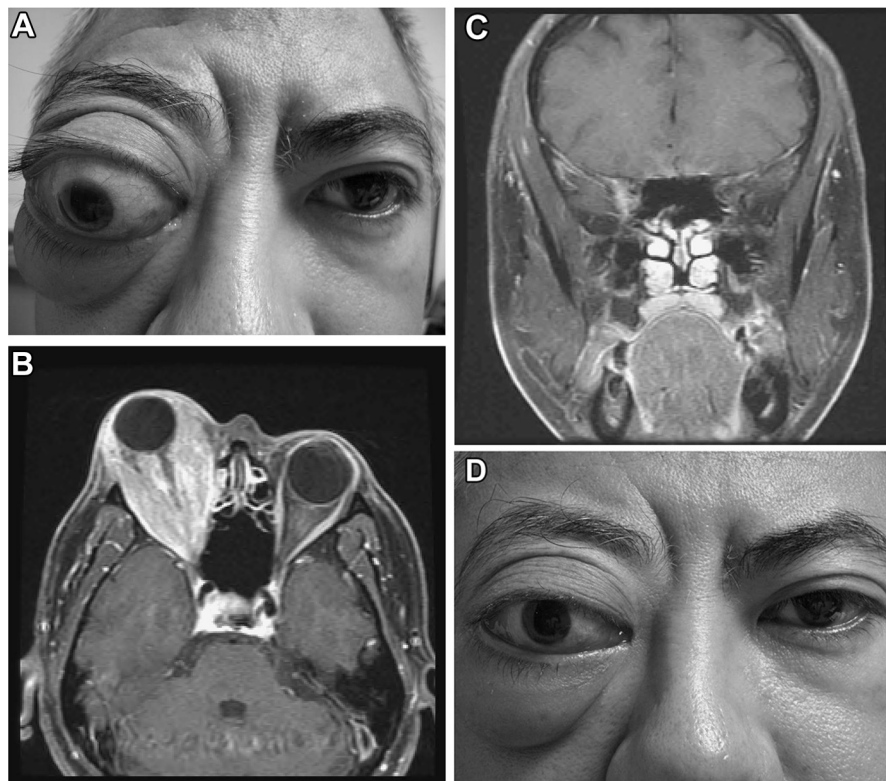


Fig. 1. (A) Case 1: severe exophthalmos, congestion and limited eye movement of the right eye was noted. (B,C) Orbital magnetic resonance imaging showed prominent retrobulbar mass involving apical region in the right orbit causing marked exophthalmos. (D) Case 1 after combination regimens of chemotherapy.

2.2. Case 2

A 64-year-old woman was referred to our hospital due to right eyelid swelling and drooping for 1 month. Ophthalmological examination revealed excellent visual acuity (6/6 in both eyes); the anterior segment and fundi showed normal appearance. However, a mass measuring 1.5 cm × 1.0 cm was palpable in the right upper lid (Fig. 2A). Right lacrimal gland tumor was noted from head and neck computed tomography (CT; Fig. 2B). Based on the CT scan finding, excisional biopsy was performed, and the pathology revealed low-grade, extranodal marginal zone B-cell lymphomas of mucosa-associated lymphoid tissue (MALT). The hematologist suggested observation and follow-up. However, recurrent lid swelling with proptosis was noted 6 months later. Recurrent lymphoma with involvement of the right lacrimal gland (Fig. 2C), right parotid gland, pretracheal region, cervical, and mediastinal nodes were found on CT scan (Stage II E). Since this was a low-grade lymphoma, debulking of lacrimal gland tumor through right anterior orbitotomy was performed. The patient also underwent adjuvant radiotherapy to the residual tumor with 36 Gy in 18 fractions. There was no local recurrence in the following 6 months, and systemic chemotherapy will be considered if high-grade transformation of lymphoma occurs.

2.3. Case 3

A 62-year-old woman noted left lower lid palpable mass for 6 months (Fig. 3). She denied systemic disease or trauma history. The ocular examinations showed normal anterior segment and fundi. The result of excisional biopsy demonstrated low-grade, extranodal marginal zone B-cell lymphomas of MALT. Laboratory data showed

normal blood profile, liver panel, and renal function. CT of head, neck, and whole abdomen showed no evidence of systemic lymphoma (Stage IE). The postoperative condition was stable without tumor recurrence in the following 6 months.

2.4. Cases 4 and 5

Two 45-year-old female patients presented with orange-red, painless, and progressively enlarging masses over nasal bulbar conjunctiva of the left eyes (Fig. 4A). The past medical history was uneventful and particularly no B-symptoms were reported. The ocular examinations were normal except for the conjunctival masses. Both patients underwent excisional biopsy and the histology also showed low-grade, extranodal marginal zone B-cell lymphomas of MALT. Neither laboratory survey nor image study showed evidence of systemic involvement (stage IE). The conjunctival wounds healed well without tumor recurrence after 1-year follow up postoperatively (Fig. 4B).

3. Discussion

Most ocular adnexal lymphomas are primary extranodal neoplasms. However, about 10–32% of patients have secondary tumors with systemic lymphoma.^{3,4} The most common subtype is extranodal marginal zone lymphoma of MALT (35–80%), followed by follicular lymphoma (20%), diffuse large B-cell lymphoma (8%), and less commonly mantle cell lymphoma, small lymphocytic lymphoma, and lymphoplasmacytic lymphoma.^{3,5} The initial evaluation of these patients requires careful ophthalmic examination and adequate tissue sampling for histopathological diagnosis. Further assessments for accurate staging and therapeutic planning include

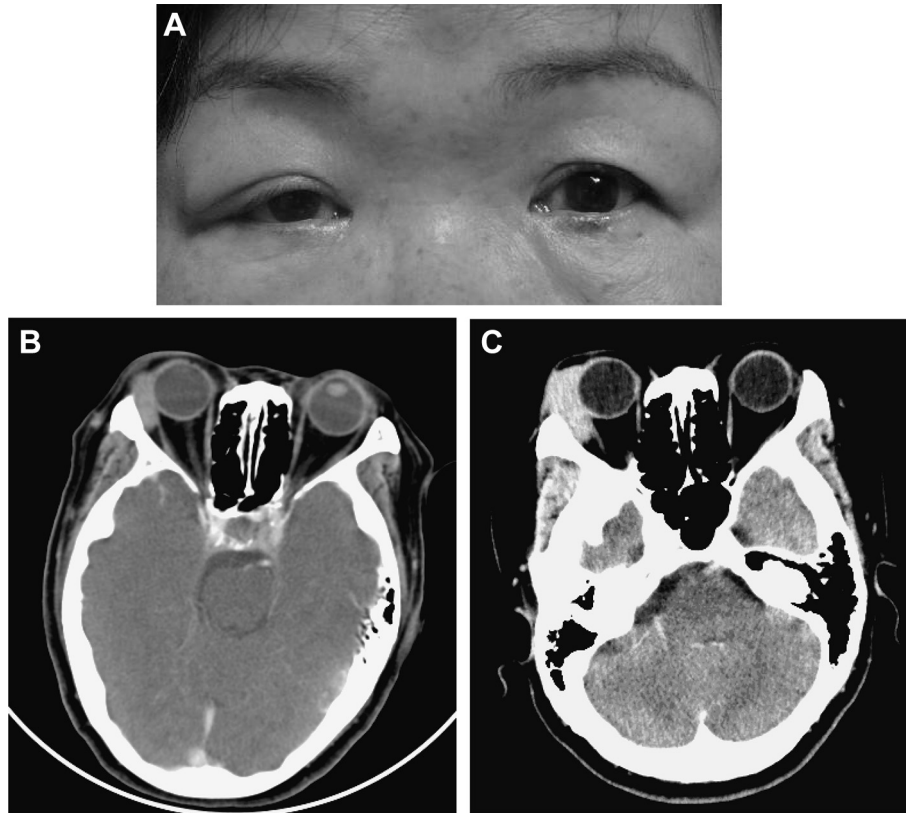


Fig. 2. (A) Case 2 at first visit: right upper lid swelling with a palpable mass. (B) Head and neck computed tomography demonstrated a right lacrimal gland tumor. (C) The follow-up computed tomography scan showed recurrent lymphoma involving the right lacrimal gland 6 months later.

thoughtful history taking and physical examination, laboratory studies, serum protein electrophoresis, serum LDH, β 2-microglobulin, chest x-ray, bone marrow biopsy, CT of chest, abdomen, and pelvis. Unfavorable prognostic features include advanced stage,⁶ old age, nodal involvement,⁷ B symptoms (fever, night sweats, and weight loss),⁸ performance status > 1 , elevated serum LDH or β 2-microglobulin levels,⁹ and p53 gene expression.¹⁰

The treatment modalities for the patients with ocular adnexal lymphoma include surgical resection, radiotherapy, single-agent or combined regimens of chemotherapy, monoclonal anti-CD20 antibody, and interferon immunotherapy.¹¹ Surgical resection is indicated for encapsulated tumors but the risk of recurrence is

relatively high. Radiotherapy for localized MALT lymphoma in the ocular adnexa offers excellent local control with a prolonged clinical course.¹² Systemic chemotherapy should be considered in patients with advanced disease or systemic manifestations. Blasi et al suggested that local immunotherapy with IFN- α seems to be an effective and lasting treatment method and provides an alternative to radiotherapy for conjunctival MALT lymphomas.¹¹

Antibiotic therapy for ocular adnexal lymphoma has also been proposed. Ferreri et al reported that patients with ocular adnexal lymphoma had a high prevalence of *Chlamydia psittaci* infection in both tumor tissue and peripheral blood mononuclear cells.¹³ However, Chanudet et al reported that *C. psittaci* is variably associated with ocular adnexal MALT lymphoma in different geographical regions.¹⁴ Because of the variable prevalence of *C. psittaci* infection in patients with ocular adnexal lymphoma, empiric antibiotic therapy without prior testing cannot be generally recommended.¹⁵

The incidence of ocular adnexal lymphoma, particularly ocular adnexal MALT lymphoma, has risen worldwide over the last few decades. It may present on routine examination or with only mild subjective symptoms. We retrospectively searched our medical record in the last 10 years, and only found these five cases. Four of our cases were low-grade and localized disease, which is comparable with previous reports in the literature. All of our patients were diagnosed by the initial and only presentation of ocular symptoms. Surgical excision alone was performed on Cases 3, 4, and 5, and remained tumor free for 6–12 months, but long-term follow-up is still needed.

In conclusion, no prospective clinical trials have been conducted to define the optimal treatment approach for ocular adnexal lymphoma, and there are no universally accepted therapeutic guidelines. The final treatment decision requires a multidisciplinary approach, taking into account the histopathological type, the extent of the disease, the impact on the eye or visual function, and disease-related

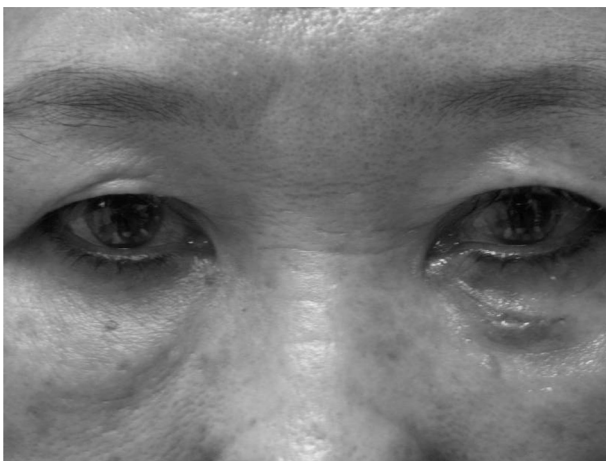

Fig. 3. Case 3: left lower lid mass was noted for 6 months.

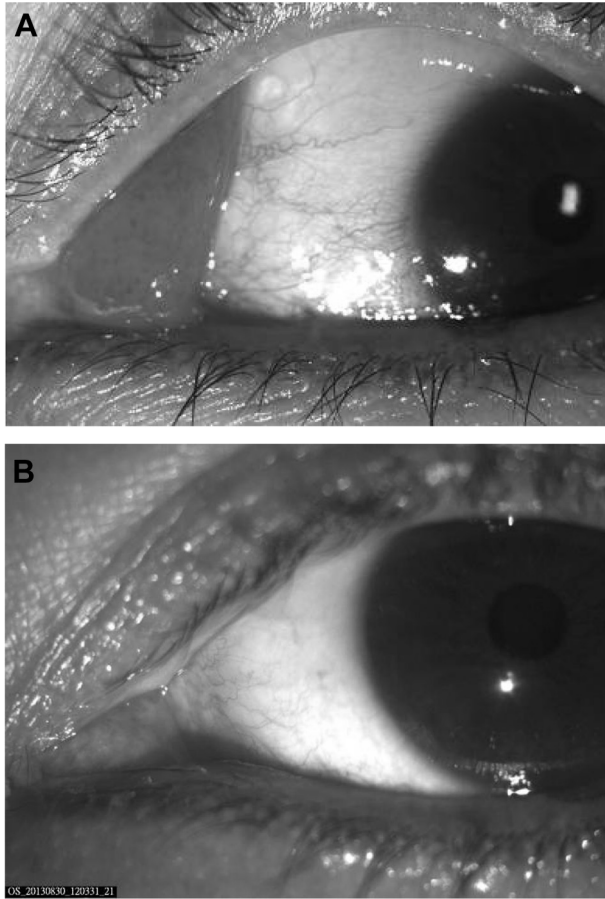


Fig. 4. (A) Case 4: an orange–red, painless mass over nasal bulbar conjunctiva of the left eye. (B) The conjunctival wound healed well without tumor recurrence after surgical excision.

prognostic factors.² Although most cases of ocular adnexal lymphoma were primary extranodal neoplasm, they may also be associated with disseminated lymphoma. Therefore, a rigorous approach to accurate diagnosis and systemic staging is fundamental for optimal treatment planning and outcome. From our limited cases, we observed a trend that the conjunctival and eyelid lymphoma seemed to have better outcome, but the ocular adnexal lymphoma involved orbits or lacrimal gland demands more vigorous treatment. However, this will need larger patients group to confirm.

References

1. Isaacson PG, Wright D. Malignant lymphoma of mucosa-associated lymphoid tissue: a distinctive type of B-cell lymphoma. *Cancer*. 1983;52:1410–1416.
2. Moslehi R, Devesa SS, Schairer C, Fraumeni Jr JF. Rapidly increasing incidence of ocular non-Hodgkin lymphoma. *J Natl Cancer Inst*. 2006;98:936–939.
3. McKelvie PA, McNab A, Francis IC, Fox R, O'Day J. Ocular adnexal lymphoproliferative disease: a series of 73 cases. *Clin Experiment Ophthalmol*. 2001;29:387–393.
4. Coupland SE, Hellmich M, Auw-Haedrich C, Lee WR, Anagnostopoulos I, Stein H. Plasmacellular differentiation in extranodal marginal zone B cell lymphomas of the ocular adnexa: an analysis of the neoplastic plasma cell phenotype and its prognostic significance in 136 cases. *Br J Ophthalmol*. 2005;89:352–359.
5. Jenkins C, Rose GE, Bunce C, Wright JE, Cree IA, Plowman N, et al. Histological features of ocular adnexal lymphoma (REAL classification) and their association with patient morbidity and survival. *Br J Ophthalmol*. 2000;84:907–913.
6. Esik O, Ikeda H, Mukai K, Kaneko A. A retrospective analysis of different modalities for treatment of primary orbital non-Hodgkin's lymphomas. *Radiation Oncol*. 1996;38:13–18.
7. Zucca E, Conconi A, Pedrinis E, Cortelazzo S, Motta T, Gospodarowicz MK, et al. Nongastric marginal zone B-cell lymphoma of mucosa-associated lymphoid tissue. *Blood*. 2003;101:2489–2495.
8. Meunier J, Lumbroso-Le Rouic L, Vincent-Salomon A, Dendale R, Asselain B, Arnaud P, et al. Ophthalmologic and intraocular non-Hodgkin's lymphoma: a large single center study of initial characteristics, natural history, and prognostic factors. *Hematol Oncol*. 2004;22:143–158.
9. Martinet S, Ozsahin M, Belkacemi Y, Landmann C, Poortmans P, Oehlere C, et al. Outcome and prognostic factors in orbital lymphoma: a rare cancer network study on 90 consecutive patients treated with radiotherapy. *Int J Radiat Oncol Biol Phys*. 2003;55:892–898.
10. Coupland SE, Hellmich M, Auw-Haedrich C, Lee WR, Stein H. Prognostic value of cell-cycle markers in ocular adnexal lymphoma: an assessment of 230 cases. *Graefes Arch Clin Exp Ophthalmol*. 2004;42:130–145.
11. Blasi MA, Gherlinzoni F, Calvisi G, Sasso P, Tani M, Cellini M, et al. Local chemotherapy with interferon-alpha for conjunctival mucosa-associated lymphoid tissue lymphoma: a preliminary report. *Ophthalmology*. 2001;108:559–562.
12. Uno T, Isobe K, Shikama N, Nishikawa A, Oguchi M, Ueno N, et al. Radiotherapy for extranodal, marginal zone, B-cell lymphoma of mucosa-associated lymphoid tissue originating in the ocular adnexa: a multiinstitutional, retrospective review of 50 patients. *Cancer*. 2003;98:865–871.
13. Ferreri A, Guidoboni M, Ponzoni M, De Conciliis C, Dell'Oro S, Fleischhauer K, et al. Evidence for an association between *Chlamydia psittaci* and ocular adnexal lymphomas. *J Natl Cancer Inst*. 2004;96:1315–1326.
14. Chanudet E, Zhou Y, Bacon CM, Wotherspoon AC, Müller-Hermelink HK, Adam P, et al. *Chlamydia psittaci* is variably associated with ocular adnexal MALT lymphoma in different geographical regions. *J Pathol*. 2006;209:344–351.
15. Grünberger B, Wöher S, Streubel B, Formanek M, Petkov V, Poespock A, et al. Antibiotic treatment is not effective in patients infected with *Helicobacter pylori* suffering from extragastric MALT lymphoma. *J Clin Oncol*. 2006;24:1370–1375.