

SARS-CoV-2: What is known and what there is to know—Focus on coagulation and lipids

As the SARS-CoV2 pandemic is still progressing, dissemination of information has become of paramount importance. However, the rapid influx of SARS-CoV-2 patients in our hospitals has overwhelmed the time needed for appropriate information interpretation and its application.^{1,2} Noteworthy, awareness among clinicians is growing about the systemic involvement triggered by SARS-CoV-2 infection. Here, we focused on two emerging clinical feature associated with SARS-CoV-2 infection with potential long-term relevance.

Especially, coagulation disorders (in both arterial and venous vascular systems) are emerging as an important issue in SARS-CoV-2 infection. Thrombocytopenia, D-dimer elevation and prolonged prothrombin time already appeared in early reports from China,³⁻⁵ a clinical picture similar to that could be observed in previous SARS-CoV-1 and MERS-CoV-1 pandemics.⁶ Many signs and symptoms of severe SARS-CoV-2 infection are indeed referable to such a fibrinolysis shutdown, which may determine venous thromboembolism (VTE), complement-mediated thrombotic microangiopathies (TMA) and disseminated intravascular coagulation (DIC).^{7,8} Endothelial dysfunction and microvascular thrombosis are the key players in VTE and TMA, and this is true also for SARS-CoV-2 infection. Different vascular cell types may trigger complement cascade activation: cardiomyocytes, endothelial cells macrophages, fibroblast smooth muscle cells and pericytes. Among them, the higher and specific expression of angiotensin-converting enzyme 2 has been found in pericytes, a type of perivascular mural cells that spread outside the endothelium of capillary and part of venules. This suggests that pericytes may trigger complement cascade activation—and then VTE and TMA—as leading SARS-CoV-2 virus targeted host cell.⁹

In parallel, coagulation cascade with thrombin generation is activated by pro-inflammatory cytokines (eg tumour necrosis factor [TNF]- α and interleukin (IL)-1 β and 6), a process known as immunothrombosis or thromboinflammation. However, the boundary between adaptive and defective haemostasis is extremely blurred and highly dependent of how strong the cytokine storm is.⁷ Especially the finding of increased D-dimer levels—a fibrin degradation product used at initial screening for venous thromboembolism

(VTE)—has prompted questions regarding the relationship between SARS-CoV-2 infection and VTE. High prevalence of VTE characterizes patients with SARS-CoV-2 infection and is associated with adverse outcome, mainly due to ventilation-perfusion mismatch secondary to pulmonary embolism (PE).¹⁰⁻¹³ Noteworthy, PE has been found as first sign of SARS-CoV2 infection even in patients with no early evidence of virus at nasal-pharyngeal swab—but later recognized by further swab, serology testing or PCR on bronchoalveolar lavage fluid—¹⁴⁻¹⁶ as also observed in our experience (IRCCS Ospedale Policlinico San Martino, Genoa, Italy). Hospitalized patients should then have coagulation tests performed at admission in order to identify stratify risk in swab-positive patients or even identify those yet 'unrecognized'. Although randomized clinical trials are still missing, there is a general agreement to treat all patients admitted with confirmed or suspected SARS-CoV-2 infection with low-molecular-weight heparin (LMWH) at prophylactic dose.¹⁷ Such treatment has been indeed associated with lower mortality in a pilot study treating 99/499 patients with severe SARS-CoV-2 infection,¹⁸ also due to the intrinsic anti-inflammatory effect of LMWH.^{19,20} Nevertheless, any consideration about a potential increased risk associated with altered coagulation tests still remains speculative and further large studies are needed to identify cut-off values or clinical scores useful for clinical practice. Even D-dimer values are not fully useful to effectively identify PE due their significant baseline elevations. Rather, clinical findings, echocardiographic evidence of right heart strain or lower extremity ultrasound should guide the use of LMWH of unfractionated heparin (UFH) at anti-coagulant dose.¹⁷

In reverse, identification and treatment of TMA still remain a challenge in clinical management of SARS-CoV-2 infection.⁸ Cardiac injury with slight troponin increase,²¹ exudative alveolar damage with massive capillary congestion and microthrombi,²² neurological manifestations,²³ kidney involvement²⁴ and haemolytic anaemia (eg Evans syndrome, autoimmune haemolytic anaemia and immune thrombocytopenic purpura)²⁵⁻²⁸ have been reported worldwide. However, the urgency of pandemic did not allow to characterize such SARS-CoV-2-related TMA. Even

mortality risk associated with such complications cannot be clearly stratified. It is likely that some inherited factors contribute to triggering TMA,²⁹ whereas worse outcome is related to general risk factors as reported for overall SARS-CoV-2-related mortality (eg sex, diabetes, obesity). Newborns and children are particular settings of patients, who seem to have less infection risk and relatively milder clinical symptoms compared to infected adults. Despite rare, coagulation disorders may affect them as expression of a multisystem inflammatory syndrome (eg Kawasaki disease) and then with different pathophysiological features than adults.

UFH and LMWH previously demonstrated limited efficacy for the treatment of sepsis-induced TMA, and no data are still available for of SARS-CoV-2 infection. Instead, clinical improvement has been reported after off-label use of complement inhibitor eculizumab but randomized clinical trials testing this drug and the other C5 inhibitor ravulizumab are needed.^{21,30} These molecules might be considered as an attractive approach to reduce SARS-CoV-2 microthrombosis, lung injury and ultimately improving the outcome. Indeed, after infiltrating the endothelium different players take part as rate-limiting steps in the inflammation-coagulation cascade. Among the other, thrombin, coagulation factor Xa or proteinase-activated receptors (PARs), especially PAR-1, are already

well studied in research and development programmes concerning future treatments in thromboembolic disease.³¹

The link with SARS-CoV-2-related mortality in patients with prior cardiovascular disease represents a more elusive aspect that still deserves to be investigated. Early reports from China provide conflicting results. Although this subset of patients displayed an increased mortality when admitted in the hospital for SARS-CoV-2 infection, the presence of a prior coronary heart disease did not reveal a significant odds ratio (in contrast with D-dimer levels and an older age).⁴ A further study better focusing on lipid profile similarly failed to provide any significant association.³² Especially concerning lipid profile, those results are in contrast with previously reported in patients during seasonal influenza epidemic,³³ or various (bacterial) infections.³⁴ Also, a large pooled data analysis (including data from MRFIT, Framingham, NORA cohorts and other) shows that respiratory disease accounted for 4% of total mortality with an inverse relationship between total cholesterol and noncancer noncardiovascular death, subcategory respiratory diseases death.³⁵ Noteworthy, patients with the Smith-Lemli-Opitz syndrome (characterized by extreme low-cholesterol phenotype) exert a less acting innate system, making them in theory more vulnerable for viral infections.³⁶ To date, no reports exist about

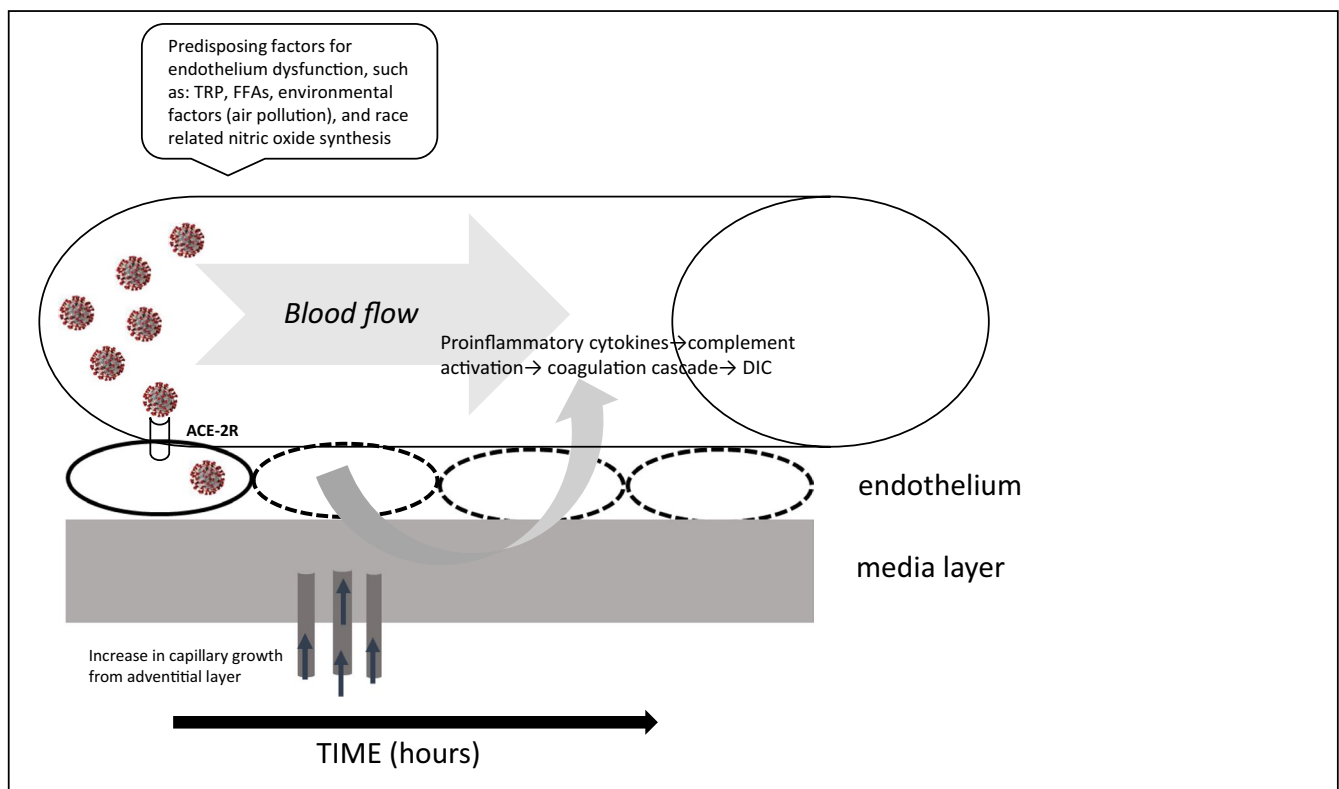


FIGURE 1 Potential mechanisms linking SARS-CoV-2 infection and atherosclerotic plaque development. Complement/coagulation cascade activation triggered by endothelial internalization of SARS-CoV-2 – via angiotensin converting enzyme 2 receptor (ACE-2R) – may have detrimental effects on atherosclerotic plaque stability, especially when combined with other determinants of plaque instability

any relation between SARS-CoV-2 infection outcome and extreme low total cholesterol as occurring in Smith-Lemli-Opitz syndrome or treatment with the extreme effective cholesterol-lowering drugs, such as PCSK-9 inhibitors (ie alirocumab and evolocumab).

At the moment, patients (for instance, those with familial hypercholesterolaemia) who are already treated with a statin, and subsequently present with a symptomatic SARS-CoV-2 infection, are advised not to discontinue their statin therapy.³⁷ This recommendation may be explained by the need to prevent atherosclerotic plaque instability induced by cytokine storm. Anyway, the washout time for a statin will usually take several weeks, while the evolution of SARS-CoV-2 infections during the first three days after admission will predominantly be predictive of its outcome. In addition, there are incoherent data about the protective effect of statins in relation to influenza-associated pneumonia. One should be careful in clinic using some statins—especially simvastatin—in combination with antiviral drugs (Figure 1).

In the pathophysiology of SARS-CoV-2, a generalized infiltration of the endothelium (vasculature) with viral elements is found with a subsequent pronounced local inflammation.³⁸ Theoretically, it could be assumed that predisposing factors could make the endothelium more vulnerable for SARS-CoV-2 infiltration and damage. As reported above, SARS-CoV-2 patients with troponin levels in the higher range (and less favourable outcomes) have higher triglyceride levels and—hypothetically—an overflow of circulating triglycerides with detrimental effect on endothelial biology, especially in the postprandial state. Indeed, triglyceride-rich particles (TRPs), especially when abundant in bloodstream, may induce local inflammation (eg TNF- α and IL-6), activation of complement and coagulation cascade, ultimately promoting endothelial dysfunction.^{39,40} It should be noticed that people living in the Western world eat mostly at least three times a day, and therefore, they could be considered being in a continuous postprandial state. Moreover, in patients who are obese (and those with a diabetes), both VLDL productions by the liver are increased (due to the insulin resistance) and the influx of chylomicrons during the day (postprandial lipemia) will make significantly accumulate TRPs in circulation with an increased paracrine effect on the vasculature.⁴¹ Factors (such as the anaesthetic and etomidate) that could reduce clearance of TRPs from circulation—for instance by lessening of function from key enzymes that play a role in postprandial lipid homeostasis—could therefore give rise to a more aggravated postprandial lipemia. Such a pre-coating of the endothelium by TRPs may therefore lead to a more available endothelium for SARS-CoV-2 virus spread.⁴² Against this background, other prior observations could become important again; SARS-CoV-2 infection gives indeed more complications among

black people (racial disparity), likely due from ethnic-dependent differences in nitric oxide generation and paracrine recovery from oxidative stress.

When acute phase of SARS-CoV-2 infection is considered, a maximal synthesis and secretion of cortisol by the adrenal gland occur. Adrenal uptake of cholesterol is not mediated by the LDL receptor but is mostly Apo-AI SR-BI facilitated. Accordingly, apo-A1 deficiency is characterized by an impaired steroidogenesis.⁴³ Although any relationship between SARS-CoV-2 Apo-A1 levels or SR-BI polymorphisms has been investigated, potential effects on steroidogenesis may have a role in modulating the cytokine storm and then clinical outcome in patients with severe SARS-CoV-2 infection.




In conclusion, clinical implications of the systemic involvement triggered by SARS-CoV-2 infection may be considered the next clinical challenge once lockdown measures will have contained the outbreak shock. As the stress on intensive therapies is easing, there is an increasing need to focus on asymptomatic SARS-CoV-2 infection, which should not be limited to its infectivity but extended to potential unrecognized clinical features and long-term effects/normalization of coagulation and lipid disorders. In this regard, some interesting insight might come from the study of liver function, which has been so far poorly investigated but physiologically involved in lipid and coagulation pathways.⁴⁴

ACKNOWLEDGEMENTS

This study was supported by a grant from the Rete Cardiologica of Italian Ministry of Health (# 2754291) to Prof. F. Montecucco. This study was supported by a grant from Fondazione Carige to Prof. F. Montecucco.

CONFLICT OF INTEREST

None.

Federico Carbone^{1,2} 
Fabrizio Montecucco^{2,3} 
Marcel Twickler⁴ 

¹First Clinic of Internal Medicine, Department of Internal Medicine, University of Genoa, Genoa, Italy

²IRCCS Ospedale Policlinico San Martino Genoa – Italian Cardiovascular Network, Genoa, Italy

³First Clinic of Internal Medicine, Department of Internal Medicine and Centre of Excellence for Biomedical Research (CEBR), University of Genoa, Genoa, Italy

⁴Department of Endocrinology, Diabetology and Metabolic Diseases, Faculty of Medicine and Health Sciences, Deurne/Antwerp University of Antwerp, Antwerp, Belgium

Correspondence

Federico Carbone, First Clinic of Internal Medicine,
Department of Internal Medicine, University of Genoa,
Genoa, Italy.
IRCCS Ospedale Policlinico San Martino Genoa – Italian
Cardiovascular Network, 10 Largo Benzi, 16132 Genoa,
Italy. Address: 6 viale Benedetto XV, 16132 Genoa, Italy.
Email: federico.carbone@unige.it

ORCID

Federico Carbone  <https://orcid.org/0000-0003-2957-4078>

Fabrizio Montecucco  <https://orcid.org/0000-0003-0823-8729>

Marcel Twickler  <https://orcid.org/0000-0001-8738-207X>

REFERENCES

- Ioannidis JPA. Coronavirus disease 2019: the harms of exaggerated information and non-evidence-based measures. *Eur J Clin Invest.* 2020;e13223. [Epub ahead of print].
- Bassetti M, Vena A, Giacobbe DR. The novel Chinese coronavirus (2019-nCoV) infections: challenges for fighting the storm. *Eur J Clin Invest.* 2020;50(3):e13209.
- Chen N, Zhou M, Dong X, et al. Epidemiological and clinical characteristics of 99 cases of 2019 novel coronavirus pneumonia in Wuhan, China: a descriptive study. *Lancet.* 2020;395(10223):507-513.
- Zhou F, Yu T, Du R, et al. Clinical course and risk factors for mortality of adult inpatients with COVID-19 in Wuhan, China: a retrospective cohort study. *Lancet.* 2020;395(10229):1054-1062.
- Guan WJ, Ni ZY, Hu Y, et al. Clinical Characteristics of Coronavirus Disease 2019 in China. *N Engl J Med.* 2020;382(18):1708-1720.
- Giannis D, Ziogas IA, Gianni P. Coagulation disorders in coronavirus infected patients: COVID-19, SARS-CoV-1, MERS-CoV and lessons from the past. *J Clin Virol.* 2020;127:104362.
- Connors JM, Levy JH. COVID-19 and its implications for thrombosis and anticoagulation. *Blood.* 2020;135:2033-2040.
- Gavriilaki E, Brodsky RA. Severe COVID-19 infection and thrombotic microangiopathy: success doesn't come easily. *Br J Haematol.* 2020. [Epub ahead of print].
- Chen L, Li X, Chen M, Feng Y, Xiong C. The ACE2 expression in human heart indicates new potential mechanism of heart injury among patients infected with SARS-CoV-2. *Cardiovasc Res.* 2020;116(6):1097-1100.
- Klok FA, Kruip M, van der Meer NJM, et al. Incidence of thrombotic complications in critically ill ICU patients with COVID-19. *Thromb Res.* 2020;191:145-147.
- Lodigiani C, Iapichino G, Carenzo L, et al. Venous and arterial thromboembolic complications in COVID-19 patients admitted to an academic hospital in Milan, Italy. *Thromb Res.* 2020;191:9-14.
- Klok FA, Kruip M, van der Meer NJM, et al. Confirmation of the high cumulative incidence of thrombotic complications in critically ill ICU patients with COVID-19: an updated analysis. *Thromb Res.* 2020;19:148-150.
- Zhang L, Feng X, Zhang D, et al. Deep vein thrombosis in hospitalized patients with coronavirus disease 2019 (COVID-19) in Wuhan, China: prevalence, risk factors, and outcome. *Circulation.* 2020. [Epub ahead of print].
- Cellina M, Oliva G. Acute pulmonary embolism in a patient with COVID-19 pneumonia. *Diagn Interv Imag.* 2020;101(5):325-326.
- Casey K, Itean A, Nicolini R, Auten J. COVID-19 pneumonia with hemoptysis: acute segmental pulmonary emboli associated with novel coronavirus infection. *Am J Emerg Med.* 2020. [Epub ahead of print].
- Wichmann D, Sperhake JP, Lutgehetmann M, et al. Autopsy findings and venous thromboembolism in patients With COVID-19. *Ann Intern Med.* 2020. [Epub ahead of print].
- Marietta M, Ageno W, Artoni A, et al. COVID-19 and haemostasis: a position paper from Italian Society on Thrombosis and Haemostasis (SISET). *Blood Transfus.* 2020;18(3):167-169.
- Tang N, Bai H, Chen X, Gong J, Li D, Sun Z. Anticoagulant treatment is associated with decreased mortality in severe coronavirus disease 2019 patients with coagulopathy. *J Thromb Haemost.* 2020;18(5):1094-1099.
- Lipowsky HH, Lescanic A. Inhibition of inflammation induced shedding of the endothelial glycocalyx with low molecular weight heparin. *Microvasc Res.* 2017;112:72-78.
- Pan Q, Zhang C, Wu X, Chen Y. Identification of a heparosan heptasaccharide as an effective anti-inflammatory agent by partial desulfation of low molecular weight heparin. *Carbohydr Polym.* 2020;227:115312.
- Campbell CM, Kahwash R. Will complement inhibition be the new target in treating COVID-19 related systemic thrombosis? *Circulation.* 2020;141(22):1739-1741.
- Menter T, Haslbauer JD, Nienhold R, et al. Post-mortem examination of COVID19 patients reveals diffuse alveolar damage with severe capillary congestion and variegated findings of lungs and other organs suggesting vascular dysfunction. *Histopathology.* 2020. [Epub ahead of print].
- Ferrarese C, Silani V, Priori A, et al. Italian multicenter retrospective-prospective observational study on neurological manifestations of COVID-19 (NEUROCOVID). *Neurolo Sci.* 2020;41(6):1355-1359.
- Ronco C, Reis T. Kidney involvement in COVID-19 and rationale for extracorporeal therapies. *Nat Rev Nephrol.* 2020;16(6):308-310.
- Zulfiqar AA, Lorenzo-Villalba N, Hassler P, Andres E. Immune thrombocytopenic purpura in a patient with Covid-19. *N Engl J Med.* 2020;382(18):e43.
- Lopez C, Kim J, Pandey A, Huang T, DeLoughery TG. Simultaneous onset of COVID-19 and autoimmune hemolytic anemia. *Br J Haematol.* 2020. [Epub ahead of print].
- Lazarian G, Quinquenel A, Bellal M, et al. Autoimmune hemolytic anemia associated with Covid-19 infection. *Br J Haematol.* 2020. [Epub ahead of print].
- Li M, Nguyen CB, Yeung Z, Sanchez K, Rosen D, Bushan S. Evans syndrome in a patient with COVID-19. *Br J Haematol.* 2020. [Epub ahead of print].
- Fogarty H, Townsend L, Ni Cheallaigh C, et al. More on COVID-19 coagulopathy in Caucasian patients. *Br J Haematol.* 2020. [Epub ahead of print].
- Diurno F, Numis FG, Porta G, et al. Eculizumab treatment in patients with COVID-19: preliminary results from real life ASL Napoli 2 Nord experience. *Eur Rev Med Pharmacol Sci.* 2020;24(7):4040-4047.

31. Jose RJ, Manuel A. COVID-19 cytokine storm: the interplay between inflammation and coagulation. *Lancet Respir Med*. 2020;8(6):e46-e47.
32. Guo T, Fan Y, Chen M, et al. Cardiovascular Implications of Fatal Outcomes of Patients With Coronavirus Disease 2019 (COVID-19). *JAMA Cardiol*. 2020. [Epub ahead of print].
33. Kwong JC, Schwartz KL, Campitelli MA, et al. Acute Myocardial Infarction after Laboratory-Confirmed Influenza Infection. *N Engl J Med*. 2018;378(4):345-353.
34. Iribarren C, Jacobs DR Jr, Sidney S, Claxton AJ, Feingold KR. Cohort study of serum total cholesterol and in-hospital incidence of infectious diseases. *Epidemiol Infect*. 1998;121(2):335-347.
35. Jacobs D, Blackburn H, Higgins M, et al. Report of the conference on low blood cholesterol: mortality associations. *Circulation*. 1992;86(3):1046-1060.
36. Beby-Defaux A, Maille L, Chabot S, Nassimi A, Oriot D, Agius G. Fatal adenovirus type 7b infection in a child with Smith-Lemli-Opitz syndrome. *J Med Virol*. 2001;65(1):66-69.
37. Banach M, Penson PE, Fras Z, et al. Brief recommendations on the management of adult patients with familial hypercholesterolemia during the COVID-19 pandemic. *Pharmacol Res*. 2020;158:104891.
38. Varga Z, Flammer AJ, Steiger P, et al. Endothelial cell infection and endotheliitis in COVID-19. *Lancet*. 2020;395(10234):1417-1418.
39. Twickler TB, Dallinga-Thie GM, Cohn JS, Chapman MJ. Elevated remnant-like particle cholesterol concentration: a characteristic feature of the atherogenic lipoprotein phenotype. *Circulation*. 2004;109(16):1918-1925.
40. Sullivan DR, Celermajer DS, Le Couteur DG, Lam CW. The vascular implications of post-prandial lipoprotein metabolism. *Clin Biochem Rev*. 2004;25(1):19-30.
41. Leon-Acuna A, Alcalá-Díaz JF, Delgado-Lista J, et al. Hepatic insulin resistance both in prediabetic and diabetic patients determines postprandial lipoprotein metabolism: from the CORDIOPREV study. *Cardiovasc Diabetol*. 2016;15:68.
42. Mantilla-Escalante DC, de Las L, Hazas MC, et al. Postprandial circulating miRNAs in response to a dietary fat challenge. *Nutrients*. 2019;11(6):1326.
43. Vergeer M, Korpelaar SJ, Franssen R, et al. Genetic variant of the scavenger receptor BI in humans. *N Engl J Med*. 2011;364(2):136-145.
44. Alqahtani SA, Schattenberg JM. Liver injury in COVID-19: the current evidence. *United Eur Gastroenterol J*. 2020;8(5):509-519.