

Aortic Cannula Tip Dislodgement: A Rare Complication

Abstract

Cardiac surgery involves use of cardiopulmonary bypass which usually requires a circulatory circuit containing numerous cannulae and tubings draining from major vessels (like superior and inferior vena cavae) and returning it back to the systemic circulation (via the aorta, femoral artery, axillary artery etc). Establishment of this circuit not only requires good surgical skills for technical procedures but also requires stringent vigilance and awareness about the working of these disposable items. Surgeons concentrating in the technical aspect might miss out on the minor manufacturing defects in these disposable items and anesthesiologist as well as perfusionist can contribute in this aspect by including systematic precheck of these items to avoid complications in future. In this case report, we would like to discuss a simple case of mitral valve replacement where during aortic decannulation the metallic tip got dislodged and thus got migrated to the abdominal aorta. This is a rare complication which none of us were expecting. By prechecking the various components of the cardiopulmonary bypass circuit, this complication was expected to be avoided.

Keywords: Aortic cannula, cardiac surgery, dislodgement, tip

Introduction

Aortic cannulation is one of the major steps from both anesthesia and surgical point of view in cardiac surgery and many complications have occurred in the past during this stage which includes tear of the aortic wall, dissection of the aortic wall, bleeding, posterior wall puncture leading to trauma to the oesophagus, and even cardiac arrest. Like cannulation of the aorta, decannulation is also an important step while coming off bypass towards the later stage of surgery. Most of the time, it is bleeding from the aortic cannulation site which is encountered during decannulation. We wish to discuss a rare yet avoidable complication which we never expected to happen.

Case History

A 42-year-old male patient weighing 60 kg with severe mitral stenosis underwent mitral valve replacement on cardiopulmonary bypass after receiving standard general anesthesia. The patient was weaned off successfully from bypass and was hemodynamically stable during this phase. However, while returning the pump blood from the aortic line, there was excessive

bleeding from the site of entry of aortic cannula. Hence, it was decided to remove the aortic cannula. However, to our surprise, while removing the aortic cannulae, the tubing suddenly gave away [Figure 1] and the metallic tip got dislodged inside the aorta. The entire thoracic part of the aorta was checked by palpation but we could not trace the metallic tip. An intraoperative X-ray abdomen was done and to our fear, the metallic tip was in the abdominal aorta at the level of third lumbar vertebra [Figure 2]. Thereafter, under fluoroscopic guidance an attempt was made to extract the cannula tip through femoral route however, the tip being larger in size was not able to negotiate beyond the aortic bifurcation into iliac arteries [Figure 3]. Finally, the patient underwent laparotomy and after locating the cannula tip, in the abdominal aorta, a partial clamp was applied, and the cannula tip was successfully extracted out [Figure 1]. The patient required additional inotropic support (adrenaline and dopamine in titrable dosage) along with 2 units of packed RBCs and 2 units of fresh frozen plasma due to blood loss during the entire procedure. The patient was extubated the next day and the rest of the postoperative stay was uneventful.

This is an open access journal, and articles are distributed under the terms of the Creative Commons Attribution-NonCommercial-ShareAlike 4.0 License, which allows others to remix, tweak, and build upon the work non-commercially, as long as appropriate credit is given and the new creations are licensed under the identical terms.

For reprints contact: reprints@medknow.com

How to cite this article: Gargava A, Sarkar M, Umbarkar S, Shringarpure A. Aortic cannula tip dislodgement: A rare complication. *Ann Card Anaesth* 2020;23:515-7.

**Aseem Gargava^{1,2},
Manjula Sarkar¹,
Sanjeeta Umbarkar¹,
Amruta
Shringarpure¹**

¹Department of Cardiovascular Anaesthesia, Seth G.S. Medical College and K.E.M. Hospital, Mumbai, Maharashtra,

²Department of Anaesthesia and Intensive Care, Maulana Azad Medical College, New Delhi, India

Submitted: 28-Aug-2019

Accepted: 10-Dec-2019

Published: 19-Oct-2020

Address for correspondence:

Dr. Aseem Gargava,
3/2 Shalimar Sterling,
Govindpura, Bhopal,
Madhya Pradesh, India.
E-mail: aseemgargava@gmail.com

Access this article online

Website: www.annals.in

DOI: 10.4103/aca.ACA_122_19

Quick Response Code:



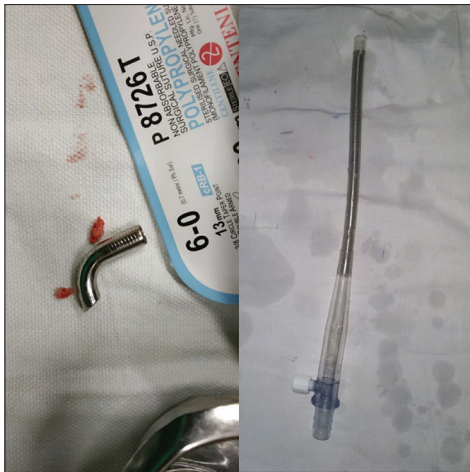


Figure 1: Dislodged metallic aortic cannula tip on the left and leftover aortic cannula tubing on the right

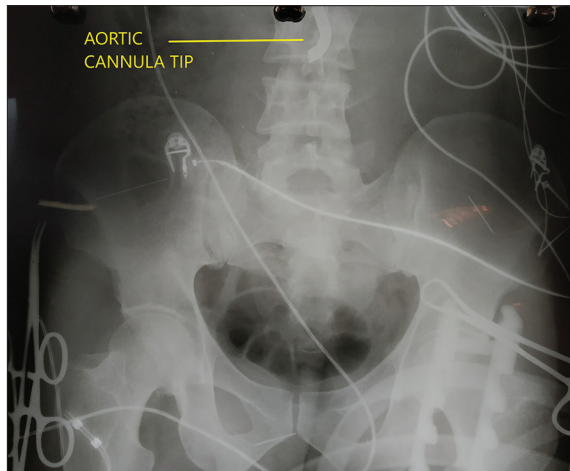

Figure 2: Abdominal X-ray showing dislodged aortic cannula tip at the level of third lumbar vertebra

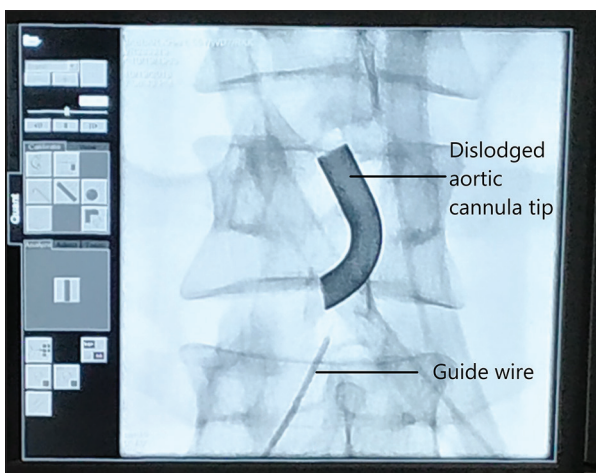


Figure 3: Fluoroscopic image showing guidewire being attempted to pass through the cannula tip

Discussion

It is said that the consequences of mistakes done in prebypass phase can be seen clearly in the postbypass

period. Complications associated with aortic cannulation for the bypass although rare are well versed. These mainly include aortic rupture, dissection, and pseudoaneurysm formation.^[1] A very rarer complication reported is the embolism of the adjustable “position stop” of the aortic cannulae that comes with them.^[2] However, the complication which we mentioned has never happened in the past in our institute. In the English literature also, there is only one such report of disconnection of the tip.^[3]

After looking for reasons and possible ways of avoiding it, we came across various possibilities.

Repeated use of same arterial cannulae after repeated sterilization

Although repeated use of cannulas has never been encouraged it has been seen that even after limited reuse the properties of the cannula are not affected beyond safety limits.^[4] In our case also we used a fresh piece of disposable 20 Fr single-use aortic cannula with curved metallic tip (manufactured by Doctor Surgicals, batch number- 201712156).

Manufacturing defect

The cannula which we were using contained two parts, a flexible body and a metallic tip. The body of the cannula is a wire-reinforced flexible tubing. The tip, on the other hand, is curved metallic and nonflexible. These two are joined with a flange to hold them together. The process of bonding is specific for the manufacturer and type of cannulae and is unknown to us but if this bond between the tip and the body is not tight enough, it might lead to many such complications like the one we faced.

Change in temperature

During cardiopulmonary bypass, the patient is cooled to a relatively low temperature and then rewarmed again. This change in temperature may affect the expansion and contraction of the cannula material which may or may not be significant.^[4] The metallic tip and the cannula tubing are made up of different materials and have a different coefficient of expansion which may lead to differential size change causing loosening of cannula tip from tubings and disconnection of the same. However, looking at the rarity of this event, it is less likely to be the cause for the same.

Pinching effect of snugger tie

At our setup, the surgeons use a heavy silk thread (3-0 or 2-0) or linen to secure the snugger to the aortic cannula. We believe that there may be a pinching effect if this thread is tied close to the junction between the metallic and cannula tubing.^[5] This pinching effect may cause slipping of the tubing from the metallic tip, especially when this tie is opened up during decannulation. Moreover, this step is done in almost all bypass surgeries and if this would have been the cause then this complication would have occurred more often. So probably it may be a contributing factor, if not the cause.

Conclusion

Being an unusual and rare complication, to be honest, we were not prepared for the effective management of such case. Avoidance of major temperature variations does not seem to be an effective and sure shot measure to avoid such incidence and in some situations, it is practically not possible as well. Since many of the contributing factors for the cause may not be modifiable, such possibilities should, therefore, be necessarily kept in mind. We suggest a precheck of all such cannulae as well as other disposable before considering them for use. The implications of even the tiniest defect in these products are serious complications and may add up to the morbidity as well as mortality of the patient. Moreover, even after considering the cost-benefit for reuse of cannulae, one must wherever possible, go for a fresh unused product over the reused ones.

Finally, we would conclude by saying that, as an anesthesiologist, one must be vigilant and careful to rare and such unknown complications.

Declaration of patient consent

The authors certify that they have obtained all appropriate patient consent forms. In the form the patient(s) has/have given his/her/their consent for his/her/their images and

other clinical information to be reported in the journal. The patients understand that their names and initials will not be published and due efforts will be made to conceal their identity, but anonymity cannot be guaranteed.

Financial support and sponsorship

Nil.

Conflicts of interest

There are no conflicts of interest.

References

1. Hayward RH, Korompai FL, Knight WL. Complications of aortic cannulation. *Ann Thorac Surg* 1984;37:440.
2. John L. How to prevent foreign body embolism with adjustable 'position stop' aortic cannulae. *Interact Cardiovasc Thorac Surg* 2005;4:135-6.
3. Scheld HH, Görlach G. Disconnection of the metallic tip of an aortic cannula during cardiopulmonary bypass. *Thorac Cardiovasc Surg* 1985;33:196-7.
4. Bloom DF, Cornhill JF, Malchesky PS, Richardson DM, Bolsen KA, Haire DM, *et al.* Technical and economic feasibility of reusing disposable perfusion cannulas. *J Thorac Cardiovasc Surg* 1997;114:448-60.
5. Singh RS, Singh H, Sharma V, Mahajan S. Disconnect of the tip of the aortic cannula during cardiopulmonary bypass. *Interact Cardiovasc Thorac Surg* 2009;8:250-1.