



Terbutaline-triggered fetal arrhythmia prior to neonatal diagnosis of Wolff-Parkinson-White syndrome: A case report

Maya Gross^a, J. Igor Iruretagoyena^a, Shardha Srinivasan^b, Jennifer Karnowski^a, Jacquelyn Adams^{a,*}

^a University of Wisconsin, Department of Obstetrics and Gynecology, 202 S. Park Street, Madison, WI 53715, United States

^b University of Wisconsin, Department of Pediatrics, 600 Highland Avenue, H6/516E, Madison, WI 53792, United States

ARTICLE INFO

Keywords:

Terbutaline
External cephalic version
Obstetrics
Tachyarrhythmia
Betamimetics

ABSTRACT

Introduction: Short-term maternal administration of betamimetics is a common obstetric practice with uses including tocolysis during antenatal corticosteroid administration for fetal lung maturity, intrapartum tachysystole, and prior to external cephalic version. While previous research has demonstrated adverse effects of prolonged use of maternal betamimetics, no prior documentation exists of fetal tachyarrhythmias beyond sinus tachycardia after administration of terbutaline.

Case: This case documents a transient fetal tachyarrhythmia consistent with presumed atrial flutter after maternal administration of terbutaline for external cephalic version. On day of life 9, the neonate presented in supraventricular tachycardia with signs of heart failure and was subsequently diagnosed with Wolff-Parkinson-White syndrome.

Conclusion: Maternal administration of terbutaline may be associated with transient fetal tachyarrhythmia. In some fetuses, this cardiac arrhythmia may predate diagnosis of an underlying cardiac disorder, warranting close follow-up after delivery.

1. Introduction

Terbutaline has multiple applications within the practice of obstetrics. Historically, it has been used as a tocolytic to inhibit preterm uterine contractions and prevent preterm labor [1,2]. While the US Food and Drug Administration has issued warnings against prolonged use of terbutaline due to potential maternal and fetal adverse effects [3], its short-term use as a tocolytic is endorsed by the American College of Obstetricians and Gynecologists [2,4,5].

Terbutaline exerts inotropic and chronotropic effects on cardiac muscle by activation of beta-1 adrenergic receptors and activates beta-2 adrenergic receptors to relax smooth muscle [6,7]. Maternal and fetal sinus tachycardia have been documented in response to maternal administration of terbutaline [3,8,9]. To the authors' knowledge, a case report of fetal tachycardia with postpartum diagnosis of neonatal ventricular tachycardia observed after maternal exposure to terbutaline is the only existing documentation of a fetal arrhythmia, aside from fetal sinus tachycardia, following maternal administration of terbutaline

[1,8].

This case report documents a transient fetal tachyarrhythmia consistent with presumed atrial flutter (AFL) after routine administration of terbutaline in preparation for external cephalic version (ECV). The fetus had no known cardiac abnormalities and had not previously had any documented issues with fetal heart rate (FHR). After birth, the neonate was diagnosed with Wolff-Parkinson-White syndrome.

2. Case presentation

A 35-year-old woman, G5P0040, presented at 37 weeks and 3 days of gestation for planned ECV for breech presentation. Pregnancy history included three prior first-trimester spontaneous abortions and one prior ectopic pregnancy managed with left salpingectomy. The current pregnancy was complicated by advanced maternal age, maternal anti-phospholipid antibody syndrome and maternal hypothyroidism, treated with enoxaparin, aspirin, and levothyroxine. Thyroid labs, measured monthly during pregnancy, were maintained within normal limits with

* Corresponding author at: 1010 Mound Street, McConnell Hall 4th Floor, Madison, WI 53715, United States.

E-mail addresses: Mgross2@uwhealth.org (M. Gross), iruretagoyen@wisc.edu (J.I. Iruretagoyena), ssrinivasan3@wisc.edu (S. Srinivasan), jkarnowski@wisc.edu (J. Karnowski), Jhadams3@wisc.edu (J. Adams).

<https://doi.org/10.1016/j.crwh.2022.e00382>

Received 13 December 2021; Received in revised form 3 January 2022; Accepted 5 January 2022

Available online 8 January 2022

2214-9112/© 2022 The Authors.

Published by Elsevier B.V. This is an open access article under the CC BY-NC-ND license

(<http://creativecommons.org/licenses/by-nc-nd/4.0/>).

adjustments of levothyroxine per endocrinology. Diagnosis of anti-phospholipid syndrome was established by elevated anticardiolipin antibodies on two occasions <12 weeks apart and history of three spontaneous pregnancy losses prior to 10 weeks of gestation. Growth ultrasounds and antenatal testing were reassuring, with an appropriately grown fetus with an estimated fetal weight of 3126 g (77 percentile) at 36 weeks and 1 day.

Upon presentation for ECV, electronic fetal monitoring (EFM) demonstrated a baseline of 140 beats per minute (BPM), moderate variability, accelerations, and no decelerations. At patient request, spinal anesthetic was administered prior to the procedure. Subcutaneous terbutaline, 25 μ g, was administered prior to the procedure. Maternal vitals after administration of the above medications demonstrated mild tachycardia (max 113 BPM) with regular rhythm lasting 30 min and transient hypotension with nadir 80/40 mmHg managed by anesthesia with phenylephrine with return to normotension (111/68 mmHg). Maternal vitals remained stable throughout the remainder of her care. Ultrasound guidance confirmed breech fetal position and reassuring FHR. After one attempted fetal rotation, bedside ultrasound demonstrated an abnormal, tachycardic FHR at 300 BPM (Fig. 1). External fetal monitoring displayed FHR in the 140 s, inconsistent with the visualized heart rate. Fetal tachyarrhythmia persisted despite maternal repositioning, intravenous fluids, and blood pressure monitoring.

Maternal Fetal Medicine was consulted. FHR was thought to be consistent with possible 2:1 atrial flutter vs. SVT; available images from bedside ultrasound displayed atrial and ventricular rates of 280–300, and atrial rates of 500–600 consistent with 2:1 AFL. Imaging of the atrial rate on M-mode was limited by gestational age and rate. Immediate medical management was deferred due to advanced gestational age and

acute onset. Bedside ultrasound was without obvious congenital cardiac anomalies or signs of hydrops. The FHR converted spontaneously to normal rate and rhythm approximately 4 h after administration of the betamimetic. Continuous fetal monitoring overnight demonstrated reassuring FHR, confirmed intermittently with ultrasound and Doppler. Formal echocardiogram with pediatric cardiology was deferred given spontaneous conversion of rhythm and reassuring screening cardiac views. The patient was discharged home the following day with instructions to continue antenatal testing and regular prenatal visits; the remainder of her prenatal course was without evidence of recurrent fetal tachyarrhythmia.

The patient underwent uncomplicated primary low transverse cesarean delivery at 39 weeks and 3 days for breech presentation. The infant was vigorous at delivery with APGAR scores of 8 and 9. The FHR was within normal limits and vital signs were stable. Neonatal TSH was within normal limits. A newborn EKG obtained prior to discharge demonstrated peaked P waves in lead II, concerning for right atrial enlargement. An echocardiogram performed on day of life (DOL) 2 showed low-normal aortic arch and isthmus dimensions without evidence of obstruction, a mildly dilated ascending aorta, and persistent patent ductus arteriosus (PDA). A repeat echocardiogram was performed on DOL 3, redemonstrating low-normal aortic arch dimensions, without evidence of obstruction, and with interval closure of the PDA. A follow-up echocardiogram at 2–4 weeks after delivery was recommended.

On DOL 9, the newborn patient was brought to her primary care physician due to tachycardia noted by the parents. On presentation, the heart rate was 250 BPM with associated tachypnea; EKG demonstrated SVT with HR up to 297 BPM (Fig. 2). The patient was transferred to the children's emergency department (ED). Upon presentation to the ED, the

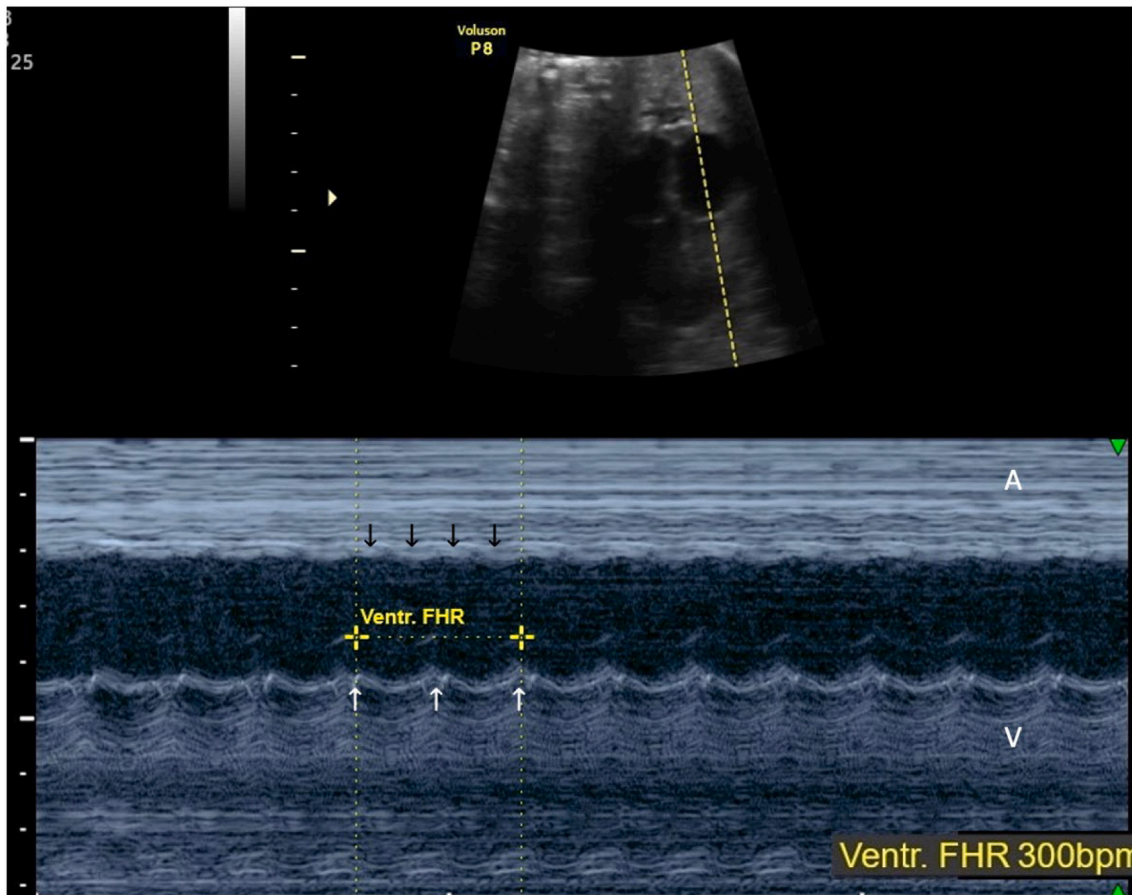


Fig. 1. Fetal tachyarrhythmia following terbutaline administration. White arrows depict ventricular contractions with corresponding rate of 300 BPM. Black arrows depict atrial contractions.

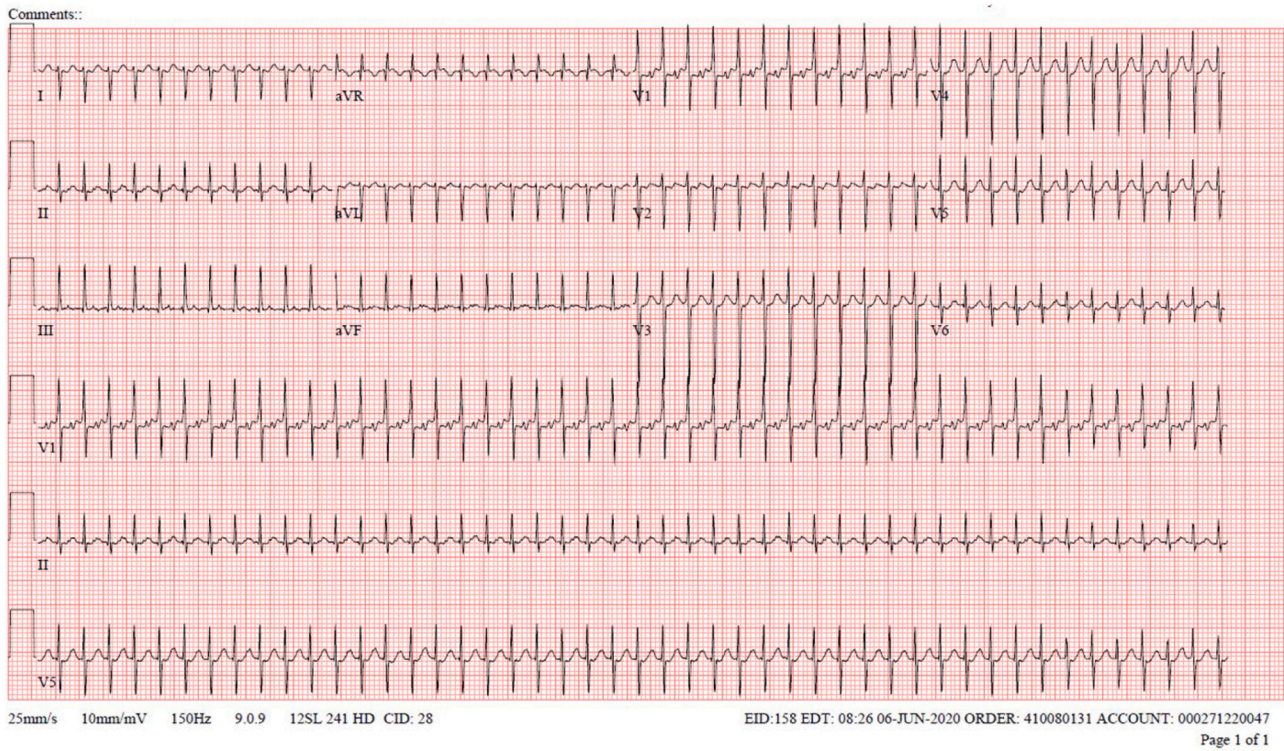


Fig. 2. Initial ECG at presentation: Narrow complex tachycardia consistent with SVT at 280 BPM.

newborn received adenosine and was cardioverted with transient pre-excitation noted upon return of sinus rhythm. She was started on propranolol on admission with no further episodes of tachyarrhythmia.

Follow-up ECG showed preexcitation consistent with a left-sided accessory pathway (Fig. 3), yielding a diagnosis of Wolff-Parkinson-White syndrome. Transient secondary cardiomyopathy with

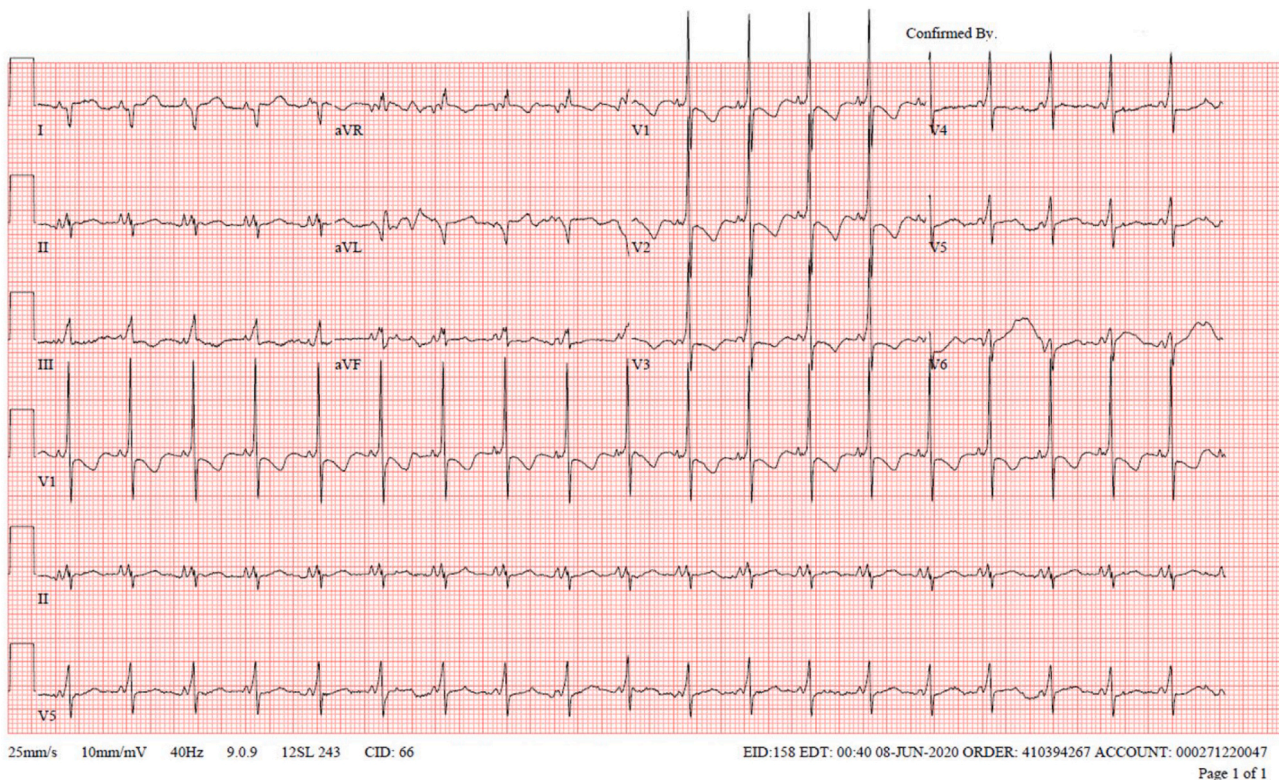


Fig. 3. Follow-up ECG in sinus rhythm showing preexcitation consistent with a left-sided WPW pathway. A positive delta wave is noted in leads V1 to V6 and is negative in leads I and aVL with a short PR segment.

moderately diminished systolic function was noted, but improvement was apparent on repeat imaging the following day. The patient was discharged home on propranolol with a cardiac event monitor.

Upon follow-up at 5 weeks of life, the previously documented tachycardia-mediated cardiomyopathy had resolved. The child was continued on propranolol with dose adjustments for breakthrough episodes of SVT related to increased weight. Repeat EKG at nine months of life demonstrated resolution of preexcitation and sinus bradycardia. Plans per pediatric cardiology included repeat EKG at 21 months of life, with plans to trial off propranolol.

3. Discussion

This case describes a pregnant patient who presented for external cephalic version at 37 weeks of gestation. Her fetus, with a previously normal targeted anatomic survey and cardiac evaluation, developed a tachyarrhythmia shortly after administration of terbutaline, which resolved spontaneously. Additional administered medications including spinal anesthesia are not associated with fetal tachycardia [11]. Neonatal evaluation demonstrated reassuring cardiac status until the neonate presented at DOL 9 with tachyarrhythmia and cardiomyopathy and was diagnosed with Wolff-Parkinson-White syndrome.

Terbutaline is a beta agonist with stimulatory effects on both B1 and B2 receptors [7]. The utility of terbutaline in obstetrics stems from B2 stimulation, leading to relaxation of smooth muscle. Historically, terbutaline and other betamimetics were administered for prolonged periods in the setting of preterm uterine contractions; however, emerging data demonstrates lack of efficacy beyond 48 h with no meaningful prolongation of pregnancy, as well as potential harm [1,2,7]. Current betamimetic use in pregnancy is limited to short-term prenatal administration for tocolysis to allow for steroid administration to aid fetal lung maturity (tocolysis in the steroid window [1–3]), prenatal administration to aid success of ECV [5], and intrapartum administration for maternal tachysystole [4,17].

Adverse maternal effects have been documented, including but not limited to maternal sinus and ventricular tachycardias, atrial fibrillation, pulmonary edema, and maternal SVT [1,3,7,12–15]. Most documented adverse maternal effects occur after prolonged use of betamimetics; ritodrine has been removed from the US market and terbutaline has received an FDA warning against use for greater than 48 h due to concern for maternal cardiac safety and maternal death [3,16].

Limited data exists regarding the potential effects of betamimetics on the fetus or neonate [18–20]. Fetal sinus tachycardia is a known side-effect of betamimetics [1]; the B1 stimulatory effect of terbutaline has been leveraged for management of congenital fetal heartblock [10,18,19]. Review of the literature demonstrates one previous case report of a fetal tachycardia to 190 BPM after maternal administration of terbutaline with subsequent diagnosis of neonatal ventricular tachycardia [8] as well as a case report of congenital atrial flutter and hydrops fetalis following prolonged administration of ritodrine [20]. No other literature exists documenting fetal tachyarrhythmia or discovery of an underlying cardiac disorder after short-term administration of terbutaline.

To the authors' knowledge, this is the first reported case of terbutaline associated with a tachyarrhythmia from underlying fetal Wolff-Parkinson-White or any other cardiac syndrome. This case presents multiple salient learning points. Fetal tachyarrhythmias following administration of terbutaline may resolve spontaneously. If a tachyarrhythmia is noted following maternal administration of terbutaline in a previously healthy fetus without signs of cardiac compromise (hydrops or cardiomyopathy), expectant management may be appropriate. Transient, unexpected fetal tachyarrhythmias following administration of maternal terbutaline may be a harbinger of future neonatal cardiac arrhythmias, begging the question of whether follow-up is needed for neonates who had transient cardiac tachyarrhythmias in utero. If a tachyarrhythmia is persistent, a formal echocardiogram should be

performed by the maternal fetal medicine or pediatric cardiology physician prior to delivery; this may be delayed until the postpartum period in fetuses nearing full term.

Future research may delve into the effects of betamimetics or tocolytics in fetuses with known cardiac conditions or the incidence of diagnosis of neonatal cardiac complications after documentation of fetal tachyarrhythmias with in-utero exposure to betamimetics.

Contributors

Dr. Maya Gross was responsible for acquisition and analysis of data and drafting of the article.

Dr. J. Igor Iruretagoyena was responsible for clinical care, data acquisition and manuscript revision.

Dr. Shardha Srinivasan was responsible for analysis and interpretation of data, article review and expert cardiology opinion.

Dr. Jennifer Karnowski was responsible for analysis of data and manuscript review/revision.

Dr. Jacquelyn Adams was responsible for conception of the study and manuscript preparation and revision.

All authors approved the final version of the manuscript.

Funding

No funding from an external source supported the publication of this case report.

Patient consent

The patient provided written consent for publication of the case, including use of images and inclusion of information obtained from review of the neonate's chart.

Provenance and peer review

This article was not commissioned and was peer reviewed.

Acknowledgements

The authors would like to acknowledge the patient, who provided written consent for this case to be presented.

Conflict of interest statement

The authors declare that they have no conflict of interest regarding the publication of this case report.

References

- [1] S. Anotayanonth, N.V. Subhedar, J.P. Neilson, S. Harigopal, Betamimetics for inhibiting preterm labour (review), *Cochrane Library Cochrane Database Syst. Rev.* (2010), <https://doi.org/10.1002/14651858.CD004352.pub2>. Published online.
- [2] Committee on Practice Bulletins, Obstetrics - in Collaboration with Hyagriv N. Simhan MMS. ACOG Practice Bulletin 171 Management of Preterm Labor. *American College of Obstetricians And Gynecologists*, Published online. Accessed August 5, 2020, <https://www.acog.org/-/media/project/acog/acogorg/clinical/files/practice-bulletin/articles/2016/10/management-of-preterm-labor.pdf>, 2016.
- [3] FDA Drug Safety Communication: New Warnings Against Use of Terbutaline to Treat Preterm Labor FDA. Accessed August 3, 2020. <https://www.fda.gov/drugs/drug-safety-and-availability/fda-drug-safety-communication-new-warnings-against-use-terbutaline-treat-preterm-labor>.
- [4] Committee on Practice Bulletins, Obstetrics with the assistance of George Macones M and SBM. ACOG Practice Bulletin 116 Management of Intrapartum Fetal Heart Rate Tracings. *Obstetrics and Gynecology*. Published online 2010, Accessed August 5, 2020, <https://www.acog.org/-/media/project/acog/acogorg/clinical/files/practice-bulletin/articles/2010/11/management-of-intrapartum-fetal-heart-rate-tracings.pdf>.
- [5] Committee on Practice Bulletins - Obstetrics, In collaboration with Gayle Olson Koutrouvelis M. ACOG Practice Bulletin 221 External Cephalic Version. *Obstetrics and Gynecology*, 2021.

- [6] B.F. Cuneo, H. Zhao, J.F. Strasburger, M. Ovadia, J.C. Huhta, R.T. Wakai, Atrial and Ventricular Rate Response and Patterns of Heart Rate Acceleration during Maternal-Fetal Terbutaline Treatment of Fetal Complete Heart Block, Published online, 2007, <https://doi.org/10.1016/j.amjcard.2007.03.081>.
- [7] M.P.M. Carson, A.J.M. Fisher, William E. Scorza, MD., Atrial fibrillation in pregnancy associated with oral terbutaline, *Obstet. Gynecol.* 100 (5) (2002).
- [8] P.E. Nehls, R. Bhat, L.A. Batten, Terbutaline-induced neonatal ventricular tachycardia: A case report and review of literature, *Ann. Pediatric Cardiology* 13 (2) (2020) 147–149, <https://doi.org/10.4103/apc.APC.102.19>. Published 2020. Accessed August 2, <https://www.ncbi.nlm.nih.gov/pmc/articles/PMC7331846/?report=reader>.
- [9] A. Theplib, V. Phupong, Success rate of terbutaline in inhibiting preterm labor for 48 h success rate of terbutaline in inhibiting preterm labor for 48 h, *J. Matern. Fetal Neonatal Med.* 29 (5) (2016) 841–844, <https://doi.org/10.3109/14767058.2015.1021671>.
- [10] Bettina F.M. Cuneo, Hui P. Zhao, Janette F.M. Strassburger, Marc M. Ovadia, James C.M. Huhta, Ronald T.P. Wakai, Atrial and ventricular rate response and patterns of heart rate acceleration during maternal–fetal terbutaline treatment of fetal complete heart block, *Am. J. Cardiol.* 100 (2007) 661–665. Accessed August 13, 2020, <https://www.mendeley.com/viewer/?fileId=6fe4b612-5157-48d7-1c79-b2cdf59cece&documentId=fe6c95e0-267d-3ee9-9f2e-f284a33ae6e9>.
- [11] American College of Obstetricians and Gynecologists, Obstetric analgesia and anesthesia. ACOG Practice Bulletin No. 209, *Obstet. Gynecol.* 133 (2019) e208–25.
- [12] S.M. Lashgari, A.S.M. Kueck, Y.M. Oyelese, Atrial fibrillation in pregnancy associated with oral terbutaline therapy, *Obstet. Gynecol.* 101 (2003) 814.
- [13] Carpenter RJJrM, Decuir PR., Cardiovascular collapse associated with oral terbutaline tocolytic therapy, *Am. J. Obstet. Gynecol.* 148 (6) (1984) 821–823.
- [14] E.L.M. Kinney, J.J.M. Trautlein, C.V.M. Harbaugh, D.R. Lambert, R.F.M. Zelis, Ventricular tachycardia after terbutaline; Letter to the editor, *JAMA.* 240 (21) (1978) 2247.
- [15] K.M. Kuczkowski, J.L. Benumof, Rebound hyperkalemia after cessation of intravenous tocolytic therapy with terbutaline in the treatment of preterm labor: anesthetic implications, *J. Clin. Anesth.* 15 (5) (2003) 357–358, [https://doi.org/10.1016/S0952-8180\(03\)00028-X](https://doi.org/10.1016/S0952-8180(03)00028-X).
- [16] J.P. Elliott, J.C. Morrison, The evidence regarding maintenance tocolysis, *Obstet. Gynecol. Int.* 2013 (2013) 1–11, <https://doi.org/10.1155/2013/708023>.
- [17] S.J. Leathersich, G.J. Hofmeyr, Acute tocolysis for uterine tachysystole or suspected fetal distress (review), *Cochrane Library Cochrane Database Syst. Rev.* (2018), <https://doi.org/10.1002/14651858.CD009770.pub2>. Published online.
- [18] B. Robinson, v., Etedgui JA, Sherman FS., Use of terbutaline in the treatment of complete heart block in the fetus, *Cardiol. Young* 11 (6) (2001) 683–686, <https://doi.org/10.1017/s1047951101001123>.
- [19] H. Yoshida, M. Iwamoto, H. Sakakibara, H. Shigeta, F. Hirahara, K. Sato, Treatment of fetal congenital complete heart block with maternal administration of beta-sympathomimetics (terbutaline): a case report, *Gynecol. Obstet. Investig.* 52 (2) (2001) 142–144, <https://doi.org/10.1159/000052960>.
- [20] A. Beitzke, R. Winter, M. Zach, H.M. Grubbauer, Congenital atrial flutter with hydrops fetalis caused by tocolytic therapy (author's transl), *Klim Padiatr.* 191 (4) (1979) 410–417. Accessed May 9, 2021, <https://madison.hosts.atlas-sys.com/shib/illiad.dll?Action=10&Form=75&Value=3565083>.