

DYSPLASIA OF HIP DEVELOPMENT: UPDATE

Roberto Guarniero

ABSTRACT

The term “developmental dysplasia of the hip” (DDH) includes a wide spectrum of abnormalities that affect the hip during its growth, ranging from dysplasia to joint dislocation and going through different degrees of coxofemoral subluxation. The incidence of DDH is variable, and depends on a number of factors, including geographical location. Approximately one in 1,000 newborn infants may present hip dislocation and around 10 in 1,000 present hip instability. Brazil has an incidence of five per 1,000 in terms of findings of a positive Ortolani sign, which is the early clinical sign for detecting the disorder. The risk factors for DDH include: female sex, white skin color, primiparity, young mother, breech presentation at birth, family history, oligohydramnios, newborns with greater weight and height, and

deformities of the feet or spine. Hip examinations should be routine for newborns, and should be emphasized in maternity units. Among newborns and infants, the diagnosis of DDH is preeminently clinical and is made using the Ortolani and Barlow maneuvers. Conventional radiography is of limited value for confirming the diagnosis of DDH among newborns, and ultrasound of the hip is the ideal examination. The treatment of DDH is challenging, both for pediatric orthopedists and for general practitioners. The objectives of the treatment include diagnosis as early as possible, joint reduction and stabilization of the hip in a secure position. Classically, treatment options are divided according to different age groups, at the time of diagnosis.

Keywords – Hip/growth & development; Congenital hip dislocation; Developmental bone disease

INTRODUCTION

We have adopted the term “developmental dysplasia of the hip” (DDH) as a replacement for the previous name of “congenital hip dislocation” (CHD) and we propose to disseminate its use. This new nomenclature more precisely describes the spectrum of abnormalities possible for hip disorders among newborns. DDH is a generic term that describes a wide range of anatomical abnormalities of the hip, which may be congenital in nature, or may develop during children’s first months of life.

In reality, the term DDH describes the wide spectrum of abnormalities that affect growing hips, from dysplasia to joint dislocation, and going through the different degrees of coxofemoral subluxation. This new name has been endorsed by the American Academy of Orthopedic Surgeons (AAOS), American Academy of Pediatrics (AAP), Pediatric Orthopedics Society of North America (POSNA), European Pediatric Orthopedics Society (EPOS) and Brazilian Society of Pediatric Orthopedics (SBOP)^(1,2).

DEFINITIONS

Dysplasia of the hip is a term that denotes an abnormality of size, morphology or anatomical orientation, in relation to the organization of either the femoral head or the acetabular cavity, or both. Acetabular dysplasia is characterized by an immature acetabulum, which may cause subluxation or luxation of the femoral head.

In cases of subluxation of the hip, the femoral head is dislocated from its normal anatomical position, but still maintains some contact with the acetabular cavity. In cases of luxation of the hip, there is no contact between the femoral head and the acetabular cavity.

Hips are described as “unstable” when the joint is reduced, in the anatomical position, but when subluxation or luxation of the joint can be caused.

Teratological dislocation is produced during the first months of intrauterine life. At birth, not only can dislocation be recognized, but also there are morphological abnormalities of such a degree that joint reduction will be very difficult, if not impossible. This category

Associate Full Professor in the Department of Orthopedics and Traumatology, University of São Paulo School of Medicine.

Correspondence: Rua Ovídio Pires de Campos, 333, 3^o andar, Cerqueira César, São Paulo, SP – E-mail: robertoguarniero@clinicareboucas.com.br

We declare that there is no conflict of interests in this article

includes dislocations associated with arthrogryposis, Larsen's syndrome, proximal femoral deficiency (with all its variants) and neuromuscular disorders, and dislocations that occur in genetic syndromes. In this group, the hips are almost always dislocated: conditions of subluxation or instability do not exist and will not be discussed in this article.

EPIDEMIOLOGY AND ETIOLOGY

The incidence of DDH is variable and depends on various factors, including geographical location. Around one in every 1,000 newborns may be born with a dislocated hip, and around 10 in every 1,000 with a subluxated (unstable) hip.

In our setting, we can expect that the incidence of a positive Ortolani sign will be around five cases in every 1,000 newborns. This is the early clinical sign used for detecting DDH, as will be outlined below^(3,4).

The risk factors for DDH include: female sex, white skin color, primiparity, young mothers, breech presentation at birth, family history, oligohydramnios, newborns with greater weight and height and newborns with deformities of the feet or spine.

The left hip is more affected (60%) and the right hip is less affected (20%) in situations of unilateral disorders, while bilateral disorders are less frequent (20%).

For unknown reasons, DDH affects individuals of black skin color less frequently.

Italians and descendents of Italians are affected more frequently, including in populations that have emigrated to other geographical regions⁽⁵⁾.

PHYSICAL EXAMINATION

The ideal situation is to perform the examination in the maternity ward, or within the first few days of life. The examination should clearly include taking the history, to assess the risk factors and antecedents, as mentioned earlier, in order to draw up the diagnosis.

The methods for diagnosing DDH were first described in the literature at least 50 years ago. In Italy, Putti started a pioneering program of early diagnosis and treatment for this disorder and published his results in 1926⁽⁶⁾. In the United States in 1932, Howorth carried out a pioneering study on early diagnosis of the disorder, at the Babies Hospital of New York. Other authors then appeared in the literature, but it was in the

late 1940s, after the Second World War, that studies with greater coverage of children were reported in the United States, Sweden and England^(5,7).

Early diagnosis can be regarded as relatively simple and safe, and it provides treatment that is generally effective. Results obtained from early diagnosis that were classified as good or excellent have been reported both within orthopedics and within pediatrics^(5,7). Early treatment provides good results in around 96% of the cases.

Hip examinations on newborns should therefore be performed routinely, and this practice should be emphasized while the newborn is still in the maternity ward. It should also be part of the outpatient follow-up over children's first weeks and months of life.

Among newborns and infants, the diagnosis of DDH is eminently clinical and is made using the Ortolani and Barlow maneuvers. These tests take very little time within the routine physical examinations on newborns⁽⁸⁻¹¹⁾.

Ortolani's sign is a test for hip reduction, i.e. when newborn with a dislocated coxofemoral joint is examined, the femoral head is reduced into the acetabulum through the maneuver, thus demonstrating the dislocation. The maneuver is performed with the child in dorsal decubitus with the hips and knees in the position of 90° flexion and the thighs in adduction with slight internal rotation. One hip is examined at a time, with the other hip well stabilized, in a position of slight abduction. In making a hip abduction movement, possibly accompanied by slight external rotation of the thighs, there may be the feeling of a "protrusion" in joints presenting this disorder (sometimes there may even be an audible sign of this "protrusion"). Such cases are thus said to present a positive Ortolani sign (Figure 1).

Barlow's sign is exactly the opposite, i.e. a maneuver to provoke dislocation of an unstable hip. Barlow's test determines the potential for dislocation of the hip under examination. The patient's thigh is kept at right angles to the trunk, in a position of adduction; force is exerted by the child's knee vertically to the hip, in an effort to dislocate the femoral head from inside the acetabulum. The examiner looks for a sign of "pistoning" in the hip under examination, which may or may not be accompanied by a "protrusion". If the hip is reduced through Ortolani's maneuver, the femoral head will be perfectly lodged in the acetabular cavity; however, with hip flexion and raising the thigh to the adduction position, the femoral head dislocates. This may occur posteriorly to



Figure 1 – Illustrative photograph of the correct way to perform Ortolani's maneuver

the acetabulum, thus characterizing an unstable hip. In Barlow's test, the upper part of the femur is kept between the index and middle fingers, above the greater trochanter, and the thumb is kept in the inguinal region. The femoral head may be levered in and out of the joint, thereby confirming the instability.

Ortolani's maneuver should not be performed using force but, rather, with delicacy and with the child perfectly calm, since this is a procedure to reduce the dislocated hip. If the child is crying a lot and agitated, this will cause difficulties and get in the way of carrying out and concluding the examination.

After a few weeks, if the hip remains dislocated, the limitation on joint abduction will be evident, and this is an important clinical sign. The maximum abduction of the hips of newborns who are considered normal is greater than 60 degrees.

As children with dislocated hips grow, the clinical signs become more obvious. With the passage of time, it becomes more difficult or impossible to reduce the dislocation through Ortolani's maneuver. Thus, this sign becomes negative. The limitation on abduction becomes greater.

Between three and six months of age, hip reduction in conscious children may become difficult. For this reason, it is uncommon to find children with a positive Ortolani sign in this age group. Thus, in this group, Ortolani's maneuver loses its diagnostic value.

The examiner should also bear in mind that if children present "cracking" noises at the time of undergoing the physical examination, this may not be due to an unstable or dislocated hip.

The methods for examining the hips of newborns are shown to medical students or medical residents by means of audiovisual material, or by using babies in the maternity ward. The necessary experience of this clinical examination, which is fundamental for pediatricians, maternity ward physicians and neonatologists, will only be acquired through examining newborns with this disorder. These difficulties can be overcome through using a model for teaching and training students and other healthcare professionals^(12,13) (Figure 2).

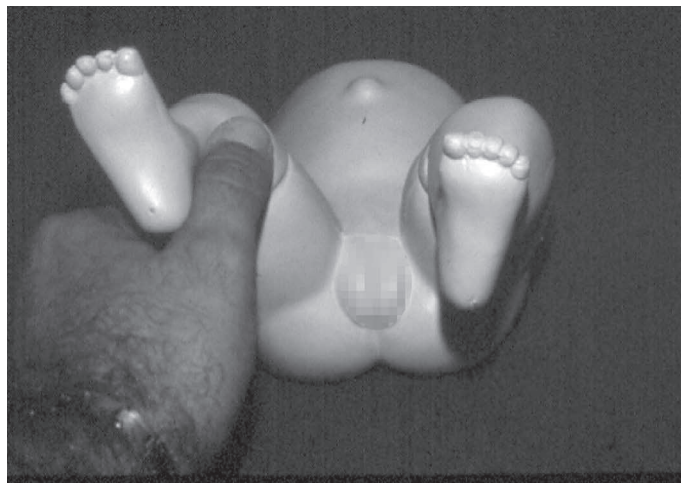


Figure 2 – Teaching model illustrating Ortolani's maneuver

Another, later sign is Galeazzi's or Allis's sign: with the child lying down with flexed knees, they will not be at the same height. This denotes a difference in length between the lower limbs. This sign will clearly be more evident in unilateral cases (Figure 3).

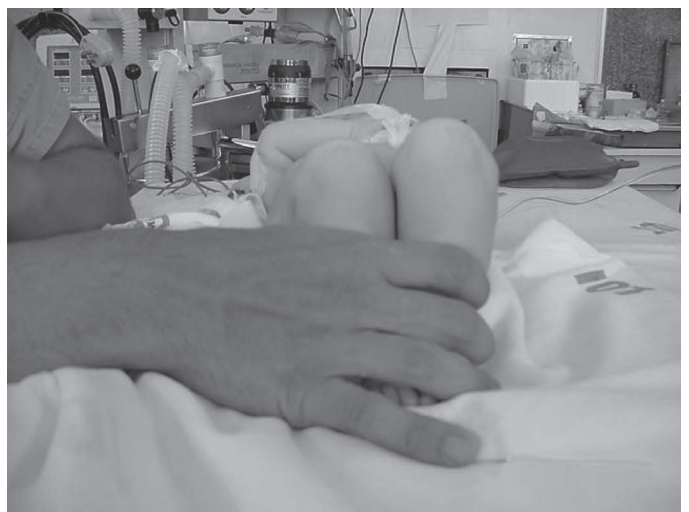

Figure 3 – Illustrative photograph of Galeazzi's sign

There may also be asymmetry in the gluteal skinfolds, but this is not always present.

In any event, we believe that maternity ward physicians or neonatologists should refer children for specialist consultations with orthopedists in the following situations:

- 1) Clinical findings of hip instability or dislocation;
- 2) Cases of doubt; and,
- 3) “High risk” patients, i.e. breech delivery, first pregnancy, young mothers or family antecedents, independent of the results from the physical examination that was performed.

IMAGING EXAMINATIONS

Conventional radiography has limited value for confirming the diagnosis of DDH among newborns, since the proximal femoral epiphysis (femoral head) does not become ossified until the age of four to six months. On the other hand, ultrasonography on the hips of neonates has an obvious potential among children within this age group, since it clearly shows the cartilaginous structures that are poorly delineated by simple radiography^(14,16).

Radiography of the pelvis starts to be used for confirmation of DDH later on, after children have reached the age of four months. It needs to be emphasized that the nucleus of ossification of the femoral head will be radiographically visible from the fourth to sixth month onwards.

In radiographic evaluations for diagnosing DDH during the first months of life, indirect measurements and signs have to be used, such as: quadrant lines, Hilgenreiner’s horizontal line, Perkins’s vertical line, Shenton’s line and the acetabular index (Figure 4).

Because of the power of resolution of axial computed tomography (ACT) for evaluating DDH, and the possibility of producing transverse slices, ACT makes it possible to observe the interposition of the tendon of the iliopsoas muscle and hypertrophy of the pulvinar, even without using contrast medium in the capsule and inside the joint cavity. It also shows femoral subluxation and enables measurement of the angle of acetabular anteversion. This examination can be performed even if the child is using a plaster cast brace and is therefore useful for providing information on the exact position of the reduction. In a study carried out at Hospital das Clínicas, University of São Paulo School of Medicine that was

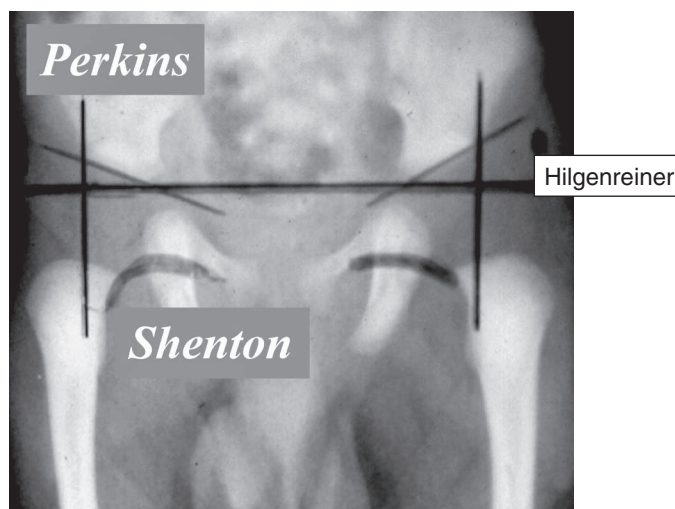


Figure 4 – Lines on radiograph of the pelvis

published in 1990, nine patients with 11 dislocated hips were studied. They underwent closed reduction with immobilization using a plaster cast brace, and this reduction was monitored using ACT. It was concluded that ACT was a good method for evaluating cases of closed reduction of DDH, and that it was useful in most cases in which simple radiography left doubts. As shown by measurements made during that study, the angle of acetabular anteversion was not always increased in cases of DDH. Furthermore, hypertrophied pulvinar could be very well detected by ACT⁽¹⁷⁾.

TREATMENT

Treatment for DDH is a challenge both for pediatric orthopedists and for general physicians. The objectives of this treatment include the aims of making the diagnosis as early as possible, achieving joint reduction and stabilizing the hip in a secure position.

Classically, the treatment possibilities are divided according to the different age groups at the time of the diagnosis.

a) Treatment for newborns up to three months of age

Treatment is indicated as soon as the diagnosis has been made. For this age group, the treatment is based on the concept that if the reduced hip is kept positioned in flexion and slight abduction, the stimulus needed for normal development of the joint will be provided. Thus, once a diagnosis of hip instability or dislocation has been established, treatment will be started with the aim

of reducing the femoral head into the acetabular cavity and maintaining it there until joint stability has definitely been achieved.

Many types of orthopedic devices are available nowadays for fulfilling these initial treatment objectives. Today, the orthosis most commonly used is Pavlik's harness (Figure 5). This orthosis provides simultaneous flexion and abduction of the coxofemoral joint through straps that join together relatively easily. According to Pavlik⁽¹⁸⁾, use of the harness that he invented diminished the risk of requiring surgical reduction.

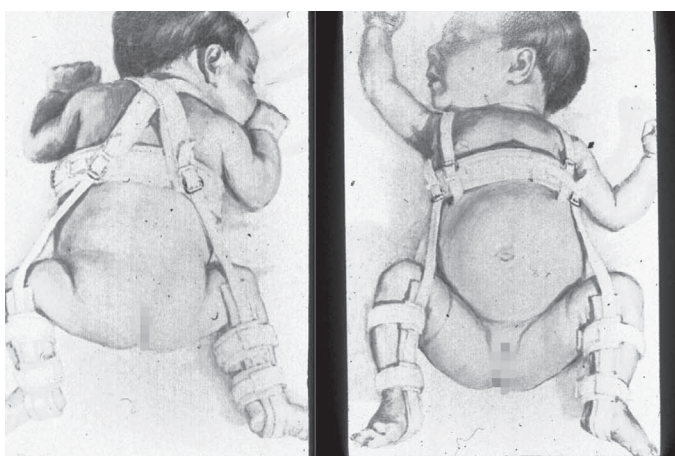


Figure 5 – Illustrative photograph of Pavlik's harness

Ramsey *et al*⁽¹⁹⁾ described the appropriate way to use Pavlik's harness. Its action is based on the principle of reduction while in a flexed position, thereby avoiding a position of forced abduction of the joint. In their study, they showed that 89% of the dislocated hips among children aged under six months could be successfully reduced and thereafter presented normal development through using this orthosis. Only one hip in their study presented slight abnormalities, consisting of osteochondritis. In two patients, failure to achieve reduction was due to not positioning the joint at flexion of 90°. These authors recommended that Pavlik's harness should be used from the newborn period to the age of nine months. They did not report any avascular necrosis of the femoral epiphysis, as also reported by authors such as Kalamchi and MacFarlane⁽²⁰⁾. However, if concentric reduction is not achieved over the first two to three weeks of use of the harness, this approach is abandoned in favor of traction followed by classical techniques for hip reduction.

Failures of reduction when using Pavlik's harness are generally due to poor follow-up of the child by the physician at the outpatient clinic. When it is decided to use the harness, the child has to be examined frequently in order to evaluate whether the device has been applied correctly, usually once a week. Children will generally use the device for six to eight weeks; as a rule of thumb, for approximately twice the numerical value of the age at which use of Pavlik's harness was started. It should be borne in mind that the device can be used up to the age of four to six months⁽²¹⁾.

In cases of failure when using the harness, our choice is to perform closed reduction and immobilization in a plaster cast brace (with or without an initial period of traction), for this age group.

b) Treatment between three months of age and walking age

Within this age range, most patients with DDH can be treated by means of closed reduction and immobilization in a plaster cast brace from the pelvis to the foot⁽²²⁾. During the operation, percutaneous tenotomy of the hip adductor muscles may be necessary.

When reduction through closed maneuvers cannot be achieved, open reduction is indicated. Thus, the indications for open reduction are as follows:

- 1) Femoral head remaining above the triradiate cartilage in the radiographic examination;
- 2) Arc of reduction/luxation less than 25° after tenotomy of the adductors;
- 3) Femoral head not entering the acetabulum;
- 4) femoral head remaining lateralized in relation to the acetabulum, four weeks after partial reduction; and
- 5) Previous failure of attempted reduction.

After the period of immobilization in the plaster cast brace, which will range from two to three months, the patient will progress to using an abduction orthosis (for example, the Milgram device) for a further two to three months.

Children with DDH require clinical and radiographic evaluations, with orthopedic treatment and observation when indicated, until reaching skeletal maturity.

c) Treatment after reaching walking age

This requirement ought not to exist, since the ideal is to make the diagnosis well before this age. Nevertheless, for some children, there may be either diagnostic failure or failure of the consequent early treatment.

The approach to use and the types of treatment for children older than one and a half to two years are matters of controversy.

Attempts to perform closed reduction may be indicated, or otherwise, open reduction will become practically obligatory. For this age group, at the time of the

operation, the femoral bone shortening to enable the joint reduction has to be taken into consideration, along with the need to operations to perform complementary osteotomy in the acetabular region (Salter and Dega osteotomy, among other types)⁽²³⁾.

The age limit for indicating attempts to reduce the hip is around four to five years of age. After this age, so-called joint “salvage” operations are used, including pelvic osteotomy of more elaborate and difficult types (Steel, Chiari, pelvic polygon and other types). Otherwise, total hip arthroplasty might be envisaged.

REFERENCES

- Guille JT, Pizzutillo PD, MacEwen GD. Development dysplasia of the hip from birth to six months. *J Am Acad Orthop Surg.* 2000;8(4):232-42.
- Guarniero R, Lage LAA, Luzo CAM, Romano D. Complicações no tratamento da displasia do desenvolvimento do quadril (DDQ): revisão da literatura e princípios de tratamento. *Acta Ortop Bras.* 1994;2(1):47-9.
- Guarniero R, Montenegro NB, Vieira PB, Peixinho M. Sinal de Ortolani: resultado do exame ortopédico em 9171 recém-nascidos na Associação Maternidade de São Paulo. *Rev Bras Ortop.* 1988;23(5):125-8.
- Guarniero R. Congenital dislocation of the hip. *Epidemiology. Mapfre Med.* 1992;3(Suppl 2):11-3.
- Bowen JR, Kotzias-Neto A. Developmental dysplasia of the hip. *Brooklandville: Data Trace;* 2006.
- Putti V. Congenital dislocation of the hip. *Surg Gynecol Obstet.* 1926;42:449.
- Howorth B. Development of present knowledge of congenital displacement of the hip. *Clin Orthop Relat Res.* 1977;(125):68-87.
- Staheli LT. *Ortopedia pediátrica na prática.* 2a. Porto Alegre: Artmed; 2008.
- Skaggs DL, Flynn JM. Staying out of trouble in pediatric orthopaedics. Philadelphia: Lippincott Williams & Wilkins; 2006.
- Storer SK, Skaggs DL. Developmental dysplasia of the hip. *Am Fam Physician.* 2006;74(8):1310-6.
- Maxwell SL, Ruiz AL, Lappin KJ, Cosgrove AP. Clinical screening for developmental dysplasia of the hip in Northern Ireland. *BMJ.* 2002;27;324(7344):1031-3.
- Guarniero R, Peixinho M, Montenegro NB. Avaliação do uso de um modelo de ensino e treinamento para o diagnóstico precoce da luxação congênita do quadril. *Rev Bras Ortop.* 1988;23(5):133-5.
- Cole WG. Evaluation of a teaching model for the early diagnosis of congenital dislocation of the hip. *J Pediatr Orthop.* 1983;3(2):223-6.
- Sernik R. *Ultrassonografia do sistema musculoesquelético.* Rio de Janeiro: Revinter; 2009.
- Synder M, Harcke HT, Domzalski M. Role of ultrasound in the diagnosis and management of developmental dysplasia of the hip: an international perspective. *Orthop Clin North Am.* 2006;37(2):141-7.
- Guarniero R, Grigoletto Júnior W, Barros JC, Stump XM, Homs C. Ultrasound in the early diagnosis of congenital hip dislocation. *Rev Hosp Clin Fac Med Sao Paulo.* 1986;41(4):194-7.
- Lage LAA, Rodrigues LEA, Stump XMGRG, Guarniero R, Peixinho M. A tomografia axial computadorizada na luxação congênita do quadril. *Rev Bras Ortop.* 1990;25(8):282-6.
- Pavlik A. The functional method of treatment using a harness with stirrups as the primary method of conservative therapy for infants with congenital dislocation of the hip. 1957. *Clin Orthop Relat Res.* 1992;(281):4-10.
- Ramsey PL, Lasser S, MacEwen GD. Congenital dislocation of the hip. Use of the Pavlik harness in the child during the first six months of life. *J Bone Joint Surg Am.* 1976;58(7):1000-4.
- Kalamchi A, MacFarlane R 3rd. The Pavlik harness: results in patients over three months of age. *J Pediatr Orthop.* 1982;2(1):3-8.
- Kalamchi A, MacEwen GD. Avascular necrosis following treatment of congenital dislocation of the hip. *J Bone Joint Surg Am.* 1980;62(6):876-88.
- Vitale MG, Skaggs DL. Developmental dysplasia of the hip from six months to four years of age. *J Am Acad Orthop Surg.* 2001;9(6):401-11.
- Forlin E, Munhoz da Cunha LA, Figueiredo DC. Treatment of developmental dysplasia of the hip after walking age with open reduction, femoral shortening, and acetabular osteotomy. *Orthop Clin North Am.* 2006;37(2):149-60.