

Sphenoid Wing Dysplasia in the Absence of Neurofibromatosis: Diagnosis and Management of a Novel Phenotype

Zachary D. Zapatero, BS

Christopher L. Kalmar, MD, MBA

Mychajlo S. Kosyk, BA

Anna R. Carlson, MD

Scott P. Bartlett, MD

Summary: Congenital sphenoid wing dysplasia is one of the major diagnostic criteria for neurofibromatosis type 1, and is often considered pathognomonic for the disease. Between 5% and 12% of neurofibromatosis type 1 cases have evidence of sphenoid wing dysplasia. Sequelae of this deficiency include slow expansion of the middle temporal fossa and progressive herniation of the temporal lobe into the orbital cavity, resulting in pulsatile exophthalmos. Herein, we report a patient with greater sphenoid wing agenesis and middle temporal fossa enlargement requiring transcranial orbital reconstruction in the absence of neurofibromatosis. To our knowledge, this represents a novel craniofacial phenotype of sphenoid wing agenesis in the absence of neurofibromatosis previously not described in the literature. (*Plast Reconstr Surg Glob Open* 2021;9:e3483; doi: [10.1097/GOX.0000000000003483](https://doi.org/10.1097/GOX.0000000000003483); Published online 18 March 2021.)

Sphenoid wing dysplasia manifests as hypoplasia or gross defects of the greater or lesser wing of the sphenoid bone. Sequelae of the deficiency include slow expansion of the orbit and middle cranial fossa, ultimately with progressive herniation of the temporal lobe into the posterior orbit resulting in pulsatile proptosis.¹ To date, all reported cases of congenital sphenoid wing dysplasia have been attributed to neurofibromatosis type 1 (NF1). NF1 is a common autosomal dominant neurocutaneous-skeletal tumor predisposing syndrome due to a mutation in the NF1 tumor suppressor gene. The NF1 gene plays a role in growth and development of the craniofacial skeleton through the RAS/RAF pathway, and thus craniofacial anomalies are observed in cases of NF1.² Greater sphenoid wing dysplasia occurs in roughly 5%–12% of cases of NF1³ and some consider the finding to be pathognomonic for the condition.⁴

A NF1 clinical diagnosis can be made if a patient has 2 of 7 of the following criteria: 6 or more café au lait macules, 2 or more cutaneous/subcutaneous neurofibromas, axillary or groin freckling, optic glioma, 2 or more lisch nodules, bony dysplasia, and first degree relative with NF1.⁵ Herein, we report the first patient in the literature with sphenoid wing agenesis in the absence of neurofibromatosis, with over 12 years of follow-up.

From the Division of Plastic and Reconstructive Surgery, The Children's Hospital of Philadelphia, Philadelphia, Pa.

Received for publication December 14, 2020; accepted January 21, 2021.

Copyright © 2021 The Authors. Published by Wolters Kluwer Health, Inc. on behalf of The American Society of Plastic Surgeons. This is an open-access article distributed under the terms of the [Creative Commons Attribution-Non Commercial-No Derivatives License 4.0 \(CCBY-NC-ND\)](https://creativecommons.org/licenses/by-nc-nd/4.0/), where it is permissible to download and share the work provided it is properly cited. The work cannot be changed in any way or used commercially without permission from the journal.

DOI: [10.1097/GOX.0000000000003483](https://doi.org/10.1097/GOX.0000000000003483)

CASE

An 18-month-old non-Hispanic White male child with no contributory medical, surgical, or family history presented for craniofacial surgery evaluation due to a pulsatile proptotic left eye. A computed tomography scan (CT) of the head revealed the absence of the left greater wing of the sphenoid with resultant displacement of the middle cranial fossa contents into the orbit and proptosis of the left orbital contents (**Fig. 1**). Following the CT scan, genetic testing was performed to confirm a presumed NF1 diagnosis. Genetic testing did not identify NF1, and the determination was made to follow the patient clinically for additional signs of NF1 to confirm the presumed diagnosis.

At 20 months old (2007), the patient underwent a transcranial reconstruction of the greater wing of the sphenoid with a titanium mesh and cranial bone graft via an anterior craniofacial approach. The technique is considered to have the greatest success in preventing progressive orbital deformity and proptosis.⁶ Six months later (2008), the patient underwent strabismus surgery for correction of related muscular imbalances. The patient was subsequently followed by ophthalmology and plastic surgery, with attention to clinical findings that could confirm the diagnosis of NF1.

During follow-up, the patient was noted to develop contour irregularities of the forehead, bitemporal hollowing, mild left esotropia, and left-sided enophthalmos (2010) with no progression of the orbital disease (**Fig. 2**).

At the age of 9.5 years (2015), a CT for surveillance of potential NF1 was notable for stable expansion of the left middle cranial fossa. No additional pathognomonic findings for NF1 were identified. By the age of 10.5 years (2016), the patient's bitemporal hollowing and contour

Disclosure: *The authors have no financial interest to declare in relation to the content of this article.*

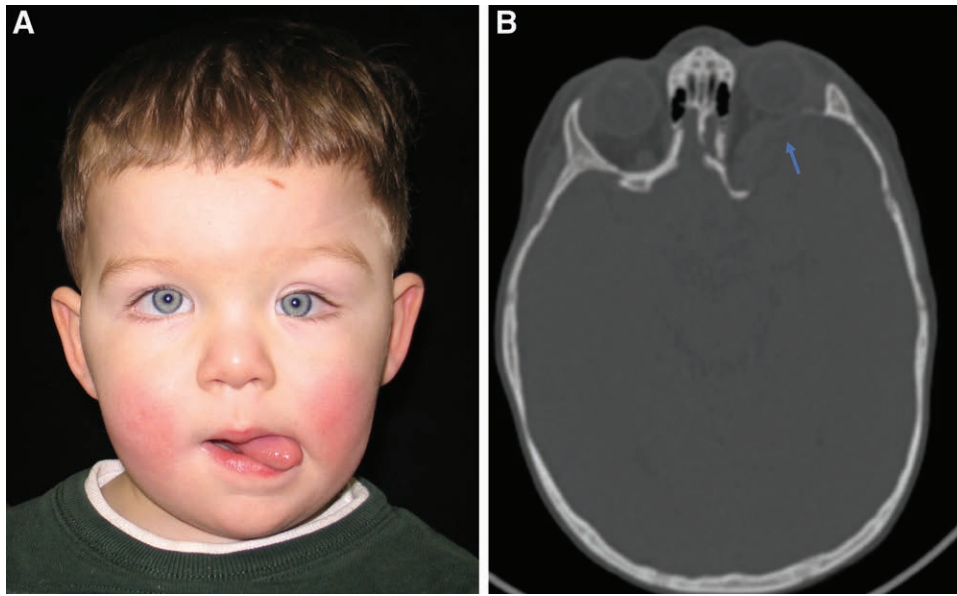


Fig. 1. An 18-month-old male child who presented for pulsatile proptosis of the left eye. Pre-orbital reconstruction photograph (A) and CT image (B) demonstrating exophthalmos and absence of the greater sphenoid wing (blue arrow).

irregularities of the forehead had progressed; at age 14 (2020), he was deemed a candidate for frontoparietal cranioplasty. A CT scan for surgical planning again identified expansion of the left middle cranial fossa with scalloping and thinning of the adjacent calvaria. At this point, given ongoing clinical concern for NF1, the patient was referred to oncology neurofibromatosis clinic and neurosurgery. Both teams reaffirmed a negative NF1 diagnosis.

The patient subsequently underwent frontal cranioplasty with carbonated calcium phosphate and achieved a favorable aesthetic result (Fig. 3).

In summary, the patient presented with isolated greater sphenoid wing agenesis requiring bony orbital reconstruction due to pulsatile proptosis, typically considered pathognomonic for NF1. After 12 years of follow-up, the patient's orbital reconstruction remains stable, and neither molecular diagnostic testing or clinical evaluation has diagnosed NF1.

DISCUSSION

In this article, we present a case of sphenoid wing agenesis and middle cranial fossa enlargement not associated with NF1. To our knowledge, this patient represents the only reported case of a patient with greater sphenoid wing agenesis in the absence of NF1, suggesting that this cranial base abnormality may present in isolation and in the absence of an underlying genetic defect. Although the current literature strongly supports the diagnosis of NF1 in patients with pulsatile proptosis and greater sphenoid wing absence,^{7,8} our patient has yet to develop any overt signs of NF1 with 12 years of follow-up. Our institution has previously published our experience regarding the management of sphenoid wing dysplasia in Naran et al, and recommend the same indications for orbital reconstruction, including significant and/or progressive dysplasia and presence of ocular symptoms believed to be a consequence of sphenoid wing absence.⁶

The pathophysiology of sphenoid wing dysplasia in patients with NF1 is debated. Macfarlane et al described an NF1-positive patient who developed radiologic changes of sphenoid dysplasia between 2 CT scans that were taken more than 10 years apart.⁹ It has been postulated that the sphenoid bone abnormalities are not congenital, but acquired due to local factors. Our institution previously explored sphenoid wing dysplasia and congenital absence in NF1 patients, and demonstrated that roughly 50% of patients had progressive dysplasia between scans, but other patients had congenital agenesis or non-progressive disease.⁶ Our patient's first CT scan was performed at the age of 20 months, which demonstrated a complete absence of the greater wing of the sphenoid bone. This finding most likely represents a true congenital defect due to the complete absence of the greater wing; however, it could be possible that there was progressive dysplasia from birth to presentation at 18 months, given that proptosis was not noticed at birth. This is less likely because there was no other local finding that would suggest a cause for progressive dysplasia. Additionally, Latham et al reported that earlier cranial bone involvement was associated with more aggressive NF1 disease,¹⁰ which reaffirms the authors' beliefs of a true negative NF1 diagnosis.

CONCLUSIONS

We have presented the first known case, to our knowledge, in the English literature, of sphenoid wing agenesis in the absence of NF1. Congenital absence of the greater sphenoid wing with resultant expansion of the middle temporal fossa is not pathognomonic for an NF1 diagnosis. Orbital reconstruction using titanium mesh and bone grafting is a viable, long-term reconstruction option in greater sphenoid wing agenesis. The authors acknowledge

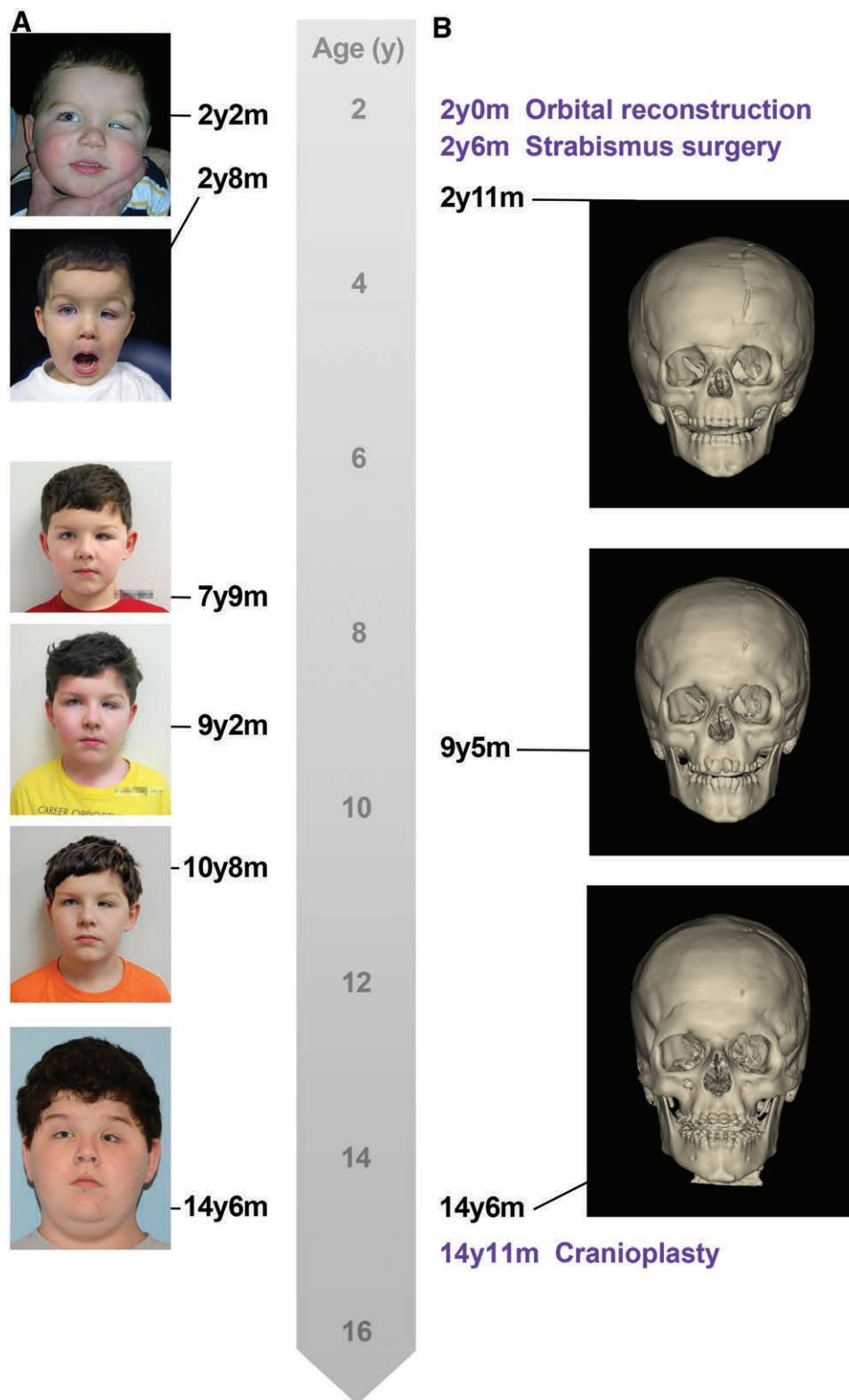


Fig. 2. Timeline of the 12-year follow-up. Clinical photographs (A) and CT images (B) demonstrating the presence of mild left esotropia, left-sided enophthalmos, and progressive forehead contour irregularities with bitemporal hollowing.

PATIENT CONSENT

Parents provided written consent for the use of the patient's images.

REFERENCES

1. Marchac D. Intracranial enlargement of the orbital cavity and palpebral remodeling for orbitopalpebral neurofibromatosis. *Plast Reconstr Surg.* 1984;73:534–543.
2. Heervä E, Peltonen S, Pirttiniemi P, et al. Short mandible, maxilla and cranial base are common in patients with neurofibromatosis 1. *Eur J Oral Sci.* 2011;119:121–127.
3. Chauvel-Picard J, Lion-Francois L, Beuriat PA, et al. Craniofacial bone alterations in patients with neurofibromatosis type 1. *Childs Nerv Syst.* 2020;36:2391–2399.
4. Dale EL, Strait TA, Sargent LA. Orbital reconstruction for pulsatile exophthalmos secondary to sphenoid wing dysplasia. *Ann Plast Surg.* 2014;72:S107–S111.
5. Ferner RE, Huson SM, Thomas N, et al. Guidelines for the diagnosis and management of individuals with neurofibromatosis 1. *J Med Genet.* 2007;44:81–88.
6. Naran S, Swanson JW, Ligh CA, et al. Sphenoid dysplasia in neurofibromatosis: Patterns of presentation and outcomes of treatment. *Plast Reconstr Surg.* 2018;142:518e–526e.
7. Friedrich RE. Reconstruction of the sphenoid wing in a case of neurofibromatosis type 1 and complex unilateral orbital dysplasia with pulsating exophthalmos. *In Vivo.* 2011;25:287–290.
8. Mortada A. Pulsating exophthalmos with orbital neurofibromatosis. *Am J Ophthalmol.* 1967;64:462–464.
9. Macfarlane R, Levin AV, Weksberg R, et al. Absence of the greater sphenoid wing in neurofibromatosis type I: congenital or acquired: case report. *Neurosurgery.* 1995;37:129–133.
10. Latham K, Buchanan EP, Suver D, et al. Neurofibromatosis of the head and neck: Classification and surgical management. *Plast Reconstr Surg.* 2015;135:845–855.



Fig. 3. Clinical photograph 1 month post frontal cranioplasty demonstrating favorable aesthetic result.

the strong association between greater sphenoid wing dysplasia and NF1 in the literature, and advocate for continued surveillance for patients presenting with similar clinical scenarios.

Scott P. Bartlett, MD

Division of Plastic and Reconstructive Surgery
The Children's Hospital of Philadelphia
3401 Civic Center Blvd