



## Cosmetic Medicine

### Special Topic

# Aspiration Before Tissue Filler—An Exercise in Futility and Unsafe Practice

Greg J. Goodman, MBBS, FACD, GradDipClinEpi, MD<sup>o</sup>;  
Mark R. Magnusson, MBBS, FRACS<sup>o</sup>; Peter Callan, MBBS, FRACS, MBA;  
Stefania Roberts, MA, MBBS, FRACP; Sarah Hart, MBChB, NZSCM;  
Frank Lin, MBBS, FRACS; Eqram Rahman, MBBS, MS, PhD;  
Cara B. McDonald, MBBS, FACD; Steven Liew, MBBS, FRACS;  
Cath Porter, MBBS; Niamh Corduff, FRACS; and Michael Clague, BA

Aesthetic Surgery Journal  
2022, Vol 42(1) 89–101

© 2021 The Aesthetic Society.

This is an Open Access article distributed under the terms of the Creative Commons Attribution-NonCommercial License (<https://creativecommons.org/licenses/by-nc/4.0/>), which permits non-commercial re-use, distribution, and reproduction in any medium, provided the original work is properly cited.

For commercial re-use, please contact journals.permissions@oup.com  
DOI: 10.1093/asj/sjab036  
[www.aestheticsurgeryjournal.com](http://www.aestheticsurgeryjournal.com)

For commercial re-use, please contact journals.permissions@oup.com

DOI: 10.1093/asj/sjab036

[www.aestheticsurgeryjournal.com](http://www.aestheticsurgeryjournal.com)

**OXFORD**  
UNIVERSITY PRESS

### Abstract

**Background:** Aesthetic physicians rely on certain anecdotal beliefs regarding the safe practice of filler injections. These include a presumed safety advantage of bolus injection after a negative aspiration.

**Objectives:** The authors sought to review and summarize the published literature on inadvertent intravascular injection of hyaluronic acid and to investigate whether the technique of aspiration confers any safety to the practitioner and the patient.

**Methods:** Pertinent literature was analyzed and the current understanding of the safety of negative and positive aspiration outlined.

**Results:** The available studies demonstrate that aspiration cannot be relied on and should not be employed as a safety measure. It is safer to adopt injection techniques that avoid injecting an intravascular volume with embolic potential than utilize an unreliable test to permit a risky injection.

**Conclusions:** To prevent intravascular injection, understanding “injection anatomy” and injection plane and techniques such as slow, low-pressure injection are important safety measures. Assurance of safety when delivering a bolus after negative aspiration does not appear to be borne out by the available literature. If there is any doubt about the sensitivity or reliability of a negative aspiration, there is no role for its utilization. Achieving a positive aspiration would just defer the risk to the next injection location where a negative aspiration would then be relied on.

### Resumo

**Histórico:** Os médicos esteticistas confiam em certas convicções sem comprovação científica a respeito da prática segura de injeções de preenchimento, que incluem uma suposta vantagem de segurança da injeção em bolo após uma aspiração negativa.

Dr Goodman is an adjunct associate professor at Monash University, Melbourne, Australia. Dr Magnusson is an associate professor at Griffith University Southport, Queensland, Australia. Dr Roberts is an aesthetic physician/phlebologist in private practice in Victoria, Australia. Dr Hart is an aesthetic physician in private practice in Auckland, New Zealand. Dr Callan is a specialist plastic surgeon in private practice in Geelong, Victoria, Australia. Dr Lin is a specialist plastic surgeon in private practice in Melbourne, Victoria, Australia. Dr Rahman is an associate professor in plastic and reconstructive surgery at Royal Free Hospital, University College London, United Kingdom. Dr McDonald is a dermatologist at St Vincent's Hospital,

Melbourne, Australia. Dr Liew is a specialist plastic surgeon in private practice in Darlinghurst, New South Wales, Australia. Dr Porter is an aesthetic practitioner in private practice in Darlinghurst, New South Wales, Australia. Dr Corduff is a specialist plastic surgeon in private practice in Geelong, Victoria, Australia. Mr Clague is an aesthetic injecting nurse in private practice in South Yarra, Victoria, Australia.

### Corresponding Author:

Dr Greg J. Goodman, 8-10 Howitt St South Yarra 3141, Victoria, Australia.

E-mail: [gg@div.net.au](mailto:gg@div.net.au); Twitter: [@DrMarkMagnusson](https://twitter.com/DrMarkMagnusson)

**Objetivos:** O objetivo dos autores foi avaliar e resumir a literatura publicada sobre injeção intravascular inadvertida de ácido hialurônico e investigar se a técnica de aspiração confere alguma segurança ao médico e ao paciente.

**Métodos:** A literatura pertinente foi analisada e foi enunciado o entendimento atual sobre a segurança das aspirações negativas e positivas.

**Resultados:** Os estudos disponíveis demonstram que a aspiração não é confiável e não deve ser utilizada como medida de segurança. É mais seguro adotar técnicas de injeção que evitem a injeção de um volume intravascular com potencial de embolia do que utilizar um teste não confiável para permitir uma injeção arriscada.

**Conclusões:** Para evitar a injeção intravascular, o entendimento da "anatomia da injeção" e do plano de injeção, bem como técnicas, como, por exemplo, a injeção lenta e de baixa pressão, são medidas de segurança importantes. A garantia de segurança ao administrar um bolo após aspiração negativa não parece ser comprovada pela literatura disponível. Se houver qualquer dúvida sobre a sensibilidade ou confiabilidade de uma aspiração negativa, não há justificativa para sua utilização. Alcançar uma aspiração positiva apenas adiará o risco em relação ao local da próxima injeção, onde uma aspiração negativa seria então adotada.

## Level of Evidence: 4



Editorial Decision date: November 19, 2020; online publish-ahead-of-print January 29, 2021.


*Finally, we shall place the Sun himself at the center of the Universe.*

—Nicolaus Copernicus

In the time of Nicolaus Copernicus, there was a widely held but scientifically incorrect belief that the earth lay at the center of the universe. Just because a belief is widely held does not make it so. This is just as true today as it was 500 years ago. A similar belief system seems to exist among practitioners who rely on the value of aspiration before filler injection, where an absence of demonstrable evidence does not seem to be an impediment to its continued teaching. Given that decisions of considerable importance (injection of static bolus) are being made on the validity of a negative finding, it behooves an examination of this practice.

Aspiration has long been considered a safety measure and is mentioned in many consensus documents. Many opinion leaders continue to teach it to aesthetic practitioners as a requirement before injection. Belief in the importance of aspiration is predicated on the following structural concepts:

1. The cannula or needle is placed in the desired position for injection and thereafter not be moved from this point; (Figure 1)
2. Once in position, the aspiration is performed and the result (positive or negative aspiration) determines whether to proceed with injection;
3. If the aspiration test is negative, then it is deemed to be safe to proceed with injection, but movement is not permitted from that point;



**Figure 1.** Needle in position abutting bone (the ultimate in remaining stationary) before aspiration. A needle tip may be altered (blunted or deformed) by this bony contact.

4. If the aspiration is positive, then the needle or cannula should be repositioned.

This all sounds superficially plausible, yet the literature and real-world experience would indicate it is intrinsically flawed. Hence, this integrative literature review aims to investigate whether the technique of aspiration confers any safety to the practitioner and patient against inadvertent intravascular injection of hyaluronic acid (HA).

**Table 1.** Beliefs and Outcomes

Belief or concept	Finding or likely outcome	References
Quick pull aspiration test on plunger sufficient to ensure safety of injection	Shown to be unreliable in most instances; difficult to clear filler from needle	24-27
Slow pull aspiration test on plunger up to 5-10 sec assures safety of injection	Unreliable in up to one-third of cases; difficult to clear filler from needle	24,25,27,28
Possible to have sufficiently steady hand to be in same position at end of aspiration as at beginning of aspiration	Doubtful. Most aspirations will have moved needle position enough to be at risk of being in a vessel at the end of aspiration.	2,3
An understanding of anatomy is sufficient to allow safe static bolus injection	Variability in anatomy, particularly within facial layer but also between layers, makes safety only relative	6-9
Vertical injection on periosteum with negative aspiration ensures safety	Needle tends to deposit product in multiple layers, especially in thin skin regions	17,18
Once aspiration is negative, movement is not advisable	A belief in aspiration would dictate this to be true and would need to be repeated at every injection point. Using lips as an example, this appears unworkable.	2,29
All blood vessels can be aspirated	Small vessels would likely collapse with pressure of aspiration	2-4
Concept of aspiration requires stationary bolus injections to be employed	Potentially dangerous if injection is intravascular as a greater deposit of cohesive material would be injected	27-29
Unprimed needles may be useful in avoiding false-negative rates	Unprimed needles require injection once with bolus, then operator must withdraw and replace needle before next injection. Unprimed needles also do not change issues regarding hand movement during aspiration procedure	3,29
Cannulae are safer than needles	Cannulae, if smaller gauge (27# or less), behave much like needles and should be subject to same safety maneuvers	19-22

## METHODS

### Study Design

Due to the high heterogeneity of the published literature reporting aspiration technique related to HA filler injection, we opted for an integrative literature review. The integrative analysis process enables different methodologies (ie, experimental and non-experimental research) to be reviewed and can play a larger role in evidence-based practice.<sup>1</sup>

### Search Strategy

Pertinent literature investigation (centered on the efficiency and safety ramifications of aspiration before injection) was performed using multiple search engines, including PubMed [United States National Library of Medicine (NLM), Bethesda, MD], Cochrane (Wiley, Hoboken, NJ), Centre for Reviews and Dissemination (University of York, York, United Kingdom), and Google Scholar (Google, Mountain View, CA) employing the following keywords (“hyaluronic acid” and “aspiration”), (“hyaluronic acid” and “blood aspiration”), and (“hyaluronic acid” or “cosmetic” and “blood aspiration”), with no limit selected for the year of publication. Studies published in English and both clinical and experimental studies were included. Searching was mainly conducted

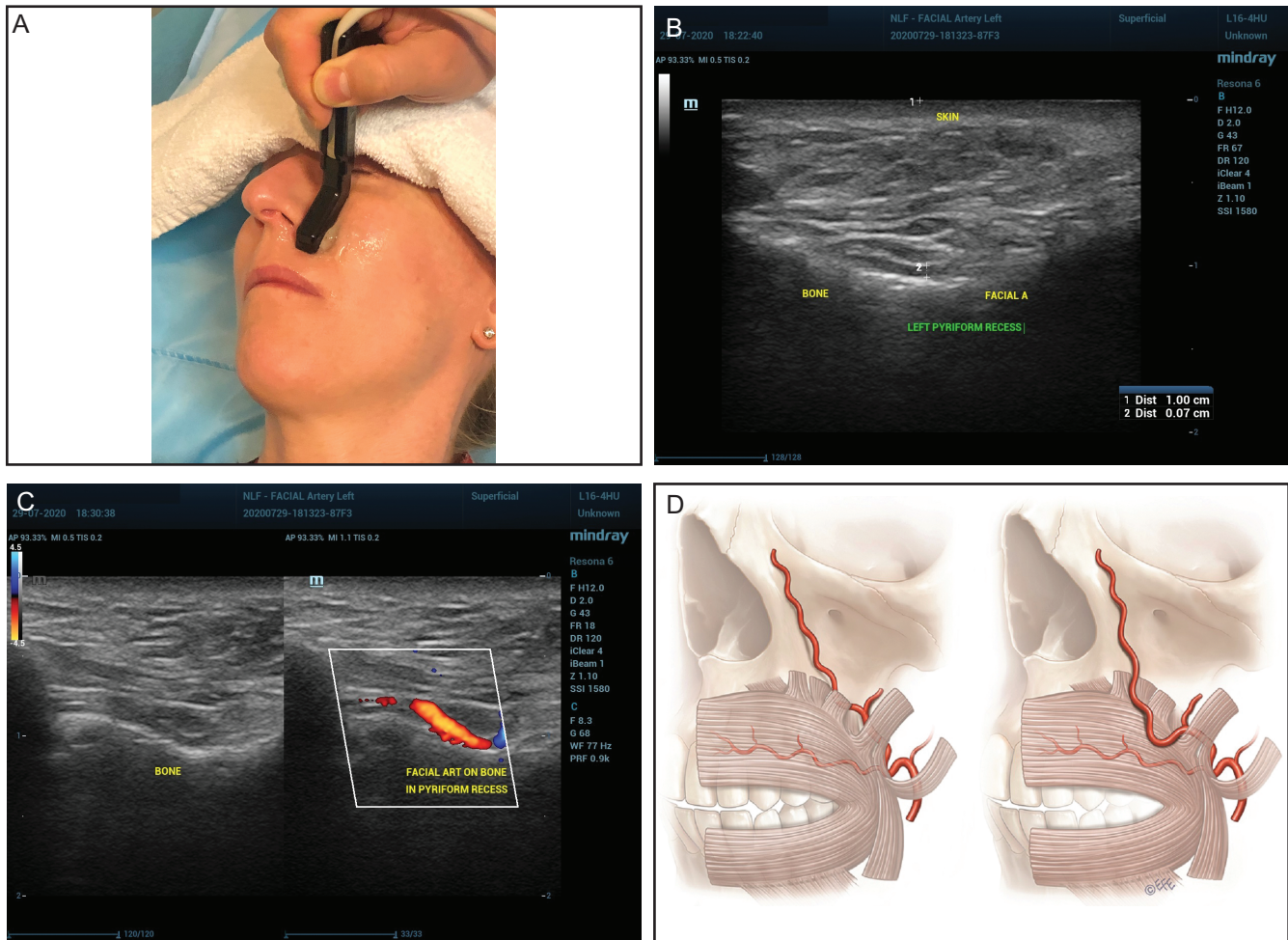
by 1 of the authors (G.G.) with contributions from many of the co-authors. The inclusion and exclusion of articles was agreed on by frequent group discussion. The searches were performed between May and September 2020.

### Data Evaluation

Due to the variable primary sources, reports were coded in accordance with 2 standards applicable to this review: methodological or theoretical rigor and a 2-point (high or low) data pertinence. Based on this data assessment rating system, no study was excluded; however, the score was employed as a data analysis component. Overall, low-rigor and low-validity papers added less to the analytical process.<sup>1</sup>

## RESULTS

Because data were conceptualized at higher abstractions, every primary source was analyzed to ensure that the new conceptualization corresponded to primary sources. A thematic synthesis was developed to thoroughly demonstrate the integration process. The basic concepts of aspiration as a safety mechanism are explored below, with the corresponding data and evidence from primary sources analyzed and integrated to determine the validity of the concepts (Table 1).



**Figure 2.** (A, B, C) Clinical and ultrasonic images of a deep aberrant artery in the deep pyrifform recess. Usual vs aberrant facial artery patterns. (D) The aberrant pattern may position the facial artery in the nasolabial fold and upper cutaneous lip.

1. The cannula or needle must be placed in the desired position for injection and not be moved from this point.

The assumption posed by this concept is that following a negative aspiration, a safe injection of filler is guaranteed if the instrument is held exactly in place.

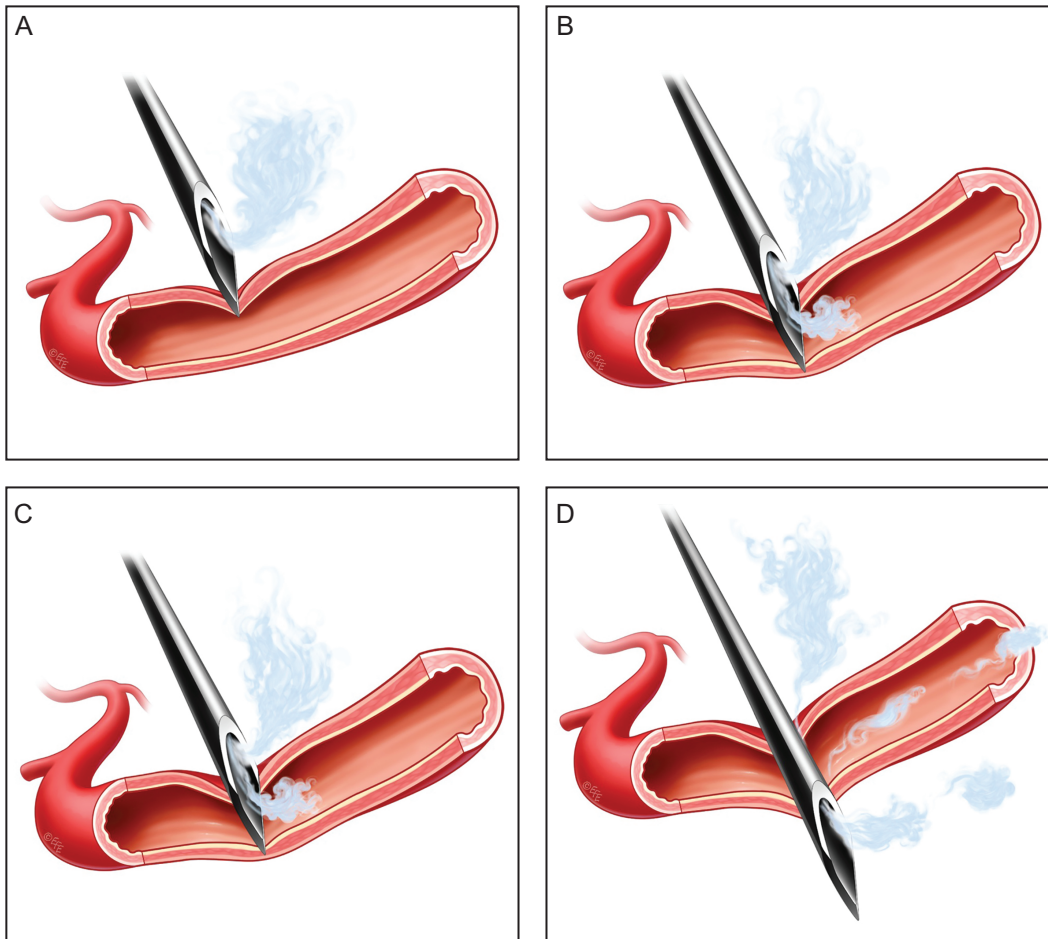
Some further aspects flow from this concept:

- a. One cannot move at all from this position or else run the risk of moving the instrument into a vessel.

The practitioner must therefore decide between the following contradictory techniques of injection: moving or aspirating. One cannot hold both positions.<sup>2</sup> Reliance on aspiration requires no movement, yet movement is promoted by many consensus groups as a significant safety procedure.<sup>3-5</sup> Movement of the instrument in and out of vessels is believed to reduce the chance of inadvertently injecting an embolic bolus of filler within a single vessel. With continual movement, any filler injected within a vessel should be small enough to dissipate harmlessly in the circulation.

Theoretical facial anatomy accompanied by a negative aspiration offers neither evidence for stationary injection nor further protection against intravascular injection. There is much variability in the facial vasculature both within facial layers and between these layers (Figure 2A-D).<sup>6-8</sup> An understanding of anatomical vascular patterns at the depth of injection will help substantially, but there are flaws in a total reliance on depth<sup>9</sup> that will be discussed further in this review.

The concept of movement as a safety maneuver is based on the undeniable fact that we are in and out of vessels all the time as evidenced by bruising as a commonplace issue when injecting fillers. Movement has been commonly employed over the years for retrograde and anterograde filling, fanning, and linear threading techniques. The caliber of most named facial vessels is only in the order of 1 to 2 mm,<sup>10</sup> and movement would likely mean only a fleeting intravascular presence (unless the vessel is cannulated) (Figure 3A-D).



**Figure 3.** (A) Needle approaching vessel. (B) Needle impinging vessel. (C) Needle passing into vessel. (D) Needle passing through vessel depositing very little and probably not significant volume of product into the vessel.

It is still possible to achieve a deposit in the one area without delivering a static bolus by utilizing small amplitude movements (a couple of millimeters of oscillation within the plane chosen for injection). When injecting on the bone, safety may be enhanced by injecting at a non-vertical angle (at the smallest acute angle possible with the bevel surface down facing towards the bony plane) to reduce the chance of the needle bevel occupying multiple tissue planes and enabling the practitioner to move the needle if they choose to do so during the injection process. This movement should reduce the chance of a large inadvertent intravascular bolus of filler, thus limiting potential ramifications, especially visual loss.<sup>2,3</sup>

b. One must deliver the bolus in precisely that position.

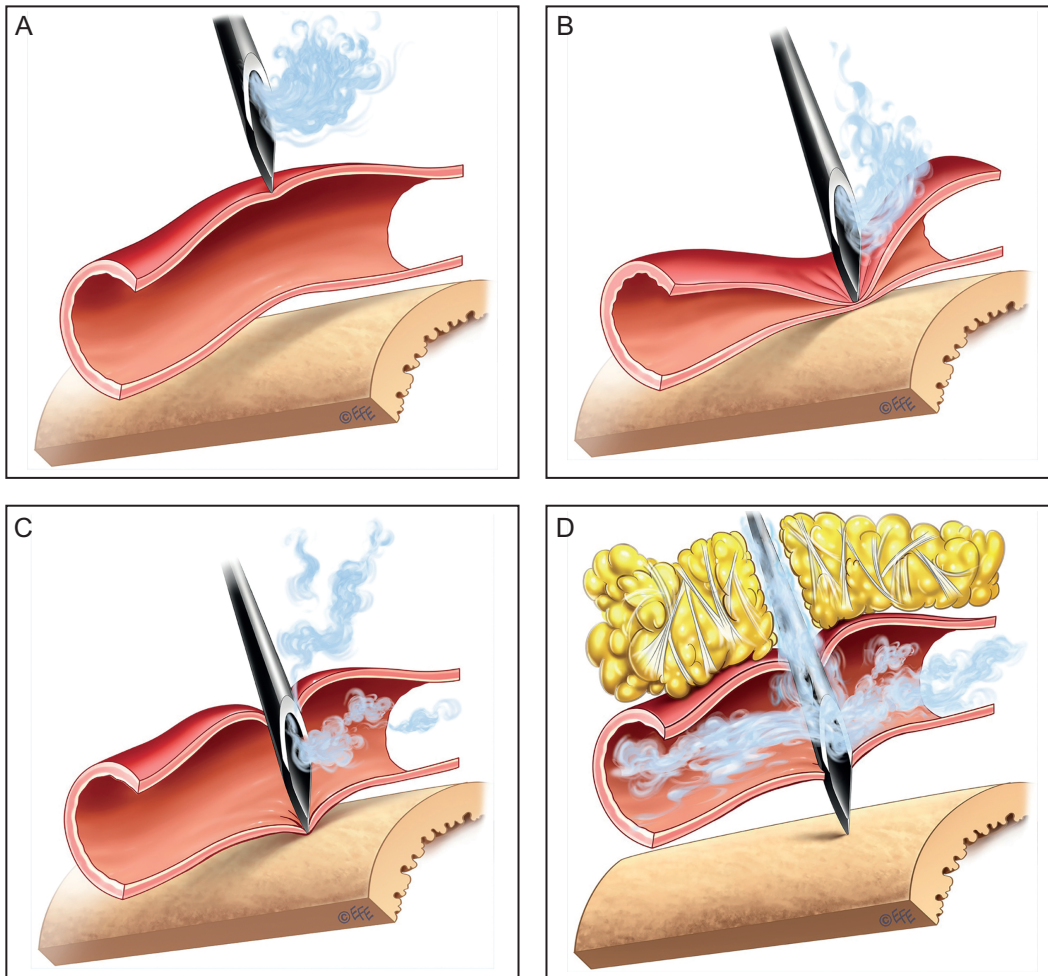
If the bolus must be delivered in a stable position, we are relying on the predictive power of negative aspiration. At present, there are no studies to our knowledge that point to this being a reliable technique.<sup>5</sup> The potential catastrophic outcome of a false-negative aspiration is an injection of a substantial amount of intravascular filler, with

possible resultant embolic consequences to the skin,<sup>11</sup> deeper facial structures,<sup>12</sup> eye,<sup>13</sup> lungs,<sup>14,15</sup> or the brain.<sup>16</sup> If we add a rapid injection at high pressure to this procedure, then this bolus becomes very dangerous indeed because it may progress retrograde through this circulation back to the retinal vessels and into the internal carotid circulation.

c. If one is to take this on as a belief, it should be something that one does in any and every area of injection.

First there is an impracticality of this approach to consider. Practitioners who are on one hand vocal with their support for staying still once in position rarely follow this concept when injecting other areas such as lips. In mobile regions such as lips, it would be thoroughly impractical if not impossible to aspirate and stay still with every injection point. Similarly, with cannula utilization, this concept is impractical and not employed because the movement of the cannula is generally utilized in preference to staying still once in the desired area.

Second, it is commonly stated that one should reach periosteum, settle here, and then perform aspiration. Of



**Figure 4.** (A) Needle is starting to impinge but not perforate vessel. (B) Needle has transfixied the vessel on to bone but has not perforated the vessel. Aspiration here will render a negative result. The hand movement required during aspiration may reposition the needle into the vessel, or the increased resistance of the bone with subsequent injection may allow vessel perforation. (C) Vessel is perforated. The operator, unaware and reassured by the negative aspiration, may proceed to injection of bolus. (D) Even if the vessel remains only partially transfixied to the periosteum, the vertical height of the bevel of the needle and the pressure differential between the resistance of the bone to forward injection pressure and the pierced vessel may see the bolus delivered largely in the vessel as the route of least resistance.

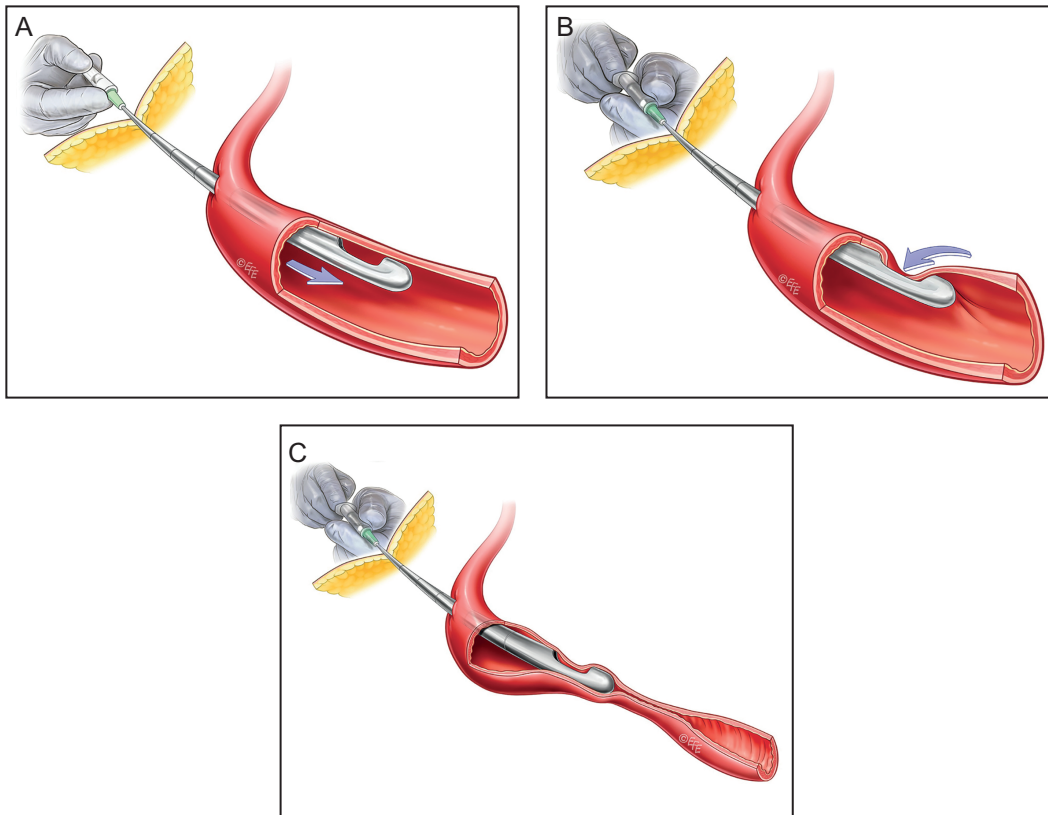
course, this only works when there is periosteum at the injection point. This is not possible in most of the perioral area and is not desirable over bony foramina.

Cadaver studies have suggested that periosteal needle placement may not have the accuracy of placement that has been assumed.<sup>17,18</sup>

These cadaver studies have also shown that a relatively vertical injection on the periosteum may cause intravascular injection through multiple mechanisms. Currently, the most commonly taught injection technique is to place the needle on the periosteum vertically before injection for injection at depth.

Both needles and cannulae are capable of piercing vessels and initiating embolization.<sup>19-21</sup> Once this happens, the following intravascular scenarios may occur despite perceived periosteal “safe” placement:

- An impacted vessel may be dragged to the bone by the needle. The needle, once on bone, may finally puncture the displaced vessel and fill it with HA. In this instance, there would be the possibility of a positive aspiration test (Figure 4A-D).<sup>19</sup>
- A second possibility is that the needle may have skewered and passed through the vessel, leaving a tract of low resistance alongside the needle extending down to the bone. This may allow filler to spread along the tract of low resistance back into the impaled vessel. Positive aspiration in this scenario is unlikely.<sup>17,22</sup>
- A third possibility is that the length of the needle bevel may induce unexpected intravascular injection even with periosteal needle positioning. In cadaver studies, vertical needle placement has been shown to allow filler in many layers,<sup>17</sup> including the dangerous



**Figure 5.** (A) Instrument has entered a vessel (here, a cannula is utilized for illustration). (B) Instrument is undergoing an aspiration maneuver but is sucking in the vessel wall, potentially producing a false negative aspiration test. (C) Instrument has entered the vessel, but with the pressure of aspiration the vessel wall may be collapsed, blocking the opening and again leading to a false-negative aspiration.

muscular lamella.<sup>23</sup> This may be due to the bevel length, which reaches up to 2 mm for a 25-gauge needle (down to 1 mm for 30 gauge). This may allow filler to be deposited not only at the tip but also along the entire length of the bevel and with retrograde flow up the track left by the passage of the needle. Some filler may be in the correct layer, but the more superficial reaches of the bevel may be in a vessel. In this situation, a positive aspiration may or may not be possible.

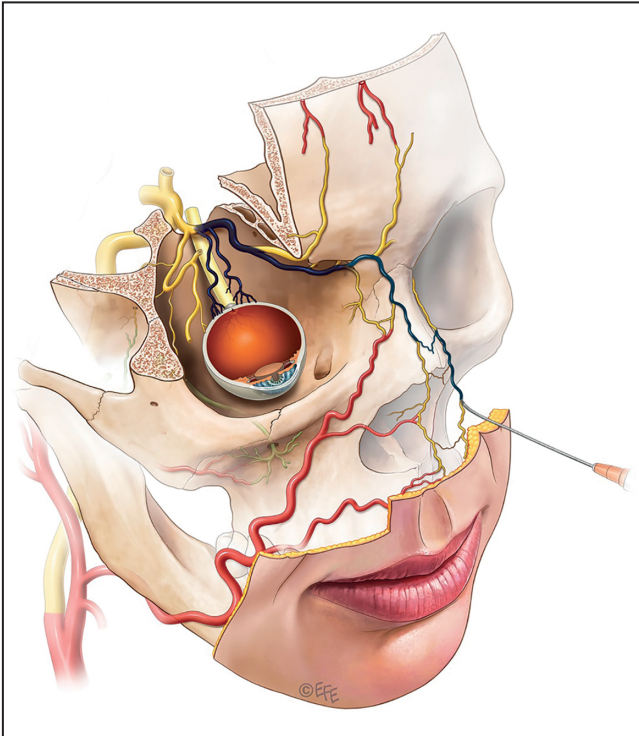
- A fourth possibility is that the needle or cannula is blocked, either by the wall of the vessel being sucked into the instrument opening or the vessel collapsing during the aspiration maneuver; despite being intravascular, a flashback is prevented (Figure 5A-C).
- d. Once in position, aspiration is performed, and the finding may be relied on to proceed or not with injection.

A series of articles have led to questioning the value of a negative aspiration as an assurance of safety. In theory, negative aspiration (if it were reliable) should assure the injector that they are not in a vessel and ensure safe injection

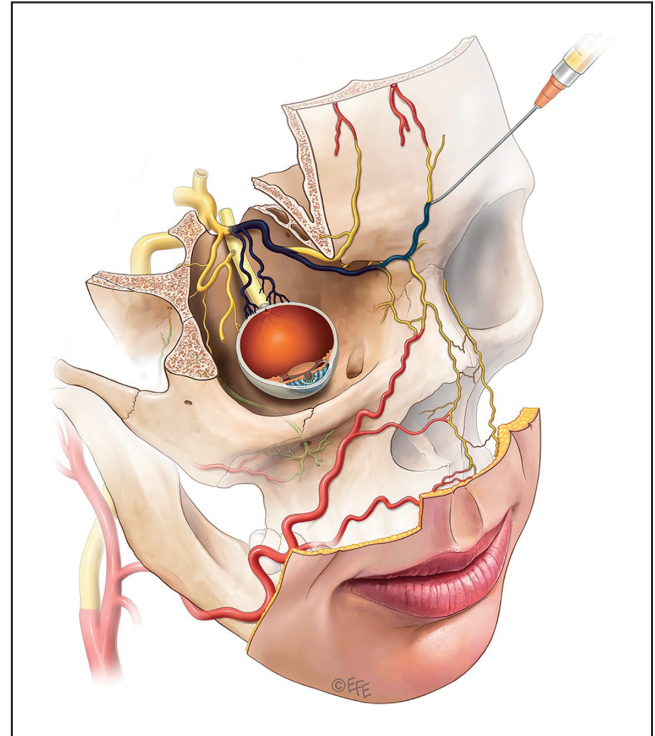
of the product. However, many concerns have been expressed in several recent papers.<sup>19,24,25,26,27</sup>

The findings of these papers are summarized below (Table 1):

- A rapid (1 second) pull and release method does not allow sufficient time for removal of the intraluminal filler material vs a long (5 seconds) pull and release method. The rapid method may give rise to false-negative results in vitro and possibly in vivo with many currently utilized fillers.<sup>24</sup>
- Aspiration of ink from a beaker was positive with only 53% of fillers utilizing supplied syringe needles but became more frequently positive as larger bore needles were employed.<sup>25</sup> However, most practitioners utilize the manufacturer's supplied needle rather than substituting a larger bore needle.
- In the most comprehensive study,<sup>26</sup> 24 fillers were investigated with 11 different needle sizes. Two bags were pressurized to 150 mm Hg to simulate arterial blood pressure, which would be higher than in vivo situations, especially for smaller facial blood vessels. One bag contained Ringer's solution with blue dye and the other



**Figure 6.** Injection of an artery (branch or trunk of the angular artery) will flow with the blood pressure of this vessel but must overcome the ophthalmic artery blood pressure to achieve access to the retinal and cerebral vasculature. This is most likely to require continued injection at sufficient pressure with a continuous bolus of material.



**Figure 7.** Given the proximate nature of the supratrochlear artery to the ophthalmic circulation, very little injection volume is required to reach the retinal vessels, making the injection of fillers near these ophthalmic artery branches much more dangerous than the branches of the external carotid arteries in the mid face and lower face.

anticoagulated blood. Of the overall 340 aspiration tests, only 112 yielded positive aspiration (33%) with a 1-second aspiration and 212 (63%) after 10-second aspiration. When the needles supplied by the manufacturers were employed, aspiration was positive in 37% of trials with a 1-second aspiration and 74% with a 10-second aspiration.

- A small in vitro study<sup>27</sup> of 10 commonly utilized fillers studied pull back time to flash employing anticoagulated blood in a vacutainer tube. Two pullback volumes (0.2 mL vs 0.5 mL) were compared, yielding a total of 20 aspirations. Widely varied results were found with no filler exhibiting flash below a 2-second pull, some requiring over 10 seconds before flash, some requiring 20 seconds, and 1 not exhibiting a flash at all.

The issues around negative aspiration as a safety maneuver can be summarized as follows:

- Insufficient negative pressure may lead to false-negative aspiration, especially in smaller vessels. The thickness and the G prime of the filler may likewise prevent accurate aspiration.<sup>26-28</sup> Because there are so many small, low-pressure facial vessels, it is likely that many times the needle will enter one of these, which may result in 3 potential issues.

- Exceptionally quick pullback aspiration will have insufficient pressure to the filler column back into the syringe on aspiration;
- It is possible that a small caliber vessel may collapse under the pressure of an attempted aspiration and reopen when pressure is released, and the injection begun allowing an inadvertent intravascular embolism;
- After a reassuring negative aspiration, subsequent bolus injection may allow retrograde filling of the smaller upstream arteries leading to major vessels. On reaching significant vessels, the downstream flow may block the intricate tributaries producing tissue embolic ischaemia. In rare cases, with pressure on the plunger and bolus formation, retrograde flow may progress into the ophthalmic arterial system. On the release of the plunger, this filler column may reverse direction with re-establishment of normal arterial flow, thus affecting all ophthalmic tributaries including the central retinal and ciliary vessels (Figure 6). Maintaining precise hand position is required after negative aspiration because even minor changes can shift needle position to the intravascular plane.<sup>18</sup> This is particularly relevant when aspirating for a prolonged time, and considerable negative pressure is exerted to enhance



the possibility of positive aspiration.<sup>28</sup> The aspiration maneuver (0.5 mL vs 0.2 mL of pullback), performed as a single or a double-handed movement, inevitably shifts the instrument such that the tip position at the end of the maneuver is not going to be the same as at initiation. Furthermore, studies conducted *in vitro* do not take into account movement by the recipient of the injecting interaction. Patient movement, even minute reactive or mimetic actions such as head turning, grimace, flinch or vocalization, will also shift the tissue planes relative to the needle tip. Finally, it is also important to realize that a full 1-mL syringe only allows limited pullback.

- b. Currently, deep injections on bone are considered safer practice in the mid-face, deep pyriform space, and temple because deep injections bypass the middle lamella where mimetic or masticatory muscles and major vessels are found.<sup>23</sup> However, foramina are found in the suprapariosteal plane in the mid-face. Cadaver studies have highlighted the relevance of these issues.<sup>17,18</sup>
- c. Vertical needle insertion may lead to multiple layer injection, involving more superficial vasculature. Injecting a static bolus after negative aspiration may still cause tissue infarction or fill very small vessels like the supratrochlear artery. In a cadaver study, volumes as low as 0.04 mL (average of 0.085 mL) were sufficient to fill the supratrochlear artery (Figure 7).<sup>28</sup>
- d. Although larger bore needles are considered beneficial for decreasing false-negative aspiration, the longer bevel length poses potential problems due to the likelihood of entering multiple layers on vertical injection.<sup>17,18</sup> This holds true especially for the thin tissues of the nose and forehead and also vulnerable deep vessels such as the temple.
- e. Priming or not priming the needle is also discussed in the literature.<sup>29</sup> It would seem that priming the needle will lead to a more direct transmission of pressure in a hydraulic sense, but not priming removes the need to suck the intraluminal filler back up the needle. This may allow a vacuum to form in the hub, which will fill with blood quickly if a vessel is impaled or transited if negative pressure is transmitted through retraction of the plunger. Relying on an unprimed needle would obligate the injector to withdraw after every single injection point and replace the needle with another unprimed needle. In addition to this impracticality of relying on unprimed needles, if one is committed to this technique, it would tempt the practitioner to concentrate on

bolus injection to limit how many needles and injection points were to be utilized. Relying on unprimed needles or newer needles that enable more effective aspiration adds nothing to the validity of the aspiration concept.<sup>2</sup>

## DISCUSSION

With the rapid growth of soft tissue filler injections, which now number in the millions annually, rare but serious adverse events are seen by many aesthetic practitioners. It is incumbent on the medical fraternity to have well-educated and informed experts able to guide less experienced injectors in the safest practices available.

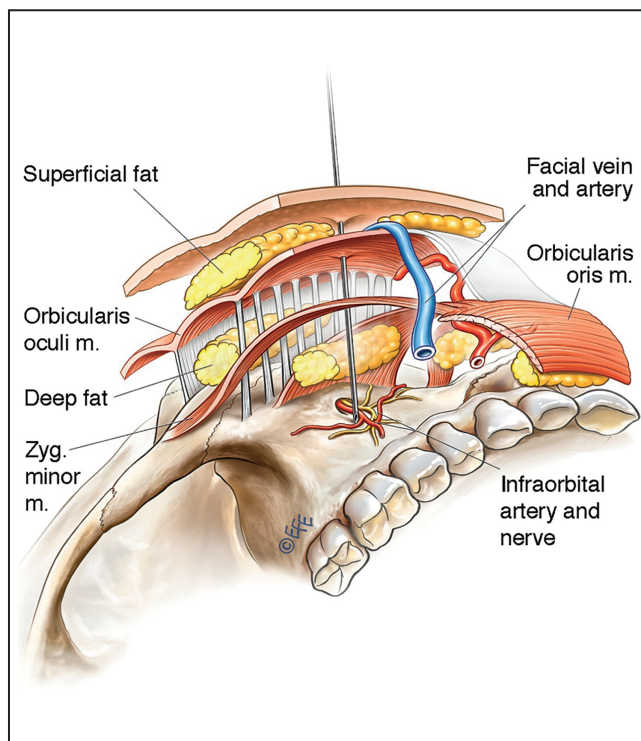
There are many injecting strategies that will minimize the chance of an intravascular event. At a consensus meeting in September 2018, 9 concepts for optimizing safety and avoiding intravascular events and consequent visual loss were elucidated and agreed on (Table 2).<sup>3</sup>

An understanding of anatomy takes primacy. Self-education by the practitioner not only extends to product utilization and placement but must extend to a thorough knowledge of facial anatomy, specifically “injection anatomy.” This particularly entails adequate vascular anatomy knowledge.<sup>30-32</sup> However, the vascular supply is quite variable in its anastomoses and patterns.<sup>6</sup> The one relative but not immutable constant is the depth of the vascular supply, but a total reliance on understanding anatomy is also potentially flawed (Figure 2A-C). Dangerous areas such as the glabella, forehead, and nose pose a particular risk for skin and eye complications because of their thin tissue planes and intimate relationship to the ophthalmic artery system. These areas exhibit a higher risk of intravascular accident with needle injection because the bevel may allow the filler to occupy many layers. The issue may be confounded by filler back traveling along the track left by a needle or cannula. This back tracking may have vascular ramifications if the instrument en route to deeper structures has pierced a vessel allowing backtracking filler to flow back into the pierced vessel.<sup>33</sup>

Although numerous articles have noted the limitations of a reliance on aspiration,<sup>2-4,34</sup> the advice was usually that practitioners utilizing this technique should understand its limitations. However, this consensus group<sup>3</sup> went further in their advice and advised that aspiration was not considered to be a safe practice and recommended against its utilization as a safety measure. Reasons for this have been explained through this article and in Table 1. To encapsulate these arguments, a false-negative aspiration may occur due to vessel collapse, movement from the initial position into a vessel after an aspiration maneuver, or difficulty with clearing the filler from the needle. This will prevent blood flash and is affected by product rheology

**Table 2.** Recommendations for Minimizing the Chance of Embolic Phenomena (After Visual Consensus Paper<sup>9</sup> 2020)

Recommendations
1. Understand the safest depth of injection in any given area
2. Inject VERY slowly and with low extrusion pressure
3. Cannulae are considered by many to be a safer alternative to needles in certain areas, including the brow, lateral, and anterior cheek. They are not considered safer for nasal injection. Smaller gauge cannulae (<25 gauge) may behave somewhat like needles in terms of their ability to pierce blood vessels.
4. Consider utilizing local anaesthetic with adrenaline at cannula entry points and within the injection field to constrict local vessels. When utilizing local anaesthetic with adrenaline, it may be worthwhile observing the patient after injection to ensure the vasoconstrictive effect resolves in order to avoid confusion with intravascular injection of filler.
5. Consider directing the needle/cannula perpendicular to primary axial vessels in the anatomical region to reduce the likelihood of vessel cannulation
6. Micro-boluses should be injected in small aliquots (<0.1 mL)
7. Move the needle in the chosen plane at all times when delivering micro-boluses, even if only in small amplitude movements
8. Consider ensuring the direction of injection is away from the eye in higher risk areas such as nose, glabella, and nasolabial fold
9. There is currently no evidence to support aspiration as a safety measure



**Figure 8.** Vessels at foramina such as the infraorbital artery are relatively immobile and prone to injury from deep injection on the bone. This is true for all exiting vascular structures from facial foramina.

factors, size of needle, and duration or force of retraction pressure.

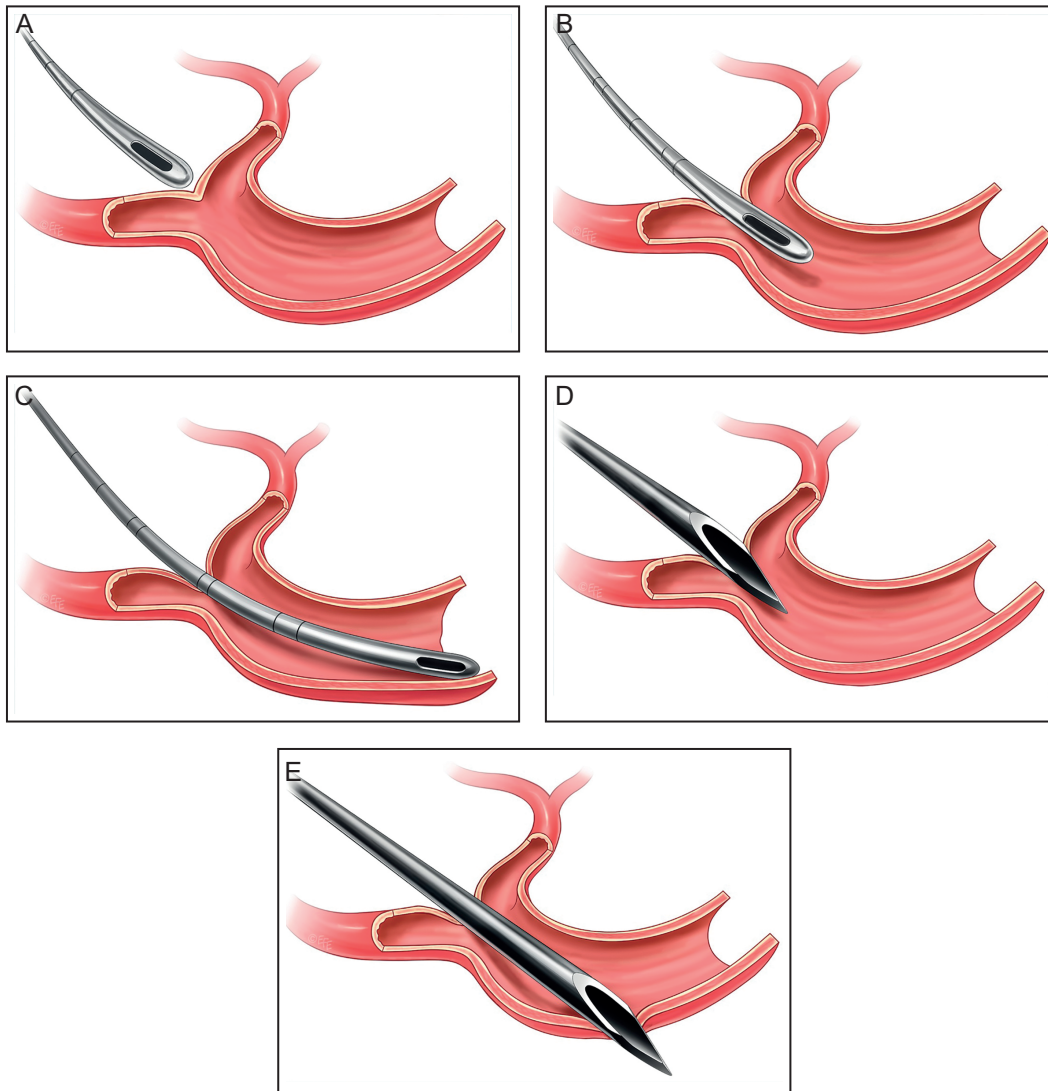
Negative aspiration may unfortunately cement the idea that the practitioner is safe, despite that they may in fact be in or move into a vessel and not realize it. They will

then try not to move the needle and possibly go on to inject a column of a variable amount of filler into the vessel. The group felt that not only was aspiration not reliable, but it stood in the way of other strategies that were deemed more reliable. It was felt that continuing movement of the instrument and limiting bolus size to microbolus size of less than 0.1 mL were important. Movement is particularly important, even at the periosteal plane, and combined with slow injection and low extrusion pressure are considered essential to avoiding intravascular injection of significant amounts of filler (Figure 3).

The fact that just because one can aspirate does not justify the attempt to do so and subsequent false assumptions this may lead to. The argument that “I aspirate because it can’t do any harm and gives me some information” similarly does not stand up to scrutiny for reasons discussed in this article. Still, some will continue to do it, citing the occasional positive aspiration as proof that the practice is sound. Karl Popper, one of the last century’s great philosophers and conceptual thinkers, is worthy of quoting in this context: “Science must begin with myths, and with the criticism of myths”<sup>35</sup> and “If we are uncritical we shall always find what we want: we shall look for, and find, confirmations, and we shall look away from, and not see, whatever might be dangerous to our pet theories.”<sup>36</sup>

Popper in his theory of falsifiability and verifiability would contend that a single false-negative aspiration would falsify the theory that aspiration works, notwithstanding all the positive aspirations that are possible or reported.

The decision of needle vs cannula is difficult. It would appear that needles are safer in certain sites and cannulae in others. Cannulae are over-represented in cases of



**Figure 9.** (A) Cannula approaching a fairly fixed point of vascular bifurcation. (B) Cannula piercing vascular bifurcation, entering vessel, and staying intravascular. (C) Cannula moving freely within the vessel, which may leave the practitioner unaware of its placement. (D) Needle entering vascular bifurcation. (E) Unlike the cannula, a needle is likely with movement to exit the vessel.

blindness,<sup>20,37</sup> and even large cannulae have been the culprit in intravascular injection episodes.<sup>27,37</sup> In general, smaller needle sizes and larger cannulae sizes are recommended,<sup>21</sup> although no cannula would appear safe in nasal injections.<sup>19</sup>

Cadaver studies suggest that if the cannula is placed at the correct depth, it tends to maintain the deposit in that layer.<sup>17,18</sup> Elegant methods have been described for their utilization.<sup>38</sup> The employment of cannulae, although blunt, includes the following issues:

- If the gauge is narrow, a cannula may act as a needle in its ability to pierce blood vessels.<sup>3,4,39</sup>
- Vessels can be relatively stabilized at certain points, such as at vascular junctions or if embedded in scar

tissue or emerging from foramina. Vessels are more liable to be cannulated at these points (Figures 8, 9A-D).<sup>21,22</sup>

- Even the widest cannulae are smaller in diameter than some facial vessels and have been responsible for intravascular injection.
- A cannula may pass through a vessel, and backtracking of filler may occur on retrograde injection.<sup>21,22</sup>
- Several cases of blindness and pulmonary embolization due to suspected intravascular embolization of fillers have been reported where cannulae were employed.<sup>40,41</sup>
- It follows that if it may be more difficult to enter a vessel with a cannula, it is also more difficult to remove it if a vessel is entered.

## CONCLUSIONS

In conclusion, injectors should consider all mechanisms for avoiding intravascular complications. The choice of the implanting tool—either needle or cannula—would appear not to guarantee safety. It is also important to realize that aspiration may result in a false negative. Aspiration by its very nature disallows 2 other important safety measures: those of movement and avoidance of static bolus production.

Recent literature would suggest that rather than rely on aspiration, avoidance mechanisms such as continuous movement when injecting, slow injection speed, low extrusion force, and small volumes, in conjunction with an in-depth understanding of the safer injection planes pertaining to vascular anatomy, may mitigate intravascular incidents.

## Acknowledgments

The authors acknowledge Dr Levent Efe (Certified Medical Illustrator) for the illustrations accompanying this paper.

## Disclosures

The authors declared no potential conflicts of interest with respect to the research, authorship, and publication of this article.

## Funding

The authors received no financial support for the research, authorship, and publication of this article.

## REFERENCES

- Whittemore R, Knafl K. The integrative review: updated methodology. *J Adv Nurs*. 2005;52(5):546-553.
- Goodman GJ, Magnusson MR, Callan P, et al. Neither positive nor negative aspiration before filler injection should be relied upon as a safety maneuver. *Aesthet Surg J*. 2021;41(4):NP134-NP136.
- Goodman GJ, Magnusson MR, Callan P, et al. A consensus on minimizing the risk of hyaluronic acid embolic visual loss and suggestions for immediate bedside management. *Aesthet Surg J*. 2020;40(9):1009-1021.
- Beleznyay K, Carruthers JDA, Humphrey S, Carruthers A, Jones D. Update on avoiding and treating blindness from fillers: a recent review of the world literature. *Aesthet Surg J*. 2019;39(6):662-674.
- Signorini M, Liew S, Sundaram H, et al. Global Aesthetics Consensus Group. Global aesthetics consensus: avoidance and management of complications from hyaluronic acid fillers-evidence- and opinion-based review and consensus recommendations. *Plast Reconstr Surg*. 2016;137(6):961e-971e.
- Cotofana S, Lachman N. Arteries of the face and their relevance for minimally invasive facial procedures: an anatomical review. *Plast Reconstr Surg*. 2019;143(4):1282-1283.
- Pils U, Anderhuber F, Neugebauer S. The facial artery—the main blood vessel for the anterior face? *Dermatol Surg*. 2016;42(2):203-208.
- Yang HM, Lee JG, Hu KS, et al. New anatomical insights on the course and branching patterns of the facial artery: clinical implications of injectable treatments to the nasolabial fold and nasojugal groove. *Plast Reconstr Surg*. 2014;133(5):1077-1082.
- Cotofana S, Alfertshofer M, Schenck TL, et al. Anatomy of the superior and inferior labial arteries revised: an ultrasound investigation and implication for lip volumization. *Aesthet Surg J*. 2020;40(12):1327-1335.
- Tucunduva MJ, Tucunduva-Neto R, Saieg M, Costa AL, de Freitas C. Vascular mapping of the face: B-mode and doppler ultrasonography study. *Med Oral Patol Oral Cir Bucal*. 2016;21(2):e135-e141.
- Kim DW, Yoon ES, Ji YH, Park SH, Lee BI, Dhong ES. Vascular complications of hyaluronic acid fillers and the role of hyaluronidase in management. *J Plast Reconstr Aesthet Surg*. 2011;64(12):1590-1595.
- Fang M, Rahman E, Kapoor KM. Managing complications of submental artery involvement after hyaluronic acid filler injection in chin region. *Plast Reconstr Surg Glob Open*. 2018;6(5):e1789.
- DeLorenzi C. Complications of injectable fillers, part 2: vascular complications. *Aesthet Surg J*. 2014;34(4):584-600.
- Jang JG, Hong KS, Choi EY. A case of nonthrombotic pulmonary embolism after facial injection of hyaluronic acid in an illegal cosmetic procedure. *Tuberc Respir Dis (Seoul)*. 2014;77(2):90-93.
- Han SW, Park MJ, Lee SH. Hyaluronic acid-induced diffuse alveolar hemorrhage: unknown complication induced by a well-known injectable agent. *Ann Transl Med*. 2019;7(1):13.
- Hong JH, Ahn SJ, Woo SJ, et al. Central retinal artery occlusion with concomitant ipsilateral cerebral infarction after cosmetic facial injections. *J Neurol Sci*. 2014;346(1-2):310-314.
- van Loghem JA, Humzah D, Kerscher M. Cannula versus sharp needle for placement of soft tissue fillers: an observational cadaver study. *Aesthet Surg J*. 2017;38(1):73-88.
- Pavicic T, Frank K, Erlbacher K, et al. Precision in dermal filling: a comparison between needle and cannula when using soft tissue fillers. *J Drugs Dermatol*. 2017;16(9):866-872.
- Beleznyay K, Carruthers JD, Humphrey S, Jones D. Avoiding and treating blindness from fillers: a review of the world literature. *Dermatol Surg*. 2015;41(10):1097-1117.
- Tansatit T, Apinuntrum P, Phetudom T. A dark side of the cannula injections: how arterial wall perforations and emboli occur. *Aesthetic Plast Surg*. 2017;41(1):221-227.
- Yeh LC, Fabi SG, Welsh K. Arterial penetration with blunt-tipped cannulas using injectables: a false sense of safety? *Dermatol Surg*. 2017;43(3):464-467.
- DeLorenzi C. New high dose pulsed hyaluronidase protocol for hyaluronic acid filler vascular adverse events. *Aesthet Surg J*. 2017;37(7):814-825.
- Goodman GJ, Al-Niaimi F, McDonald C, Ciconte A, Porter C. Why we should be avoiding periorificial mimetic muscles when injecting tissue fillers. *J Cosmet Dermatol*. 2020;19(8):1846-1850.
- Carey W, Weinkle S. Retraction of the plunger on a syringe of hyaluronic acid before injection: are we safe? *Dermatol Surg*. 2015;41(Suppl 1):S340-S346.

25. Casabona G. Blood aspiration test for cosmetic fillers to prevent accidental intravascular injection in the face. *Dermatol Surg.* 2015;41(7):841-847.
26. Van Loghem JA, Fouché JJ, Thuis J. Sensitivity of aspiration as a safety test before injection of soft tissue fillers. *J Cosmet Dermatol.* 2018;17(1):39-46.
27. Torbeck RL, Schwarcz R, Hazan E, Wang JV, Farberg AS, Khorasani H. In vitro evaluation of preinjection aspiration for hyaluronic fillers as a safety checkpoint. *Dermatol Surg.* 2019;45(7):954-958.
28. Khan TT, Colon-Acevedo B, Mettu P, Delorenzi C, Woodward JA. An anatomical analysis of the supratrochlear artery: considerations in facial filler injections and preventing visual loss. *Aesthet Surg J* 2017;37(2):203-208.
29. Tseng FW, Bommareddy K, Frank K, et al. Descriptive analysis of 213 positive blood aspiration cases when injecting facial soft tissue fillers. *Aesthet Surg J.* 2021;41(5):616-624.
30. Kumar N, Rahman E, Addis PJ. An effective and novel method for teaching applied facial anatomy and related procedural skills to esthetic physicians. *Adv Med Educ Pract.* 2018;9:905-913.
31. Kumar N, Swift A, Rahman E. Development of "core syllabus" for facial anatomy teaching to aesthetic physicians: a Delphi consensus. *Plast Reconstr Surg Glob Open.* 2018;6(3):e1687.
32. Kumar N, Rahman E. Effectiveness of teaching facial anatomy through cadaver dissection on aesthetic physicians' knowledge. *Adv Med Educ Pract.* 2017;8:475-480.
33. Sufan W, Lei P, Hua W, Hangyan S, Ye Z, Yu J, Haifeng Z. Anatomic study of ophthalmic artery embolism following cosmetic injection. *J Craniofac Surg.* 2017;28(6):1578-1581.
34. Heydenrych I, Kapoor KM, De Boule K, et al. A 10-point plan for avoiding hyaluronic acid dermal filler-related complications during facial aesthetic procedures and algorithms for management. *Clin Cosmet Investig Dermatol.* 2018;11:603-611.
35. Popper K. Conjectures and refutations. Edited: London: Routledge and Keagan Paul, 1963, pp. 33-39.
36. Birner J. Karl Popper's the poverty of historicism after 60 years. *Metascience.* 2018;27(2):183-193.
37. Chatrath V, Banerjee PS, Goodman GJ, Rahman E. Soft-tissue filler-associated blindness: a systematic review of case reports and case series. *Plast Reconstr Surg Glob Open.* 2019;7(4):e2173.
38. Surek C, Beut J, Stephens R, Lamb J, Jelks G. Volumizing viaducts of the midface: defining the Beut techniques. *Aesthet Surg J.* 2015;35(2):121-134.
39. Pavicic T, Webb KL, Frank K, Gotkin RH, Tamura B, Cotofana S. Arterial wall penetration forces in needles versus cannulas. *Plast Reconstr Surg.* 2019;143(3):504e-512e.
40. Thanasarnaksorn W, Cotofana S, Rudolph C, Kraissak P, Chanasumon N, Suwanchinda A. Severe vision loss caused by cosmetic filler augmentation: case series with review of cause and therapy. *J Cosmet Dermatol.* 2018;17(5):712-718.
41. Jiang X, Liu DL, Chen B. Middle temporal vein: a fatal hazard in injection cosmetic surgery for temple augmentation. *JAMA Facial Plast Surg.* 2014;16(3):227-229.

# AESTHETIC SURGERY JOURNAL

// The ASJ in-house team, editorial board, staff, and reviewers are incredibly engaged and committed; they have successfully combined the utmost in professionalism with friendliness to create a close relationship with readers and authors. ASJ is so valuable because of its excellent peer review process. The success of this comprehensive quality control is evident in the rapidly increasing relevance of ASJ in the aesthetic surgery community. Case in point: In 2011, the journal had an Impact Factor of 1.469; increased to 3.480 in 2018. As one of the most awarded journals for education, members of the Norwegian Society of Aesthetic Plastic Surgery have been delighted by the introduction of ASJ to our community, especially given our collaboration with the American Society for Aesthetic Plastic Surgery. I am grateful to Dr. Foad Nahai for bringing the journal to the world and for bringing the world to the journal. //

Dr. Amin Kalaaji, MD, PhD, *Specialist in Plastic Surgery, President, Norwegian Society of Aesthetic Plastic Surgery, Oslo Plastic Surgery Clinic, Oslo, Norway*



 @ASJrnl
  Aesthetic Surgery Journal
  Aesthetic Surgery Journal
  aestheticsurgeryjournal\_asj

[academic.oup.com/asj](http://academic.oup.com/asj)

**OXFORD**  
UNIVERSITY PRESS