

A Comparison of the Quality of Sleep between Pre and Post-Surgery Cervical Herniated Nucleus Pulposus Patients Utilizing the Anterior Discectomy Method

Ridha Dharmajaya^{1*}, Dina Keumala Sari², Ratna Akbari Ganie

¹Neurosurgery Department, Universitas Sumatera Utara, Indonesia; ²Nutrition Department, Universitas Sumatera Utara, Indonesia; ³Clinical Pathology Department, Universitas Sumatera Utara, Indonesia

Abstract

Citation: Dharmajaya R, Sari DK, Ganie RA. A Comparison of the Quality of Sleep between Pre and Post-Surgery Cervical Herniated Nucleus Pulposus Patients Utilizing the Anterior Discectomy Method. Open Access Maced J Med Sci. 2017 Dec 15; 5(7):948-954. https://doi.org/10.3889/oamjms.2017.209

Keywords: Quality of sleep; Cervical herniated nucleus pulposus; Anterior discectomy operation.

***Correspondence:** Ridha Dharmajaya, Universitas Sumatera Utara, Indonesia. E-mail: ridha@usu.ac.id

Received: 24-Aug-2017; **Revised:** 24-Sep-2017; **Accepted:** 29-Sep-2017; **Online first:** 10-Dec-2017

Copyright: © 2017 Ridha Dharmajaya, Dina Keumala Sari, Ratna Akbari Ganie. This is an open-access article distributed under the terms of the Creative Commons Attribution-NonCommercial 4.0 International License (CC BY-NC 4.0).

Funding: This research did not receive any financial support.

Competing Interests: The authors have declared that no competing interests exist.

BACKGROUND: Herniated Nucleus Pulposus (HNP) is the prolapse of the intervertebral disk through a tear in the annulus fibrosus. This causes nerve root compression with clinical pain manifestation and affects the quality of sleep.

AIM: The aim of this study was find out the comparison in the quality of sleep between before (pre) and after (post) surgery cervical HNP patients.

METHODS: This study was a retrospective cohort study. Ninety patients were asked to complete the Pittsburgh Sleep Quality Index (PSQI) questionnaire. All data which has been computed were analysed with the McNemar test.

RESULT: The outcome reveals that from 90 patient's cervical HNP, 81 (90%) were 40 years old age group and 66 (73.3%) of them were women. The result showed that 66 (73.3%) patients have a bad sleep quality before surgery. Surgery has increased the quality of sleep after surgery 66 (73.3%) patients had good sleep quality. There was a significant difference in the quality of sleep pre and post operation ($p = 0.001$).

CONCLUSION: There was a significant difference in the quality of sleep between pre and post operation cervical HNP patient utilising anterior discectomy methods.

Introduction

Herniated Nucleus Pulposus (HNP) is the prolapse of the intervertebral disk through a tear in the annulus fibrosus which causes nerve root compression [1-3]. Prevalence of HNP is 1-2% of world population, and generally, HNP can occur at all vertebrae level from cervical until lumbar spine, eighty percent of HNP is lumbar HNP, and 20% is cervical HNP [4-6]. Sixty percent of age group with cervical HNP are 90-40 years old, and its prevalence is more often in males than females [7].

The most common cause of a cervical herniated nucleus pulposus is gradual degeneration of the disc, attenuation (weakening) of the posterior annulus fibrosis, and subsequent protrusion of the nucleus pulposus into the spinal canal causing

compression of the nerve root [8, 9]. The disc injury occurs suddenly because of an accident or trauma, another cause of cervical herniated nucleus pulposus is low vitamin D level [10, 11]. Higher prevalence of vitamin D level found in Indonesian women which most of them also had polymorphism of vitamin D receptor gene, TaqI and BsmI [12, 13].

Vitamin D deficiency associated to polymorphism of vitamin D receptor gene that the t allele of vitamin D receptor TaqI is associated with a high risk of degenerative disc disease and disc bulge developing, especially in individuals younger than 40 years [14, 15]. Most of the women had polymorphism of vitamin D receptor gene, TaqI and BsmI, related to vitamin D deficiency in urban and rural areas [15, 16]. Besides vitamin D deficiency, obesity also the cause of recurrent hernia nucleus pulposus. The previous study reported that obesity was a strong and

independent predictor of recurrent HNP after lumbar microdiscectomy. Surgeons should incorporate weight loss counselling into their preoperative discussions with patients [17].

Cervical HNP clinical manifestation is a radiated pain from the neck to the upper extremities (arm). Pain can be worse in several positions such as neck extension, ipsilateral rotation and lateral flexion. The feel of pain in the neck can make the quality of sleep worsen [17, 18]. Cervical HNP treated with conservative and surgery therapy, and in the early stage, conservative therapy can be done to decrease symptoms, but in the concluding stage, surgery therapy has to be carried out [19]. Surgery will be performed if the conservative therapy fails or if the patients have myelopathy signs and symptoms. Myelopathy signs and symptoms are paresthesia/paresis and urinated-defecated-sexual disorders [17,20].

The gold standard for diagnosed Cervical HNP is with Magnetic Resonance Imaging (MRI), especially T2 sequence [21]. It showed the position of the spinal cord, whether there is a compression of the surrounding tissue, bone and cartilage to the spinal cord or not [21, 22]. The gold standard in the majority of the studies confirming the presence of a herniated disc was cross-sectional imaging and or surgery. The gold standard in the diagnosis is surgery; however, when assessing the validity of subjective complaints or physical examination findings, use of cross-sectional imaging as a gold standard may be considered an acceptable substitute. The validity of surgery as a gold standard can be questioned, however, as findings at surgery can be subjective [21-23].

The treatment for a cervical herniated disc almost always begins with a trial of conservative treatment, which is frequently effective [24]. Surgical intervention is considered when a patient with a cervical herniated nucleus pulposus continues to have pain, weakness, and or numbness and has failed conservative modalities [24, 25]. The goal of surgery is to remove the compression from the spinal cord and or spinal nerves to improve a patient's pain and level of function [22]. The preferred surgical treatment is an anterior cervical discectomy and fusion.

Every disease with pain symptoms, mental disorders (anxiety or depression) can also cause sleep disorders [26]. During recovery, the patient needs some more sleep and energy but can be disturbed with uncomfortable symptoms like pain [26, 27]. The difficulty or lack of sleep during a patient's post-operation will inhibit the healing process [27]. The time of sleep is a time for cell regeneration, if the post-operative patients cannot sleep, the cell can not regenerate completely [26-29]. There were many patients with cervical HNP rejected to do the operation because of misunderstanding about this problem [30].

Based on this problem, the researchers were

interested in comparing the quality of sleep during the pre-operation and post-operation cervical HNP patient utilising the anterior discectomy methods. The aimed of this study also for better understand about risk factor of HNP and pain for better management.

Methods

The study method is an observational study with retrospective analyses at the Adenin Adenan Hospital, Medan City, North Sumatera Province, Indonesia. The inclusion criteria are post-operative, where the cervical HNP patient utilising anterior discectomy methods and the data were collected in August 2014 until December 2016. The exclusion criteria were, the patients with another disease which cause disability and organ failure, and also unreachable patients or not willing patients to be subject. Data were directly from the subjects who were interviewed with the quality of sleep questionnaire, Pittsburgh Sleep Quality Index (PSQI) [31]. The result of this study was based on the questionnaire scores, if the score is greater than five the result is bad, but if the score is lower than or equal to 5 the result is good.

Surgical technique

The author used anterior discectomy before total disc replacement (TDR) placement in patients with a herniated disc. The herniated disc material was removed anteriorly in conjunction with preparing the disc space for TDR placement in this study. Using this technique of performing an anterior-based complete discectomy, it may remove the herniated disc fragment and successfully decompress the canal contents without having to reenter the canal through a previously operated area while minimising the revision decompression risks, eliminating the offending herniation. A similar technique has been described for anterior lumbar interbody fusion. A combination of curette and punch Kerrison rongeur can be used to take down the posterior longitudinal ligament and allow direct visualisation and nerve hook access into the epidural space [32-34].

Sample Measurement and Examination

The Pittsburgh Sleep Quality Index (PSQI) was the instrument used to evaluate the quality of sleep in adults. The PSQI questionnaire consists of nine self-questions and five questions of sleep partner. The PSQI scoring 7 component quality of sleep, the range of scores was 0 (not difficult) until 3 (very difficult). Summarize total component score (range 0-21), if total score outcomes < 5, the result is

good and if total score outcomes > 5, the quality of sleep result is bad [31].

The data were collected by the researchers through direct interview utilising the PSQI questionnaire. Every patient was asked ten questions each, and their answers were used to measure the quality of sleep during pre-operative and post-operative utilising the anterior discectomy method. Each patient obtained two qualities of sleep data, pre- and post-operative data.

Body mass index (BMI) included height (to the nearest 0.5 cm), weight (to the nearest 0.1 kg) and calculated as kg/m². Categorized BMI was based on Asia Pacific, < 18.5 classified as underweight, 18.5-22.9 classified as normoweight, 23-24.9 classified as overweight/at risk, 25-29.9 classified as obese I, and >30 classified as obese II [35].

Statistic Analytic

Power calculation and estimation of sample size were based on the primary outcome measure of the trial. Data are presented as mean and one standard deviation (SD) or as number and frequency (%). In the tabulation of data, McNemar statistic test was used to determine the difference between the quality of sleep during pre-operative and post-operative cervical HNP utilising anterior discectomy methods. The variable was nominal and ordinal variable with the category scale. Categorical data will be presented by the percentage. Level of significance was set at 5%, if the p-value < 0.05 then it means that any meaningful proportion has to differentiate between two group data. This study used SPSS (version 11.5; SPSS Inc, Chicago, IL) for data analysis.

Research Appropriateness

This study has passed the tests from Health Research Ethical Committee Medical Faculty of North Sumatera University, Medan City, North Sumatera with the number 98/TGL/KEPK FK USU-RSUP HAM/2016. Before participation, the subjects had to fill the approval sheet after they have gotten the explanation about the principal study, such as the aim, the examination, the advantages and the disadvantages of the study.

Results

Descriptive data are presented in Table 1, one hundred and two patients with cervical HNP has performed surgery utilising the anterior discectomy

methods from 2014 to 2016, twelve patients could not fulfil the inclusion criteria in this study, leaving ninety patients who formed the basis for this study as subjects. Mean of outpatient clinics each year were 30-40 patients, for three years data had been collected.

Table 1: Clinical data and outcome measures (n=90)

Variables	f (frequencies)	Percentage (%)
Gender		
• Male	24	26.7
• Female	66	73.3
Age (years)	53.97±11.04	
Age group		
• < 40 years old	9	10
• > 40 years old	81	90
Body mass index (kg/m ²)	25.8±3.9	
BMI classification		
• Underweight	-	-
• Normal	4	4.4
• Overweight	79	87.8
• Obese I	7	7.8
• Obese II	-	-
Main symptom		
• Axial pain only	36	40
• Axial pain < Radicular pain	39	43.3
• Axial pain = Radicular pain	15	16.7
Preoperative MRI findings		
• Protrusion	39	43.3
• Extrusion	48	53.3
• Stenosis	3	3.4

Data for age are expressed as mean±SD

In Table 1, the result of this study showed that two times higher prevalence of HNP found in female than male in this study. Almost of the study subjects were older than 40 years and higher percentage body mass index which the highest was overweight.

Table 2: Pre-post operative quality of sleep outcome

Parameters	Frequencies (f)	Percentage (%)
Quality of sleep (pre-operative)		
• Good	24	26.7
• Bad	66	73.3
Quality of sleep (post-operative)		
• Good	75	85
• Bad	15	15

Table 2 and Table 3 summarise the pre-operative quality of sleep outcome, 66 (73.3%) subjects have a bad quality of sleep, and 24 (26.7%) subjects have a good quality of sleep post-operative. Post-operative showed that higher percentage of good quality of sleep than bad quality of sleep with significant value (p < 0.005)

Table 3: Quality of sleep cross-tabulation with McNemar test

		Post Operative Quality of Sleep		TOTAL
		Good (> 50)	Bad (< 50)	
Pre Operative	Good (> 50)	21	3	24
Quality of Sleep	Bad (<50)	54	12	66
	TOTAL	75	15	90
McNemar Test				0,001

All these subjects showed compression, using Magnetic Resonance Imaging (MRI) T2 sequence of HNP patients showed compression of the spinal canal, for cervical it would compress the spinal cord.

Nucleus pulposus of the disc would come out through the wall of the disc, filled the spinal canal and compress the spinal cord (Fig. 1).

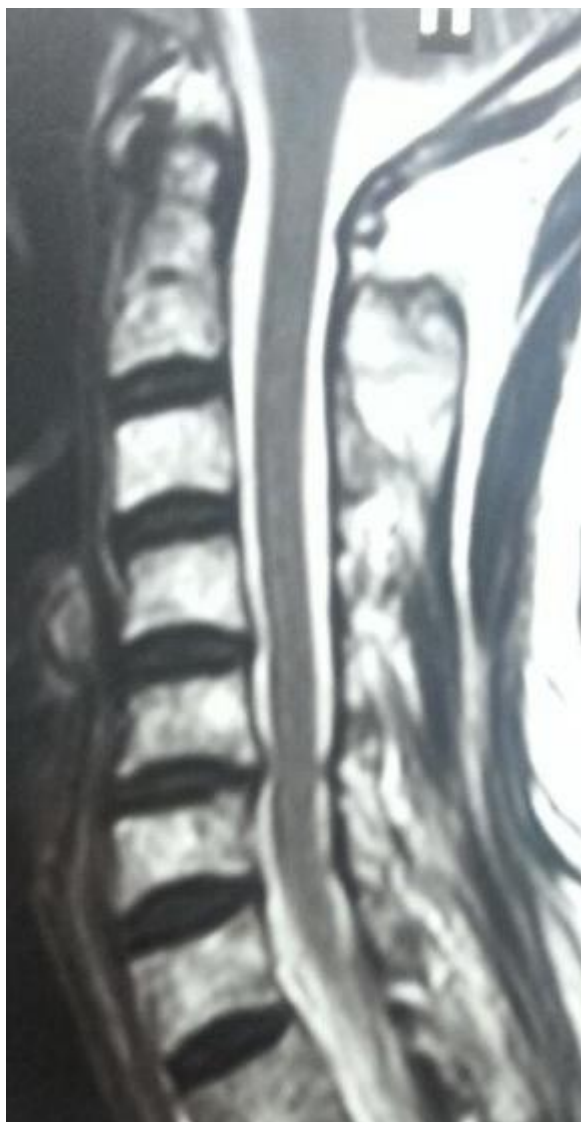

Figure 1: Magnetic Resonance Imaging T2 sequence of cervical spine, showed compression of spinal cord at C 5-6 level

Discussion

The study demonstrated that there is a different quality of sleep between before and after cervical HNP surgery utilising anterior discectomy methods, quality of sleep is important to be given careful consideration, as it affects the postoperative recovery substantially. Post-operative anterior discectomy methods offered the significantly better quality of sleep than pre-operative, which led to a significantly shorter stay in the hospital [36]. However, this effect was almost exclusively attributed to a significantly lower consumption of opioids postoperatively and sleeping pills [37-39]. As shown in

this study, quality of sleep post-operative is a feature that influences the recovery.

Anterior cervical discectomy and fusion is a simple surgery procedure with low risk and short duration [40,41]. This procedure which was used in this study, good effect of intraoperative vertebral reduction and well-recovered function after the operation. After skin incision in a linear fashion at large line, platysma was open with sharp and blunt dissection. Retracted the neck muscle such as sternocleidomastoid, omohyoid, sternohyoid muscle and retracted trachea and thyroid to lateral and find the cervical spine bone. Recognised the level of the spine with needle marker and C-arm then starts discectomy (Fig. 2). Finished the discectomy and made fusion, using an autologous bone graft or titanium cage or polyetheretherketone (PEEK) [36]. This study used autologous bone graft taken from the hip of the patient.

In this study, women had a higher prevalence of HNP than men, probably due to vitamin D deficiency that will affect calcium serum in the circulation [12, 13]. Low vitamin D and calcium serum were the caused of osteoporosis, a metabolic bone disorder characterised by low bone mass and microarchitectural deterioration, with a subsequent increase in bone fragility and susceptibility to fracture [42]. The risk factor of vitamin D deficiency was a lifestyle, such as avoiding sunlight exposure and polymorphism of vitamin D receptor (VDR) gene was the cause of vitamin D deficiency [13, 15].

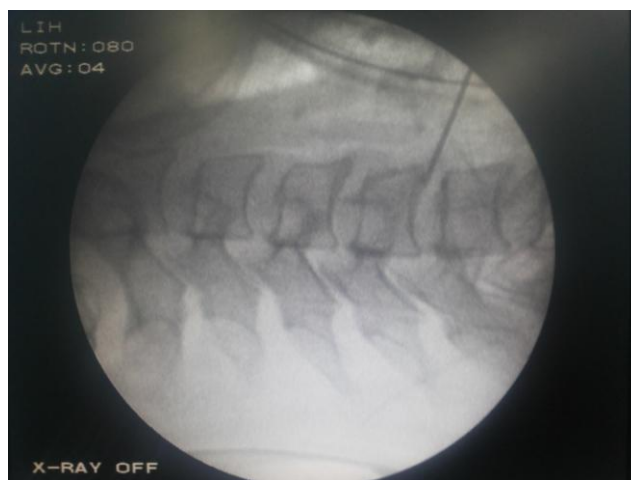


Figure 2: Radiological X-Ray view by C-Arm with needle marker

Vitamin D deficiency-insufficiency was found in healthy women with TaqI and BsmI single nucleotide polymorphisms in the VDR gene [15, 16]. Vitamin D deficiency and insufficiency are associated with increased risk of osteoporosis, poorer muscle function, low bone mass, and microarchitectural deterioration, with a subsequent increase in bone fragility and susceptibility to fracture [42]. The previous study showed that the TaqI polymorphism of vitamin D receptor gene is associated with the

development of degenerative disc disease in the lumbar spine with an odds ratio (OR) of 2.61 [14].

Aging had to correlate to HNP occurrence, in this study shows the result that the age group of the HNP patients was more than forty years older than the youngest or equal. It was appropriated with the other study results that more often HNP patients were between the age groups of 40 and 50 years old [43, 44]. This is because, the ageing process of the intervertebral disc, starts with the disc inflexibility, the lack of elasticity of the nucleus pulposus and disc degeneration [45]. Also, because of the repeated trauma on the intervertebral disc and tear of the annulus fibrosus [45-47].

The relative body weight gains the first day after surgery was an independent risk factor for bad quality of sleep in the present study [48]. But, in this study we did not assess the body weight gain, only body weight pre-operative. The relative body weight gain may be an effect of the increased release of stress hormones and inflammatory processes and thus may represent an increased stress response [49].

Degenerative disk disease can be particularly seen in overweight patients with greater BMI [49, 50]. Studies have demonstrated a probable correlation between obesity and lumbar spine related disorders, most likely secondary to increasing biomechanical stress in the lower thoracic and lumbar spine. Open spinal surgery in obese patients is associated with longer operative times, larger blood loss, and increased perioperative morbidity [51, 52].

Most studies have shown that postoperative pain perception can be affected by sleep disturbance producing a hyperalgesic state [37-39]. However, from this study particularly in the pre-operative period where the pain was the predominant cause of sleep disturbance, it is a pain which leads to sleep disturbance and that while a hyperalgesic state may be exacerbated by poor sleep, it is an initial pain that starts this process and consuming sleeping pills.

Previous studies showed that there were several factors contribute to disturbed sleep postoperatively [37-39, 53]. Use of opioids has been shown to change sleep architecture substantially in healthy subjects [38, 53]. The injury caused by surgery provokes a complex stress response involving the release of stress hormones, humoral mediators of the endocrine and metabolic system, and activation of the immune system [38, 39, 53].

Based on the results from this study, a conclusion can be drawn that there was a significantly different quality of sleep between the pre- and post-operation using anterior discectomy methods; that was due to the symptom of cervical HNP before surgery. The quality of sleep before surgery is bad and after surgery significantly changed for the better. Pain is the most common symptom of cervical HNP

and one of the prevalence causes of sleep disorders in adults. Surgery is the definitive therapy for cervical HNP because it will decrease the symptoms and provide a better quality of sleep than before. This was appropriated with this study result that those patients who performed surgery will have better feelings of pain, functional pleasure and healing process than non-surgery therapy.

There are some methodological concerns in this study; the study was not powered to detect differences in other secondary outcome measures such as time operation, time of anaesthesia, and using sleeping pills. Also, this was not a randomised controlled trial. Therefore this study is seen as exploratory and hypothesis generating.

Recommendations were the doctors should do a follow-up with patients before and after surgery and patient with bad quality of sleep needs support from family and people around because cervical HNP can affect many aspects of life. There is a need for health workers and the society to be educated about cervical HNP to enhance early diagnosis.

References

1. Chung SK, Kim YE, Wang KC. Biomechanical effect of constraint in lumbar total disc replacement: a study with finite element analysis. *Spine*. 2009; 34:1281-6. <https://doi.org/10.1097/BRS.0b013e3181a4ec2d> PMID:19455003
2. Madhok R, Kanter A. Extreme-lateral, minimally invasive, a transpoas approach for the treatment of far-lateral lumbar disc herniation. *J Neurosurg Spine*. 2010; 12: 347-50.
3. Borendal Wodlin N, Nilsson L, Kjølhed P. Health-related quality of life and postoperative recovery in fast track hysterectomy. *Acta Obstet Gynecol Scand*. 2011; 90:362-8. <https://doi.org/10.1111/j.1600-0412.2010.01058.x> PMID:21306322
4. DeLucca JF, Cortes DH, Jacobs NT, Vresilovic EJ, Duncan RD, Elliot DM. Human cartilage endplate permeability varies with degeneration and intervertebral disc site. *Journal of Biomechanics*. 2016; 49: 550-7. <https://doi.org/10.1016/j.jbiomech.2016.01.007> PMID:26874969 PMCID:PMC4779374
5. Krutko AV, Baykov ES, Sadovoy MA. Reoperation after microdiscectomy of lumbar herniation: Case report. *Int J of Surg Case Rep*. 2016; 24: 119-23. <https://doi.org/10.1016/j.ijscr.2016.04.043> PMID:27236580 PMCID:PMC4887591
6. Hammer C, Heller J, Kepler C. Epidemiology and pathophysiology of cervical disc herniation. *Semin Spine Surg*. 2016; 28(2): 64-7.
7. Jordan J, Konstantiniou K, O'Dowd J. Herniated lumbar disc. *BMJ Clin Evid*. 2009; 1118. PMID:19445754
8. Bowles RD, Setton LA. Biomaterials for intervertebral disc regeneration and repair. *Biomaterial*. 2017; 129: 154-67.
9. Hu B, Wang J, Wu X, Chen Y, Yuan W, Chen H. Interleukin-17 upregulates vascular endothelial growth factor by activating the JAK/STAT pathway in nucleus pulposus cells. *Join Bone Spine*. 2017; 84: 327-34.
10. Mayer JE, Iatridis JC, Chan D, Qureshi SA, Gottesman O, Hecht AC. Genetic polymorphisms associated with intervertebral disc degeneration. *Spine J*. 2013; 13: 299-317.

11. Boden SD. Spinescope. *Semin Spine Surg.* 2013; 25: 295–300.
12. Sari DK, Damanik HA, Lipoeto NI, Lubis Z. Occurrence of Vitamin D Deficiency among Woman in North Sumatera, Indonesia. *Malaysian J Nutr.* 2014;20:63–70.
13. Sari DK, Tala ZZ, Lestari S, Hutagalung S, Ganie RA. Vitamin D Supplementation in Women with Vitamin D Receptor Gene Polymorphisms: A Randomized Controlled Trial. *Asian J Clin Nutr.* 2017; 9(2):89–96.
14. Kenneth C, Danny C, Jaro K, Yiquin C, Jeffrey JT, Shea-Ping Y, et al. Association of the Taq I Allele in Vitamin D Receptor With Degenerative Disc Disease and Disc Bulge in a Chinese Population. *Spine.* 2006; 31 (10): 1143–48.
15. Sari DK, Tala ZZ, Lestari S, Hutagalung S, Ganie RA. Vitamin D receptor gene polymorphism among Indonesian women in North Sumatera. *Asian J Clin Nutr.* 2017; 9(1):44–50.
16. Sari DK, Tala ZZ, Lestari S, Hutagalung S, Ganie RA. Lifestyle differences in rural and urban areas affected the level of vitamin D in women with single nucleotide polymorphism in North Sumatera. *Asian J Clin Nutr.* 2017; 9(2):57–63.
17. Yeung JT, Johnson JI, Karim AS. Cervical disc herniation presenting with neck pain and contralateral symptoms. *J of Med Case Reports.* 2012; 6: 166. <https://doi.org/10.1186/1752-1947-6-166> PMID:22741922 PMCid:PMC3411405
18. Mart M, Rozenberg S, Duplan B, et al. Quality of sleep in patients with chronic low back pain. *Eur Spine J.* 2008;839–44.
19. Pirris S, Dhall S, Mummaneni P, Dhall S, Kanter AS. Minimally invasive approach to extraforaminal disc herniations at the lumbosacral junction using an operating microscope: case series and review of the literature. *Neurosurg Focus.* 2008; 25:E10. <https://doi.org/10.3171/FOC/2008/25/8/E10> PMID:18673039
20. Manchikanti L, Singh V, Calodney AK, Helm S 2nd, Deer TR, Benyamin RM et al. Percutaneous lumbar mechanical disc decompression utilizing Dekompressor®: an update of current evidence. *Pain Physician.* 2013; 16 (2Suppl): SE1–24.
21. Galluci M, Limbuci M, Paonessa A, Splendiani A. Degenerative disease of the spine. *Neuroima Neuroimag Clin N Am.* 2007; 17: 87–103. <https://doi.org/10.1016/j.nic.2007.01.002> PMID:17493541
22. Kelekis AD, Filippiadis DK, Martin JB, Broutzos E. Standards of practice: quality assurance guidelines for percutaneous treatments of intervertebral discs. *Cardiovasc Intervent Radiol.* 2010; 33(5): 909–13. <https://doi.org/10.1007/s00270-010-9952-5> PMID:20676639
23. Kelekis A, Filippiadis D. Percutaneous therapy versus surgery in chronic back pain: how important is imaging in decision-making? *Imaging Med.* 2013; 5(2): 187–96. <https://doi.org/10.2217/iim.13.15>
24. Nguyen C, Sanchez K, Roren A, Palazzo C, Falcou L, Drape J, et al. Anatomical specificities of the degenerated cervical spine: a narrative review of clinical implications, with special focus on targeted spinal injections. *Annals of Physic and Rehab Med.* 2016; 59: 276–81. <https://doi.org/10.1016/j.rehab.2015.12.006> PMID:26904960
25. Chi JH, Tay B, Stahl D, Lee R. Complex Deformities of the Cervical Spine. *Neurosurg Clin N Am.* 2007; 18: 295–304. <https://doi.org/10.1016/j.nec.2007.01.003> PMID:17556131
26. Freedman MK, Overton EA, Saulino MF, Horlding MY, Kornbluth ID. Interventions in chronic pain management. *Arch Phys Med Rehabil.* 2008; 89 Suppl 1: S41–6.
27. Roy-Byrne PP, Davidson KW, Kessler RC, Asmundson GJG, Goodwin RD, Kubzansky L. Anxiety disorders and comorbid medical illness. *Gen Hosp Psy.* 2008; 30: 208–25. <https://doi.org/10.1016/j.genhosppsych.2007.12.006> PMID:18433653
28. Zarrabian MM, Johnson M, Kriellaars D. Relationship Between Sleep, Pain, and Disability in Patients With Spinal Pathology. *Arch of Physic Med and Rehab.* 2014; 95:1504–9.
29. Durand G, Girodon J, Debais F. Medical management of failed back surgery syndrome in Europe: Evaluation modalities and treatment proposals. *Neurochirurgie.* 2015; 61: S57–S65. <https://doi.org/10.1016/j.neuchi.2015.01.001> PMID:25676909
30. Asmundson GJ, Katz J. Understanding the co-occurrence of anxiety disorders and chronic pain: state-of-the-art. *Depress Anxiety.* 2009; 26 (10): 888–901.
31. Mollayeva T, Thurairajah P, Burton K, Mollayeva S, Shapiro CM, Colantonio A. The Pittsburgh sleep quality index as a screening tool for sleep dysfunction in clinical and non-clinical samples: A systematic review and meta-analysis. *Sleep Med Rev.* 2016; 25: 52–73.
32. Salame K, Lidar Z. Minimally invasive approach to far lateral lumbar disc herniation: technique and clinical results. *Acta Neurochir (Wien).* 2010; 152: 663–8.
33. Cole JS 4th, Jackson TR. Minimally invasive lumbar discectomy in obese patients. *Neurosurgery.* 2007; 61:539–44. <https://doi.org/10.1227/01.NEU.0000290900.23190.C9> PMID:17881966
34. Kim JM, Lee SH, Ahn Y, et al. Recurrence after successful percutaneous endoscopic lumbar discectomy. *Minim Invasive Neurosurg.* 2007; 50: 82–5. <https://doi.org/10.1055/s-2007-982504> PMID:17674293
35. Gill T. Epidemiology and health impact of obesity: an Asia Pacific perspective. *Asia Pac J Clin Nutr.* 2006; 15 (Suppl): 3–14.
36. Lemcke J, Al-Zain F, Meier U, Suess O. Polyetheretherketone (PEEK) Spacers for Anterior Cervical Fusion: A Retrospective Comparative Effectiveness Clinical Trial. *Open Orthop J.* 2011; 5:348–53.
37. Dimsdale JE, Norman D, DeJardin D, Wallace MS. The effect of opioids on sleep architecture. *J Clin Sleep Med.* 2007; 3:33–6. PMID:17557450
38. Kjølhede P, Langström P, Nillson P, Wodlin NB, Nillson L. The Impact of Quality of Sleep on Recovery from Fast-Track Abdominal Hysterectomy. *J Clin Sleep Med.* 2012; 8(4):395–402.
39. Schuh-Hofer S, Wodarski R, Pfau DB, Caspani O, Magerl W, Kennedy JD. One night of total sleep deprivation promotes a state of generalized hyperalgesia: a surrogate pain model to study the relationship of insomnia and pain. *Pain.* 2013;154(9):1613–21. <https://doi.org/10.1016/j.pain.2013.04.046> PMID:23707287
40. Glenn JS, Yaker J, Guyer RD, Ohnmeiss DD. Anterior discectomy and total disc replacement for three patients with multiple recurrent lumbar disc herniations. *The Spine J.* 2011;11:e1–e6. <https://doi.org/10.1016/j.spinee.2011.07.030> PMID:21907631
41. Marcus JD, James AR, Härtl R. Minimally Invasive Surgical Treatment Options for Lumbar Disc Herniations and Stenosis. *Semin Spine Surg.* 2011; 23:20–6.
42. Sari DK, Tala ZZ, Lestari S, Hutagalung S, Ganie RA. Body mass index but not 25(OH)D serum is associated with bone mineral density among Indonesian women in North Sumatera: a cross sectional study. *Asian J Clin Nutr.* 2017; 9(1):37–43.
43. Amoretti N, Huwart L, Marcy PY, Foti P, Hauger O, Boileau P. CT- and fluoroscopy-guided percutaneous discectomy for lumbar radiculopathy related to disc herniation: a comparative prospective study comparing lateral to medial herniated discs. *Skeletal Radiol.* 2013; 42: 1:49–53. <https://doi.org/10.1007/s00256-012-1422-5> PMID:22644540
44. Yar T. Spinal shrinkage as a measure of spinal loading in male Saudi University students and its relationship with body mass index. *Saudi Med J.* 2008; 29: 1453–7. PMID:18946572
45. Kaito T, Hosono N, Mukai Y, et al. Induction of early degeneration of the adjacent segment after posterior lumbar interbody fusion by excessive distraction of lumbar disc space. *J Neurosurg Spine.* 2010; 12:671–9. <https://doi.org/10.3171/2009.12.SPINE08823> PMID:20515354
46. Botolin S, Puttlitz C, Baldini T, et al. Facet joint biomechanics at the treated and adjacent levels after total disc replacement. *Spine.* 2011; 36: E27–32. <https://doi.org/10.1097/BRS.0b013e3181d2d071> PMID:20975623

47. Leahy M, Zigler JE, Ohnmeiss DD, et al. Comparison of results of total disc replacement in postdiscectomy patients versus patients with no previous lumbar surgery. *Spine*. 2008; 33:1690–3. <https://doi.org/10.1097/BRS.0b013e31817bd2f0> PMID:18580740
48. Meredith DS, Huang RC, Nguyen J, Lyman S. Obesity increases the risk of recurrent herniated nucleus pulposus after lumbar microdiscectomy. *The Spine J*. 2010; 10:575–80.
49. Gilleard W, Smith T. Effect of obesity on posture and hip joint moments during a standing task, and trunk forward flexion motion. *Int J Obes*. 2007; 31:267–71. <https://doi.org/10.1038/sj.ijo.0803430> PMID:16801923
50. Olsen MA, Nepple JJ, Riew KD, Lenke LG, Bridwell KH, Mayfield J, Fraser VJ, et al. Risk factors for surgical site infection following orthopaedic spinal operations. *J Bone Joint Surg Am*. 2008; 90:62–9. <https://doi.org/10.2106/JBJS.F.01515> PMID:18171958
51. Park P, Upadhyaya C, Garton HJ, Foley KT. The impact of minimally invasive spine surgery on perioperative complications in overweight or obese patients. *Neurosurgery*. 2008; 62:693–9. <https://doi.org/10.1227/01.neu.0000317318.33365.f1> PMID:18425016
52. Cole JS 4th, Jackson TR. Minimally invasive lumbar discectomy in obese patients. *Neurosurgery*. 2007; 61:539–44. <https://doi.org/10.1227/01.NEU.0000290900.23190.C9> PMID:17881966
53. Chouchou F, Khoury S, Chauny JM, Denis R, Lavigne GJ. Postoperative sleep disruptions: a potential catalyst of acute pain? *Sleep Med Rev*. 2014; 18(3):273–82. <https://doi.org/10.1016/j.smrv.2013.07.002> PMID:24074687