




Review Article

Evolution of patients with surgically treated drug-resistant occipital lobe epilepsy

Pablo Barbero Aznarez¹, Marta Pastor Cabeza², Ana Sofia Alvarez Quintana¹, Monica Lara-Almunia¹, Julio Albisua Sanchez¹

¹Department of Neurosurgery, Jimenez Diaz Foundation University Hospital, Madrid, ²Department of Neurosurgery, Germans Trias i Pujol Hospital, Badalona, Catalonia, Spain.

E-mail: *Pablo Barbero Aznarez - pbaabp@hotmail.com; Marta Pastor Cabeza - marta_pastor21@hotmail.com; Ana Sofia Alvarez Quintana - ana.aquintana@fjd.es; Monica Lara-Almunia - mnclr23@gmail.com; Julio Albisua Sanchez - jalbisua@quironosalud.es



***Corresponding author:**

Pablo Barbero Aznarez,
Department of Neurosurgery,
Jimenez Diaz Foundation
University Hospital, Madrid,
Spain.

pbaabp@hotmail.com

Received : 06 May 2020

Accepted : 14 July 2020

Published : 01 August 2020

DOI

10.25259/SNI_251_2020

Quick Response Code:



ABSTRACT

Background: This study was to describe the evolution of patients who underwent surgical treatment of drug-resistant occipital lobe epilepsy (OLE) at our institution.

Methods: We performed a retrospective analysis of data collected from electronic and paper clinical records of 20 patients who were diagnosed of OLE and underwent epilepsy surgery at our institution between 1998 and 2018. We also contacted patients by telephone and asked them to fill out a questionnaire about quality of life in epilepsy (QOLIE-10). Assembled data were analyzed using descriptive statistics.

Results: The age at surgery ranged between 19 and 55 years. The period encompassing epilepsy onset and the date of surgery was variable. Semiology of seizures included visual symptoms in 75% of patients. In 90% of cases subdural grids, depth electrodes or a combination of both were used to plan the surgery. The most frequent neuroimaging and histopathological finding was cortical dysplasia (55%). The postoperative follow-up period was up to 15 years. The most common score on the Engel scale was I (70%). Visual deficits increased after surgery. Median score on QOLIE-10 questionnaire was 82.5 (interquartile range: 32.5).

Conclusion: Surgical treatment of drug-resistant OLE offers hopeful results to those patients who have run out of pharmacological options and leads to postoperative deficits that are deemed expectable and occasionally acceptable.

Keywords: Engel, Focal epilepsy, Occipital, Quality of life in epilepsy inventory-10, Surgery

INTRODUCTION

Occipital epilepsy is a relatively non-frequent entity that constitutes 5–10% of cases of focal epilepsy. Its etiology is attributed to a wide spectrum of causes, including metabolic, structural, neoplastic, traumatic, infectious, and idiopathic processes.^[8] Typically, this type of epilepsy has been associated with the appearance of visual symptoms (e.g., visual hallucinations, campimetric defects, transient amaurosis or eye movement sensation, among others) and occipital abnormalities in the electroencephalogram (EEG), although these findings are not present in all patients and their absence does not rule out the diagnosis.^[1] In certain cases, this pathology can be manifested by altered level of consciousness and/or generalized tonic-clonic activity. This semiology is due to the fact that the seizures originated in the posterior cerebral cortex can spread

This is an open-access article distributed under the terms of the Creative Commons Attribution-Non Commercial-Share Alike 4.0 License, which allows others to remix, tweak, and build upon the work non-commercially, as long as the author is credited and the new creations are licensed under the identical terms.

©2020 Published by Scientific Scholar on behalf of Surgical Neurology International

rapidly to other cortical areas, giving symptoms more related to the diffusion zone of the crisis than to its origin.^[2] Proof of this is that in up to 50% of cases of occipital epilepsy appear temporal or frontal motor seizures, which complicates the diagnosis of this entity.^[4]

This intrinsic difficulty in diagnosis is increased by the fact that the surface EEG is often ineffective or unclear when it comes to locating the origin of the seizures.^[16] Some studies attribute the low localization values of the surface EEG to the high prevalence of extensive (79%) and bilateral (29%) epileptogenic foci in this pathology, as well as to the anatomical position of the occipital lobe at the base of the brain and its multiple connections with other brain areas.^[8,13] The limitations associated with surface electrodes highlight the importance of using more invasive monitoring methods (such as subdural and/or depth electrodes) and neuroimaging tests when diagnosing and characterizing this type of epilepsy anatomically.

The estimation of medically intractable epilepsy in people with epilepsy is over 30%.^[12] In those patients in whom antiepileptic drugs (AED) fail to reduce the frequency of seizures, surgery has been established as a therapeutic alternative with good results and favorable morbidity and mortality rates. Previous studies in individuals with surgically treated temporal lobe epilepsy (the most common surgically treated epilepsy), refer to crisis-free patient rates around 60–80%.^[3,8] Compared to temporal epilepsy, occipital epilepsy is much less common and therefore relatively underestimated. To date, there is no randomized clinical trial on the surgical treatment of occipital epilepsy and the available case series show a significant results variability, due to their small sample size and the heterogeneity of their patients.^[8,11]

An important aspect when considering surgical treatment in occipital epilepsy is that, due to the anatomical proximity to the visual cortex, this procedure has been associated with an increased risk of postoperative visual deficits. Previous studies suggest that more than 50% of patients experience some type of visual defect after surgery.^[8] The patient's visual status and the degree of postoperative visual deficit that is considered acceptable should therefore be discussed between patient and surgeon before the intervention.^[11]

The objective of this study is to describe the evolution of a sample of 20 patients diagnosed and operated on drug-resistant occipital epilepsy.

MATERIALS AND METHODS

Population of study

The population of our study is made up of all patients diagnosed with drug-resistant occipital epilepsy who underwent surgery at our institution between 1998 and

2018. To delimit this sample, we initially performed a review of the Epilepsy Unit database and selected those patients that met the following criteria: (1) clinical semiology and/or electroencephalographic activity (ictal and/or interictal) compatible with occipital epilepsy; (2) refractory epilepsy despite the prescription and proper taking of AEDs; and (3) surgical resection in the occipital lobe. Of the total number of patients included in the database, we identified 20 individuals who met the criteria. The presurgical evaluation of these patients included: Clinical history, neurological examination, neuropsychological evaluation, monitoring with ictal and/or interictal video-EEG, campimetry, magnetic resonance imaging (MRI) and, in a high percentage of cases, invasive monitoring with subdural and/or depth electrodes.

Data collection

Once the study population was established, data were collected. The main sources of information were the patient medical records (both electronic and paper) and phone interviews. The sample variables evaluated were the following: sex, age, family and personal history, consumption and dose of pre- and post-surgical AEDs, affected hemisphere, age of epilepsy, duration of epilepsy until surgery, frequency of previous crisis before surgery, type of crisis, semiology of the seizures, findings in the neurological examination and neuropsychological evaluation, findings in brain MRI, type of electroencephalographic monitoring and findings in ictal and/or interictal EEG, findings in the pre- and post-surgical imaging, surgical technique, histopathological findings, postsurgical complications, follow-up time (in years), result of surgery (assessed by Engel classification),^[7] and score on the quality of life in epilepsy inventory-10 (QOLIE-10) quality of life questionnaire.^[15] This study has been carried out with the approval of the Ethics Committee of our hospital and the Ethics Subcommittee of the Faculty of Medicine of our university.

QOLIE-10

The QOLIE-10 is a validated and specific quality of life questionnaire for epilepsy. It consists of 10 questions, each of which is assigned a score from 1 to 5 depending on the patient's response. The total points obtained are weighted by means of a formula that allows us to assess the results with a maximum of 100 points. High scores reflect a good quality of life.

Statistics

Given the number of patients included in the study, the analysis of the data obtained was performed by descriptive statistics. In this type of statistical analysis, qualitative variables are expressed through percentages and quantitative variables

through measures of central tendency and dispersion, such as mean and standard deviation or median and interquartile range (IQR). Considering the asymmetric distribution of our sample, the quantitative variables are expressed by median and IQR.

RESULTS

Demographic and clinical characteristics

The demographic and clinical characteristics of the patients are shown in [Table 1]. Of the 20 patients included in the

study, 12 (60%) were women and eight (40%) were men, with a median age at surgery of 30.5 years (IQR: 14.5). The median duration of epilepsy before the intervention was 19 years (IQR: 9). The affected hemisphere was the right one in 10 patients and the left in the remaining 10. The frequency of presurgery seizures was high in all patients, with a median of 12 crises per month (IQR: 20.75). Of interest, two patients (10%) had been operated before the current intervention: one of them for an astrocytoma and another for dysplasia.

Table 1: Demographic characteristics, semiology, and campimetry.

#	Sex/age	Duration (years)	Semiology	Optic campimetry
1	F/21	18	Screaming, fixed gaze, non-reactivity, sucking, chewing, stiffness of upper limbs, falling	-
2	F/35	19	Aura of fear. Amaurosis in both eyes or micropsia	-
3	F/25	19	Temporal. Ascending epigastric aura, orofacial and upper limb automatisms	-
4	F/33	10	Visual (color triangle) and auditory aura (music), thoracic oppression	-
5	M/18	7	Fixed gaze, non-reactivity; pelvic, trunk and lower limbs uncoordinated movements	-
6	M/55	55	Right generalized stiffness	Normal
7	M/19	17	Non-reactivity, upward gaze, vision loss, short phrases and mouth deviation to the left	-
8	M/55	55	Clonic eye movements, followed by paresthesias and clonic movements of the left hemibody	-
9	M/19	17	Runs for refuge, disconnection, holding breath. Well-formed but meaningless phrases, can manipulate with both hands but more to the right, sucking	Left hemianopsia
10	F/26	23	Cloudy view, fixed-glaze, non-reactivity, oculocephalic deviation to the left, sucking	Left inferior homonymous quadrantanopia
11	F/36	26	Photopsias. Deja-vu. Decrease of the visual field from the left until it disappears, epigastric sensation, nausea, disconnection, sucking	Normal
12	M/23	21	Colored stars in the center of the visual field. Weakness and convulsions in the left limbs	Temporal partial hemianopsia
13	F/27	18	Spiral in the center of the visual field, cloudy view	-
14	M/24	21	Visual aura, deja vu, incoherent language, swallowing, manual automatisms	Right inferior homonymous quadrantanopia
15	F/45	33	Feeling of seeing things in the left visual field that is not able to describe, generalized stiffness, fixed gaze, non-reactivity, falling	-
16	F/33	16	-	-
17	M/28	24	Spatial distortion, anxiety, fixed gaze, manual automatisms	-
18	M/40	16	White flashes in the right visual field, oculocephalic deviation to the right, generalized seizures	Scotoma with minor respect of central area
19	F/40	30	Guttural sounds, blurred vision ± disconnection and manual automatisms. Cephalic torsion, clonic seizures in the right upper limb, dystonia in the lower left limb, tonic-clonic seizures	Homonymous quadrantanopia
20	F/22	10	Colored spots that move from one field to another, depersonalization, vertigo, immobilization, searching with hands, disorientation, strange behavior	Right homonymous hemianopsia
21	F/41	26	Disconnection, fixed glaze, oral, and manual automatisms. Thoracic oppression that sometimes spread to the head, choking sensation, and anxiety	-
22	F/34	5	Disconnection, words changing, English-Spanish mixture (± ascending heat and head pressure). Eyes wide open, snorting. Horizontal lines in the right visual field	Normal

In presurgical neuropsychological evaluation, five patients (25%) presented with significant alterations: four (20%) had a low IQ and one (5%) presented heminegligence. Regarding presurgical visual function, we only found information available in this regard in 10 patients (50%). Of these 10 patients, three (15%) had a preserved visual function, three (15%) had quadrantanopia, three (15%) had hemianopsia, and one patient (5%) had a central scotoma due to retinal dystrophy.

The type of seizures described was very variable: seven patients (35%) presented complex partial and partially generalized seizures, five patients (25%) presented simple partial and complex partial seizures (focal in the ILAE classification, five patients (25%) presented complex partial seizures, one patient (5%) had simple partial seizures, one patient (5%) had simple and secondarily generalized partial seizures, and one patient (5%) had simple, complex, and secondarily generalized partial seizures (partial means focal in the International League Against Epilepsy classification).^[14]

Regarding the semiology of the seizures, 15 of the 20 patients (75%) had visual auras or some type of visual symptom during crisis. Some symptoms described in these patients were: amaurosis, micropsia, upward gaze, photopsia, blurred vision, and among others. A high percentage of patients experienced altered level of consciousness (50%) and orofacial and/or manual automatisms (50%), symptoms suggestive of spreading epileptogenic focus to the temporal region. In 35% of patients, tonic activity and/or hyperactive automatisms were observed, suggesting spread to the frontal lobe. Two patients (10%) had generalized tonic-clonic seizures.

Electroencephalographic findings

The results of electroencephalographic monitoring and other findings related to the diagnosis and follow-up of patients are shown in [Table 2].

As part of the presurgical evaluation, a video-EEG with surface electrodes was performed in all patients and a ictal and/or

interictal electroencephalographic record was obtained. Ictal EEG showed epileptiform activity in several locations: occipital in eight patients (40%), occipitotemporal in three patients (15%), posterior temporal in three patients (15%), parietal in three patients (15%), temporal in one patient (5%), and temporoparietooccipital in one patient (5%). In one case, the findings obtained were inconclusive. In patients with available interictal EEG, it found activity at occipitotemporal level in 50% of cases, posterior temporal in 25% of cases and occipital in 25%.

Invasive monitoring

It was considered necessary to perform an intracranial EEG in 18 of 20 patients (90%) to correctly locate the epileptogenic area and plan the surgery. About 65% of these records were made by subdural electrodes, 10% by depth electrodes, and 15% by a combination of subdural and depth electrodes.

Neuroimaging

Presurgical MRI revealed lesions in all patients included in the study. The most frequent finding was cortical dysplasia, present in 11 of 20 patients (55%). The next most frequent finding was encephalomalacia, present in three patients (15%). In the remaining patients, the following lesions were observed: one ischemic lesion (5%), one neoplasia (5%), one cortical atrophy (5%), one tuberous sclerosis (5%), one arteriovenous malformation (AVM) treated with embolization (5%), and one cavernoma (5%).

Surgical technique

The extent of the surgery was determined individually according to the findings obtained in the presurgical MRI and the ictal and/or interictal EEG. In 14 patients (70%), a regional (spatially extensive) resection was performed while in the remaining six (30%) a lesionectomy was performed. In [Figures 1 and 2], the case of two patients included in

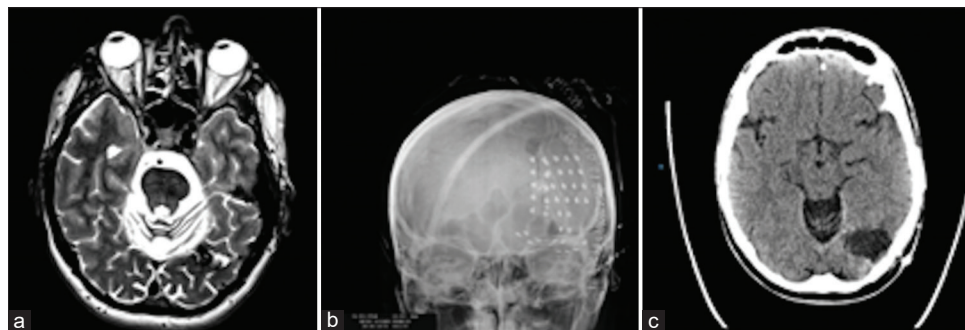


Figure 1: Forty-year-old patient with epilepsy for 16 years consisting of simple, complex, and secondarily generalized partial seizures with visual aura. (a) Axial presurgical brain magnetic resonance imaging scan showing an arteriovenous malformation treated with embolization in the left occipital region. (b) Simple skull radiograph showing the arrangement of the subdural grid electrode. (c) Axial postsurgical cranial CT scan showing a left occipital lesionectomy. After surgery, the patient rarely presents crisis (Engel Class II). Postoperatively, he had an absolute scotoma with slight respect of the central area.

Table 2: Clinical characteristics and outcomes.

#	Ictal EEG	Invasive monitoring	Brain MIR	Histopathology	Postsurgical campimetry	Follow-up (years)	Engel	QOLIE-10
1	Left parietal	No	Polymicrogyria, left cerebellar hypoplasia	Occipital dysraphism	-	6	IVC	-
2	Right temporoparietotoccipital	Subdural electrodes	Posttraumatic lesion/dysplasia/temporo-occipital cortical tumor	Cortical dysplasia	Left homonymous hemianopsia	5	IA	45
3	Right parietal	Subdural electrodes	Right posterior temporal cortical dysplasia	Cortical dysplasia	-	15	IIB	57.5
4	Left occipital	Subdural electrodes	Cortical dysplasia	Cortical dysplasia	-	5	ID	95
5	Left occipital	Subdural electrodes	Dysplastic interhemispheric fissure	Unspecific changes	Inferior right homonymous quadrantanopsia	14	IA	85
6	Right parietal	Subdural electrodes	Right parietal subcortical ischemic residual lesion	Cortical dysplasia	-	14	IA	82.5
7	Right posterior temporal	Subdural electrodes	Right temporo-occipital cortical dysplasia	Cortical dysplasia	Left hemianopsia	2	IA	92.5
8	Occipital right	Subdural electrodes	Right occipital craniotomy with underlying residual malacic cavity	Cortical dysplasia	-	7	IA	92.5
9	Posterior temporal right	No	Right medial temporo-occipital tumor	Ganglioglioma-gangliocytoma	Normal	3	IVA	-
10	Right occipital	Subdural electrodes	Right occipital cortical atrophy	Isomorphic gliosis	Temporal hemianopsia	8	IA	-
11	Left occipital	Subdural electrodes	Interhemispheric dysplasia	Cortical dysplasia	Right homonymous hemianopsia	11	ID	95
12	Left occipital	Subdural electrodes	Left parieto-occipital encephalomalacia	Ischemic gliotic lesion	Right homonymous hemianopsia	1	IA	-
13	Inconclusive	Subdural electrodes	Focal right occipital parasagittal cortical dysplasia	Cortical dysplasia	-	3	IIIA	80
14	Left temporo-occipital	Subdural and deep electrodes	Possible dysplasia/heterotopia in left temporo-occipital region	Cortical dysplasia	-	3	IVB	80
15	Right temporal	Subdural and deep electrodes	Cortical-subcortical tubers	Cortical tubers	Left homonymous hemianopsia	0.5	IB	-
16	Left occipital	Subdural electrodes	Right basal occipital AVM treated with embolization	AVM with signs of embolization	Scotoma	3	IIC	87.5

(Contd...)

Table 2: (Continued)

#	Ictal EEG	Invasive monitoring	Brain MIR	Histopathology	Postsurgical campimetry	Follow-up (years)	Engel	QOLIE-10
17	Left temporo-occipital	Subdural and deep electrodes	Left temporo-occipital cortico-subcortical dysplasia	Cortical dysplasia	Homonymous quadrantanopsia	3	IA	90
18	Left occipital	Subdural electrodes	Right cortico-subcortical dysplasia	Nodular ectopy	-	8	IA	72.5
19	Right occipito-temporal	Deep electrodes	Left temporo-occipital cavernoma	Cortical dysplasia	Homonymous hemianopsia	2	IA	60
20	Left posterior temporal	Deep electrodes		Cavernous angioma	-	1	IA	60

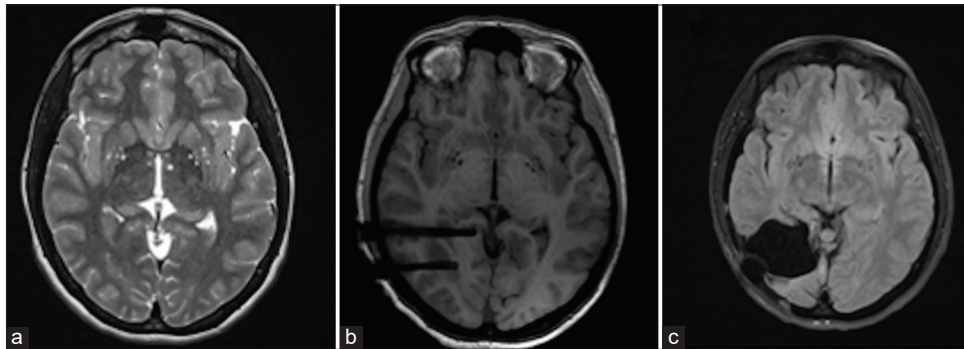


Figure 2: Forty-one-year-old patient with epilepsy for 26 years consisting of complex partial seizures and secondarily generalized with temporal semiology. (a) Axial presurgical brain magnetic resonance imaging (MRI) scan showing dysplasia (arrow) in the right occipito-temporal region. (b) Axial cerebral MRI section showing the arrangement of the depth electrodes. (c) Axial postsurgical brain MRI section showing right occipito-temporal regional resection. After surgery, the patient was free of crisis (Engel Class I). Postoperatively, she becomes hemianopic.

the study is presented and the type of surgical resection performed in each of them is shown.

Histopathological findings

The most frequent histopathological finding was, in accordance with MRI, cortical dysplasia, present in 11 of the 20 patients (55%). The next most frequent histopathological finding was gliosis, present in two patients (10%). In the remaining cases, the pathology provided the following results: one dysraphism (5%), one ganglioglioma-gangliocytoma (5%), one nodular ectopia (5%), one tuberous sclerosis (5%), one AVM treated with embolization (5%), one cavernoma (5%), and nonspecific findings (5%).

SURGERY RESULTS

The median postoperative follow-up time was 4 years (IQR: 5.5). The intervention results were evaluated by means of the Engel classification: 14 patients (70%) were

free of disabling seizures (Engel Class I) (11 patients (55%) were Class IA). Two patients (10%) rarely present crippling seizures (Engel Class II), one patient (5%) improved significantly (Engel Class III), and three patients (15%) did not experience significant improvement (Engel Class IV). At least, none of these three patients had visual loss after surgery.

The surgery allowed reducing the number of AEDs in 10 patients (50%). After the intervention, five patients (25%) presented complications, including: (1) cranial osteomyelitis episode; (2) deafferentation disorder and mild hemiparesis; (3) mild sensory dysphasia and semantic paraphasias or anomia; (4) episodes of “flashes” when falling asleep; and (5) bleeding from a pontine cavernoma.

Regarding the postsurgical visual function, we only found information available in this regard in 11 patients (55%) probably due to loss of old clinical records. Of these 11 patients, one (5%) had a preserved visual function, seven (35%) had hemianopsia, two (10%) had quadrantanopia, and

one (5%) had a scotoma due to retinal dystrophy (already detected in presurgical campimetry).

QOLIE-10

To get the score of the questionnaire in our patients, we contacted them by phone, obtaining an answer in 15 of the 20 patients (25% non-responders). The median score obtained in our sample was 82.5 (IQR: 32.5).

DISCUSSION

This study reflects our experience with a series of 20 patients operated on drug-refractory occipital epilepsy. Fifteen of the 20 patients (75%) had auras or visual symptoms, corroborating the relationship between visual symptomatology and this type of epilepsy. Likewise, a high percentage of patients presented temporal and/or frontal semiology in the form of orofacial and/or manual automatisms and tonic-clonic activity, reflecting the rapid diffusion capacity of occipital crises. Analyzing these clinical characteristics, we can conclude that the population of our study was quite representative of occipital epilepsy in terms of semiology.

One of the main obstacles in the management of occipital lobe epilepsy (OLE) is the difficulty in accurately identifying the epileptogenic focus. In this type of epilepsy, the surface EEG has proven to be of limited utility in this regard. Previous studies have shown that in OLE, the most common electroencephalographic finding is not paroxysmal activity in the occipital lobe, but the presence of spike-waves in the temporal lobe. Occasionally, this finding can lead to an erroneous diagnosis of temporal epilepsy.^[8] According to these data, in our study, the ictal surface EEG located the epileptogenic focus at a purely occipital level in less than half of the cases and suggested involvement of the temporal lobe in 40% of the seizures.

Given the limitations associated with surface EEG, the use of invasive techniques (such as depth and subdural electrodes) is a common practice in the diagnosis of this type of epilepsy. This is corroborated by the fact that 90% of patients included in our study required invasive monitoring. In relation to the surgical results obtained, 14 of the 18 individuals (77.77%) undergoing invasive monitoring obtained a Class I Engel, while those two patients in whom this procedure was not carried out obtained an Engel of IV (we have to state that these two patients had a ganglioglioma and a dermal sinus, respectively, with complete resection of both. We think that several groups would have considered direct surgery without invasive monitoring in these cases). These findings highlight the importance of this type of monitoring in patients with OLE.

MRI is another tool that has facilitated the identification of occipital lesions. The finding of an MRI lesion is a factor

that contributes essentially to reaching a diagnosis of occipital epilepsy and is usually linked to a favorable surgical outcome.^[16] In our study, 100% of the patients presented lesions in the presurgical MRI. This fact has been decisive in the type of surgical approach performed (centered on the lesion) and in the proportion of patients who have been free of seizures after intervention.

We have used invasive diagnostics in 90% of the patients, although we have found a putative epileptogenic lesion in all patients. We think the use of invasive diagnostics changed our strategy. However, we performed in 30% of the patients lesionectomy, which is a surgical procedure almost completely guided by the MRI imaging, because surface EEG has poor localizing and predictive value and to reduce the surgery failure rate due to sampling error. Besides, there can be occipital plus epilepsies and swift propagation to anterior regions.^[13]

The results obtained in our series (70% of seizure-free patients) are in a range similar to the results reported in recent surgical series^[9] and confirm that surgery is an effective therapy for the treatment of epilepsy drug-resistant occipital. Likewise, the high scores obtained in the QOLIE-10 questionnaire suggest that patients maintain a good quality of life after the intervention. We did not perform a preoperative assessment of quality of life. However, Chaturvedi *et al.*^[5] reported mean preoperative quality of life score of 24.92 and a postoperative score of 83.97. The score they used, QOLIE-89 is also out of a 100 as in the one we used, QOLIE-10. We have a postoperative QOLIE score of 82.5.

Certain authors suggest that the result of surgery may be correlated with certain types of pathologies.^[6] The most frequent histopathological finding in our series of patients was cortical dysplasia (55%), in accordance with recent surgical series. Eight of the 11 patients (72.72%) with cortical dysplasia were free of seizures after the intervention (Engel Class I). These data corroborate what has been described in previous studies, in which there has been a tendency to obtain favorable results in patients with cortical development malformations.^[10]

One of the main concerns related to OLE surgery is its ability to produce new visual defects or aggravate pre-existing defects.^[4] In our study, 45% of patients experienced new or aggravated visual defects after the intervention. This increase in the number of visual deficits is in accordance with what is referred to by other studies to date and confirms the importance of informing the patient about the possibility of experiencing impairment of visual function after the intervention. It is important to note, however, that this possibility may be acceptable to the patient if the surgery turns out to be effective in eliminating seizures.

Due to the high risk of death and disability related to medically intractable epilepsy, a visual field deficit is a

reasonable compromise if there is a reasonable opportunity for seizure freedom. Of course the patient and family are the decision makers; therefore, the potential of visual field deficit dominates the conversation between surgeon and patient/family when discussing surgery for OLE. One point in this regard is that laser ablation is becoming the preferred treatment approach for focal cortical dysplasia in the occipital lobe due to the highly selective nature of the treatment and greatest likelihood of preserving visual radiation fibers. Nevertheless, this technique is not yet available in our hospital.

This study has certain limitations that should be considered. First, the sample size of our study is small, and the patients included in it have a high heterogeneity. These limitations have prevented us from carrying out an inferential statistical analysis, so we have not been able to establish a correlation between the evaluated variables and the results of surgery or postsurgical visual function. Second, our study is a retrospective study, so we have not been able to access certain information related to the clinical record and the findings in the diagnostic tests of the patients. This fact is an essential limitation in the evaluation of the visual function of the patients before and after the intervention since the pre- and post-surgical campimetries were only available in 50% and 55% of the cases, respectively. Besides seizure outcome, one of the most important issues concerning resections for OLE is the neurological outcome in terms of visual field deficits. Unfortunately, preoperative visual field data were available in only 10 patients. Furthermore, postoperative visual field data were available also in only 11 patients.

CONCLUSION

Occipital epilepsy is an uncommon type of focal epilepsy. Visual symptoms and occipital abnormalities in the EEG are suggestive findings of this pathology, although they are not present in all patients. Imaging tests and invasive monitoring have an essential role in the diagnosis and characterization of this entity. In patients with drug-resistant occipital epilepsy, surgery is a therapeutic modality to consider, with which favorable results are obtained. In our case series, 70% of patients were free of seizures and presented a good quality of life after surgery, as suggested by the high scores in the QOLIE-10 questionnaire. In accordance with previous studies, a significant percentage of patients experienced the appearance or aggravation of visual deficits after surgery. However, visual deficits after occipital lobe surgery are expected and the patient is counseled and understands that the visual field deficit is acceptable to have an opportunity for seizure freedom.

Ethical approval

This study was carried under the approval of the Ethics Committee of our center and the Ethics Subcommittee of

the Faculty of Medicine of our university in accordance with the 1964 Helsinki declaration and its later amendments or comparable ethical standards. As a retrospective study, formal consent is not required. This article does not contain any studies with animals performed by any of the authors.

Declaration of patient consent

Institutional Review Board permission obtained for the study.

Financial support and sponsorship

Nil.

Conflicts of interest

There are no conflicts of interest.

REFERENCES

1. Appel S, Sharan AD, Tracy JI, Evans J, Sperling MR. A comparison of occipital and temporal lobe epilepsies. *Acta Neurol Scand* 2015;132:284-90.
2. Barba C, Doglietto F, De Luca L, Faraca G, Marra C, Meglio M, *et al.* Retrospective analysis of variables favoring good surgical outcome in posterior epilepsies. *J Neurol* 2005;252:465-72.
3. Bekelis K, Desai A, Kotlyar A, Thadani V, Jobst BC, Bujarski K, *et al.* Occipitotemporal hippocampal depth electrodes in intracranial epilepsy monitoring: Safety and utility. *J Neurosurg* 2013;118:345-52.
4. Binder DK, Von Lehe M, Kral T, Bien CG, Urbach H, Schramm J, *et al.* Surgical treatment of occipital lobe epilepsy. *J Neurosurg* 2008;109:57-69.
5. Chaturvedi J, Rao MB, Arivazhagan A, Sinha S, Mahadevan A, Chowdary MR, *et al.* Epilepsy surgery for focal cortical dysplasia: Seizure and quality of life (QOLIE-89) outcomes. *Neurol India* 2018;66:1655-66.
6. Dalmagro CL, Bianchin MM, Velasco TR, Alexandre V Jr., Walz R, Terra-Bustamante VC, *et al.* Clinical features of patients with posterior cortex epilepsies and predictors of surgical outcome. *Epilepsia* 2005;46:1442-9.
7. Engel J Jr., Van Ness PC, Rasmussen TB, Ojemann LM. Outcome with respect to epileptic seizures. In: Engel J Jr., editor. *Surgical Treatment of Epilepsies*. New York: Raven Press; 1993. p. 609-21.
8. Harward SC, Chen WC, Rolston JD, Haglund MM, Englot DJ. Seizure outcomes in occipital lobe and posterior quadrant epilepsy surgery: A systematic review and meta-analysis. *Neurosurgery* 2017;82:350-8.
9. Heo W, Kim JS, Chung CK, Lee SK. Relationship between cortical resection and visual function after occipital lobe epilepsy surgery. *J Neurosurg* 2017;129:524-32.
10. Jehi LE, O'Dwyer R, Najm I, Alexopoulos A, Bingaman W. A longitudinal study of surgical outcome and its determinants following posterior cortex epilepsy surgery. *Epilepsia* 2009;50:2040-52.

11. Joswig H, Girvin JP, Blume WT, Burneo JG, Steven DA. Awake perimetry testing for occipital epilepsy surgery. *J Neurosurg* 2017;129:1195-9.
12. Kwan P, Brodie MJ. Early identification of refractory epilepsy. *N Engl J Med* 2000;342:314-9.
13. Marchi A, Bonini F, Lagarde S, McGonigal A, Gavaret M, Scavarda D, *et al.* Occipital and occipital plus epilepsies: A study of involved epileptogenic networks through EEG quantification. *Epilepsy Behav* 2016;62:104-14.
14. Scheffer IE, Berkovic S, Capovilla G, Connolly MB, French J, Guilhoto L, *et al.* ILAE classification of the epilepsies: Position paper of the ILAE commission for classification and terminology. *Epilepsia* 2017;58:512-21.
15. Viteri C, Codina M, Cobaleda S, Lahuerta J, Barriga J, Barrera S, *et al.* Validation of the Spanish version of the QOLIE-10 quality of life in epilepsy questionnaire. *Neurologia* 2008;23:157-67.
16. Yang P, Jia Y, Lin Q, Mei Z, Chen Z, Zheng Z, *et al.* Intractable occipital lobe epilepsy: Clinical characteristics, surgical treatment, and a systematic review of the literature. *Acta Neurochir (Wien)* 2015;157:63-75.

How to cite this article: Barbero Aznarez P, Pastor Cabeza M, Alvarez Quintana AS, Lara-Almunia M, Albusua Sanchez J. Evolution of patients with surgically treated drug-resistant occipital lobe epilepsy. *Surg Neurol Int* 2020;11:222.