








Original Article



Patients with Isolated Focal Right Ventricular Dyskinetic Segments: Toward a Better Understanding of This Cohort

Mohamad Jihad Mansour , MD^{1,2,*}, Omar Hamoui , MD^{2,*}, Joseph Asmar , MD¹, Elie Chammas , MD^{1,2}, Wadiah Ayoub , MD², Jihad Daher , MD³, and Wael A. AlJaroudi , MD²

OPEN ACCESS

Received: Nov 28, 2018

Revised: Jan 17, 2019

Accepted: Feb 6, 2019

Address for Correspondence:

Wael A. AlJaroudi, MD

Division of Cardiovascular Medicine,
Clemenceau Medical Center, PO Box 11-2555,
Clemenceau Street, Beirut, Lebanon.
E-mail: wjaroudi@hotmail.com

*Mohamad Jihad Mansour and Omar Hamoui contributed equally.

Copyright © 2019 Korean Society of
Echocardiography

This is an Open Access article distributed
under the terms of the Creative Commons
Attribution Non-Commercial License (<https://creativecommons.org/licenses/by-nc/4.0/>)
which permits unrestricted non-commercial
use, distribution, and reproduction in any
medium, provided the original work is properly
cited.

ORCID iDs

Mohamad Jihad Mansour 
<https://orcid.org/0000-0003-4184-275X>
Omar Hamoui 
<https://orcid.org/0000-0001-9939-5660>
Joseph Asmar 
<https://orcid.org/0000-0002-8833-7964>
Elie Chammas 
<https://orcid.org/0000-0002-1025-5424>
Wadiah Ayoub 
<https://orcid.org/0000-0002-1758-4298>
Jihad Daher 
<https://orcid.org/0000-0001-5285-3986>
Wael A. AlJaroudi 
<https://orcid.org/0000-0003-0890-4437>

¹Division of Cardiology, Faculty of Medical Sciences, Lebanese University, Hadath, Lebanon

²Division of Cardiovascular Medicine, Clemenceau Medical Center, Beirut, Lebanon

³Department of Radiology, Clemenceau Medical Center, Beirut, Lebanon

ABSTRACT

BACKGROUND: The 2010 revised Task Force criteria for the diagnosis of arrhythmogenic right ventricular cardiomyopathy (ARVC) provided guidance for the classification of patients as definitive, borderline or possible ARVC. However, many patients with clinical suspicion for ARVC have isolated RV dyskinetic segments only and partly meet cardiac magnetic resonance (CMR) imaging criteria. This subgroup of patients and the implication of this imaging finding remain not well defined.

METHODS: There were 65 consecutive patients with clinical suspicion for ARVC who were referred for CMR between 2015 and 2017. The presence of fatty infiltration and fibrosis were assessed using T2 imaging and myocardial delayed enhancement sequences, respectively. RV wall motions, volumes and ejection fraction (EF) of all patients were re-analysed and quantified. Available data on family history, Holter findings, and electrocardiograms were also reviewed.

RESULTS: There were 5 patients (7.7%) that fulfilled major CMR criteria for ARVC: 4 were classified as having definitive ARVC; and 1/5 as borderline. There were 33 patients with no RV dyskinetic segments: none were classified as having definitive or borderline ARVC; 4/33 were classified as possible ARVC, leaving 29/33 as normal or no ARVC. Finally, there were 27 remaining patients (41.5%) with isolated RV dyskinetic segments: 1/27 was classified as definitive ARVC; 4/27 as borderline; 8/27 as possible; leaving 15/27 as indeterminate. Compared to control, those with isolated RV dyskinesia (including the subgroup labelled as indeterminate 15/27) had more abnormal RVEF, larger RV end-diastolic volume index (82 ± 12 mL/m² vs. 72 ± 12 mL/m², p-value 0.0127), and a trend for higher odds of dilated RV (odds ratio 3.0 [0.81-11], p-value 0.09).

CONCLUSIONS: Among patients with a clinical suspicion for ARVC, almost 40% had isolated focal RV dyskinetic segments with the majority remaining unclassified. This cohort had more RV dilation and abnormal EF compared to control.

Keywords: Arrhythmogenic right ventricular cardiomyopathy; Minor; Indeterminate criteria; Dyskinetic segments; Cardiac magnetic resonance

Conflict of Interest

The authors have no financial conflicts of interest.

INTRODUCTION

Arrhythmogenic right ventricular cardiomyopathy (ARVC) is a rare inherited genetic disorder characterized by the replacement of the right ventricular (RV) myocardium with fibro-fatty layers, resulting in structural abnormalities, regional dyskinesia, ventricular arrhythmia and often sudden cardiac death.^{1,2)} The diagnosis of ARVC is classified as definitive, borderline or possible, based on major and minor criteria which take into account structure, function, family history, histology, documented arrhythmia and electrocardiogram (ECG) abnormalities.^{3,4)} Cardiac magnetic resonance (CMR) is considered one of the gold standard imaging modalities to detect RV dyskinetic segments, quantify RV volumes and ejection fraction (EF). In comparison to echocardiography, CMR is not limited by acoustic windows, can image the RV in any plane, and provides accurate and reproducible quantitative volumes and functional assessment, in addition to tissue characterization such as intramyocardial fat and myocardial fibrosis.⁵⁾

However, many patients with palpitation and arrhythmia have only focal dyskinetic segments with normal RV volume and/or EF. It is unclear whether these are non-specific findings, part of the spectrum of the disease, or precursor for ARVC detected early because of early screening.⁶⁾ Their clinical implication and prognosis are also unknown.

Our study aims at assessing those patients with isolated focal RV dyskinesia, compare them to a control group and those who meet definitive criteria for ARVC, in a better attempt to characterize them.

METHODS**Study population**

From the CMR database at Clemenceau Medical Center, Beirut, Lebanon, the charts of 65 consecutive patients who were imaged between July 2015 and September 2017 with clinical suspicion for ARVC, were extracted and reviewed for final analysis. Patients were referred because of clinical symptoms, family history of sudden cardiac death, suspicious ECG, high premature ventricular contraction burden, non-sustained or sustained ventricular tachycardia on 24 hours Holter, that meet some criteria for ARVC based on the 2010 revised Task Force criteria (TFC) (**Table 1**).⁴⁾

There were no patients with ischemic heart disease, dilated cardiomyopathy, congenital heart disease and/or insufficient axial or short axis cine images for exclusion. Demographics and indication of CMR testing were prospectively entered at the time of testing and were subsequently retrieved from the reports for analysis. The study was approved by the Institutional Review Board committee with waiver of consent and complied with the Declaration of Helsinki.

CMR imaging

CMR was performed on all patients with suspected diagnosis of ARVC, using 3.0 Tesla GE MR scanner (Discovery™ MR750w GEM 70 cm, Milwaukee, Wisconsin, USA). RV wall motion analysis was assessed using standard FIESTA cine sequences for axial, short-axis, 2, 3 and 4-chamber views (slice thickness 8.0 mm, TE minimum, flip angle 45°, bandwidth 125 Hz, NEX 1.0). The presence of fatty infiltration was assessed using T2 imaging with and without

Table 1. Baseline characteristics stratified by presence or absence of RV dyskinetic segments by CMR

	All patients (N = 65)	Normal CMR (n = 33)	Isolated RV dyskinesia (n = 27)	RV dyskinesia meeting CMR criteria for ARVC (n = 5)	p-value
Demographics					
Age (years)	43 ± 15	41 ± 16	46 ± 15	46 ± 13	0.47
Male gender	44 (67.6)	21 (63.6)	18 (66.6)	5 (100)	0.25
Body surface area (m ²)	1.89 ± 0.21	1.87 ± 0.23	1.90 ± 0.19	1.92 ± 0.06	0.87
Clinical indications					
Palpitations	30 (46.2)	19 (57.6)	10 (37.0)	1 (20)	0.14
Dilated RV*	14 (21.5)	4 (12.1)	8 (29.6)	2 (40)	0.12
Presyncope/syncope	12 (18.5)	4 (12.1)	7 (26.0)	1 (20)	0.28
Chest pain	3 (4.6)	3 (9.1)	0 (0)	0 (0)	0.41
Dizziness	1 (1.5)	1 (3.0)	0 (0)	0 (0)	0.99
Family history	5 (7.7)	2 (6.1)	2 (7.4)	1 (20)	0.45
24 hours Holter ECG[†]					
Premature ventricular beats	33 (65)	18 (69)	14 (67)	1 (25)	0.25
Non-sustained VT	13 (25)	5 (19)	5 (24)	3 (75)	0.086
Other [‡]	5 (10)	3 (12)	2 (9)	0 (0)	0.99

ARVC: arrhythmogenic right ventricular cardiomyopathy, CMR: cardiac magnetic resonance, ECG: electrocardiogram, RV: right ventricle, VT: ventricular tachycardia. *dilated RV on echocardiography.

[†]Holter results were available for 51 patients (total) (26 with normal CMR, 21 with minor/indeterminate criteria, 4 with major criteria).

[‡]Other: epsilon wave, sinus tachycardia, supraventricular tachycardia, idioventricular rhythm and 2:1 AV block.

Data shown are number (%) not otherwise specified.

fat saturation (slice thickness 8.0 mm, TE 55 ms, auto refocus flip angle 107°, echo train length 25, blood suppression inversion time 648 ms, bandwidth 83.3 Hz, NEX 1.0). Delayed gadolinium enhancement analysis (slice thickness 8.0 mm, TE Min Full, flip angle 25°, inversion time 300-400 ms, bandwidth 41.7 Hz, NEX 1.0) was performed after intravenous injection of Omniscan's GE Healthcare Gadolinium-based contrast agent, administered with 40 mL saline flush at a dose of 0.15 mmol/kg.

Both axial and short axis images were used to assess for the presence of dyskinetic or aneurysmal segments. Quantitative analysis of RV volumes and EF was performed from the short axis cine stack images as recommended^(2,4) using GE workstation AW750w and the Cardiac VX software (cardiac analysis and reporting, software version 1.1.0, 2013, General Electric Company, Waukesha, Wisconsin, USA).

Major CMR criteria for ARVC were defined according to the 2010 revised TFC⁽⁴⁾ as: regional RV akinesia, dyskinesia or dyssynchronous contraction AND 1 of the following:

- RV end-diastolic volume indexed to body surface area ≥ 110 mL/m² (male) or ≥ 100 mL/m² (female).
- RV EF $\leq 40\%$.

Minor criteria were defined as regional RV akinesia, dyskinesia or dyssynchronous contraction AND 1 of the following:

- RV end-diastolic volume indexed to body surface area ≥ 100 to 110 mL/m² (male) or ≥ 90 to 100 mL/m² (female).
- RV EF $> 40\%$ to $\leq 45\%$.

The quantitative analysis and wall motion interpretation were performed by a single level III trained and experienced reader, who de-identified and re-read all 65 studies, and was blinded at the time of the reading to the detailed clinical available data (i.e. family history, results of the Holters and ECG) and whether the referred patients met any major or minor non-imaging criteria that could bias his interpretation.

Patients were classified as having no RV dyskinetic segments, those with RV dyskinesia and meet major CMR criteria for ARVC, and those with isolated RV dyskinesia.

Statistical analysis

Continuous variables were expressed as means (standard deviation) and compared by use of the unpaired Student t-test, Wilcoxon rank test or ANOVA as appropriate. Categorical variables were expressed as frequency (percentages) and compared by use of the Fisher exact test, Pearson chi-square test, or Kruskal-Wallis as appropriate. All statistical tests were 2-sided. A p-value < 0.05 was set a priori and considered statistically significant. All statistical analyses were performed with the SPSS Statistics version 22 (IBM Corp., Armonk, NY, USA).

RESULTS

The cohort consisted of 65 patients (mean age of 43 ± 15 years, 67.6% of males) who were referred for CMR with a clinical suspicion for ARVC. The most common indications for CMR were palpitations, abnormal echocardiogram, presyncope/syncope, and abnormal 24 hours Holter monitoring (**Table 1**).

There were 5 patients (7.7%) that fulfilled a major CMR criterion for ARVC: 4/5 were classified as having definitive ARVC; and 1/5 as borderline (based on the available family history, ECG and/or Holter findings) (**Table 1**). There were 33 patients (50.8%) with no RV dyskinetic segments (4/33 had mildly dilated RV thought to be most likely athletic heart, and all with preserved EF): none were classified as having definitive or borderline ARVC; 4/33 were classified as possible ARVC (based on other non-imaging minor criteria); leaving 29/33 as normal or no ARVC (**Tables 1 and 2**). Finally, there were 27 remaining patients (41.5%) with isolated RV dyskinetic segments (almost a third had mildly dilated RV and 15% with mildly reduced RVEF): 1/27 was classified as definitive ARVC; 4/27 as borderline; 8/27 as possible; leaving 15/27 as indeterminate (**Tables 1 and 2**).

Table 2. RV characteristics by CMR

	All patients (N = 65)	Normal CMR (n = 33)	Isolated RV dyskinesia (n = 27)	RV dyskinesia meeting CMR criteria for ARVC (n = 5)	p-value
RV EDVi (mL/m ²)	79 ± 19	72 ± 12	82 ± 18	114 ± 4	< 0.0001
RV EDVi (female, n = 21)					0.24
< 90 mL/m ²	20 (95)	12 (100)	8 (89)	0 (0)	
90–99 mL/m ²	1 (5)	0 (0)	1 (11)	0 (0)	
≥ 100 mL/m ²	0 (0)	0 (0)	0 (0)	0 (0)	
RV EDVi (male, n = 44)					< 0.0001
< 100 mL/m ²	28 (64)	17 (81)	11 (61)	0 (0)	
100–109 mL/m ²	11 (25)	4 (19)	7 (39)	0 (0)	
≥ 110 mL/m ²	5 (11)	0 (0)	0 (0)	5 (100)	
RV ejection fraction (%)	55 ± 7	57 ± 5	55 ± 7	41 ± 5	< 0.0001
RV ejection fraction					< 0.0001
≥ 46%	57 (88)	33 (100)	23 (85)	1 (20)	
41–45%	6 (9)	0 (0)	4 (15)	2 (40)	
≤ 40%	2 (3)	0 (0)	0 (0)	2 (40)	
Regional RV a/dyskinesia	32 (49.2)	0 (0)	27 (100)	5 (100)	< 0.0001
LGE in RV	5 (7.7)	0 (0)	1 (3.7)	4 (80)	< 0.0001
LV EDVi, mL/m ²	76 ± 15	74 ± 12	79 ± 19	71 ± 11	0.41
LV ejection fraction (%)	59 ± 6	58 ± 5	59 ± 6	60 ± 6	0.40
LGE in left ventricle	1 (1.5)	0 (0)	0 (0)	1 (20)	0.002

ARVC: arrhythmogenic right ventricular cardiomyopathy, CMR: cardiac magnetic resonance, EDVi: end-diastolic volume indexed to body surface area, LGE: late Gadolinium enhancement, LV: left ventricle, RV: right ventricle. Data shown are number (%) not otherwise specified.

Compared to patients with no RV dyskinetic segments, those with isolated RV dyskinesia (and similarly the subgroup labelled as indeterminate 15/27) had larger RV end-diastolic volume index ($82 \pm 12 \text{ mL/m}^2$ vs. $72 \pm 12 \text{ mL/m}^2$, p-value 0.0127), and a trend for higher odds of dilated RV (odds ratio 3.0 [0.81-11], p-value 0.09). No odds ratio could be calculated for RV EF since there were no abnormal EF in the control group.

DISCUSSION

The key findings of the study were: 1) almost 40% of patients referred for suspicion for ARVC had isolated dyskinetic RV segments; 2) of these 27 patients, 1, 4, and 8 were classified as having definitive, borderline or possible ARVC, respectively, while the majority remained unclassified; 3) this subgroup had more RV dilation and abnormal RV EF compared to the control group.

ARVC is a rare genetic disorder characterized by dyskinetic/aneurysmal RV walls, RV dilation and impaired systolic function, and is one of the leading causes of sudden cardiac death among athletes in the Mediterranean region (**Figure 1**).^{7,8)} The prevalence of ARVC varies from

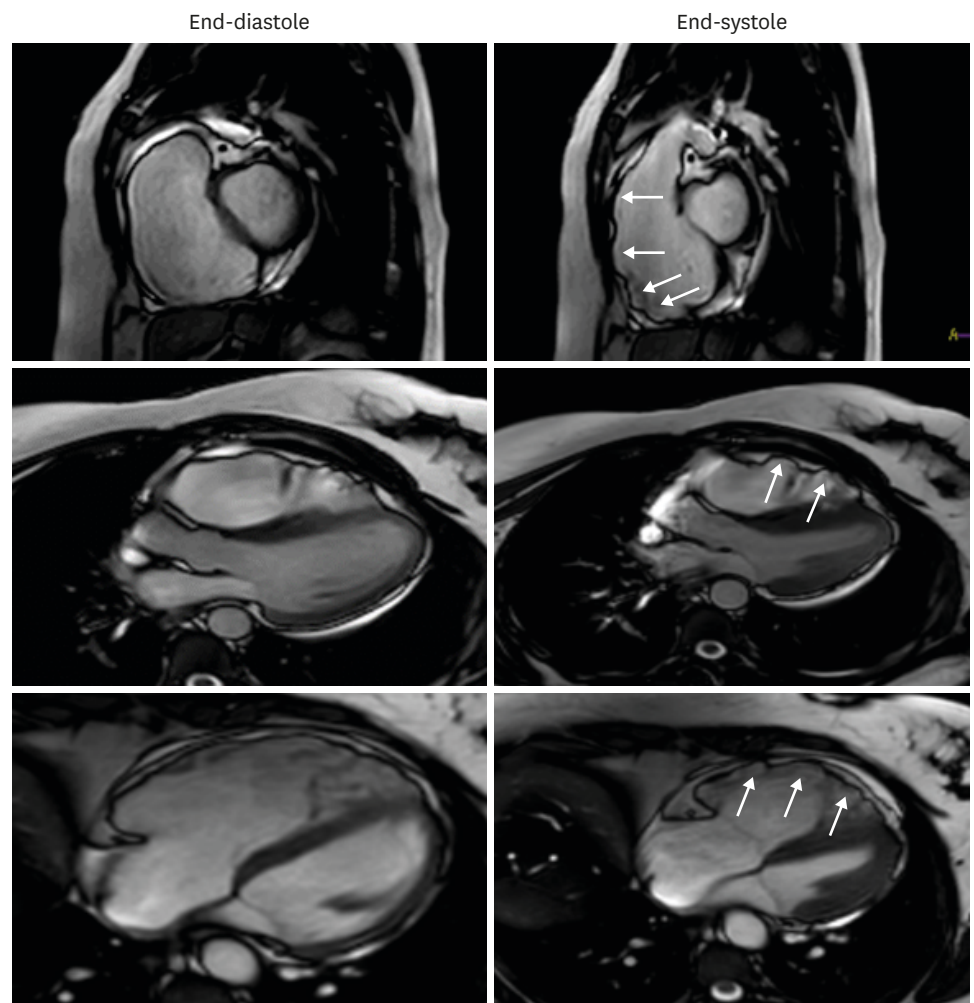


Figure 1. Cardiac magnetic resonance (CMR) imaging of a 45-year-old male patient with family history of sudden cardiac death and ventricular tachycardia on Holter. CMR showed dilated right ventricle (RV) with end-diastolic volume index of 120 mL/m^2 , end-systolic volume index of 76 mL/m^2 , reduced RV ejection fraction at 37%, and several RV dyskinetic segments (white arrows), meeting major CMR criteria for arrhythmogenic right ventricular cardiomyopathy.

1:1000 to 1:5000.⁹⁾¹⁰⁾ Despite its low prevalence, ARVC accounts for a disproportionately high percentage of referrals for CMR. The diagnosis relies on major and minor criteria which take into account structure, function, family history, histology, documented arrhythmia and ECG abnormalities. CMR is a reference standard imaging modality that allows visualization of all RV walls for global and regional RV function (axial and short axis views), quantifies EF, and differentiates ARVC from several mimickers of the disease.¹¹⁾

Non-pathological wall motion disorders are common; some are due to tethering of the free wall by the moderator band, and can easily be mistaken for pathological regional wall motion contraction, particularly with unexperienced or biased readers.¹²⁾⁴⁾ Therefore, the presence of isolated RV dyskinesia should be accompanied by clinical and follow-up data to ascertain whether this is pathological finding and part of a spectrum of a progressive disease. While intramyocardial and RV free wall fat imaging is still performed, its role should be limited to avoid over calling.¹⁵⁾

The 2010 revised TFC for the diagnosis of ARVC became more stringent than those published in 1994, and resulted in reduction of total patients meeting any diagnostic CMR criteria for ARVC from 22.7% to 2.6%,¹⁶⁾ and similarly in other studies.¹⁷⁾¹⁸⁾ The reduced sensitivity however was counterbalanced by increased specificity,¹⁹⁾ although a significant high proportion of patients has become unclassified, reaching almost a third in one study.⁶⁾ Our study showed that almost 40% of patients had isolated RV dyskinesia and more than half of them remained unclassified (**Figure 2**). The new finding is that this cohort had higher RV end-diastolic volumes index and were more likely to have impaired RV systolic function compared to the control group. Similarly, in a prospective analysis by Hamid et al.²⁰⁾, relatives of patients with ARVC who had isolated minor criteria were found to have higher prevalence of electrocardiographic T wave inversion, positive signal averaged electrocardiography and non-sustained ventricular tachycardia, and hence classified as probable ARVC, giving more evidence to the fact that there is a spectrum for the disease and evolution of it. Still, there is presently no official consensus on serial imaging or clinical strategy for surveillance of patients with isolated RV dyskinesia.

It has been well established that EF is not a very sensitive marker of impaired systolic function, at least not in the early stages. Indeed, in cardio-oncology, global longitudinal strain was shown to be a better indicator of early left ventricular systolic dysfunction than EF.²¹⁾ It is reasonable to assume that many patients with isolated focal dyskinetic RV segments might have abnormal global longitudinal strain despite normal global RV EF, which could reclassify patients. Indeed, a recent study showed that strain analysis by feature-tracking CMR objectively quantified global and regional RV dysfunction and dyssynchrony in patients with ARVC, and provided incremental value over conventional cine CMR imaging.²²⁾ Hence, integrating abnormal RV strain as an add-on criterion for ARVC might reclassify patients, and increase the sensitivity of the test without compromising its specificity. This remains hypothesis-generating and should be evaluated in future studies.

Limitations

To the best of our knowledge, this is the first study to assess patients with clinical suspicion for ARVC and isolated RV dyskinesia from the Mediterranean region. However, we recognize several limitations. First, this is a retrospective single centre study with referral and selection bias. Second, the sample size is relatively small given that ARVC is a rare disease. Third, the study lacked echocardiographic and histological data, and only half of the patients had Holter

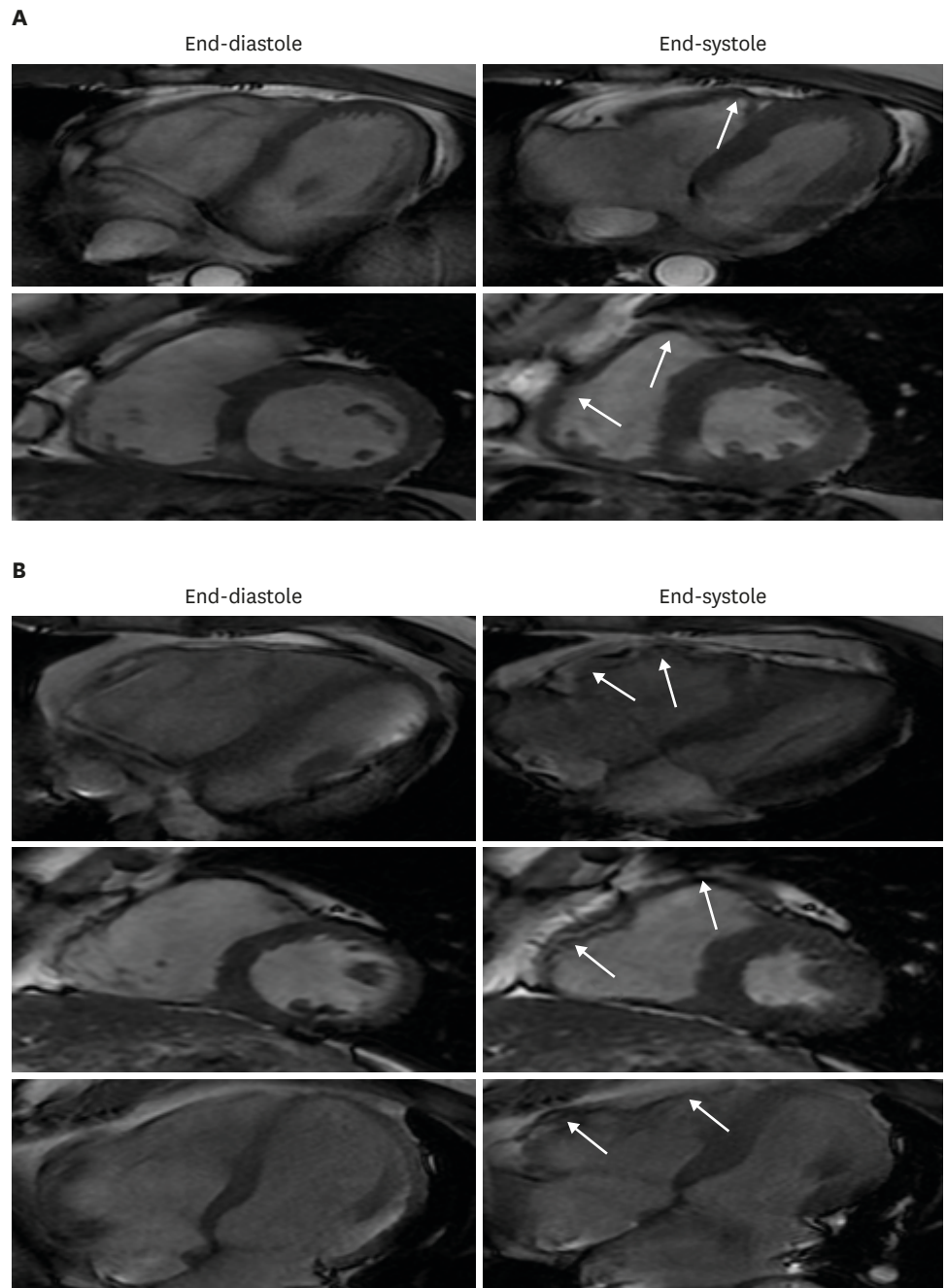


Figure 2. Two patients with isolated focal right ventricular (RV) dyskinetic segments (white arrows) that remained unclassified. Panel A: 42-year-old female with frequent premature ventricular beats on Holter. Cardiac magnetic resonance (CMR) showed RV end-diastolic volume index of 87 mL/m², end-systolic volume index of 44 mL/m², and a calculated RV ejection fraction at 49%. Panel B: 50-year-old male with palpitations. CMR showed end-diastolic volume index of 105 mL/m², end-systolic volume index of 61 mL/m², and a calculated RV ejection fraction at 42%.

results available for analysis; this would affect the final classification of patients as having definitive borderline, possible, or indeterminate ARVC. Fourth, clinical and imaging follow-up are lacking, which would have been of great interest particularly for those with isolated focal RV dyskinesia. There is an ongoing effort to follow-up these patients, repeat CMR imaging as well as ECGs and Holters in the following years, and gather clinical endpoints such as sudden cardiac death, syncope, and heart failure. In the absence of clinical endpoints,

the relevance of isolated RV dyskinetic segments remains poorly understood. Fifth, RV wall motion was assessed by a single reader, with a lack of data on reproducibility, intra and inter-observer agreement. Finally, the potential differential and alternative diagnosis for isolated RV dyskinesia remains hypothetical in many of the cases in the absence of further clinical data.

Conclusion

Among patients with a clinical suspicion for ARVC, almost 40% had isolated focal dyskinetic RV segments with the majority remaining unclassified. This cohort had more RV dilation and abnormal EF compared to control. Integrating other imaging CMR data such as RV strain might prove useful in detecting subtle RV systolic impairment and could classify further patients. The clinical and prognostic implications of these findings need to be followed up prospectively in larger cohorts.

REFERENCES

1. Haugaa KH, Haland TF, Leren IS, Saberniak J, Edvardsen T. Arrhythmogenic right ventricular cardiomyopathy, clinical manifestations, and diagnosis. *Europace* 2016;18:965-72.
[PUBMED](#) | [CROSSREF](#)
2. te Riele AS, Tandri H, Bluemke DA. Arrhythmogenic right ventricular cardiomyopathy (ARVC): cardiovascular magnetic resonance update. *J Cardiovasc Magn Reson* 2014;16:50.
[PUBMED](#) | [CROSSREF](#)
3. Borgquist R, Haugaa KH, Gilljam T, et al. The diagnostic performance of imaging methods in ARVC using the 2010 Task Force criteria. *Eur Heart J Cardiovasc Imaging* 2014;15:1219-25.
[PUBMED](#) | [CROSSREF](#)
4. Marcus FI, McKenna WJ, Sherrill D, et al. Diagnosis of arrhythmogenic right ventricular cardiomyopathy/dysplasia: proposed modification of the Task Force Criteria. *Eur Heart J* 2010;31:806-14.
[PUBMED](#) | [CROSSREF](#)
5. Perazzolo Marra M, Rizzo S, Bauce B, et al. Arrhythmogenic right ventricular cardiomyopathy. Contribution of cardiac magnetic resonance imaging to the diagnosis. *Herz* 2015;40:600-6.
[PUBMED](#) | [CROSSREF](#)
6. Femia G, Hsu C, Singarayay S, et al. Impact of new task force criteria in the diagnosis of arrhythmogenic right ventricular cardiomyopathy. *Int J Cardiol* 2014;171:179-83.
[PUBMED](#) | [CROSSREF](#)
7. Rachoin R, Saleh BA, Mansour B, Rachwan RJ, AlJaroudi W. Arrhythmogenic ventricular cardiomyopathy and sudden cardiac death: Left or right? *J Nucl Cardiol* 2017;24:527-33.
[PUBMED](#) | [CROSSREF](#)
8. Elmaghawry M, Alhashemi M, Zorzi A, Yacoub MH. A global perspective of arrhythmogenic right ventricular cardiomyopathy. *Glob Cardiol Sci Pract* 2013;2012:81-92.
[PUBMED](#)
9. Basso C, Corrado D, Marcus FI, Nava A, Thiene G. Arrhythmogenic right ventricular cardiomyopathy. *Lancet* 2009;373:1289-300.
[PUBMED](#) | [CROSSREF](#)
10. Sen-Chowdhry S, Morgan RD, Chambers JC, McKenna WJ. Arrhythmogenic cardiomyopathy: etiology, diagnosis, and treatment. *Annu Rev Med* 2010;61:233-53.
[PUBMED](#) | [CROSSREF](#)
11. Rastegar N, Burt JR, Corona-Villalobos CP, et al. Cardiac MR findings and potential diagnostic pitfalls in patients evaluated for arrhythmogenic right ventricular cardiomyopathy. *Radiographics* 2014;34:1553-70.
[PUBMED](#) | [CROSSREF](#)
12. Bluemke DA, Krupinski EA, Ovitt T, et al. MR imaging of arrhythmogenic right ventricular cardiomyopathy: morphologic findings and interobserver reliability. *Cardiology* 2003;99:153-62.
[PUBMED](#) | [CROSSREF](#)
13. Bomma C, Rutberg J, Tandri H, et al. Misdiagnosis of arrhythmogenic right ventricular dysplasia/cardiomyopathy. *J Cardiovasc Electrophysiol* 2004;15:300-6.
[PUBMED](#) | [CROSSREF](#)

14. Quick S, Speiser U, Kury K, Schoen S, Ibrahim K, Strasser R. Evaluation and classification of right ventricular wall motion abnormalities in healthy subjects by 3-tesla cardiovascular magnetic resonance imaging. *Neth Heart J* 2015;23:64-9.
[PUBMED](#) | [CROSSREF](#)
15. Sievers B, Addo M, Franken U, Trappe HJ. Right ventricular wall motion abnormalities found in healthy subjects by cardiovascular magnetic resonance imaging and characterized with a new segmental model. *J Cardiovasc Magn Reson* 2004;6:601-8.
[PUBMED](#) | [CROSSREF](#)
16. Liu T, Pursnani A, Sharma UC, et al. Effect of the 2010 task force criteria on reclassification of cardiovascular magnetic resonance criteria for arrhythmogenic right ventricular cardiomyopathy. *J Cardiovasc Magn Reson* 2014;16:47.
[PUBMED](#) | [CROSSREF](#)
17. Vermes E, Strohm O, Otmani A, Childs H, Duff H, Friedrich MG. Impact of the revision of arrhythmogenic right ventricular cardiomyopathy/dysplasia task force criteria on its prevalence by CMR criteria. *JACC Cardiovasc Imaging* 2011;4:282-7.
[PUBMED](#) | [CROSSREF](#)
18. Cox MG, van der Smagt JJ, Noorman M, et al. Arrhythmogenic right ventricular dysplasia/cardiomyopathy diagnostic task force criteria: impact of new task force criteria. *Circ Arrhythm Electrophysiol* 2010;3:126-33.
[PUBMED](#) | [CROSSREF](#)
19. Femia G, Sy RW, Puranik R. Systematic review: Impact of the new task force criteria in the diagnosis of arrhythmogenic right ventricular cardiomyopathy. *Int J Cardiol* 2017;241:311-7.
[PUBMED](#) | [CROSSREF](#)
20. Hamid MS, Norman M, Quraishi A, et al. Prospective evaluation of relatives for familial arrhythmogenic right ventricular cardiomyopathy/dysplasia reveals a need to broaden diagnostic criteria. *J Am Coll Cardiol* 2002;40:1445-50.
[PUBMED](#) | [CROSSREF](#)
21. Smiseth OA, Torp H, Opdahl A, Haugaa KH, Urheim S. Myocardial strain imaging: how useful is it in clinical decision making? *Eur Heart J* 2016;37:1196-207.
[PUBMED](#) | [CROSSREF](#)
22. Prati G, Vitrella G, Allocca G, et al. Right ventricular strain and dyssynchrony assessment in arrhythmogenic right ventricular cardiomyopathy: cardiac magnetic resonance feature-tracking study. *Circ Cardiovasc Imaging* 2015;8:e003647; discussion e003647.
[PUBMED](#) | [CROSSREF](#)