

Postoperative Abdominal Infection Caused by *Corynebacterium minutissimum*

Ji Young Shin¹, Woon Kee Lee², Yiel-Hea Seo³, and Yoon Soo Park¹

¹Department of Internal Medicine, ²Department of Surgery, and ³Department of Laboratory Medicine, Gachon University School of Medicine, Gil Hospital, Incheon, Korea

Corynebacterium minutissimum is a non-spore forming, gram-positive, aerobic or facultative anaerobic bacillus. It is the causative organism of erythrasma, a common superficial infection of skin, which typically presents as reddish-brown macular patches. To date, it has rarely been found to cause invasive disease, although other non-diphtheria corynebacteria are becoming increasingly common as opportunistic pathogens. We report on a rare case of abdominal infection due to *C. minutissimum* in an immunocompetent adult who was successfully treated with intravenous amoxicillin/sulbactam.

Key Words: *Corynebacterium*; Abdomen; Infection

Introduction

Corynebacterium minutissimum is a gram-positive, non-spore-forming, aerobic or facultative anaerobic bacillus, which is a resident microbe of skin and mucosal membranes. It is the etiologic organism of erythrasma, a common superficial infection of skin [1]. Although some cases of *C. minutissimum* infection have been reported, it has rarely been a causative agent of invasive extracutaneous infection. To the best of our knowledge, we report on the first case of postoperative abdominal infection caused by *C. minutissimum*.

Case Report

A 76-year-old male patient was referred to the Infectious Division due to high fever and diarrhea. Emergency radical subtotal gastrectomy had been performed 11 days earlier due to occurrence of gastric perforation after endoscopic submucosal dissection of early gastric cancer. After radical subtotal gastrectomy, piperacillin/tazobactam (4.5 g every 8 h) had been administered for treatment of peritonitis. The patient had a medical history of chronic obstructive pulmonary disease without medication. He complained of abdominal discomfort and dyspepsia. On physical examination, he was alert and cooperative. His body temperature was 38.1°C, blood pressure, 130/80 mmHg, pulse, 120 beats per minute, and respiratory

Received: August 16, 2013 **Revised:** October 15, 2013 **Accepted:** October 15, 2014

Corresponding Author : Yoon Soo Park, MD, PhD

Department of Internal Medicine, Gachon University School of Medicine,
Gil Hospital, 21 Namdong-daero 774beon-gil, Namdong-gu, Incheon 405-760,
Korea

Tel: +82-32-460-8506, Fax: +82-32-469-4320

E-mail: yspark@gilhospital.com

This is an Open Access article distributed under the terms of the Creative Commons Attribution Non-Commercial License (<http://creativecommons.org/licenses/by-nc/3.0>) which permits unrestricted non-commercial use, distribution, and reproduction in any medium, provided the original work is properly cited.

Copyrights © 2014 by The Korean Society of Infectious Diseases | Korean Society for Chemotherapy

www.icjournal.org

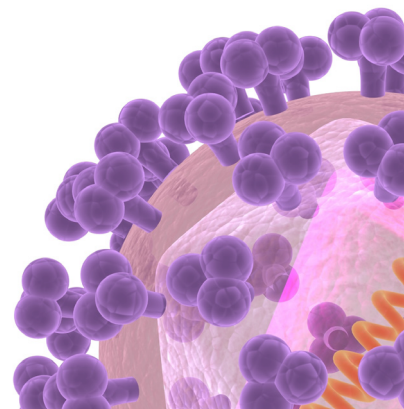

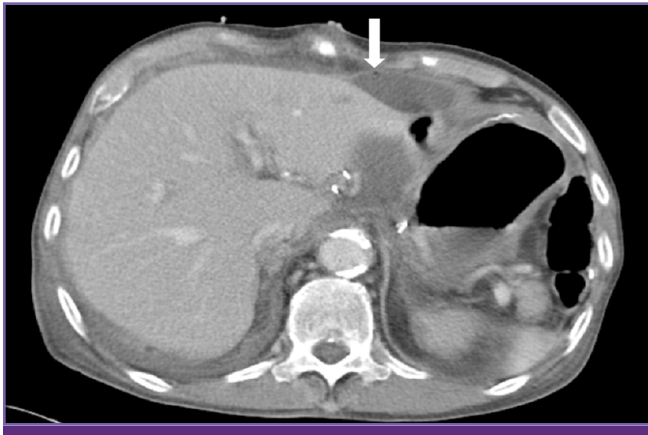


Figure 1. CT on abdomen showed complicated fluid collection with a small amount of air bubble (arrow) around the operation site.

rate, 25 breaths per minute. Generalized abdominal tenderness was observed, without rebound tenderness. Blood tests showed a leukocyte count of $42,770/\text{mm}^3$ with segmented neutrophils of 90.2% and a high sensitivity C-reactive protein level of 21.22 mg/dL. His blood, urine culture result showed no growth of bacteria. Findings on abdominal computed tomography showed complicated fluid collection with a small amount of air bubble around the operation site (Fig. 1). Percutaneous catheter drainage was inserted into the peritoneal cavity. Doripenem (500 mg every 8 h) was started empirically.

Gram stain of abdominal drainage showed slightly curved, gram-positive rods. A positive catalase reaction was observed. The specimen was cultured on 5% sheep blood agar plates at 35°C overnight and identified using the Vitek II Anaerobic and *Corynebacterium* identification card (BioMérieux, Durham, NC, USA). Final results of culture testing confirmed *C. minutissimum*. The isolate was susceptible to ampicillin, tetracycline, erythromycin, and vancomycin, but intermediately susceptible to penicillin. Initial empiric doripenem was discontinued and amoxicillin/sulbactam (1 g/500 mg every 8 h) was started and maintained for 23 days, until discharge. Subsequent abdominal CT on the 40th post-operative day showed no complicated fluid. The patient was discharged on the 44th post-operative day.

Discussion

Corynebacterium species are found as colonizers of the skin and other tissues and in the environment. Although pathogenic non-diphtheriae *Corynebacterium* (*Corynebacterium jeikeium*, *Corynebacterium amycolatum*, *Corynebacterium*

urealyticum, and *C. minutissimum*) have been reported with some frequency, these bacteria are among the micro-organisms that are often neglected by physicians and clinical microbiologists [2]. Among non-diphtheriae *Corynebacterium*, *C. minutissimum* remains an uncommon cause of invasive disease. To date, 20 cases of invasive *C. minutissimum* infection have been reported [3, 4]. These include two cases of peritonitis, both involving patients with peritoneal dialysis [5, 6], and one case of post-surgical abscess in a patient who had undergone cervical discectomy [7]. To the best of our knowledge, we report on the third case of abdominal infection, the second postoperative infection, and the first postoperative abdominal infection caused by *C. minutissimum*.

Although multi-resistance has been well documented in *C. jeikeium* [8, 9], *C. urealyticum* [9], and *Corynebacterium striatum* [10, 11] strains and in *C. amycolatum* [12], *C. minutissimum* is generally susceptible to antimicrobials, including ampicillin, tetracycline, erythromycin, and vancomycin [9, 13]. In our case, the isolate was susceptible to ampicillin, tetracycline, erythromycin, and vancomycin.

Invasive *C. minutissimum* infection usually occurs in immunocompromised patients and/or patients with skin disruption due to surgery or indwelling devices, such as a central venous catheter and peritoneal dialysis catheter [5, 6, 14, 15]. Although the source of infection was unknown, skin disruption by surgery and drainage catheter might have contributed to development of invasive *C. minutissimum* infection in this patient.

In conclusion, given an increasing number of cases with non-diphtheriae *Corynebacterium* as a cause of serious opportunistic infection in immunocompromised patients and the more common use of indwelling devices causing a breach in the skin-barrier [3, 4], clinicians would be wise to keep this organism in mind as a rare cause of post-surgical abdominal infection.

References

1. Coyle MB, Lipsky BA. *Coryneform* bacteria in infectious diseases: clinical and laboratory aspects. Clin Microbiol Rev 1990;3:227-46.
2. Funke G, von Graevenitz A, Clarridge JE 3rd, Bernard KA. Clinical microbiology of *coryneform* bacteria. Clin Microbiol Rev 1997;10:125-59.
3. Dalal A, Likhi R. *Corynebacterium minutissimum* bacteremia and meningitis: a case report and review of litera-

- ture. J Infect 2008;56:77-9.
4. Eshwara VK, Munim F, Shetty A, Gupta A, Nitin J, Mukhopadhyay C. *Corynebacterium minutissimum* infecting pseudomeningocele: a rare case. J Microbiol Immunol Infect 2014;47:149-51.
 5. Van Bosterhaut B, Cuvelier R, Serruys E, Pouthier F, Wauters G. Three cases of opportunistic infection caused by propionic acid producing *Corynebacterium minutissimum*. Eur J Clin Microbiol Infect Dis 1992;11:628-31.
 6. Fernández Girón F, Saavedra Martín JM, Benítez Sánchez M, Fernández Mora F, Rodríguez Gómez E. *Corynebacterium minutissimum* peritonitis in a CAPD patient. Perit Dial Int 1998;18:345-6.
 7. Golledge CL, Phillips G. *Corynebacterium minutissimum* infection. J Infect 1991;23:73-6.
 8. Traub WH, Geipel U, Leonhard B, Bauer D. Antibiotic susceptibility testing (agar disk diffusion and agar dilution) of clinical isolates of *Corynebacterium jeikeium*. Chemotherapy 1998;44:230-7.
 9. Soriano F, Zapardiel J, Nieto E. Antimicrobial susceptibilities of *Corynebacterium* species and other non-spore-forming gram-positive bacilli to 18 antimicrobial agents. Antimicrob Agents Chemother 1995;39:208-14.
 10. Otsuka Y, Ohkusu K, Kawamura Y, Baba S, Ezaki T, Kimura S. Emergence of multidrug-resistant *Corynebacterium striatum* as a nosocomial pathogen in long-term hospitalized patients with underlying diseases. Diagn Microbiol Infect Dis 2006;54:109-14.
 11. Renom F, Garau M, Rubí M, Ramis F, Galmés A, Soriano JB. Nosocomial outbreak of *Corynebacterium striatum* infection in patients with chronic obstructive pulmonary disease. J Clin Microbiol 2007;45:2064-7.
 12. Funke G, Punter V, von Graevenitz A. Antimicrobial susceptibility patterns of some recently established *coryneform* bacteria. Antimicrob Agents Chemother 1996;40:2874-8.
 13. Lagrou K, Verhaegen J, Janssens M, Wauters G, Verbist L. Prospective study of catalase-positive *coryneform* organisms in clinical specimens: identification, clinical relevance, and antibiotic susceptibility. Diagn Microbiol Infect Dis 1998;30:7-15.
 14. Bandera A, Gori A, Rossi MC, Degli Esposti A, Ferrario G, Marchetti G, Tocalli L, Franzetti F. A case of costochondral abscess due to *Corynebacterium minutissimum* in an HIV-infected patient. J Infect 2000;41:103-5.
 15. Rupp ME, Stiles KG, Tarantolo S, Goering RV. Central venous catheter-related *Corynebacterium minutissimum* bacteremia. Infect Control Hosp Epidemiol 1998;19:786-9.