

## Research Article

Shimin Wu, Xinjian Zhu, Lijuan Xiang, Jianqiang Chen, Chunxiao Chen\*

# The diagnostic accuracy of conventional forceps biopsy compared to ESD

<https://doi.org/10.1515/med-2017-0039>

received December 4, 2016; accepted July 18, 2017

**Keywords:** Intraepithelial neoplasia; Endoscopic submucosal dissection; Conventional forceps biopsy

**Abstract:** Objective: conventional forceps biopsy (CFB) is the most popular way to screen for gastric epithelial neoplasia (GEN). Our study aimed to compare the diagnostic accuracy between conventional forceps biopsy and endoscopic submucosal dissection (ESD).

**Methods:** 105 patients diagnosed GEN finally undertook ESD in our hospital were enrolled. We retrospectively assessed the characteristics of pathological results of CFB and ESD.

**Results:** The overall pathologic concordance rate between the CFB and ESD specimens was 68.57%. 55 cases of CFB maintained low-grade intraepithelial neoplasia (LGIN) under ESD, 18 cases (23.1%) diagnosis for high-grade intraepithelial neoplasia (HGIN), 5 cases (6.4%) diagnosis for cancer. Moreover, 10 cases of CFB maintained HGIN under ESD. Lesions with surface hyperemia (44.4% vs. 27.54%) or surface ulcer (57.14% vs. 26.76%) were more likely to cancerate ( $P < 0.05$ ).

**Conclusion:** endoscopic biopsy in the diagnosis of low-grade intraepithelial neoplasia, may exist or progression to high-grade intraepithelial neoplasia, some may have cancer, should take active treatment measures.

## 1 Introduction

Gastric cancer is the third leading cause of cancer deaths around the world and the early diagnosis of gastric cancer is difficult [1]. Unlike advanced gastric cancer, precancerous lesions or early-gastric cancer have no specific clinical manifestations and symptoms. Therefore, it is very important to improve survival rates for patients by the early diagnosis of gastric cancer. Early gastric cancer screening by gastroscopy has been quite popular in some country [2]. Through the screening of gastroscopy, we can detect early cancer, high-grade intraepithelial neoplasia (HGIN), low-grade intraepithelial neoplasia (LGIN). However, due to limitations such as biopsy site and depth, part of cancerous lesions may be misdiagnosed. Multiple biopsy of CFB was needed to be conducted. Once precancerous lesions were found, we would advise patients to conduct ESD to resect lesions totally to prevent further carcinogenesis [3]. Jeon *et al* reported that overall histological concordance rate between the endoscopic forceps biopsy and ESD specimens was 81.1% (107/132) [4]. Lu *et al* also report that concordance rate was 68.92% (306/444) between CFB and ESD [5]. Compared with surgery, ESD can bring fewer traumas. However, it still has the risk of perforation and bleeding, as well as the huge cost. It is very important to perfect routine biopsy pathologic evaluation before ESD.

In our study, we retrospectively assessed the characteristics of 105 pathological results of CFB and ESD in our hospital and calculated the concordance rate. Through analysis, we can estimate who is more suitable for conservative treatment and who is not.

**\*Corresponding author: Chunxiao Chen**, Department of Gastroenterology, the First Affiliated Hospital, College of Medicine, Zhejiang University, No.79 Qingchun Road, Hangzhou 310003, China. Tel: +86-571-87236863, E-mail: 648479451@qq.com

**Shimin Wu, Chunxiao Chen**, Department of Gastroenterology, the First Affiliated Hospital, College of Medicine, Zhejiang University, Hangzhou 310003, China

**Shimin Wu, Lijuan Xiang, Jianqiang Chen, Xinjian Zhu**, Shaoxing shangyu people's hospital, China

Authors contributors: Shimin Wu and Chunxiao Chen designed the study; Shimin Wu performed the research; Xinjian Zhu, Lijuan Xiang and Jianqiang Chen collected and analyzed the data; Shimin Wu wrote the paper; Chunxiao Chen revised the paper.

## 2 Materials and methods

### 2.1 Basic information

From July 1, 2014 to June 1, 2016, we retrospectively enrolled 105 patients finally undertaking ESD in Shaoying shangyu people's hospital, including 78 LGIN and 27 HGIN under CFB. Patients were included according to the following criteria: (1) informed consent was provided before ESD; (2) age more than 18; (3) CFB was also performed before ESD. Exclusion criteria: (1) patients with other chronic diseases; (2) any reasons caused the interrupt of ESD; (3) patients had the history of cancer.

The histological diagnosis of LGIN, HGIN, and early cancer was determined according to the World Health Organization classification [6]. We almost got 2-3 specimens under CFB in lesion site in order to improve the diagnostic accuracy. Mean age of LGIN was  $63.86 \pm 9.34$ , including 45 males and 33 females. Moreover, the mean age of HGIN was  $63.63 \pm 9.61$ , including 19 males and 8 females.

Ethical approval: The research related to human use has been complied with all the relevant national regulations, institutional policies and in accordance the tenets of the Helsinki Declaration, and has been approved by the authors' institutional review board or equivalent committee.

### 2.2 Endoscopy and biopsy

We used Olympus GIF - XQ260 electronic gastroscope for gastroscopy (Olympus, Tokyo, Japan). According to Japanese endoscopic society classification standards, we recorded the lesion area, shape and the situation surface (including antrum, angle of stomach, body of stomach and cardia). The conventional fixation, dehydration, embedding, sectioning, HE staining, and the microscopic observation conducted gastroscope biopsy specimens. Two pathologists confirmed the final histological diagnosis separately and each of them had at least 10 years working experience.

### 2.3 ESD

Explaining the natural development of disease process of gastric intraepithelial neoplasia and conducting ESD to patients with lesion confined within the mucosal layer. All of the patients conducting ESD signed informed consent.

Histologic diagnosis adopt WHO digestive system tumor pathological diagnosis standard classification [6].

### 2.4 Statistical analysis

According to different influence factors, we analyzed which really influenced concordance rate. Univariate analysis was performed using Student's t test for the continuous variables and chi-square test was used to compare categorical variables. The statistical significance was defined as  $P \leq 0.05$ . We used SPSS 21.0 (IBM, Chicago, IL, USA) to perform the statistical analysis. Another associated data was calculated and plotted using GraphPad Prism 5 (Graph Pad, San Diego, CA, USA).

## 3 Results

78 LGIN patients under CFB, including 58 in antrum, 10 in angle of stomach, 4 in body of stomach, 6 in cardia. Pathological changes mainly concentrated in the gastric antrum and angle, but the distribution of the lesions had no statistical difference. According to Japanese endoscopic institute classification standard, lesions endoscopic morphology was given priority to with II type and mixed type, occupying 82.1% (64/78). Surface hyperemia occupied 11.5% (9/78), surface ulcer lesions accounted for 9.0% (7/78). (Table 1). 27 LGIN patients under CFB, including 15 in antrum, 6 in angle of stomach, 3 in body of stomach, 3 in cardia. (Table 2).

The pathologic concordance rate of LGIN between the CFB and ESD specimens was 70.51% (55/78). Moreover, 18 cases diagnosed HGIN and 5 cases diagnosed early carcinoma. Pathological upgrade appeared in antrum (24.14%), angle (50%), body (25%), cardia (50%), respectively (Table 1). We could find angle and cardia had higher pathological upgrade, but there was no statistical difference ( $P > 0.05$ ). In addition, we observed that lesions with surface hyperemia (44.4% vs. 27.54%) or surface ulcer (57.14% vs. 26.76%) were more likely to appear pathological upgrade ( $P < 0.05$ ). While of surface hyperemia and surface ulcer, the ratio of gender, age, and situation had no statistical differences. We found that 3 of 14 cases (21.4%) with type mixed diagnosed cancer. 33.33% (15/45) male cases had pathological upgrade, including 4 cases (8.89%) diagnosed cancer. Moreover, 24.24% female cases (8/33) had pathological upgrade, including 1 cases (3.03%) diagnosed cancer. However, there was no statistic difference between male and female ( $P > 0.05$ ). Average age of male

**Table 1:** Characteristic of 78 LGIN patients under CFB

	CFB	ESD		
	LGIN	LGIN	HGIN	CA
Location				
antrum	58	44	11	3
angle	10	5	4	1
body	4	3	1	0
cardia	6	3	2	1
Surface hyperemia				
Yes	9	5	3	1
No	69	50	15	4
Surface ulcer				
Yes	7	3	2	2
No	71	52	16	3
Endoscopic morphology				
Type I (protrude)	10	8	2	0
Type II (superficial)	50	39	10	1
Type III (introcession)	4	1	2	1
Mixed	14	5	6	3
HP+	24	14	6	4

CFB: conventional forceps biopsy

ESD: endoscopic submucosal dissection

LGIN: low grade intraepithelial neoplasia

HGIN: high grade intraepithelial neoplasia

CA: cancer

pathological upgrade cases was  $67.81 \pm 8.2$ , and no pathological upgrade was  $62.29 \pm 9.3$ . Pathological upgrade cases were older than no pathological upgrade cases ( $P=0.031$ ). While there was no statistical difference in female cases ( $67.83 \pm 8.27$  vs.  $62.2 \pm 9.33$ ,  $P>0.05$ ).

The pathologic concordance rate of HGIN between the CFB and ESD specimens was 62.96% (17/27). Moreover, 10 cases (37.04%) diagnosed early carcinoma. Pathological upgrade appeared in antrum (33.33%), angle (50%), body (33.33%), cardia (33.33%), respectively (Table 2). There was no statistical difference between each other ( $P>0.05$ ). Lesions with surface ulcer appeared pathological upgrade from HGIN to carcinogenesis more easily ( $P=0.024$ ). No statistical difference was found between male and female of pathological upgrade (42.11% vs. 25%,  $P>0.05$ ). In addition, neither male nor female cases had no statistical difference of age between pathological upgrade and no pathological upgrade cases.

## 4 Discussion

In 2000, the international agency for research on cancer (IARC) published a new tumor classification and firstly applying the definition of intraepithelial neoplasia to the

diagnosis of gastrointestinal epithelium precancerous lesions. WHO working group changed triple classification into secondary classification of LGIN and dysplasia HGIN [7]. For LGIN, regular follow-up is an effective means while difference of biopsy is a challenge to the diagnosis of LGIN in clinical work. The reason is that gastroscopic biopsy only reflects a site of disease in the stomach instead of the whole. Jung *et al* reported that differentiation of biopsy specimens is meaningless, because potential malignant lesions may exist in rest lesions [8]. Even hyperplastic polyp with 5 mm diameter may diagnose cancer [9]. Therefore, underestimate of lesions would lead to the lack of effective treatment and poor prognosis.

ESD has become one of the main treatment of early gastric cancer because of characteristics of small attack and quicker recovery [10]. Along with the progress of the endoscopic technique, ESD can safely resect larger lesions. Stripping lesions can provide complete pathological specimens and compensate for the limitations of biopsy materials, which is conducive to make more accurate pathological diagnosis [11]. So the early diagnosis of HGIN and early cancer is very important.

In our study, the pathologic concordance rate of LGIN was 70.51%. 23 cases diagnosed HGIN or cancer under ESD. CFB specimens usually include mucosal epithelium, lamina propria, which rarely involves the mucosal muscu-

**Table 2:** Characteristic of 27 HGIN patients under CFB

	CFB HGIN	ESD HGIN	CA
Location			
antrum	15	10	5
angle	6	3	3
body	3	2	1
cardia	3	2	1
Lesion size			
<20mm	9	7	2
>20mm	18	10	8
Surface hyperemia			
Yes	16	9	7
No	11	8	3
Surface ulcer			
Yes	9	3	6
No	18	14	4
Endoscopic morphology			
Type I (protrude)	8	6	2
Type II(superficial)	13	9	4
Type III(introcession)	3	1	2
Mixed	3	1	2
HP+	16	9	7

CFB: conventional forceps biopsy

ESD: endoscopic submucosal dissection

HGIN: high grade intraepithelial neoplasia

CA: cancer

laris. While ESD specimens include mucosal muscularis. So if we improve the depth and quality of CFB specimens, the pathologic concordance rate would be improved. We further analyzed whether lesions morphology can help analyze HGIN and early cancer. We found that the severity of the lesion is closely relative to surface hyperemia and ulcers. 21.4% cases with mixed type diagnosed cancer under ESD. So we should pay close attention to lesions with surface hyperemia and ulcers. In figure 1, we could see that CFB showed LGIN while ESD showed moderately differentiated adenocarcinoma. CFB only represents point lesion rather than the entire lesion, which requests us to conduct multi-point biopsy for suspicious lesions as far as possible. In addition, chromoendoscopy, magnifying endoscopy, Narrow Band Imaging (NBI), Endoscopic confocal microscopy can clearly observed lesions characteristic changes, which will also improve the accuracy of lesions.

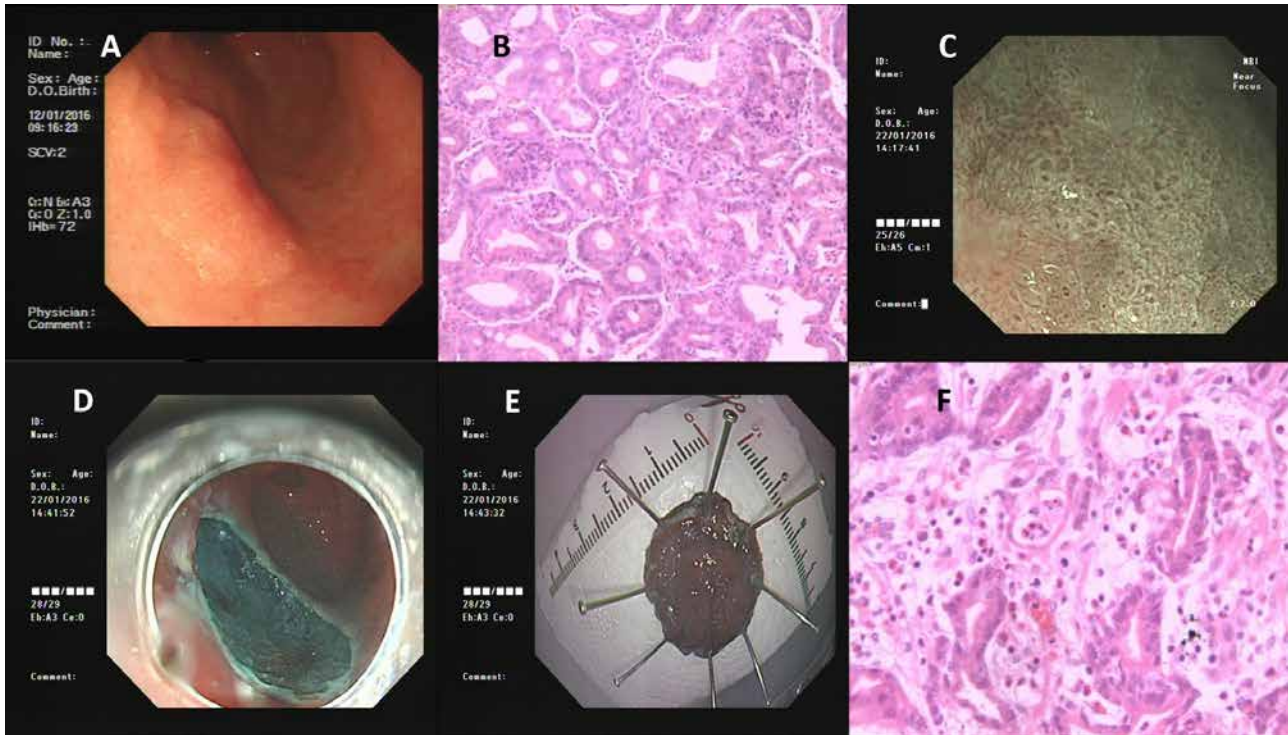
In our study, 5 patients (33.33%) showed adenocarcinomas under ESD while HGINs under CFB. By contrast, only 5.17% (3/58) patients showed adenocarcinomas under ESD while LGINs under CFB. It was a high ratio in HGINs patients. Therefore, HGIN is a strong indication to perform ESD.

Moreover, our study also had several limitations. The main limitation was potential selective bias in our retrospective study. Patients with high income, medical resource and education may have more opportunity to perform periodic physical examination and preventive ESD. In addition, we excluded patients with heterotopic pancreas and gastrointestinal stromal tumors (GIST), which were diagnosed by confocal laser endomicroscopy or endoscopic ultrasonography. The reason why we excluded these patients was that CFB pathological results showed Mild-to-moderate inflammation and other endoscopy technique had more diagnostic value.

## 5 Conclusion

In conclusion, LGIN lesions with old patients, surface hyperemia and ulcers may exist or progress for HGIN or cancer. Clinicians should pay more attention to communicate with pathologists and make an accurate diagnosis in combination with endoscopic images. Patients with HGIN under CFB have high indication to conduct ESD. For these lesions, preventive ESD is needed as soon as possible after





**Figure 1:** A) gastric mucosa with swell and surface hyperemia under conventional endoscopy; B) CFB histological result showed LGIN (HE×400); C) NBI found that the demarcation between the lesions and surrounding mucosa mouth shape was irregular and the missing of mucosa capillary network; D) ESD image; E) the shape of ESD specimen was 2.0cm×2.5cm; F) postoperative histological result showed moderately differentiated adenocarcinoma, which was limited to the mucosa and close to the mucosal muscularis, and the lateral cutting edge and base cutting edge were all negative (HE×400).

fully informed patient, which will reduce missed diagnosis of cancer as far as possible.

**Conflict of interest statement:** Authors state no conflict of interest.

## Reference

- [1] International Agency for Research on Cancer. GLOBOCAN 2012: Estimated Cancer Incidence, Mortality and Prevalence Worldwide in 2012. <http://globocan.iarc.fr/>
- [2] Veitch AM, Uedo N, Yao K, East JE. Optimizing early upper gastrointestinal cancer detection at endoscopy. *Nature reviews Gastroenterology & hepatology* 2015;12:660-667
- [3] Won CS, Cho MY, Kim HS, Kim HJ, Suk KT, Kim MY, et al. Upgrade of Lesions Initially Diagnosed as Low-Grade Gastric Dysplasia upon Forceps Biopsy Following Endoscopic Resection. *Gut and liver* 2011;5:187-193
- [4] Jeon HK, Ryu HY, Cho MY, Kim HS, Kim JW, Park HJ, et al. A randomized trial to determine the diagnostic accuracy of conventional vs. jumbo forceps biopsy of gastric epithelial neoplasias before endoscopic submucosal dissection; open-label study. *Gastric cancer : official journal of the International Gastric Cancer Association and the Japanese Gastric Cancer Association* 2014;17:661-668
- [5] Lu C, Lv X, Lin Y, Li D, Chen L, Ji F, et al. Retrospective study: The diagnostic accuracy of conventional forceps biopsy of gastric epithelial compared to endoscopic submucosal dissection (STROBE compliant). *Medicine* 2016;95:e4353
- [6] Aaltonen LA HS. World Health Organization., International Agency for Research on Cancer. Pathology and genetics of tumours of the digestive system. Lyon Oxford: IARC Press; Oxford University Press. 2000
- [7] LA HSA. World Health Organization classification of tumor: pathology and genetics of tumors of digestive system Lyon: IARC Press 2000;37-68
- [8] Jung MK, Jeon SW, Park SY, Cho CM, Tak WY, Kweon YO, et al. Endoscopic characteristics of gastric adenomas suggesting carcinomatous transformation. *Surgical endoscopy* 2008;22:2705-2711
- [9] Han AR, Sung CO, Kim KM, Park CK, Min BH, Lee JH, et al. The clinicopathological features of gastric hyperplastic polyps with neoplastic transformations: a suggestion of indication for endoscopic polypectomy. *Gut and liver* 2009;3:271-275
- [10] Lin LF, Huang PT, Ho KS, Tung JN. Endoscopic mucosal resection of early esophageal carcinoma--experience of 9 cases. *Journal of the Chinese Medical Association : JCMSA* 2008;71:347-352
- [11] Szaloki T, Toth V, Nemeth I, Tiszlavicz L, Lonovics J, Czako L. Endoscopic mucosal resection: not only therapeutic, but a diagnostic procedure for sessile gastric polyps. *Journal of gastroenterology and hepatology* 2008;23:551-555