

Calcified in-stent restenosis in a venous stent

Jens-Ove Schmidt, MD,^a Johnny Kent Christensen, MD,^b and Kim Christian Houliand, MD, PhD,^a
Kolding, Denmark

Stenting of the iliac veins has been an established treatment for improving venous runoff from the legs after thrombolysis of iliofemoral deep venous thrombosis for more than a decade, yet little is known about the long-term fate of stents in the central veins. We describe a case of heavily calcified in-stent restenosis in a 10-year-old venous stent as well as a way of treating this rare condition. With growing numbers of venous stents reaching a significant age, a need for treatment of long-term complications like the one presented here most probably will arise. (*J Vasc Surg Cases* 2015;1:261-3.)

Since the first catheter-directed thrombolysis (CDT) of thrombosed iliac veins described by Okrent et al¹ in 1991, the treatment has won widespread acceptance. Broholm et al² have shown that early CDT reduces the risk for development of post-thrombotic syndrome, thus contributing to the popularity of the treatment. Approximately half of the cases treated with CDT are followed by stenting of the iliac veins.³ Furthermore, stenting of the iliac veins is a feasible way of relieving symptoms of established post-thrombotic syndrome.⁴ However, by now, knowledge of the long-term fate of venous stents is limited, yet the first reports of stent stenosis and occlusion and suggestions for the treatment of such are beginning to appear in the literature. With the first stentings being far more than a decade ago, long-term complications may be imminent, leaving a need to establish treatments for late stent stenosis and occlusions. In the following, we describe a case of heavily calcified in-stent restenosis that led to stent occlusion, recently treated at our clinic. The patient has given her consent for publication of the case.

CASE REPORT

The patient, a 35-year-old woman, was a nonsmoker and took no oral contraceptives; she had a history of acute left-side iliofemoral deep venous thrombosis 10 years earlier. At the time, she was treated with CDT and stenting of the left iliac veins. She received warfarin for no more than 1 year despite the fact that she was heterozygous for factor V Leiden mutation. In the past 10 years, she had given birth to two children.

She was referred to our clinic with 1 week's recurrent symptoms of acute left-sided deep venous thrombosis (swelling and

pain of the left leg and low abdominal pain). Magnetic resonance phlebography and color duplex ultrasound scan both showed absence of flow in the iliac stent. Outflow was partly re-established after 1 day of ultrasound-accelerated CDT (UACDT), but there was significant residual thrombus. Because incomplete thrombus resolution is not an uncommon finding after only 24 hours of UACDT, we continued the treatment, but the thrombus showed no signs of further resolution even after an additional 2 days of UACDT. Digital subtraction phlebography revealed severe compression of the stent (a 12-mm, 12-cm-long nitinol stent) at the May-Thurner point, which did not seem to be entirely covered by the stent, and residual thrombus inside the stent distal to the compression. Anticipating the material to be the rubbery chronic thrombus usually found in restenosed stents, we decided to debulk the old stent to create sufficient diameter for a second stent to resolve the compression. Unfortunately, mechanical debulking by that time was not yet standard treatment at our center, so arrangements needed to be made to do the procedure. We therefore decided to treat the patient with provisional plain balloon angioplasty at the site of compression preceded by placement of a vena cava filter for protection against embolization of thrombus material.

Mechanical debulking was planned to be performed 2 weeks later, and she was discharged on high-dose low-molecular-weight heparin.

DISCUSSION

Before debulking, we performed computed tomography phlebography, which much to our surprise revealed severe calcification of the material inside the stent, causing a >75% stenosis distal to the compressed part of the stent (Fig 1).

Since neither we nor our colleagues at the only other center in Denmark performing interventions on the central veins were familiar with calcified in-stent restenosis in venous stents, we searched the literature for this condition and suggestions on its treatment, but our search on MEDLINE revealed no matching articles.

We decided to treat the patient as follows.

To eliminate any eventual fresh thrombus formed in the 2-week waiting period, we started the procedure with 48 hours of UACDT with the EKOS EkoSonic system (EKOS Corp, Bothell, Wash).

To create as big a lumen inside the old stent as possible, we then performed transcatheter mechanical debulking

From the Department of Vascular Surgery^a and Department of Radiology,^b Little Belt Hospital.

Author conflict of interest: none.

Correspondence: Jens-Ove Schmidt, MD, Department of Vascular Surgery, Sygehus Lillebaelt, Skovvangen 2-8, 6000 Kolding, Denmark (e-mail: jensi@dadlnet.dk).

The editors and reviewers of this article have no relevant financial relationships to disclose per the Journal policy that requires reviewers to decline review of any manuscript for which they may have a conflict of interest.

2352-667X

Copyright © 2015 The Authors. Published by Elsevier Inc. on behalf of the Society for Vascular Surgery. This is an open access article under the CC BY-NC-ND license (<http://creativecommons.org/licenses/by-nc-nd/4.0/>).

<http://dx.doi.org/10.1016/j.jvsc.2015.07.008>

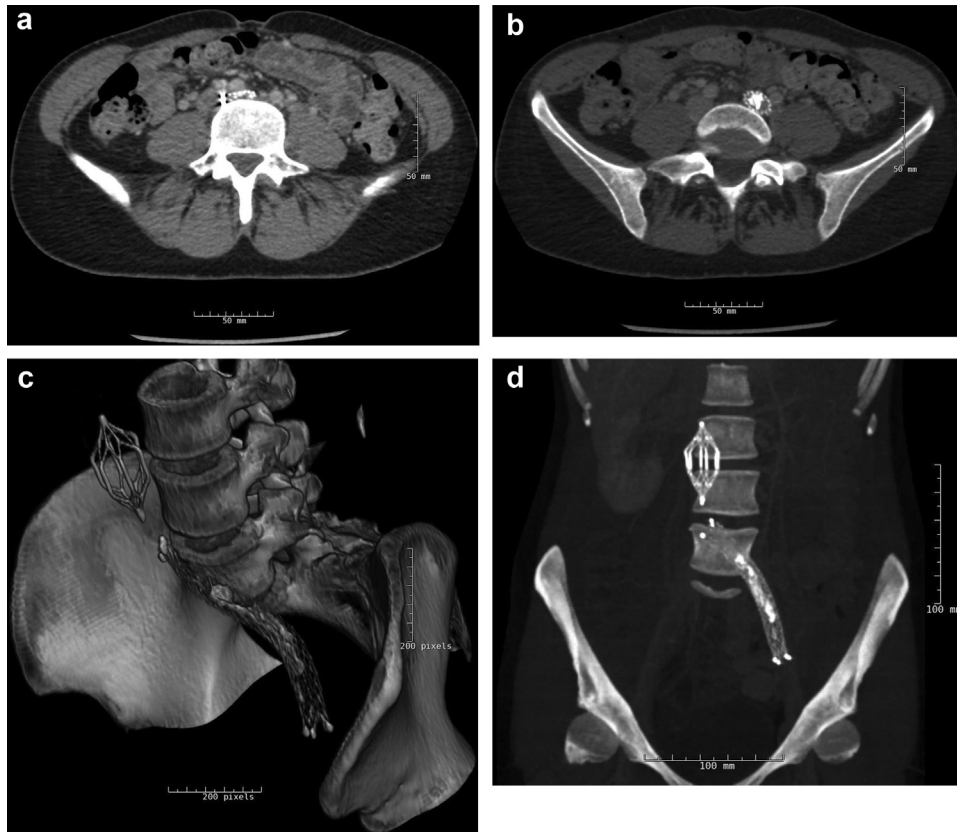

Fig 1. Computed tomography scans showing compression of the stent at the May-Thurner point (a) and high-density (calcified) material inside the stent distal to the compression (b). Three-dimensional reconstructions of these scans show the entire stent, including the compressed outflow and the calcified material within it as well as the vena cava filter (c and d).

strictly inside the stent with an 8F Rotarex catheter (Straub Medical AG, Wangs, Switzerland). The Rotarex catheter is an over-the-wire device, consisting of a catheter with a rotating head, spinning at 40,000 rpm, driven by an external motor. The rotating head detaches and fragments thrombus material from the vessel wall. An inner Archimedes screw inside the catheter, rotating at the same speed, creates a vacuum that aspirates the material and transports it out of the vessel. Although mechanical debulking of calcifications is not strict on-label use of the Rotarex catheter, it did remove some but far from all of the calcified material (visual estimate, 25%-50%; Fig 2).

After debulking, we preballooned the old stent with a 12-mm Atlas balloon (C. R. Bard Inc, Murray Hill, NJ), a noncompliant high-pressure balloon, at 16 bar, forcing the residual material into the vessel wall.

The lesion was then restented with a 12-mm, 15-cm sinus-Venous stent (Optimed GmbH, Ettlingen, Germany), a dedicated venous stent with a high radial force, covering the entire May-Thurner compression and the entire length of the previous stent, thus sandwiching the material between the two stents. The entire stent complex

was then postballooned with a 12-mm Atlas balloon at 14 bar to pack the sandwiched material as much as possible and to resolve the May-Thurner compression, thus restoring unobstructed outflow from the leg.

Final four-plane digital subtraction phlebography showed the new stent fully expanded, the May-Thurner compression completely resolved, and the residual material sandwiched between the stents (Fig 3). The cava filter was shown to be free of emboli and was removed at the end of the procedure. The patient experienced instant relief of symptoms and was discharged the following day on lifelong warfarin, 14 days of high-dose low-molecular-weight heparin, and 1 year with compression stockings.

On the first follow-up visits 6 weeks and 3 months after the procedure, she was asymptomatic, and duplex ultrasound showed normal flow in the deep veins including the stented area. Further follow-up visits are planned at 6, 9, 12, 18, and 24 months after the procedure.

CONCLUSIONS

With rising numbers of venous stents reaching a significant age, the number of late complications, such as stent

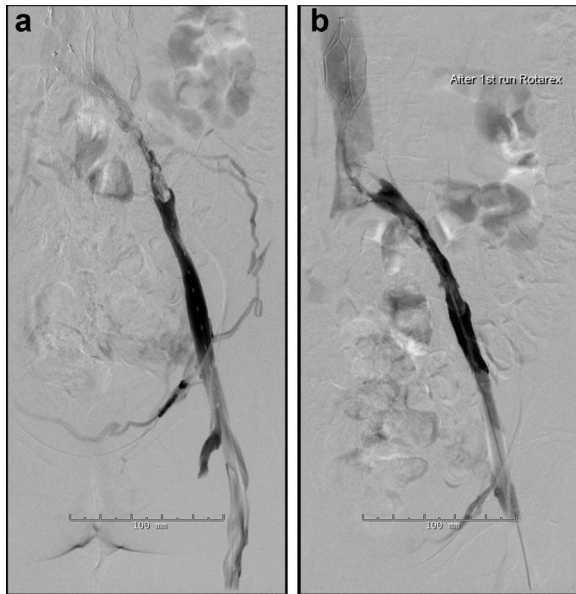

Fig 2. Digital subtraction phlebography showing the results after 48 hours of ultrasound-accelerated catheter-directed thrombolysis (UACDT, **a**) and after mechanical debulking with the Rotarex catheter (**b**).

restenosis and occlusion, may increase in the following years. Stent primary patency rates for stented chronic venous lesions are reported to be in the range of 57% to 79% at 72 months.⁵ Suggestions for treatment of in-stent restenosis and occlusion range from CDT with or without restenting to more technically advanced solutions, like percutaneous or open thrombectomy with or without restenting.

We here describe calcified in-stent restenosis as a rare late stent-related complication and show a feasible, minimally invasive, and supposedly safe way of treating the condition.

The large time span from initial treatment to occurrence of late complication in our case (10 years) indicates that prolonged stent surveillance may be indicated to detect restenosis before it leads to stent occlusion. At least this could be of benefit for individuals at risk (ie, for individuals with thrombophilia, after pregnancies, and for individuals with suboptimal initial treatment). More data on long-term follow-up of venous stents will be helpful in estimating the extent of the problem.

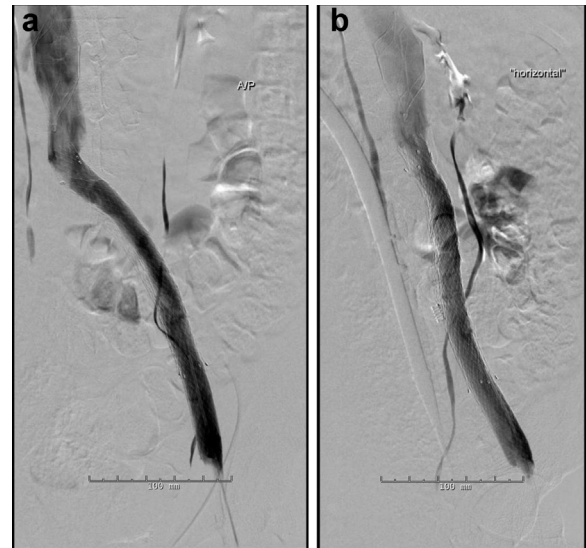


Fig 3. Digital subtraction phlebography in the anteroposterior projection (**a**) and at the same angle of view as the three-dimensional reconstruction in Fig 1, *c* (**b**) showing the re-established venous outflow through the left iliac veins. The new stent is fully expanded and covers the entire length of the old stent, including the May-Thurner point. The residual calcified material is sandwiched between the two stents on the inferior right-hand side.

We are deeply grateful to Dr Gerard O'Sullivan, University Hospital Galway, Ireland, for his swift and kind advice on this challenging case.

REFERENCES

1. Okrent D, Messersmith R, Buckman J. Transcatheter fibrinolytic therapy and angioplasty for left iliofemoral venous thrombosis. *J Vasc Interv Radiol* 1991;2:195-7.
2. Broholm R, Sillesen H, Damsgaard MT, Jørgensen M, Just S, Jensen LP, et al. Postthrombotic syndrome and quality of life in patients with iliofemoral venous thrombosis treated with catheter-directed thrombolysis. *J Vasc Surg* 2011;54(Suppl):18S-25S.
3. Bækgaard N, Broholm R, Just S. Indications for stenting during thrombolysis. *Phlebology* 2013;28(Suppl 1):112-6.
4. Comerota A. Deep venous thrombosis and postthrombotic syndrome: invasive management. *Phlebology* 2015;30(Suppl):59-66.
5. Neglén P, Hollis KC, Olivier J, Raju S. Stenting of the venous outflow in chronic venous disease: long-term stent-related outcome, clinical, and hemodynamic result. *J Vasc Surg* 2007;46:979-90.

Submitted May 30, 2015; accepted Jul 24, 2015.