



# EDP-M plus sintilimab in the treatment of adrenocortical carcinoma: a case report

Zhipeng Zhang<sup>1,2</sup>, Ningning Liu<sup>1,2</sup>, Qi Li<sup>1,2</sup>

<sup>1</sup>Department of Medical Oncology and Cancer Institute, Shuguang Hospital, Shanghai University of Traditional Chinese Medicine, Shanghai, China; <sup>2</sup>Academy of Integrative Medicine, Shanghai University of Traditional Chinese Medicine, Shanghai, China

Correspondence to: Qi Li, Ningning Liu. Department of Medical Oncology and Cancer Institute, Shuguang Hospital, Shanghai University of Traditional Chinese Medicine, 528 Zhangheng Road, Shanghai 201203, China. Email: qili@shutcm.edu.cn; liuningning689@126.com.

**Background:** Adrenocortical carcinoma (ACC) is a rare malignancy occurring in the adrenal cortex characterized by its low incidence rate, aggressive tumor behavior with high propensity of invasion and distant metastasis, and poor prognosis. When detected, it usually appears as advanced tumor with limited treatment options. Systemic chemotherapy is the only recommended treatment option and EDP-M plus sintilimab has recently emerged as a new treatment option. In the present study, we report a case of ACC treated with EDP-M plus sintilimab.

**Case Description:** We present a 30-year-old female patient with ACC and bilateral lung metastases. PET-CT scan showed multiple metastatic sites in both lungs, among which the largest one was located in the lower lobe of the right lung, with a size of 42 mm × 22 mm. A space-occupying lesion was also found in the right adrenal gland with a size of 92 mm × 51 mm. The patient was treated with EDP plus sintilimab for four cycles in our hospital and mitotane was introduced after the first cycle. Follow-ups after the second and fourth cycles found significantly reduced lung metastases with all imaging examinations indicating PR status. The patient received maintenance therapy thereafter with sintilimab plus mitotane. Until recently, the patient's lung metastases have basically disappeared and no disease progression has been observed. The progression free survival (PFS) of this patient has been extended to about 7 months.

**Conclusions:** Although deemed as the standard chemotherapeutic regimen for advanced ACC, the efficacy of EDP-M is not satisfactory. This case study demonstrates the clinical effectiveness of EDP-M plus sintilimab in the treatment of advanced ACC with good patient tolerance, suggesting that this regimen combination can be a promising treatment option for refractory ACCs.

**Keywords:** Adrenocortical carcinoma (ACC); EDP-M plus sintilimab; clinical efficacy; adverse effects; case report

Submitted Sep 17, 2021. Accepted for publication Feb 24, 2022.

doi: 10.21037/tcr-21-1993

View this article at: <https://dx.doi.org/10.21037/tcr-21-1993>

## Introduction

EDP-M (etoposide, doxorubicin, cisplatin and mitotane) is considered the first-line treatment for advanced adrenocortical carcinoma (ACC) due to its efficacy to potentially prolong patients' overall survival, which can result in stable disease (SD) status in about 50% of the patients. However, the objective response rate is less than 25% (1). The prognosis of advanced ACC remains poor, and new therapeutic strategies are warranted (2). Sintilimab,

a fully human immunoglobulin G4 (IgG4) monoclonal antibody, can effectively bind to PD-1 receptor and block its interaction with PD-L1 and PD-L2, inhibit the immunosuppressive response mediated by PD-1 pathway, and activate the immune surveillance and killing effect of T cells on tumor (3). The goal of this study is to investigate the efficacy and safety of EDP-M plus sintilimab in the treatment of ACC. ACC is a rare and highly invasive malignancy with an annual incidence of 0.7–2.0 per million people, which can occur at any age with a peak age of

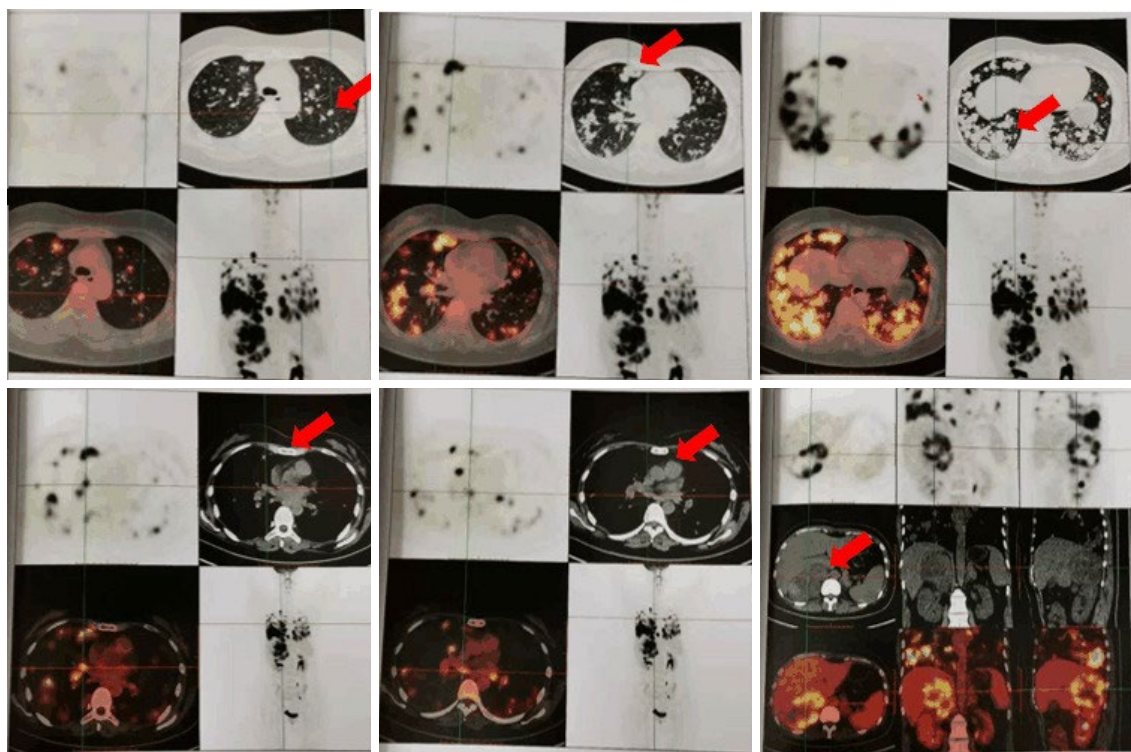
40–50 years old. The incidence of ACC is slightly higher in women (55–60%) (4), and in children southern Brazil has the highest prevalence of 0.27%, which is mainly due to specific *TP53* gene germline mutations (R337H). Patients with stage I and stage II ACC can be cured by radical surgery, and the 5-year survival rate can be up to 60–80%; while patients with local (stage III) or advanced disease (stage VI) ACC would have a 5-year survival of only 30% to 50% or less than 25% despite ongoing adjuvant therapy (5). EDP-M is a commonly used chemotherapeutic regimen in patients with advanced ACC. Etoposide (VP-16), a cell cycle-specific anti-tumor agent, is an effective component of lignans isolated from podophyllin. VP-16 acts on topoisomerase II in S or G2 phase and leads to the formation of a stable cleavable complex (drug-enzyme-DNA), thus hindering DNA repair and playing its anti-tumor role (6). Moreover, cisplatin, a metal complex of platinum, is an alkylating agent mainly targeting the DNA. Cisplatin interacts with DNA inter- and intra-strand crosslinks to form DDP~DNA complex, and thereby interfere DNA replication, affect its synthesis and promote the apoptosis of cancer cells (7). Doxorubicin forms complex with DNA by inserting DNA base pairs, which results in inhibition of DNA replication and transcription and consequently the proliferation of tumor cells (8). In short, the above three chemotherapeutic drugs all act on the G0/G1 phase of the cell cycle, interfere with the synthesis of DNA, and kill or inhibit tumor cells. Mitotane (O, P0-DDD (1 - (o-chlorophenyl) - 2,2-dichloroethane)) is a derivative of the insecticide dichlorodiphenyl trichloroethane with a high response rate in the treatment of ACC (about 30–50% of the patients respond to mitotane) (9). Its main mechanism of action is the destruction of mitochondria of adrenocortical cells as well as the cellular atrophy and necrosis of the cortical fascicular and reticular zones. Clinically, mitotane has been demonstrated to be effective against tumor growth and in symptomatic alleviation in functional ACC through blocking the synthesis and secretion of cortisol and androgen. It is mainly used in unresectable ACC patients or those with local recurrence and metastasis that cannot be re-resected (10).

Although EDP-M is the standard chemotherapy regimen in the treatment of advanced ACC, its curative effect is not satisfactory. Immune checkpoint inhibitors (ICIs) have greatly revolutionized and shifted the paradigm of cancer treatment. Programmed PD-1/PD-L1 checkpoint pathway is one of several pathways to regulate T cell activation and maintain its tolerance to autoantigens. PD-L1 is expressed

on the surface of various types of tumor cells and can bind to PD-1 on tumor infiltrating T cells, and thereby inhibits T cell activation and cytotoxicity while facilitates tumor cells to escape immune surveillance. Consequently, tumor cells continue to proliferate, grow and metastasize (11). As a fully human high-affinity monoclonal antibody, sintilimab targets PD-1 and PD-L1 and restores T cell-mediated killing function of tumor cells by blocking the interaction between PD-1 and PD-L1/PD-L2 (12). Compared to humanized antibodies, sintilimab can minimize the immunogenic issues caused by chimeric antibodies or humanized antibodies due to species differences and reduce the production of neutralizing antibodies or drug-resistant antibodies against therapeutic antibodies. As a fully human antibody, the CDR sequence and frame region sequence of sintilimab are derived from human. In the comprehensive treatment of cancer, immunotherapy plus chemotherapy is not only a good treatment combination, but also a treatment modality with good therapeutic effect. Clinically, chemotherapy can directly kill malignant tumor cells, present and activate tumor antigens, and provide prerequisites needed for immunotherapy. The combination of the two can truly complement each other and give full play to the role of anti-tumor efficacy. To our knowledge, few study evaluating the efficacy and safety of immunotherapy in ACC has been reported. Despite few clinical data, no large clinical trials supporting the efficacy of EDP-M plus sintilimab is available in the treatment of ACC. This paper reports a case of advanced ACC treated with EDP-M plus sintilimab, which may provide new insight for future clinical research. We present the following case in accordance with the CARE reporting checklist (available at <https://tcrcr.com/article/view/10.21037/tcr-21-1993/rc>).

### Case presentation

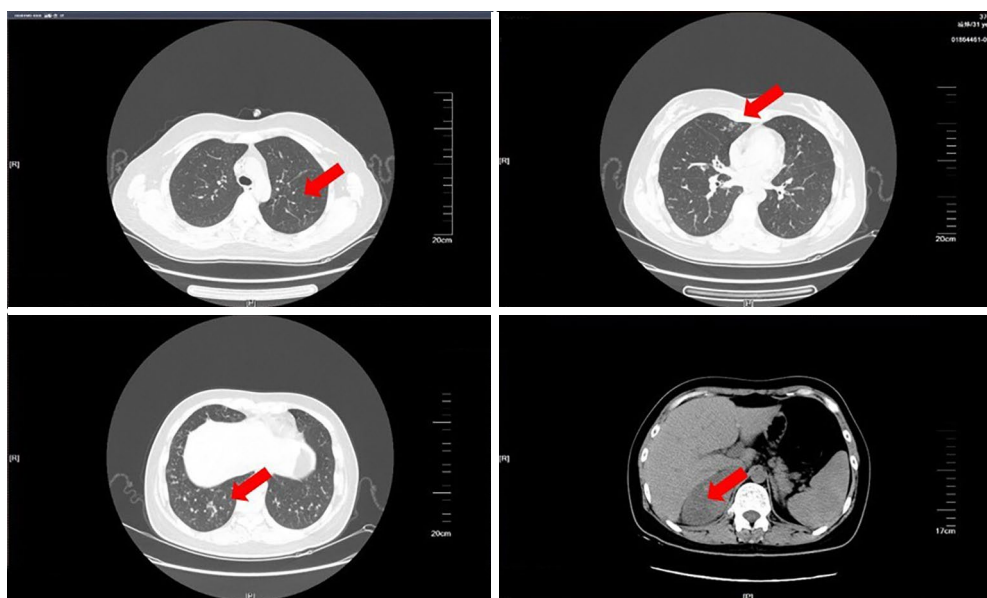
The patient, a 30-year-old female Han Chinese working as an office clerk, went to our hospital complaining of cough, chest tightness and wheezing for more than two months which had aggravated for one week. On September 21, 2020, she went to Shanghai Lung Hospital for PET-CT examination, which revealed diffuse nodules and masses with abnormal glucose metabolism in both lungs. The largest lesion was located in the right lower lobe with a size of 42 mm × 22 mm and SUVmax of 19.71. Lymph nodes with abnormal glucose metabolism were seen in the mediastinum station 7 and the bilateral hilum, of which the largest one was located in the right hilum with a size of



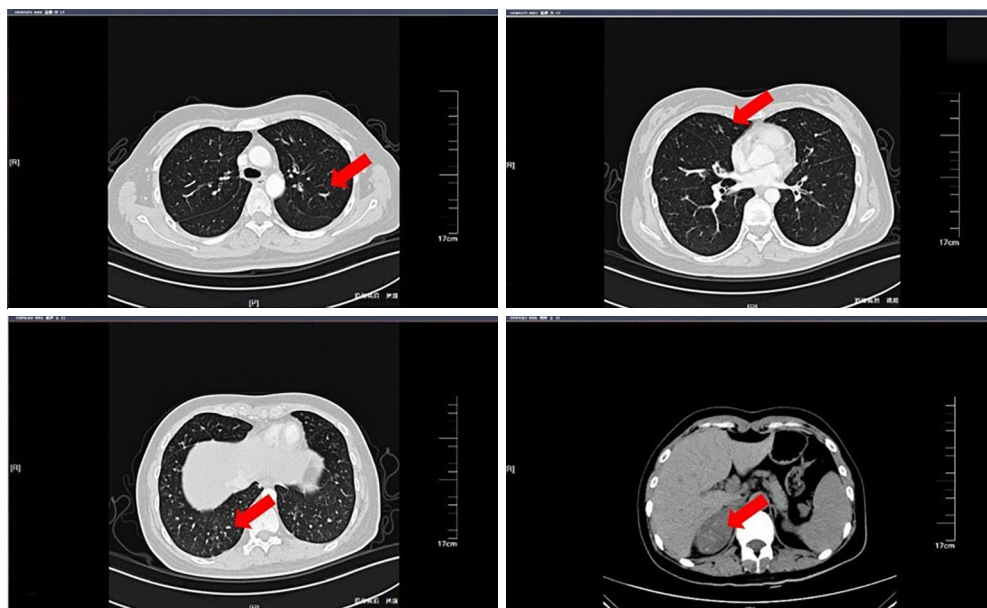
**Figure 1** PET-CT showed soft tissue mass in the right adrenal gland and multiple metastases in both lungs before treatment with EDP-M plus sintilimab. Arrows indicate metastatic lesions in the lung and primary lesions in the right adrenal gland. PET-CT, positron emission tomography computed tomography; EDP-M, etoposide, doxorubicin, cisplatin and mitotane.

16 mm × 9 mm and SUVmax of 14.05. Meanwhile, a soft tissue mass with abnormally elevated glucose metabolism was seen in the right adrenal region with a maximum cross section of approximately 99 mm × 59 mm and SUVmax of 23.02. The mass was lobulated at its margins and the adjacent liver and kidney were compressed; Lymph nodes with mildly increased glucose metabolism was found adjacent to the abdominal aorta, of which the largest one was approximately 8 mm × 5 mm in size with SUVmax of 2.21 (*Figure 1*). Lung biopsy with immunohistochemistry on September 30, 2020 confirmed the diagnosis of ACC in the right lung with multiple metastases. Immunohistochemical results revealed following results: CK (-), vimentin (+), TTF-1 (-), napsina (-), syn (+), CGA (-), CD56 (+), NSE (+/-), insm1 (partially weak +), P40 (-), Melan-A (partially +), D2-40 (-), ZEB1 (-), CD31 (vascular +). The diagnosis was made accordingly as (right) adrenal malignancy with metastases in the bilateral clavicular region, mediastinum, bilateral pulmonary hilum, retroperitoneal lymph nodes and both lungs (cT4N1M1 stage IV). Patient received EDP plus sintilimab for one cycle in our hospital on October 8th,

2020 with the following specific regimen: sintilimab 200 mg D1 + etoposide 150 mg D1-3 + doxorubicin liposome 40 mg D1 + cisplatin 40 mg D1-3. Patient was started on oral mitotane (2 g, three times a day) 10 days after the initiation of EDP plus sintilimab. The second cycle of EDP-M plus sintilimab was started on November 4, 2020. Chest CT scan on November 25, 2020 showed multiple metastases in both lungs, of which the largest one was located in the right lower lobe with a size of about 24 mm × 6 mm. The lesion was found to be smaller in size compared with the previous finding in PET-CT on September 21, 2020. Meanwhile, the lymph nodes in the mediastinum and right hilum were mildly enlarged which was smaller than before. The space-occupying lesion in the right adrenal gland was about 92 mm × 51 mm in size, which was smaller compared with the previous finding. The lesion was evaluated as PR according to RECIST1.1 (*Figure 2*). The third and fourth cycles of treatment were started on November 27, 2020 and December 18, 2020, respectively with the same regimen described above. Chest CT scan on January 8, 2021 showed multiple metastases in both lungs, of which the larger one



**Figure 2** CT showed that after two cycles of chemotherapy, the tumor located in the right lower lobe had significant reduction in size. Arrows indicate lung metastasis and the primary lesion in the right adrenal gland.



**Figure 3** CT showed that after four cycles of chemotherapy, the tumor located in the right lower lobe had further significant reduction in size. Arrows indicated lung metastasis and the primary lesion in the right adrenal gland.

was located in the right lower lobe with a size of about 9 mm × 2 mm. Mildly enlarged lymph nodes were also found in the mediastinum and right hilum with the size similar to the previous finding on November 25, 2020. The space-occupying lesion in the right adrenal gland was about

78 mm × 37 mm in size, which was smaller compared with the previous finding. The disease was re-evaluated as PR according to RECIST1.1 (Figure 3). The patient was subsequently given maintenance therapy with sintilimab 200 mg plus mitotane, during which adverse events such as

mild diet loss (grade 1), hand and foot syndrome (grade 2), constipation (grade 2), myelosuppression (grade 2) and alopecia (grade 3) occurred. Recent follow-up found that the patient was generally in good condition, without symptoms such as cough, chest tightness or asthma. Follow-up chest CT scan indicated no disease progression. Thus, the progression-free survival (PFS) of the patient has been extended to about 5 months so far.

All procedures performed in this study were in accordance with the ethical standards of the institutional and/or national research committee(s) and with the Helsinki Declaration (as revised in 2013). Written informed consent was obtained from the patient for publication of this case report and accompanying images. A copy of the written consent is available for review by the editorial office of this journal.

## Discussion

ACC is an extremely rare malignancy originating from the adrenal cortex with low incidence, aggressive tumor behavior, low rate of early diagnosis and poor prognosis. Surgical resection is the treatment of choice for stage I and stage II ACC, which is also the only potentially curable therapy for ACC (13). Mitotane is a commonly used agent preferably for patients with unresectable or recurrent ACC, with the highest response rate in the treatment of ACC. Whether mitotane should be administered in postoperative adjuvant treatment remains controversial. Nevertheless, mitotane is recommended as adjuvant treatment for histologically confirmed high-grade giant tumors (regardless of tumor size, Ki-67 staining tumor cells >10%, >20 nuclear divisions per 50HPF) and low-grade tumor with intraoperative spillage or rupture (14). Studies have shown that mitotane primarily acts on cell mitochondria in the adrenal cortex to induce its degeneration and necrosis, and thereby activates apoptotic processes involving caspase 3 and caspase 7 activations (15). Mitotane is also able to interfere with mitochondrial respiratory chain functional complex IV (cytochrome oxidase) and induce morphological fragmentation of mitochondrial membranes required for respiratory chain activity and steroid synthesis (16). A study included 391 patients diagnosed with advanced ACC evaluated the role of mitotane monotherapy in the treatment of advanced ACC and found 26 (20.5%) patients had objective response, including 3 complete responses. The overall median PFS and OS was 4.1 and 18.5 months, respectively, demonstrating that mitotane is effective against advanced ACC (17). In a recent retrospective

analysis enrolling 36 patients with metastatic ACC treated with mitotane monotherapy as the first-line therapy, 3 (8%) patients had complete response, 1 (3%) had partial response, and one (3%) had stabilization after slow disease progression (duration of 6 months). This study demonstrated high complete response rates to mitotane treatment in patients with metastatic ACC (18).

Mitotane monotherapy is suitable for patients with low tumor load and slow disease progression. However, for patients with rapidly progressing ACC or multiple metastases, cytotoxic chemotherapy plus mitotane would be a more reasonable option. EDP-M is currently the standard chemotherapy regimen in the first line treatment of advanced ACC (19). In a randomized phase-III FIRM-ACT study, the overall survival of patients with advanced ACC treated with EDP-M (etoposide, doxorubicin, cisplatin and mitotane) tended to be prolonged, but no significant difference was found when compared with Sz-M (streptozotocin and mitotane) therapy (14.8 *vs.* 12.0 months). Nevertheless, EDP-M significantly prolonged the time of tumor progression compared with Sz-M (5.0 *vs.* 2.1 months) (4). In a clinical trial evaluating second-line therapies for ACC, 145 patients with advanced disease received a gemcitabine-based chemotherapy (gemcitabine + capecitabine), either in combination with mitotane or not. The results showed a median PFS of 12 weeks and partial response or stable disease were achieved in 4.9% and 25.0% of the patients, respectively. The treatment was generally well tolerated, but with limited efficacy (20).

Despite the advantages of EDP-M, the mean survival rate of patients with advanced ACC is still frustrating. Currently, immunotherapy has brought revolutionary changes to cancer treatment, exemplified by the emerging of monoclonal antibodies such as CTLA-4, PD-1 and PD-L1 and their promising anti-tumor activity in different solid tumors. The role of these antibodies have drawn researchers' interest in exploring their efficacy in the setting of ACC (21). In a phase II study of pembrolizumab that enrolled 39 patients with advanced ACC, the clinical activity of 200 mg pembrolizumab every 3 weeks was assessed regardless of the prior therapy received. This study reported an objective response rate of 23% (9 patients) and a disease control rate of 52% (16 patients). Meanwhile, the median duration of response has not yet been reached, while the median progression free survival (PFS) was 2.1 months and the median overall survival was 24.9 months, indicating that pembrolizumab has durable antitumor activity and clinical safety profile (22). Another phase II study of

pembrolizumab in patients with advanced rare cancers that enrolled 15 patients with ACC showed that the PFS of the 4 patients was 31%, the overall objective effective rate (ORR) was 15%, and the clinical benefit rate (CBR) was 54% from study initiation to 27 weeks. It also reported certain anticancer effect of pembrolizumab in patients with ACC (23). In a recent phase II trial of nivolumab enrolling 10 patients with metastatic ACC, the median PFS was 1.8 months, in which 2 patients were in stable condition that lasted for 48 and 11 weeks, respectively, demonstrating good anti-tumor activity of nivolumab (24).

Immunochemotherapy is gaining momentum as a promising option for the comprehensive treatment of various malignancies. ICIs used synergistically with chemotherapy agents can enhance antitumor effect, change the body's immune suppression state and enhance its antitumor function, increase the lymphatic system identification of tumor antigens, increase the recognition of tumor antigens by the lymphatic system, and thereby exert non-specific immune effects. Meanwhile, the combined therapy can improve anti-tumor activity, exert specific killing effect of small tumors and micrometastasis and thereby inhibits tumor recurrence and metastasis and prolong patient survival. Sintilimab is a PD-1 ICI developed in China. Currently there are no clinical studies reporting the combination of chemotherapy and mitotane in the treatment of ACC. Therefore, the patient in this study signed the informed consent for off-label use of medication. The patient was evaluated as PR after both two and four cycles of treatment with EDP-M plus sindilizumab, followed by sindilizumab plus mitotane as maintenance therapy. So far, the patient has achieved PFS of almost 5 months and are now under surveillance.

The main adverse events during treatment were diet loss, hand and foot syndrome, constipation, myelosuppression, and alopecia (21,25). In this study, infusion reactions such as shivering, palpitation and chest tightness occurred during the treatment, which was alleviated by discontinuation or delay of infusion. Other side effects, such as grade I anorexia, grade II constipation, grade 2 myelosuppression and grade 3 alopecia, were also well managed.

To our knowledge, this study is the first clinical report on first-line treatment of ACC with EDP-M combined with sintilimab. In spite of the adverse events, patient tolerance is acceptable and objective responses have been identified. There have been no large clinical studies to guide the indications of sintilimab for ACC, as well as the role of PD-1 and EDP plus mitotane. Despite the good clinical

effect shown in patient medical record, we did not test the expressions of PD-L1, TMB and MSI/MMR in this patient. Therefore, it needs to be verified by studies with larger sample size and its specific mechanism needs to be further explored.

In conclusion, we report a case of adrenocortical carcinoma treated with EDP-M plus sintilimab, which showed significant response with few signs of residual tumor viability in metastatic sites. Considering the limited treatment options and poor survival associated with ACC, the present case may provide a new insight for decision making of treatment modalities for ACC.

### Acknowledgments

We would like to thank Han Zhang for his help in polishing our paper.

*Funding:* None.

### Footnote

*Reporting Checklist:* The authors have completed the CARE reporting checklist. Available at <https://tcr.amegroups.com/article/view/10.21037/tcr-21-1993/rc>

*Conflicts of Interest:* All authors have completed the ICMJE uniform disclosure form (available at <https://tcr.amegroups.com/article/view/10.21037/tcr-21-1993/coif>). The authors have no conflicts of interest to declare.

*Ethical Statement:* The authors are accountable for all aspects of the work in ensuring that questions related to the accuracy or integrity of any part of the work are appropriately investigated and resolved. All procedures performed in this study were in accordance with the ethical standards of the institutional and/or national research committee(s) and with the Helsinki Declaration (as revised in 2013). Written informed consent was obtained from the patient for publication of this case report and accompanying images. A copy of the written consent is available for review by the editorial office of this journal.

*Open Access Statement:* This is an Open Access article distributed in accordance with the Creative Commons Attribution-NonCommercial-NoDerivs 4.0 International License (CC BY-NC-ND 4.0), which permits the non-commercial replication and distribution of the article with the strict proviso that no changes or edits are made and the

original work is properly cited (including links to both the formal publication through the relevant DOI and the license). See: <https://creativecommons.org/licenses/by-nc-nd/4.0/>.

## References

- Kerkhofs TM, Ettaieb MH, Hermsen IG, et al. Developing treatment for adrenocortical carcinoma. *Endocr Relat Cancer* 2015;22:R325-38.
- Altieri B, Ronchi CL, Kroiss M, et al. Next-generation therapies for adrenocortical carcinoma. *Best Pract Res Clin Endocrinol Metab* 2020;34:101434.
- Han Y, Liu D, Li L. PD-1/PD-L1 pathway: current researches in cancer. *Am J Cancer Res* 2020;10:727-42.
- Fassnacht M, Dekkers OM, Else T, et al. European Society of Endocrinology Clinical Practice Guidelines on the management of adrenocortical carcinoma in adults, in collaboration with the European Network for the Study of Adrenal Tumors *Eur J Endocrinol* 2018;179:G1-G46.
- Jasim S, Habra MA. Management of Adrenocortical Carcinoma. *Curr Oncol Rep* 2019;21:20.
- Oviatt AA, Kuriappan JA, Minniti E, et al. Polyamine-containing etoposide derivatives as poisons of human type II topoisomerases: Differential effects on topoisomerase II $\alpha$  and II $\beta$ . *Bioorg Med Chem Lett* 2018;28:2961-8.
- Qi L, Luo Q, Zhang Y, et al. Advances in Toxicological Research of the Anticancer Drug Cisplatin. *Chem Res Toxicol* 2019;32:1469-86.
- Chen C, Lu L, Yan S, et al. Autophagy and doxorubicin resistance in cancer. *Anticancer Drugs* 2018;29:1-9.
- Creemers SG, Hofland LJ, Korpershoek E, et al. Future directions in the diagnosis and medical treatment of adrenocortical carcinoma. *Endocr Relat Cancer* 2016;23:R43-69.
- Corso CR, Acco A, Bach C, et al. Pharmacological profile and effects of mitotane in adrenocortical carcinoma. *Br J Clin Pharmacol* 2021;87:2698-710.
- Baumeister SH, Freeman GJ, Dranoff G, et al. Coinhibitory Pathways in Immunotherapy for Cancer. *Annu Rev Immunol* 2016;34:539-73.
- Hoy SM. Sintilimab: First Global Approval. *Drugs* 2019;79:341-6.
- Gaujoux S, Mihai R; joint working group of ESES and ENSAT. European Society of Endocrine Surgeons (ESES) and European Network for the Study of Adrenal Tumours (ENSAT) recommendations for the surgical management of adrenocortical carcinoma. *Br J Surg* 2017;104:358-76.
- Calabrese A, Basile V, Puglisi S, et al. Adjuvant mitotane therapy is beneficial in non-metastatic adrenocortical carcinoma at high risk of recurrence. *Eur J Endocrinol* 2019;180:387-96.
- Lehmann TP, Wrzesiński T, Jagodziński PP. The effect of mitotane on viability, steroidogenesis and gene expression in NCI-H295R adrenocortical cells. *Mol Med Rep* 2013;7:893-900.
- Hescot S, Slama A, Lombès A, et al. Mitotane alters mitochondrial respiratory chain activity by inducing cytochrome c oxidase defect in human adrenocortical cells. *Endocr Relat Cancer* 2013;20:371-81.
- Megerle F, Herrmann W, Schloetelburg W, et al. Mitotane Monotherapy in Patients With Advanced Adrenocortical Carcinoma. *J Clin Endocrinol Metab* 2018;103:1686-95.
- Reidy-Lagunes DL, Lung B, Untch BR, et al. Complete Responses to Mitotane in Metastatic Adrenocortical Carcinoma-A New Look at an Old Drug. *Oncologist* 2017;22:1102-6.
- Stigliano A, Chiodini I, Giordano R, et al. Management of adrenocortical carcinoma: a consensus statement of the Italian Society of Endocrinology (SIE). *J Endocrinol Invest* 2016;39:103-21.
- Henning JEK, Deutschbein T, Altieri B, et al. Gemcitabine-Based Chemotherapy in Adrenocortical Carcinoma: A Multicenter Study of Efficacy and Predictive Factors. *J Clin Endocrinol Metab* 2017;102:4323-32.
- Varghese J, Habra MA. Update on adrenocortical carcinoma management and future directions. *Curr Opin Endocrinol Diabetes Obes* 2017;24:208-14.
- Raj N, Zheng Y, Kelly V, et al. PD-1 Blockade in Advanced Adrenocortical Carcinoma. *J Clin Oncol* 2020;38:71-80.
- Naing A, Meric-Bernstam F, Stephen B, et al. Phase 2 study of pembrolizumab in patients with advanced rare cancers. *J Immunother Cancer* 2020;8:e000347.
- Carneiro BA, Konda B, Costa RB, et al. Nivolumab in Metastatic Adrenocortical Carcinoma: Results of a Phase 2 Trial. *J Clin Endocrinol Metab* 2019;104:6193-200.
- Uchihara M, Tanioka M, Kojima Y, et al. Clinical management and outcomes associated with etoposide, doxorubicin, and cisplatin plus mitotane treatment in metastatic adrenocortical carcinoma: a single institute experience. *Int J Clin Oncol* 2021;26:2275-81.

**Cite this article as:** Zhang Z, Liu N, Li Q. EDP-M plus sintilimab in the treatment of adrenocortical carcinoma: a case report. *Transl Cancer Res* 2022;11(6):1829-1835. doi: 10.21037/tcr-21-1993