

# Insulinoma: a quarter century of dietary control

Hessa Boharoon<sup>1</sup>, Shaunak Navalkisoor<sup>2</sup>, Tu Vinh Luong<sup>3</sup>, Martyn Caplin<sup>1</sup> and Ashley Grossman<sup>1</sup>

<sup>1</sup>Neuroendocrine Tumour Unit, ENETS Centre of Excellence, London, UK, <sup>2</sup>Department of Nuclear Medicine, and <sup>3</sup>Department of Pathology, Royal Free Hospital, London, UK

Correspondence  
should be addressed  
to H Boharoon  
**Email**  
[dr.hesssa@gmail.com](mailto:dr.hesssa@gmail.com)

## Summary

Insulinomas are rare pancreatic neuroendocrine neoplasms (NENs) that are typically sporadic and solitary, with the majority being <2 cm in diameter at diagnosis. The median duration of symptoms before diagnosis is variable; however, this is usually in the region of 12–18 months. We report on an insulinoma diagnosed some 25 years following initial symptoms, having by that stage attained a diameter of 4 cm. We present a 50-year-old man who was reported with hypoglycaemic symptoms on his wedding 25 years prior to eventual confirmation of an insulinoma. He had since learned to live with the symptoms by eating frequently to manage his hypoglycaemia. However, over recent months, he reported a substantial deterioration in his symptoms, and indeed, had collapsed on two occasions. He had a fasting glucose of 2.9 mmol/L with grossly inappropriate elevated insulin and C-peptide levels. MRI demonstrated a 4.1 cm lesion at the body of pancreas and an indeterminate 9-mm liver lesion with a negative <sup>68</sup>Gallium-DOTATATE PET scan. Accordingly, he was initiated on diazoxide and referred to the surgical team for distal pancreatectomy: histology confirmed a 4.4-cm well-differentiated pancreatic NEN of intermediate grade (NEN G2, Grade 2, 2017 World Health Organization (WHO) pancreatic-NEN classification), with positive immunohistochemistry for insulin. His hypoglycaemia episodes have ceased, and he remains under active surveillance. Our case demonstrates the possibility of dietary control of insulinoma-induced hypoglycaemia, and the likelihood that such a prolonged delay in diagnosis has led to the uncommonly large size of the apparently benign tumour which is usually 'small and indolent'.

## Learning points

- Most patients with insulinomas have lesions that are 1–2 cm in size, with 96% being less than 3 cm.
- The mean tumour size of insulinomas found in 3 of the largest reported series was 1.5 cm, with a range of 0.1–7.0 cm.
- It is not uncommon for patients to have symptoms for several months to years before diagnosis; however, no reported cases had the symptoms such long for 25 years, and the large size of the tumour in this case may reflect the very long history.

## Background

This case report emphasises some unusual features of an insulinoma of which a clinician should be aware, including an extremely large tumour size in the absence of definite features of malignancy, and the longevity of the symptoms which were managed by diet.

## Case presentation

A 50-year-old man was referred to our neuroendocrine tumour unit with a recent history of apparent hypoglycaemic attacks. However, he said that his 'attacks' actually first occurred on his wedding day in Pakistan; he became non-specifically unwell on that day and was



taken to a local hospital where he was told that he had a very low blood sugar level. Following this diagnosis, no specific treatment was initiated, however he had to take at least three meals to avoid hypoglycemic attacks, which manifested as ‘pins-and needles’ in his arms and tongue. In addition, he would become confused. He discovered that as long as he had his three regular meals a day he could avoid these problems, but if he missed out any food, the problems developed and could be severe. On many occasions, he reported he became rather confused but found that a glucose-rich snack effectively terminated his symptoms. These episodes remained stable over time, and he moved to the UK 12 years ago. He continued to be managed without medical advice with frequent meals. However, 3 months prior to being seen he had noticed a rapid deterioration in his symptoms; indeed, on two occasions he had collapsed. He said that he could now not go for more than 2 h without eating. He was otherwise well and was just taking amlodipine 5 mg a day for hypertension for the previous 6 months. He had no other significant past medical history, and he had not noticed any change in weight, while in his family there was just a history of type 2 diabetes mellitus. He is a nonsmoker. He has recently taken on a new position as a healthcare trainer and has 3 children between 12 and 23 years, all of whom are well. There was no family history of hyperparathyroidism, ulcer disease, or unexplained hypoglycaemia. On examination, he looked generally well, with a blood pressure of 140/90 mm Hg, weight: 69.7 kg, height: 170.4 cm, and BMI: 24 kg/m<sup>2</sup>. There was no abnormality in any system examined.

## Investigation

The result of an overnight fasting glucose was 2.9 mmol/L in conjunction with grossly elevated insulin and C-peptide levels (see Table 1), a normal cortisol response to a short Synacthen test (30 min, 487 nmol/L), and plasma adrenocorticotrophic hormone 27 ng/L. Threshold levels for diagnosis of hyperinsulinism in patients with hypoglycaemia of 3 mmol/L or less have

**Table 1** Blood results.

Baseline laboratory tests	Results
Glucose (mg/dL (mol/L))	52.2 (2.9)
Insulin (pmol/L)	247
C-peptide (pmol/L)	3101
24 h urine for sulfonylureas	Negative
Adrenal antibodies	Negative
HbA1c (mmol/mol)	36

been recommended (10): insulin (by IRMA) > 36 pmol/L, C-peptide ≥ 200 pmol/L, and proinsulin ≥ 5 pmol/L.

On another occasion, his glucose level spontaneously dropped to 2.0 mmol/L, at which point his C-peptide and insulin levels were again grossly elevated. He had a sulfonylurea screen that was negative. The results of his subsequent laboratory evaluation are detailed in Table 1. An MRI scan revealed a 4.1 cm pancreatic lesion which was partially necrotic, as well as an indeterminate 9-mm arterially enhancing lesion within his liver (Fig. 1). A <sup>68</sup>Gallium-DOTATATE PET scan demonstrated no avidity in the body of the pancreas lesion or in the indeterminate lesion in segment 4a of the liver (Fig. 1).

## Treatment

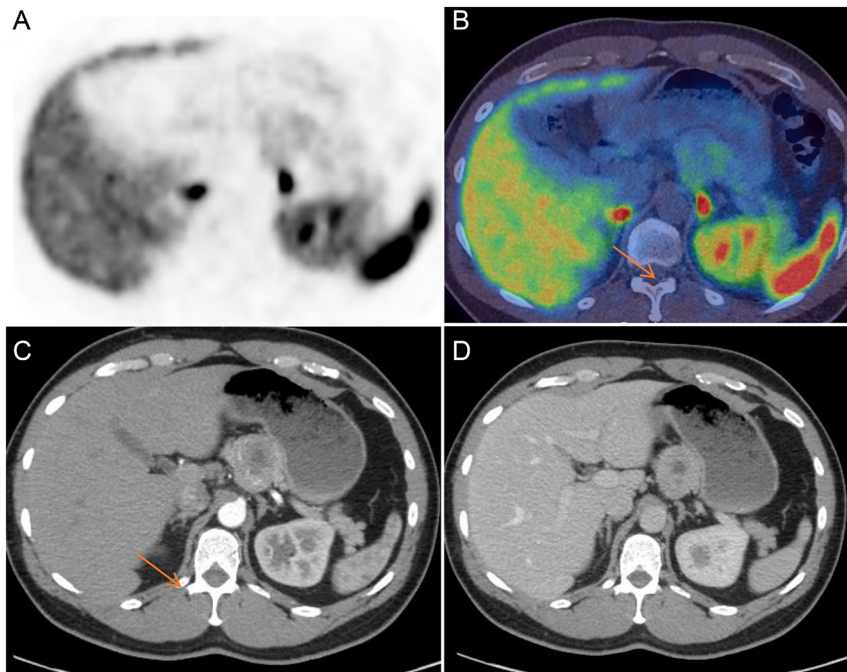
He was diagnosed with an insulinoma plus an indeterminate liver lesion and underwent an open distal pancreatectomy, splenectomy, cholecystectomy, and liver wedge biopsy. At operation, a 55 × 146 × 49 mm tumour was resected from the distal pancreas. There was no evidence of gross invasion, abnormal lymph nodes, or liver metastases. Pathological evaluation revealed a well-differentiated insulinoma (Fig. 2C), with a Ki-67 of 4% and less than 1 mitosis per 10 high power field (HPF). There was no local or microscopic vascular invasion. Immunohistochemical studies using an immunoperoxidase method demonstrated tumour cells positive for CAM5.2, chromogranin, synaptophysin, and insulin and negative for CK19, glucagon, and somatostatin (Fig. 2B). The tumour was classified as an insulinoma, according to European Neuroendocrine Tumor Society TNM stage (2006): pT3 N0 (0/11) V1 M0. The segment 4b lesion was diagnosed as focal nodular hyperplasia and negative for metastatic neuroendocrine tumour markers.

## Outcome and follow-up

His postoperative course was complicated by a low-output pancreatic fistula which rapidly resolved. His blood random blood glucose levels post-surgery varied between 6.5 and 10.5 mmol/L. Some 6 months post-surgery, he remains well, is eating normally, and has had no further hypoglycaemic episodes.

## Discussion

We report a case of a large insulinoma measuring over 4 cm in a patient who had apparently first reported hypoglycaemic symptoms some 25 years earlier, with later symptoms compatible with hypoglycaemia avoided

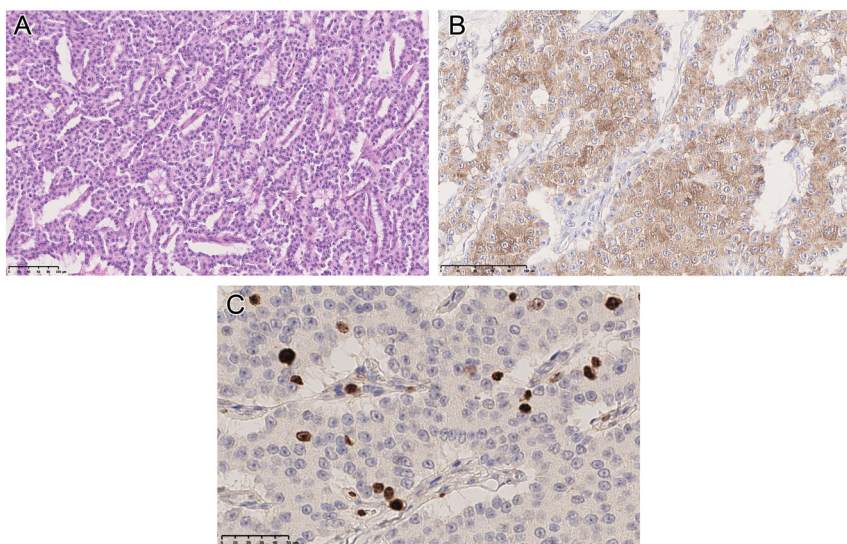


**Figure 1**  
<sup>68</sup>Ga-dotatate PET/CT (A) PET, (B) fused PET/CT, (C) CT arterial phase CT, and (D) portovenous phase CT.

or aborted by food, especially carbohydrate-rich meals. While the tumour was large, which is relatively unusual for an insulinoma, there was no evidence of local invasion or metastases to the regional lymph nodes or liver. Most patients with insulinomas have benign lesions that are 1–2 cm in size, with 96% being less than 3 cm (1). While the WHO considers all insulinomas may be potentially metastatic, those which are ‘small and indolent’ very rarely demonstrate malignant or metastatic behaviour. The mean tumour size of insulinomas found in 3 of the largest reported series was 1.5 cm, with a range of 0.1–7.0 cm (2, 3, 4). ‘Aggressive tumours’ according to the WHO

classification generally tend to be large at diagnosis. Other than being low-grade 2, with a Ki-67 of 4%, the tumour in this patient showed no evidence of malignant or metastatic behaviour.

Tumours larger than 3 cm raise concern for malignancy. The diagnosis of malignancy is based on the presence of metastases to the liver or regional lymph nodes, or gross evidence of local invasion. In a review of metastatic insulinomas, Danforth *et al.* (4) identified 62 cases: 17 from the NIH and 45 others reported in the literature. Thorough pathological data were available for 14 of the patients treated at the NIH: the mean tumour size was  $4.7 \pm 0.6$



**Figure 2**  
(A) H&E stained section ( $\times 20$ ) shows a well-differentiated neuroendocrine neoplasm composed of neoplastic cells regular in shape, with moderate amounts of eosinophilic cytoplasm, uniform round nuclei, chromatin with speckled appearance, and inconspicuous nucleoli. (B) Immunostained-section ( $\times 35$ ) shows positivity of the neoplastic cells for insulin. (C) Immunostained section for Ki-67 ( $\times 40$ ) shows a proliferation index (Ki-67) of 4%.



cm. There were 11 lesions more than 3 cm in diameter, including 2 that were 7.0 cm and 1 that was 9.0 cm. Data regarding tumour size were available for 25 of the 45 cases found in their literature review, and the average size in this group was  $7.1 \pm 0.8$  cm (4). An additional review of the world literature identified only 3 reported cases of insulinomas more than 9 cm in size, all of which were benign by traditional criteria (5, 6). While there are no conclusive histological criteria or histochemical markers that reliably predict biological behaviour, the definitive diagnosis of a malignant or aggressive insulinoma is still based on the presence of metastases or gross evidence of local invasion (7, 8). The relatively large tumour in our patient appears to show essentially indolent characteristics, although he will clearly require long-term surveillance.

It is not uncommon for patients to have symptoms for several months to years before diagnosis, but our patient appears to be unique in first demonstrating hypoglycaemic attacks some 25 years prior to presentation. In a large series, the interval between the onset of symptoms and a definitive diagnosis of insulinoma was 37 months, with a range of 0–14 years. It is interesting that our patient was able to control his hypoglycaemia with simple dietary measures, at least until the final few months before he presented to us. It is therefore tempting to speculate that the unusual occurrence of a very long history is related to the large size of the tumour at presentation, suggesting either very slow growth of the tumour over the 25 years or a sudden change in size concomitant with the worsening symptoms over the preceding months.

The biochemical diagnosis of an insulinoma depends on the demonstration of significant hypoglycaemia in the presence of inappropriate insulin and C-peptide levels, in the absence of factitious drug use (8). If hypoglycaemia does not occur spontaneously or after a simple overnight fast, a supervised 48 h or preferably 72 h fast is necessary; there are various protocols for this, but all require close medical supervision (9).

Having made the diagnosis, insulinomas can be difficult to identify, especially when  $<2$  cm in diameter. Cross-sectional imaging with CT is often negative, while MRI may be more effective (10).

In the past, calcium-stimulated hepatic venous sampling was useful for 'regionalisation', but more recently endoscopic ultrasound (EUS) has become dominant and allows for tissue biopsy. In our case, the size of the tumour allowed for identification with MRI alone, while radionuclide scanning with  $^{68}\text{Ga}$ -dotatate PET was negative, as it is in about 50% of such indolent insulinomas (11). More recently, radionuclide scanning with labelled

GLP-1 analogues such as exendin,  $^{68}\text{Ga}$ -exendin PET scanning, has localised even very small insulinomas (12), including those associated with MEN1 (13). In our case, we felt that cross-sectional imaging alone was sufficiently diagnostic. The medical management of insulinoma, used to treat and prevent hypoglycaemia, is generally restricted to unresectable metastatic tumours, unsuccessful operation with persistent symptoms, inoperable patients, and patients awaiting or refusing surgery. Moreover, other recent techniques for the management of insulinoma have been reported, including injection of octreotide, EUS-guided alcohol ablation, radiofrequency ablation, or embolisation of an insulinoma. In our case, patient was managing with frequent meals and adjusting his diet for 25 years without complicated hypoglycaemia.

Most insulinomas can be cured with surgery, the surgical procedure of choice depending on the size and location of the mass. Tumour enucleation is the procedure of choice for small and solitary nodules that do not encroach on the pancreatic or bile ducts (7). Resection options include distal pancreatectomy (with or without splenectomy), Whipple procedure (pancreaticoduodenectomy), or median pancreatectomy, depending on the site of the insulinoma. To date, laparoscopic resection has often been performed for insulinomas that are small, isolated, and/or located in the body or tail of the pancreas. Radical resection should be considered for patients in whom the lesion is not single, not well-capsulated,  $>4$  cm in diameter, and involves or is near the main pancreatic duct. Lymphadenectomy is not usually performed. Although the cure rate after resection for insulinoma is very high, it is necessary to be aware of the potential for post-operative complications after pancreatic surgery, especially post-operative pancreatic fistula.

In conclusion, this case reports a patient with an exceedingly long history of symptoms associated with a large insulinoma: we speculate that the history has led to the unexpectedly large size of this apparently indolent lesion.

---

#### Patient's perspective

We welcome comments from your patient; their own description of their experience may help other patients or clinicians who are dealing with a similar problem. If your patient would like to contribute, please ensure they include only relevant personal details. Patients may describe their symptoms, how any tests and treatments affected them, and how the problem is now.

---

#### Declaration of interest

The authors declare that there is no conflict of interest that could be perceived as prejudicing the impartiality of the research reported.





### Funding

This study did not receive any specific grant from any funding agency in the public, commercial or not-for-profit sector.

### Patient consent

Written informed consent for publication of their clinical details and/or clinical images was obtained from the patient.

### Author contribution statement

H Boharoon: primary author. S Navalkissoor: help to obtain the radiology imaging. T V Luong: help to obtain the histology slides. M Caplin: help to review and edit the case. A Grossman: supervised the patient, helped to write and review the case.

## References

- 1 Pasiaka JL, McLeod MK, Thompson NW & Burney RE. Surgical approach to insulinomas: assessing the need for preoperative localization. *Archives of Surgery* 1992 **127** 442–447. (<https://doi.org/10.1001/archsurg.1992.01420040088015>)
- 2 Grant CS. Surgical aspects of hyperinsulinemic hypoglycemia. *Endocrinology and Metabolism Clinics of North America* 1999 **28** 533–554. ([https://doi.org/10.1016/s0889-8529\(05\)70087-6](https://doi.org/10.1016/s0889-8529(05)70087-6))
- 3 Doherty GM, Doppman JL, Shawker TH, Miller DL, Eastman RC, Gordenn P & Nortonn JA. Results of a prospective strategy to diagnose, localize, and resect insulinomas. *Surgery* 1991 **110** 989–997.
- 4 Danforth Jr DN, Gorden P & Brennan MF. Metastatic insulin-secreting carcinoma of the pancreas: clinical course and the role of surgery. *Surgery* 1984 **96** 1027–1037.
- 5 Arensman RM & Glassford GH. Giant insulinoma. *American Journal of Surgery* 1976 **131** 603–604. ([https://doi.org/10.1016/0002-9610\(76\)90023-4](https://doi.org/10.1016/0002-9610(76)90023-4))
- 6 Marrano D, Campione O, Santini D, Piva P, Alberghini M & Casade R. Cystic insulinoma: a rare islet cell tumor of the pancreas. *European Journal of Surgery* 1994 **160** 519–522.
- 7 Lack EE (eds). *Pathology of the Pancreas, Gallbladder, Extrahepatic Biliary Tract and Ampullary Region*, pp. 323–373. New York: Oxford University Press, 2003.
- 8 Finlayson E & Clark OH. Surgical treatment of insulinomas. *Surgical Clinics of North America* 2004 **84** 775–785. (<https://doi.org/10.1016/j.suc.2004.02.004>)
- 9 Ueda K, Taira T, Hakoda H, Nakata S, Okata S, Nagai T, Aoki S, Mishima H, Sako A, Maruyama T, *et al.* Giant insulinoma: report of a case and review of published reports. *Surgical Case Reports* 2016 **2** 136. (<https://doi.org/10.1186/s40792-016-0265-z>)
- 10 Okabayashi T, Maeda H, Nishimori I, Sugimoto T, Ikeno T & Hanazaki K. Pancreatic fistula formation after pancreaticoduodenectomy; for prevention of this deep surgical site infection after pancreatic Hepatogastroenterology. *Hepato-Gastroenterology* 2009 **56** 519–523.
- 11 Druce MR, Muthuppalaniappan VM, O’Leary B, Chew SL, Drake WM, Monson JP, Akker SA, Besser M, Sahdev A, Rockall A, *et al.* Diagnosis and localisation of insulinoma: the value of modern MRI in conjunction with calcium stimulation catheterization. *European Journal of Endocrinology* 2010 **162** 971–978. (<https://doi.org/10.1530/EJE-10-0056>)
- 12 Cryer PE, Axelrod L, Grossman AB, Heller SR, Montori VM, Seaquist ER, Service FJ & Endocrine Society. Evaluation and management of adult hypoglycemic disorders: an Endocrine Society Clinical Practice Guideline. *Journal of Clinical Endocrinology and Metabolism* 2009 **94** 709–728. (<https://doi.org/10.1210/jc.2008-1410>)
- 13 McAuley G, Delaney H, Colville J, Lyburn I, Worsley D, Govender P & Torreggiani WC. Multimodality preoperative imaging of pancreatic insulinomas. *Clinical Radiology* 2005 **60** 1039–1050. (<https://doi.org/10.1016/j.crad.2005.06.005>)

Received in final form 15 July 2022

Accepted 19 August 2022