



## CASE REPORT

# Headache induced by the sphenoid sinus mucocele<sup>☆</sup>



## Cefaleia atribuída a uma mucocele no seio esfenoidal

Kyu Eun Lee, Kyung Soo Kim<sup>\*</sup>

*Department of Otorhinolaryngology-Head and Neck Surgery, Chung-Ang University College of Medicine, Seoul, South Korea*

Received 5 February 2013; accepted 23 February 2013

Available online 3 July 2014

### Introduction

Although headache is a well-known presenting symptom of isolated sphenoid sinus disease,<sup>1</sup> it usually delays its diagnosis, since sinonasal symptoms are lacking; thus, these patients initially present to neurologists and neurosurgeons to assess the headache.

The mucocele, which is a benign, cystic lesion lined by respiratory epithelium, is one of the disease entities originating from the sphenoid sinus. However, the sphenoid sinus is the least common site of the paranasal sinuses, representing 1–2%.<sup>2</sup>

The authors report a case of isolated sphenoid sinus mucocele that only presented with headache for over six months, and also review the literature regarding the pathophysiology of such headaches.

### Case report

A 23-year-old, previously healthy male presented with right-sided headache over six months. The headache was intermittent and dull, but recently it had become more

severe in intensity. The neurological examination was normal. In order to exclude other symptomatic headaches, brain magnetic resonance imaging (MRI) was performed by his neurologist, which showed no intracerebral structural lesions. However, it revealed a cystic lesion in the right sphenoid sinus, without erosion of the bony wall (Fig. 1). Since his neurologist thought this lesion was not associated with the headache, it was decided to observe changes in size for six months. Although non-steroidal anti-inflammatory drugs (NSAIDs) had some effect, his headache was not completely relieved, and recently became more aggravated. Six months later, brain MRI was re-evaluated because of his ongoing and aggravated headache; it showed no change in size, but minimal changes in signal intensity (Fig. 1). The provisional diagnosis attributed the headache to the right sphenoid sinus mucocele. After the right-sided sphenoidotomy, a brownish cystic mass was found and excised completely (Fig. 1). The patient has been completely relieved of his symptoms for the last 12 months.

### Discussion

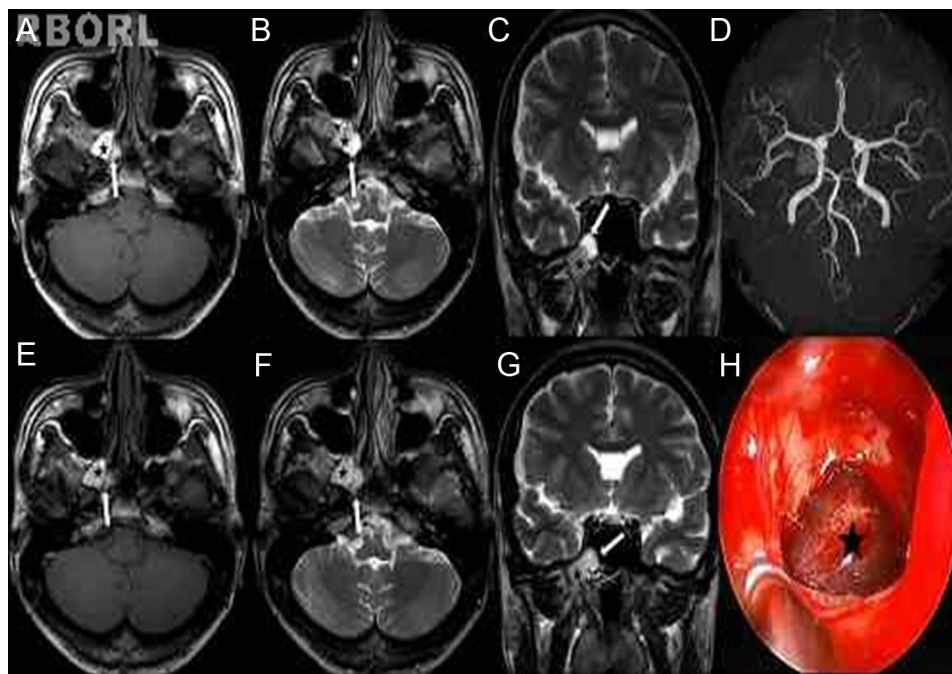
The most common symptom of sphenoid sinus mucoceles is headache caused by lesion dimensions.<sup>1,3</sup> The headache induced by sphenoid sinus mucoceles usually occurs as a bilateral, slowly progressive worsening pain, and can temporarily be relieved by NSAIDs.<sup>4</sup>

There are three important points to explain the mechanism of the headache.

<sup>☆</sup> Please cite this article as: Lee KE, Kim KS. Headache induced by the sphenoid sinus mucocele. *Braz J Otorhinolaryngol.* 2015;81:113–4.

<sup>\*</sup> Corresponding author.

E-mail: [99-21045@hanmail.net](mailto:99-21045@hanmail.net) (K.S. Kim).



**Figure 1** (A–D) The mucocele is composed of two separate parts. T1-weighted magnetic resonance imaging (MRI) scan (A, axial) shows a hyperintense part (black star: high protein content) and a mildly hyperintense part (white arrow: high water content). T2-weighted MRI scans (B, axial; C, coronal) shows a hypointense part centrally, with a surrounding rim of hyperintense mucosa (black star) and a part of a high signal. MRA scan (D) shows normal arterial vasculature and a mucocele. (E–G) Six months later, brain MRI was re-evaluated. It showed no changes in size, but minimal changes in signal intensity of the lesion. The T2-weighted signal is lower than expected in the part of high water content (white arrow), indicating the increase of protein within the mucocele. (H) After wide sphenoidotomy, the blackish cystic mass (black star) was found and completely removed by endoscopic surgery.

First, the headache induced by the presence of mucocele is generally of the somatic type, deep, visceral, and its nature is clearly interoceptive, characteristic of the mucosa of the paranasal sinuses. The headache induced by sphenoid sinus mucoceles is directly related to mechanical pressure on the sinus anatomy, such as expansion and infection. It can be referred to any part of the head, since the nerve supply of the sphenoid sinus comes from the ophthalmic division of the trigeminal nerve.<sup>5</sup>

Second, the headache is presumably due to stretching of the dura covering the planum sphenoidale and the floor of the anterior cranial fossa, because mucoceles are expansile and locally destructive, with the ability to resorb bone, causing erosions of the sinus wall.<sup>5</sup>

Last, the headache is associated with inflammatory cytokines such as IL-1, IL-6, TNF alpha, and PGE2 found in mucoceles. Studies have found that cytokines are one of the principal causes of osteolysis of the bone surrounding mucoceles.<sup>6</sup> Cytokines are involved in inflammation, in modulation of the pain threshold, and also in trigeminal sensitization.

Mucocele may have variable signal intensities on MRI depending on their protein content, inspissation, and possible superinfection.<sup>2</sup> In the present patient, there was a hyperintense lesion on T1-weighted MRI, which showed lower than expected enhancement on T2-weighted MRI, consistent with high protein contents.<sup>2,6</sup> On follow-up MRI, there were some changes in signal intensity, suggesting an increase of protein content within the mucocele associated with increase of inflammatory cytokines.

## Final remarks

Although the mucocele may be of small size, the clinician should consider it in the case of intractable headache with regard to differential diagnosis.

## Conflicts of interest

The authors declare no conflicts of interest.

## References

1. Lawson W, Reino AJ. Isolated sphenoid sinus disease: an analysis of 132 cases. *Laryngoscope*. 1997;107:1590–5.
2. Kosling S, Hinter M, Brandt S, Schulz Th, Bloching M. Mucocele of the sphenoid sinus. *Eur J Radiol*. 2004;51:1–5.
3. Giovannetti F, Filiaci F, Ramieri V, Ungari C. Isolated sphenoid sinus mucocele: etiology and management. *J Craniofac Surg*. 2008;19:1381–4.
4. Bauer B, Evers S, Lindörfer HW, Schuierer G, Henningsen H, Husstedt IW. Headache caused by a sphenoid mucocele but presenting as an ergotamine-induced headache. *Headache*. 1997;37:460–2.
5. Iqbal J, Kanaan I, Ahmed M, al Homsy M. Neurosurgical aspects of sphenoid sinus mucocele. *Br J Neurosurg*. 1998;12:527–30.
6. Kariya S, Okano M, Hattori H, Sugata Y, Matsumoto R, Fukushima K, et al. Expression of IL-12 and T helper cell 1 cytokines in the fluid of paranasal sinus mucoceles. *Am J Otolaryngol*. 2007;28:83–6.