

# Heated and Humidified High Flow Nasal Canal Oxygen Supplementation as an Effective Treatment for High-Risk Prethreshold Retinopathy of Prematurity

Xian Zhang<sup>1,\*</sup>, Gaoxiang Wang<sup>2,\*</sup>, Binbin Liu<sup>1</sup>, Bo Chen<sup>1</sup>, and Hong Yang<sup>1</sup>

<sup>1</sup> Department of Ophthalmology, Tongji Hospital, Tongji Medical College, Huazhong University of Science and Technology, Wuhan, China

<sup>2</sup> Department of Hematology, Tongji Hospital, Tongji Medical College, Huazhong University of Science and Technology, Wuhan, China

**Correspondence:** Hong Yang, Department of Ophthalmology, Tongji Hospital, Tongji Medical College, Huazhong University of Science and Technology, Jiefang Avenue 1095, Wuhan 430030, China. e-mail: dr\_yangh@aliyun.com  
Bo Chen, Department of Ophthalmology, Tongji Hospital, Tongji Medical College, Huazhong University of Science and Technology, Jiefang Avenue 1095, Wuhan 430030, China. e-mail: eyechen@aliyun.com

**Received:** 22 May 2018

**Accepted:** 1 January 2019

**Published:** 25 April 2019

**Keywords:** retinopathy of prematurity; oxygen supplementation; high flow nasal cannula

**Citation:** Zhang X, Wang G, Liu B, Chen B, Yang H. Heated and humidified high flow nasal canal oxygen supplementation as an effective treatment for high-risk prethreshold retinopathy of prematurity. *Trans Vis Sci Tech.* 2019;8(2):20, <https://doi.org/10.1167/tvst.8.2.20>  
Copyright 2019 The Authors

**Purpose:** We evaluated the effect of heated and humidified high flow nasal cannula (HFNC) oxygen supplementation to promote regression of high-risk prethreshold retinopathy of prematurity (Hrp-ROP) in premature infants.

**Methods:** A prospective study was designed for Hrp-ROP premature infants undergoing HFNC oxygen supplementation to evaluate its capacity for promoting ROP regression. Statistical analysis with independent samples *t*-tests and Fisher's exact tests was performed, and forest plots were created to illuminate the odds ratio of factors associated with ROP regression as well as HFNC complication.

**Results:** With HFNC, 16 of 20 infants with Hrp-ROP experienced regression, which is higher than the natural regression rate, comparing to the data in other clinical trials (52% in the STOP-ROP study). Among four progressed ROP infants, three were treated with laser photocoagulation and one received anti-vascular endothelial growth factor (VEGF) therapy. The anti-VEGF treated patient encountered ROP recurrence one month after injection and was treated successfully by additional HFNC. No significant differences between regression and progression cases were found for gestational age, birth weight, plus disease, age for HFNC, and SO<sub>2</sub> level. The blood saturation of oxygen was significantly increased after HFNC ( $92 \pm 1.3\%$  vs.  $96.6 \pm 0.8\%$ ,  $P < 0.001$ ), while the heartbeat rate (HR) and respiratory rate (RR) had no significant differences ( $139.4 \pm 5.4$  vs.  $140.6 \pm 4.5$ ,  $P = 0.409$ ;  $37.7 \pm 2.3$  vs.  $37 \pm 1.9$ ,  $P = 0.330$ , respectively). The main complication of HFNC was nasal erosion associated with airflow and HFNC duration (RR = 1.8,  $P = 0.026$ ; RR = 1.8,  $P = 0.026$ , respectively).

**Conclusions:** The progression of Hrp-ROP was significantly decreased after HFNC oxygen supplementation with slightly tolerable complication.

**Translational Relevance:** Our study suggests that HFNC can be an alternative treatment for Hrp-ROP, potentially avoiding the problems caused by other invasive treatment.

## Introduction

Retinopathy of prematurity (ROP) is the primary cause of blindness in infants. The causes of ROP have been widely investigated in past years, with low birth weight (BW), low birth gestational age (GA), and high levels of oxygen inhalation during the premature stage considered to be the main risks.<sup>1-4</sup> With improvement in neonatal intensive care in the past

decades, the survival rate of low BW and low GA premature infants has greatly improved, resulting in a higher incidence of ROP.

In general, ROP involves two phases: in early phase 1, hyperoxia suppresses normal retinal development, while in late phase 2 retinal hypoxia induces neovascularization.<sup>2</sup> Several multicenter, double-blind, randomized controlled studies have focused on oxygen supplemental therapy as an additional treatment for ROP in phases 1 and 2.<sup>5-7</sup> The meta-

analysis of 10 studies shows that low  $SO_2$  (70%–96%) in the first few postnatal weeks and high  $SO_2$  (94%–99%) at gestational age of 32 weeks or older are associated with decreased risk of progression to severe retinopathy of prematurity.<sup>8</sup> However, decreased  $SO_2$  at phase 1 significantly increased mortality, while increased  $SO_2$  with high concentration oxygen inhalation at phase 2 is associated with increased pulmonary complications.

In conventional oxygen supplementation, infants usually use a nasal cannula with low flow and high concentration oxygen, which may have several side effects. First, the cold and dry air flow more than >2 L/min may cause airway dryness, mucosal dryness, and nosocomial infections, resulting in airway mucosal injury and airway obstruction due to mucous plugs.<sup>9</sup> Second, the high fraction of inhaled oxygen ( $FiO_2$ ) has been suspected to induce pulmonary dysplasia and may increase the mortality of premature infants.<sup>10</sup> These complications are important factors, especially in fragile premature infants, that intensively affect the validity of oxygen supplementation for ROP.

High flow nasal cannula (HFNC) is a relatively new noninvasive ventilation therapy and already has been used widely in adults and pediatrics for various kinds of respiratory disorders.<sup>12,14–16</sup> Unlike the cold and dry air in conventional oxygen supplementation, HFNC delivers heated and humidified high flow blended air/oxygen (4–10 L/min), which causes less damage to the airway and requires lower  $FiO_2$ .<sup>11–13,17</sup> In addition, by giving a positive airway pressure, HFNC is of benefit for pulmonary dysplasia, which is a common complication in premature infants.<sup>18,19</sup> Therefore, we hypothesized that HFNC is a better modality for continuous long-term oxygen supplementation, which is more comfortable and effective for premature infants with less oxygen toxicity.

To our knowledge, we are the first to report use of HFNC as ROP treatment. In this prospective study, our goals were to investigate the efficiency of HFNC on regression of high-risk prethreshold ROP and to evaluate the safety of long-term HFNC use in premature infants.

## Methods

### Study Oversight and Design

This study complied with the tenets of the Declaration of Helsinki and was approved by the institutional review boards of Tongji Hospital of

Huazhong University of Science and Technology. Parents or guardians of the infants provided written informed consent before enrollment.

Preterm infants with high-risk prethreshold ROP were enrolled in this study and treated with continuous HFNC. The progression of ROP was observed carefully to evaluate the effect of HFNC on high-risk prethreshold ROP.

### Participants

ROP classification was referred to the criteria updated by the revised International Classification of Retinopathy of Prematurity in 2005. The definition and recommendation of types 1 and 2 prethreshold ROP were as according to the Early Treatment for Retinopathy of Prematurity (ETROP) randomized trial.<sup>20,21</sup> In the ETROP Study Type 1, eyes were recommended to be treated promptly in 72 hours, while Type 2 eyes could be cautiously observed and treated if the ROP progressed. The high-risk prethreshold ROP (Hrp-ROP), therefore, is defined as type 1 prethreshold ROP or progressive type 2 ROP.

Infants were eligible for enrollment if they were initially diagnosed as having Hrp-ROP. Infants were ineligible if they had more severe ROP requiring urgent treatment, if they had severe systemic disorders that were not suitable for continuous HFNC, or if they could not reach the  $SO_2 > 95%$  with airflow up to 10 L/min.

### Study Intervention

Preterm infants enrolled in this study were treated with continuous heated and humidified HFNC.  $FiO_2$  was set to 25% and the gas flow was initially at 6 L/min from Precision Flow device (Vapotherm, Exeter, NH) and adjusted between 4 and 10 L/min to maintain blood  $SO_2$  at 95% to 98% according to the continuous pulse oximeter (IntelliVue MP5; Philips, Hamburg, Germany). Fundus observation was performed by the same experienced ophthalmologist with a binocular indirect ophthalmoscope and a RetCam 3 digital imaging system (Clarity Medical Systems, Inc., Pleasanton, CA) was used if the fundus had obvious changes. The observation was closely performed every day after HFNC for the first 3 days, followed by every 3 days in the next 2 weeks, and then followed by once a week if ROP had not yet regressed. At any point during the observation period, if the ROP was getting worse, the HFNC was terminated and laser photocoagulation or intravitreal injection of anti-vascular endothelial growth factor (VEGF) drugs (0.25 mg, 10

mg/mL; Ranibizumab; Lucentis, Novartis, Basel, Switzerland) was performed to treat the progressed ROP.

## Study Outcomes

The primary outcome was the regression of ROP after continuous HFNC. HFNC treatment was considered effective if the ROP regressed and failed if ROP progressed during observation. The regression or progression of ROP was defined as: (1) plus disease attenuation or aggravation, (2) ROP stage regression or progression, and (3) retinal vessels reaching to further peripheral area or experiencing growth stagnation. Due to the ETROP recommendation of type 1 prethreshold ROP treatment, which was suggested promptly in 72 hours after diagnosis, the beginning of evaluation was performed closely in the first 72 hours. If treatment was effective, HFNC continued and infants continued to be observed closely. Otherwise, laser or anti-VEGF treatment was performed immediately.

The interval from HFNC treatment to laser or anti-VEGF intervention, systemic situation including the SO<sub>2</sub>, breath rate, nasal trauma, and other complications also were recorded as additional outcomes during the whole observation.

## Statistical Analysis

Ocular and systemic characteristics were analyzed using the independent samples *t*-test and Fisher exact test for continuous and categorical variables, respectively. Factors affecting the ROP regression and HFNC complications were assessed using the Fisher exact test and shown by a forest plot. All statistical analyses were performed using SPSS software version 19.0 (SPSS, Inc., Chicago, IL) or Prism 7.0 (Graph-Pad, San Diego, CA). Numeric data were presented as mean  $\pm$  standard deviation while the cutoff for statistical significance was considered as  $P < 0.05$ .

## Results

### Study Patients

In this study, 515 preterm infants were screened and 28 infants identified with Hrp-ROP (type 1 or progressive type 2 prethreshold ROP) were recruited from December 15, 2015 to October 18, 2016. Among these recruited infants, eight were excluded from this study because the parents of two eventually claimed an urgent treatment and quit the study, three had

respiratory depression and received respiratory resuscitation, and three had continuous SO<sub>2</sub>  $<$  95% with HFNC at 10 L/min. In total, data were obtained from 20 infants.

Table 1 shows the data of all infants regarding the general information, ROP classification, prethreshold ROP identification, and clinical outcomes. Average GA was  $29.3 \pm 2.1$  weeks, and average BW was  $1.3 \pm 0.29$  kg. Of these 20 infants, 12 and eight were diagnosed with types 1 and 2 ROP, respectively.

### The Validity of HFNC for Hrp-ROP Regression

Of the 20 infants, 16 achieved ROP regression, while four manifesting with ROP progression eventually underwent additional treatment (three by laser ablation and one by anti-VEGF injection of 0.25 mg Lucentis). The only infant who received anti-VEGF therapy had recurrent ROP 1 month after injection and was successfully treated by additional HFNC. The total regression rate of ROP was 80% (16/20), while the type 1 ROP subgroup had a higher validity compared to the type 2 ROP (91.6% [11/12] vs. 62.5% [5/8],  $P = 0.153$ ; Fig. 1A).

The factors associated with ROP regression were analyzed with Fisher's exact test in univariate analyses. Table 2 shows the forest plot of factors associated with ROP regression. All investigated factors, such as gestational age, sex, birth weight, plus disease, age of HFNC, and SO<sub>2</sub> level, had no significant association with ROP regression. Conversely, type 1 ROP seemed to have a slight tendency, which was more sensitive to HFNC therapy (RR, 1.4667;  $P = 0.153$ , Table 2).

### Systemic Situation Changes After HFNC

Table 3 shows the systemic situation changes after HFNC. The blood saturation of oxygen (SO<sub>2</sub>) was significantly increased after HFNC ( $92 \pm 1.3\%$  vs.  $96.6 \pm 0.8\%$ ,  $P < 0.001$ ), while the heartbeat rate (HR), and respiratory rate (RR) were not significantly influenced by HFNC ( $139.4 \pm 5.4$  vs.  $140.6 \pm 4.5$ /min,  $P = 0.409$ ;  $37.7 \pm 2.3$  vs.  $37 \pm 1.9$ /min,  $P = 0.330$ , respectively; Fig. 1B).

### Complications Associated With HFNC

In this study, infants with HFNC supplementation were generally safe except for five infants who experienced minimal complications. Among these patients, one had mild gastrectasis, while the remaining four suffered nasal erosion, which was treated successfully by local smearing of Vaseline ointment

**Table 1.** General Information and Outcomes of Prethreshold ROP Infants Treated by HFNC

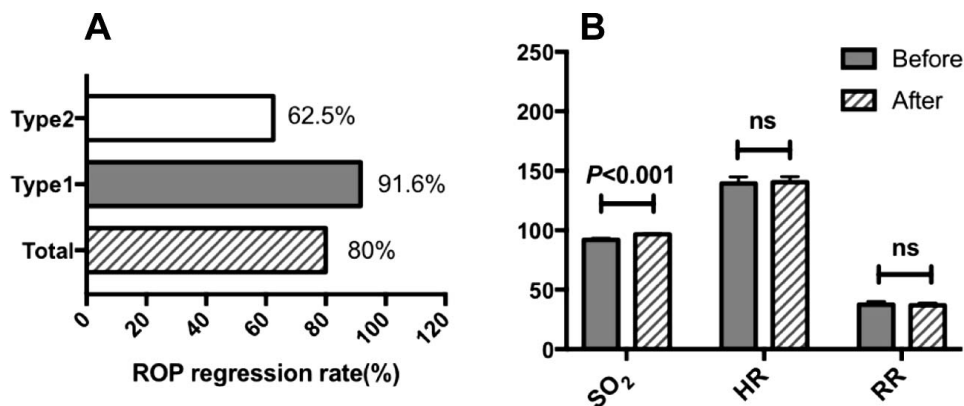
Patient No.	GA, wk+d	Sex	BW, kg	Zone & Stage	ROP Type	Age at HFNC, wk+d	ROP Regression	Laser Ablation	Anti-VEGF Injection	ROP Recurrence	Additional HFNC
1	28+3	F	1.23	I,1+	1	33+6	Y				
2	30+5	M	1.54	II,3-	2	44+5	Y				
3	30+4	M	1.37	II,3-	2	41+8	Y				
4	33+3	F	2.2	II,3-/II,3-	2	37+6	Y				
5	28+6	M	1.05	II,3-/II,3-	2	44+6	N	Y		N	N
6	30+5	M	1.3	I,2-/I,2-	2	36	N	Y		N	N
7	29+3	M	1.35	I,2-/I,2-	2	44	N	Y		N	N
8	26+2	M	1.02	II,3-	2	32+1	Y				
9	28+1	F	1.4	I,2+/I,2+	1	35+6	Y				
10	28+6	F	1.13	II,2+/II,2+	1	33	Y				
11	28+2	F	1.19	II,2+/II,1+	1	34+2	Y				
12	33	F	1.27	II,3-	2	36+4	Y				
13	27+1	M	1.04	II,2+/II,2+	1	37+1	Y				
14	26+5	F	0.98	II,2+/II,2+	1	36+4	N		Y	Y	Y
15	27+6	M	1.12	II,2+/II,2+	1	36+2	Y				
16	31+5	F	1.35	II,2+/II,2+	1	38+2	Y				
17	29+4	M	1.26	II,2+/II,2+	1	40+1	Y				
18	31+1	F	1.49	II,3+/II,3+	1	37+6	Y				
19	26+3	M	0.94	I,1+	1	32+5	Y				
20	30+5	M	1.8	II,3+/II,2+	1	35+3	Y				

without discontinuation of the HFNC (Table 3). Table 4 shows the forest plot of risk factors associated with this complication. High air flow and long duration of HFNC were associated with the nasal erosion (RR = 1.8,  $P = 0.026$ ; RR = 1.8,  $P = 0.026$ , respectively, Table 4). Older age to start HFNC also

seemed to decrease the tendency for nasal erosion (RR = 0.667,  $P = 0.117$ , Table 4).

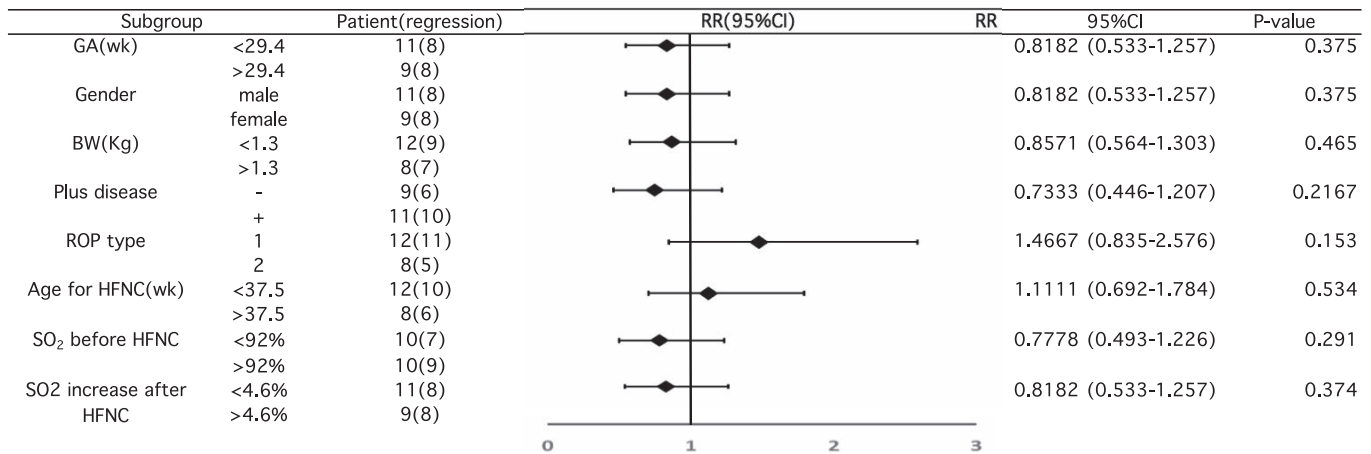
### Representative Case of ROP Regression After HFNC

Figures 2A and 2B show a successful treatment of type 1 prethreshold ROP (zone II, 2+) in a patient



**Figure 1.** (A) The regression rate of different types of prethreshold ROP. (B) The changes of SO<sub>2</sub> (displayed as a percentage), heartrate and respiratory rate (displayed as times/min) after HFNC.

**Table 2.** Forest Plot of Factors Associated With ROP Regression



who was referred to our hospital for further laser ablation or anti-VEGF injection. After HFNC therapy, the plus disease quickly faded, and the vessels kept growing to peripheral regions. Following

continuous HFNC for 1 month, the plus disease almost disappeared with only a minimal 1- to 2-stage ROP in zone III. She avoided laser ablation and ultimately had restoration of the peripheral retina.

**Table 3.** Systemic Situation Changes and Complications After HFNC

Patient No.	Flow Rate, L/min	HFNC Duration, wk	Blood SO <sub>2</sub> , %		HR, bpm		RR, rpm		Complication
			Before	After	Before	After	Before	After	
1	8	4+6	89-96	94-98	113-172	109-170	29-52	30-51	Nasal erosion
2	4	3	92-95	95-99	97-165	103-163	26-45	27-45	
3	6	2+5	91-96	96-99	101-170	105-168	28-47	27-45	
4	6	2	90-94	95-98	107-175	109-171	30-51	28-48	
5	4	2+3	93-95	95-99	100-159	103-161	26-45	25-43	
6	10	1+2	88-95	95-98	106-159	112-175	30-50	28-49	
7	4	1+2	92-96	96-99	101-163	104-168	25-43	24-41	
8	10	4+4	86-92	93-96	117-180	125-177	32-50	30-49	Nasal erosion
9	8	3+4	89-93	94-97	114-173	110-171	29-49	27-48	
10	8	5+3	89-94	94-98	118-179	116-175	30-47	30-45	Gastrectasis
11	6	5+1	90-93	93-97	113-172	120-168	28-51	27-46	
12	6	3+2	90-94	94-98	111-172	112-172	28-46	28-48	
13	6	2+4	90-95	95-98	109-169	106-171	27-49	27-49	
14	6	3+2	90-94	95-98	106-174	112-170	29-46	28-47	
15	8	3+4	89-93	94-97	108-167	110-169	26-44	25-48	
16	6	2+5	91-95	96-99	105-170	113-168	27-48	26-45	
17	4	2+6	92-96	96-99	99-163	107-167	25-43	26-43	
18	8	3+6	89-93	95-99	111-170	113-166	28-46	29-45	
19	10	6+4	86-92	92-97	118-176	126-170	31-52	30-49	Nasal erosion
20	8	3+6	89-94	93-97	109-170	113-175	27-46	25-47	Nasal erosion

**Table 4.** Forest Plot of Factors Associated With Nasal Complication

Subgroup	Patient(erosion)	RR(95%CI)	RR	95%CI	P-value
GA(wk)	>29.4	9(1)			
	<29.4	11(3)			
Gender	female	9(1)			
	male	11(3)			
BW(Kg)	>1.3	8(1)			
	<1.3	12(3)			
Air flow (L/min)	>6.8	9(4)			
	<6.8	11(0)			
HFNC duration(wk)	>3.5	9(4)			
	<3.5	11(0)			
Age at HFNC(wk)	>37.5	8(0)			
	<37.5	12(4)			

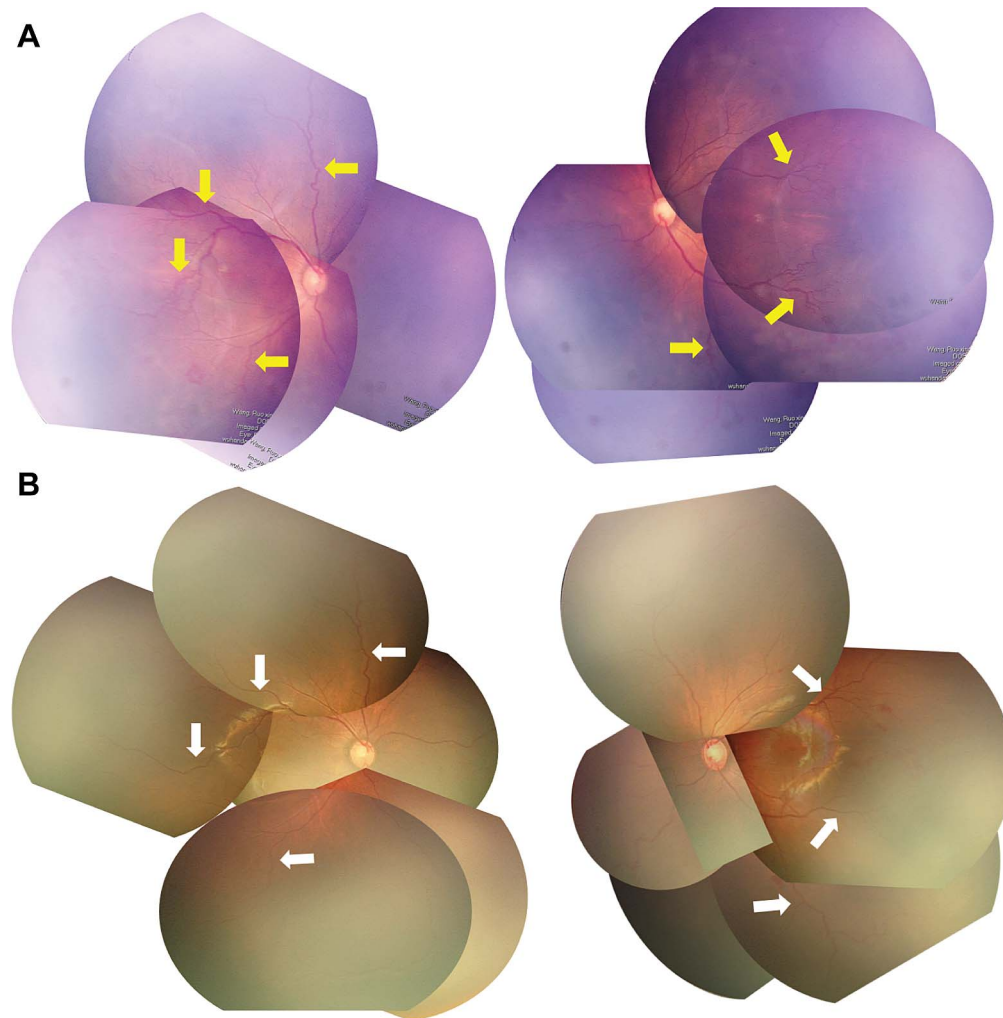
## Discussion

For decades, several studies focused on the benefits of supplemental oxygen therapy as a noninvasive method of ROP treatment while the results remain controversial.<sup>8,22,24</sup> In our study, 20 prethreshold ROP infants who met the criteria for invasive treatment were treated with HFNC, and the ROP regression rate was 80% (16/20), which was higher than that in conventional observation (80% vs. 52% in STOP-ROP study).<sup>23</sup> Gaynon et al.<sup>24</sup> reported the significantly decreased ROP progression from 37% to 7% when the SO<sub>2</sub> was targeted from <95% to 99%. Recently, Colaizy et al.<sup>22</sup> reported significantly decreased ROP progression after implementation of an oxygen therapy protocol (23% vs. 44%). Both aforementioned results are consistent with our findings. Conversely, the STOP-ROP study showed that supplemental oxygen therapy has no significant benefits for ROP regression. Compared to the STOP-ROP study, infants in our study had larger BW and older GA (1302 ± 299 vs. 726 ± 160 g; 29.3 ± 2.1 vs. 25.4 ± 1.5 weeks, respectively), and the intervention time was later (37.4 ± 3.8 vs. 25.4 ± 1.5 weeks).<sup>23</sup> These factors might induce less severe ROP as well as better tolerance for supplemental therapy, and, therefore, a biased result. Nevertheless, our preliminary findings strongly demonstrated that HFNC therapy was effective for Hrp-ROP regression.

We also evaluated the factors affecting the ROP regression. In the STOP-ROP study, the prethreshold ROP without plus disease seemed more beneficial to oxygen supplement. However, in our study, we found more regression cases in the plus(+) (90.9% vs. 66.7%)

and type 1 (91.6% vs. 62.5%) groups, although the *P* value had no significance (*P* = 0.216 and 0.153, respectively). We inferred that the plus (+) and type 1 ROP were more aggressive, which might reflect a higher level of VEGF, so as to be more sensitive to oxygen suppression. However, a study with larger sample size is required to further evaluate the effect of HFNC on different subtypes of ROP.

Although the laser ablation has a definite effect, its long-term visual functional side effects, such as myopia and visual field impairment, remain major concerns.<sup>25</sup> In our study, 16 of 20 infants achieved ROP regression without laser ablation. Our findings strongly suggest that supplemental oxygen can be an effective alternative method for early-stage ROP. Compared to laser ablation, which destroys the peripheral retina, noninvasive oxygen supplementation has potential advantages for visual function improvement. There is little doubt that ROP is a complicated disease with a variety of stages, zones, as well as plus disease. Our preliminary data could not answer the exact relationship between ROP regression and oxygen supplementation regarding the ROP phase, classification, oxygen concentration, and treatment time point and duration. However, our finding is significant for exploring the novel method for ROP treatment. Instead of hypoxia treatment in the first phase increasing the mortality of preterm infants, we focused on the second phase of ROP which was more feasible because the increased oxygen is beneficial for infant survival and neovascularization suppression. In addition, the larger infants in this phase are much more likely to tolerate the oxygen supplemental therapy. As we expected, the results were consistent with the



**Figure 2.** (A) RetCam fundus images of type 1 prethreshold ROP with obvious tortuous vessels (yellow arrows). (B) Same eyes after HFNC. Plus disease quickly faded and vessels extended to more peripheral area (white arrows in [B]).

hypothesis that oxygen supplemental therapy by HFNC was beneficial to Hrp-ROP. In the future, animal studies to investigate the relationship between  $\text{SO}_2$  and vitreous VEGF level may further reveal the mechanism of  $\text{SO}_2$  changes in ROP treatment.

In our study, preterm infants require continuous oxygen supplementation for at least 1 month or longer. Our findings showed that the  $\text{SO}_2$  after HFNC was obviously increased at relatively low  $\text{FiO}_2$  (from  $92\% \pm 1.3\%$  to  $96.6\% \pm 0.8\%$  at  $25\% \text{ FiO}_2$ ,  $P < 0.01$ ) without significant changes in HR and RR. In addition, no pulmonary complications, necrotizing enterocolitis, and increasing mortality were detected in this study except for a few minimal side effects. The most common complication was nasal erosion (4/20), which was easy to manage by

Vaseline ointment and was related to HFNC flow (RR, 1.8; 95% confidence interval [CI], 1.003–3.229;  $P = 0.026$ ) and duration (RR, 1.8; 95% CI, 1.003–3.229;  $P = 0.026$ ). Thus, administration of Vaseline ointment before giving HFNC may have benefit to reduce this complication. HFNC is suggested to have several actions to increase  $\text{SO}_2$  and improve air exchange: (1) reduction of the nasopharyngeal dead cavity to increase oxygen fraction in the alveoli, (2) creation of an end-distending pressure to increase the alveolar ventilation and reduce the inspiratory resistance, and (3) improvement of pulmonary compliance by inspiring the heated and humidified gas.<sup>12</sup> Compared to traditional oxygen therapy, several studies have shown that HFNC is more effective and tolerable with fewer side effects, such as oxygen toxicity, nasal trauma, and pulmonary

disease, which are related to infant mortality.<sup>14–16</sup> Thus, due to the long-term use of continuous oxygen and the fragile physical condition of preterm infants, we consider HFNC a better choice for ROP oxygen supplementation.

It is interesting that the infant who received anti-VEGF therapy had recurrence and was successfully treated by re-taking HFNC. Anti-VEGF is a great progress of ROP treatment in recent years and dramatically improves the prognosis of severe ROP, especially for zone I ROP and aggressive posterior ROP.<sup>2</sup> However, recurrent ROP after anti-VEGF injection is common and laser ablation is the most frequently used supplementary treatment.<sup>26,27</sup> This case gave us an inspiration that the oxygen supplementary therapy also can be an alternative choice for recurrent cases and meanwhile without ablating the peripheral area, and the infants, therefore, may have better retinal function outcome.

Our study also has some limitations: small sample size, no negative control, and lack of randomly hierarchical design. The number of cases was mainly restricted by a relatively short enrollment period and the criteria for the high-risk prethreshold ROP, which has a low proportion in ROP infants (5.4%, 28 in 515 in our study). We also did not set a control group treated with conventional observation, owing to the recommendation from ETROP clinical trial which suggests infants manifesting type 1 or progressive type 2 prethreshold ROP should be treated with laser ablation or anti-VEGF intravitreal injection within 72 hours to reduce the adverse outcome.<sup>25</sup> Thus, the infants in our study meet the above criteria, which are not allowed to be observed naturally. However, the preliminary result is encouraging. The regression rate is significantly higher (16/20) than the natural probability compared to other large random clinical ROP trials. Further work may be involved to compare the current results with our historical patients' data 1 year before to better validate the impact of HFNC on ROP regression.

In conclusion, our preliminary data showed that HFNC is an effective and safe treatment for ROP regression in infants with Hrp-ROP. With oxygen supplementation by HFNC, some ROP infants have potential opportunity to recover through noninvasive intervention, avoiding the problems caused by other invasive treatment. Large samples are required to further investigate the validity of HFNC in ROP regression.

## Acknowledgments

The authors thank Wei Liu, MD the pediatrician at Tongji Hospital, for invaluable cooperation and Lisa Beckmann, PhD, Northwestern University, for revising the manuscript.

Supported by the Department of Pediatrics and Department of Ophthalmology in Tongji Hospital, Tongji Medical College, Huazhong University of Science and Technology.

Disclosure: **X. Zhang**, None; **G. Wang**, None; **B. Liu**, None; **B. Chen**, None; **H. Yang**, None

\*Xian Zhang and Gaoxiang Wang equally contributed to this article.

## References

1. Classification of Retinopathy of P. The international classification of retinopathy of prematurity revisited. *Arch Ophthalmol*. 2005;123:991–999.
2. Hellström A, Smith LEH, Dammann O. Retinopathy of prematurity. *Lancet*. 382:1445–1457.
3. Gilbert C, Rahi J, Eckstein M, O'Sullivan J, Foster A. Retinopathy of prematurity in middle-income countries. *Lancet*. 1997;350:12–14.
4. Lad EM, Nguyen TC, Morton JM, Moshfeghi DM. Retinopathy of prematurity in the United States. *Br J Ophthalmol*. 2008;92:320–325.
5. Tin W, Milligan DWA, Pennefather P, Hey E. Pulse oximetry, severe retinopathy, and outcome at one year in babies of less than 28 weeks gestation. *Arch Dis Child*. 2001;84:F106.
6. Anderson CG, Benitz WE, Madan A. Retinopathy of prematurity and pulse oximetry: a national survey of recent practices. *J Perinatol*. 2004;24:164–168.
7. Carlo WA, Finer NN, Walsh MC, et al. Target ranges of oxygen saturation in extremely preterm infants. *N Engl J Med*. 2010;362:1959–1969.
8. Chen ML, Guo L, Smith LE, Dammann CE, Dammann O. High or low oxygen saturation and severe retinopathy of prematurity: a meta-analysis. *Pediatrics*. 2010;125:e1483–e1492.
9. Benditt JO. Adverse effects of low-flow oxygen therapy. *Resp Care*. 2000;45:54–61; discussion 61–54.
10. Jobe AH, Kallapur SG. Long term consequences of oxygen therapy in the neonatal period. *Semin Fetal Neonat Med*. 2010;15:230–235.



11. Saugstad OD. Resuscitation of newborn infants: from oxygen to room air. *Lancet*. 2010;376:1970–1971.
12. Mikalsen IB, Davis P, Øymar K. High flow nasal cannula in children: a literature review. *Scand J Trauma Res Emerg Med*. 2016;24:93.
13. Davis PG, Tan A, O'Donnell CPF, Schulze A. Resuscitation of newborn infants with 100% oxygen or air: a systematic review and meta-analysis. *Lancet*. 2004;364:1329–1333.
14. Hernández G, Roca O, Colinas L. High-flow nasal cannula support therapy: new insights and improving performance. *Crit Care*. 2017;21:62.
15. Jeon GW. Respiratory support with heated humidified high flow nasal cannula in preterm infants. *Korean J Ped*. 2016;59:389–394.
16. Yoder BA, Stoddard RA, Li M, King J, Dirnberger DR, Abbasi S. Heated, humidified high-flow nasal cannula versus nasal CPAP for respiratory support in neonates. *Pediatrics*. 2013; 131:e1482–e1490.
17. Wilkinson D, Andersen C, O'donnell CP, De Paoli A. High flow nasal cannula for respiratory support in preterm infants. *Midwif Dig*. 2011;21:380–381.
18. Saslow JG, Aghai ZH, Nakhla TA, et al. Work of breathing using high-flow nasal cannula in preterm infants. *J Perinatol*. 2006;26:476–480.
19. Manley BJ, Owen LS, Doyle LW, et al. High-Flow Nasal Cannulae in Very Preterm Infants after Extubation. *New Engl J Med*. 2013;369: 1425–33.
20. Hardy RJ, Palmer EA, Dobson V, et al. Risk analysis of prethreshold retinopathy of prematurity. *Arch Ophthalmol*. 2003;121:1697–1701.
21. Fielder AR. Preliminary results of treatment of eyes with high-risk prethreshold retinopathy of prematurity in the early treatment for retinopathy of prematurity randomized trial. *Arch Ophthalmol*. 2003;121:1769–1771.
22. Colaizy TT, Longmuir S, Gertsch K, Abramoff MD, Klein JM. Use of a supplemental oxygen protocol to suppress progression of retinopathy of prematurity. *Invest Ophthalmol Vis Sci*. 2017; 58:887–891.
23. Group TS-RMS. Supplemental therapeutic oxygen for prethreshold retinopathy of prematurity (STOP-ROP), a randomized, controlled trial. I: primary outcomes. *Pediatrics*. 2000;105:295–310.
24. Gaynon MW, Stevenson DK, Sunshine P, Fleisher BE, Landers MB. Supplemental oxygen may decrease progression of prethreshold disease to threshold retinopathy of prematurity. *J Perinatol*. 1997;17:434–438.
25. Good WV, on behalf of the Early Treatment for Retinopathy of Prematurity Cooperative Group. Final results of the Early Treatment for Retinopathy of Prematurity (ETROP) randomized trial. *Trans Am Ophthalmol Soc*. 2004;102:233–250.
26. Hu Q, Bai Y, Chen X, Huang L, Chen Y, Li X. Recurrence of retinopathy of prematurity in zone II stage 3+ after ranibizumab treatment: a retrospective study. *J Ophthalmol*. 2017;2017: 5078565.
27. Lyu J, Zhang Q, Chen C-L, et al. Recurrence of retinopathy of prematurity after intravitreal ranibizumab monotherapy: timing and risk factors. *Invest Ophthalmol Vis Sci*. 2017;58:1719–1725.