

## A rare case of takotsubo syndrome led to intra-myocardial dissection and left ventricular apical aneurysm

Reihaneh Zavar<sup>(1)</sup> , Mehrbod Vakhshoori<sup>(2)</sup> , Mohsen Mirmohammadsadeghi<sup>(3)</sup>,  
Mohammad Hashemi-Jazi<sup>(4)</sup>

### Case Report

#### Abstract

**BACKGROUND:** Takotsubo syndrome (TS) is a reversible left ventricular (LV) systolic dysfunction occurred mostly in post-menopausal women after an emotional or physical stress. The exact mechanism has yet to be found. In clinical settings, TS should be differentiated from myocardial infarction (MI) due to totally different management protocols. Several diagnostic criteria are available, but Mayo Clinic criteria is the most widely used. Prognosis of TS is favorable and the recurrence and mortality rates are low. Treatment is mostly supportive and after a few weeks, most of patients' electrocardiography (ECG) and echocardiographic findings will be normalized, though to its benign course, TS can cause some complications. Intra-myocardial dissection and LV apical aneurysm, as a complication of TS has never been reported yet and was just announced in rare cases of MI.

**CASE REPORT:** Our patient was a 32-year-old aphasic woman referring with palpitation and chest discomfort. Further examinations after exclusion of MI revealed TS leading to LV apical aneurysm and intra-myocardial dissection.

**CONCLUSION:** Intra-myocardial dissection should be considered as one of the rarest TS complications. Several studies are necessary for defining the exact pathophysiological mechanisms.

**Keywords:** Takotsubo Cardiomyopathy, Dissection, Cardiac Aneurysm

*Date of submission:* 07 Sep. 2018, *Date of acceptance:* 21 Nov. 2018

#### Introduction

Takotsubo syndrome (TS), apical ballooning syndrome, broken heart syndrome, and stress-related cardiomyopathy are synonyms for an acute severe reversible left ventricular (LV) systolic dysfunction which was first reported by Sato et al. in 1990.<sup>1-5</sup> The word takotsubo refers to an instrument used to catch octopus in Japan.<sup>3,4</sup> From 20<sup>th</sup> century, the number of articles about takotsubo was increased and some forms like right ventricle (RV) involvement and apical sparing syndrome were also reported as variants of this disease.<sup>6</sup>

The mean age of takotsubo is 62-75 years and is mostly seen in post-menopausal women.<sup>5</sup> Despite the unknown mechanism, several theories have been postulated for the pathophysiology of the disease such as catecholamine-induced myocardial stunning, coronary artery spasm, and coronary microvascular dysfunction (CMD).<sup>1,3,4</sup> Most of the patients first experienced an emotional or physical

stress before the onset of symptoms like dyspnea or chest discomfort.<sup>1,5,6</sup>

Till now, there is no acceptable criteria for diagnosing TS and due to its similarity in symptoms and electrocardiography (ECG) and laboratory findings to myocardial infarction (MI), differentiation is crucial because of different management strategies.<sup>1,3,7</sup>

Patients with TS have good prognosis and LV systolic function of 96% of them will be normalized completely after some weeks to months and in-hospital mortality prevalence is 1%-2%.<sup>3,7</sup>

**How to cite this article:** Zavar R, Vakhshoori M, Mirmohammadsadeghi M, Hashemi-Jazi M. **A rare case of takotsubo syndrome led to intra-myocardial dissection and left ventricular apical aneurysm.** ARYA Atheroscler 2019; 15(1): 33-7.

1- Assistant Professor, Cardiac Rehabilitation Research Center, Cardiovascular Research Institute, Isfahan University of Medical Sciences, Isfahan, Iran

2- General Practitioner, Heart Failure Research Center, Cardiovascular Research Institute, Isfahan University of Medical Sciences, Isfahan, Iran

3- Assistant Professor, Isfahan Cardiovascular Research Center, Cardiovascular Research Institute, Isfahan University of Medical Sciences, Isfahan, Iran

4- Professor, Interventional Cardiology Research Center, Cardiovascular Research Institute, Isfahan University of Medicine Sciences, Isfahan, Iran

Correspondence to: Mehrbod Vakhshoori, Email: mehrbod10@yahoo.com

Despite its good prognosis, some complications had been reported among which heart failure (HF) with or without pulmonary edema was the most common.<sup>6,7</sup> One of the rarest complications in this regard mostly seen in MI is dissection which the intra-myocardial one is more prevalent and the only dissection type which has been reported in literature for TS is spontaneous coronary artery dissection (SCAD).<sup>8-10</sup> However, other rare complication in this context in LV aneurysm leading to intra-myocardial dissection and LV apical aneurysm has never been reported yet.

In this article, we described a rare case of TS which led to intra-myocardial dissection and LV apical aneurysm.

### Case Report

The patient was a 32-year-old aphasic woman who came to our emergency department with a history of gradual palpitation and chest discomfort in her left hemithorax.

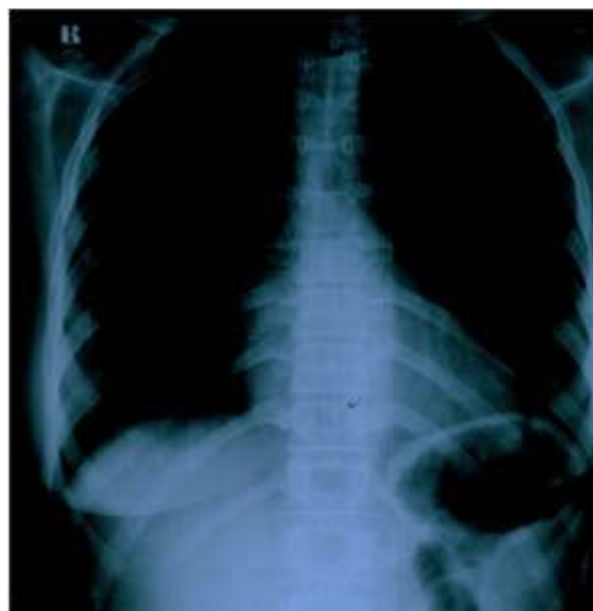She had no family history of cardiac diseases. Her past medical history was unremarkable except for two episodes of embolic cerebrovascular accidents (CVAs) eight and six years ago, respectively.

Her first attack happened following physical stress of moving furniture which caused left hemiplegia. Due to probable chance of MI, she underwent angiography in which findings included normal coronary arteries and large aneurysms in anteroapical and posterolateral LV region with ejection fraction (EF) of 40%. Thereafter, she was treated with warfarin.

Her hemiplegia resolved in the next two years after the prior event; then, she discontinued warfarin by herself and she experienced another

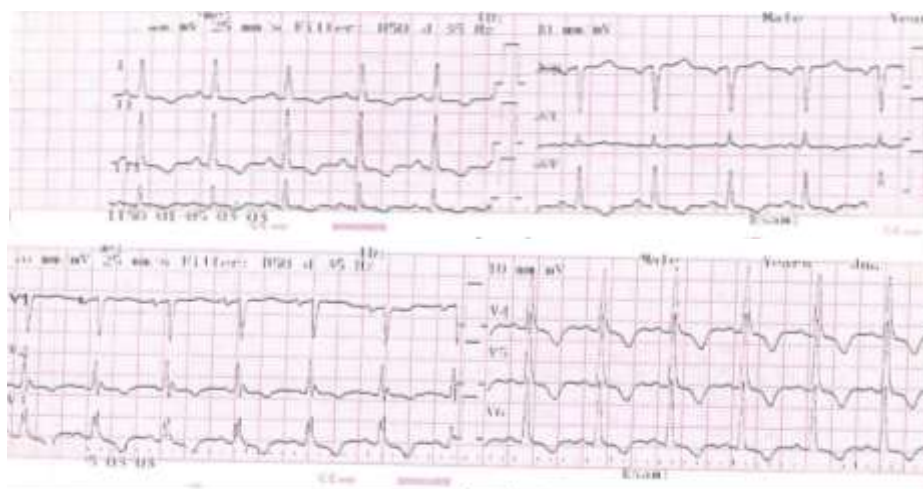
attack with the occurrence of aphasia. Another angiography results showed several aneurysms in lateral LV wall and EF of 40%. Again, medical treatment was initiated.

At the time of present admission, her vital signs were normal. The patient was aphasic. In her heart auscultation, late systolic murmur was heard in apical region. Other physical examinations did not reveal any positive findings. All laboratory data were in normal ranges. In her requested chest X-ray (CXR), cardio-thoracic ratio (CTR) was normal, but the left upper border of the heart was straight (Figure 1).



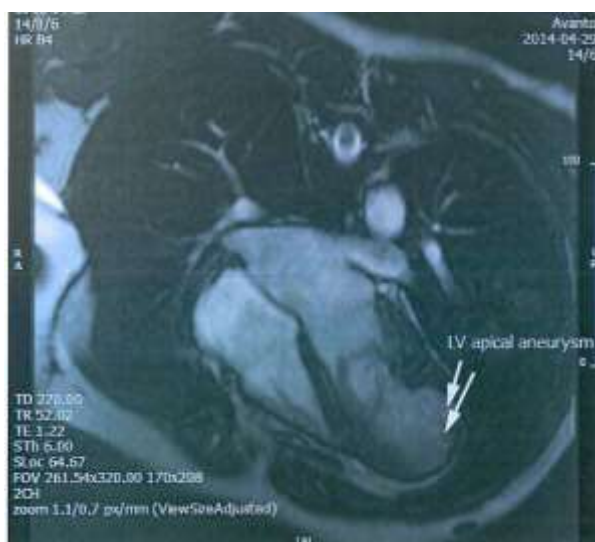**Figure 1.** Straight left upper border of heart

Inverted T waves were recorded in the precordial leads (Figure 2).



**Figure 2.** Inverted T waves in precordial leads

Due to possibility of MI, she went under angiography and the result revealed patent coronary arteries. Based on initial signs and symptoms, possible diagnosis of TS was made. Transesophageal echocardiography (TEE) showed moderate LV enlargement with moderate systolic dysfunction (EF = 40%), mild to moderate mitral regurgitation (MR), mild tricuspid regurgitation (TR),<sup>11</sup> and normal RV size. Her pulmonary artery pressure (PAP) was 34 mmHg. Her diastolic function was normal, but there was a pulsatile mass with intra-myocardial dissection to its pericardium in apico-lateral region. In her cardiovascular magnetic resonance (CMR) imaging the followings were reported (Figure 3): disrupted LV myocardial continuity close to apical segments with a large LV apical dyskinctic outpouching which was covered by a thin layer of subepicardial myocytes and pericardium connected directly to apico-lateral LV segment (maximum width: 42 mm, maximum depth: 32 mm, neck: 14 mm). The early gadolinium enhancement (EGE) images did not show any evidence of intra or paracardiac thrombus, but in late gadolinium enhancement (LGE) images, a thin layer of fibrosis around the outpouching and inferolateral apical LV segment was seen. All the results were in favor of a LV apico-lateral pseudo aneurysm without thrombosis. The patient went under surgery due to possibility of sudden aneurysm rupture. An intra-operative finding was moderate true aneurysm in apico-lateral and posterior region of LV segment and therefore aneurysmectomy was performed for her. All the findings revealed a probable old TS leading intra-myocardial dissection and LV apical aneurysm.



**Figure 3.** Left ventricular (LV) apical aneurysm

The patient was discharged with warfarin and in acceptable general condition. Her routine follow ups after surgery were normal and did not show any abnormalities.

## Discussion

TS became popular in literature during the past 25 years and thousands of articles were published about it and led it to be categorized as one of the topics in cardiomyopathy groups.<sup>1,3,4</sup> This reversible LV dysfunction has several pathophysiologic hypotheses which several other studies must have been done to define the exact mechanism. Three possibilities available are catecholamine-induced myocardial stunning, CMD, and coronary artery spasm which the first two of them are more acceptable worldwide.<sup>3-5,7</sup>

This disease has a classic form in which LV apex is being affected, but there are other forms like inverted takotsubo (artichoke heart) and midventricular (hawk's beak) or isolated RV involvement.<sup>6,7</sup>

Although classic TS is more prevalent in post-menopausal women which could be due to hormonal effects or early dying of men even before diagnosis, younger premenopausal women contain most number of atypical TS.<sup>7</sup> There are some risk factors reported for TS which some of them include estrogen lacking or genetic factors.<sup>3,4</sup> Unlike typical cases, our patient was a young woman with regular menstruation.

TS prevalence was estimated to be between 1.5% and 2.2%.<sup>2</sup> Although it is rare, recurrence could occur 3 months to 13 years thereafter,<sup>7</sup> and the exact recurrence rate has yet to be defined, but ranges from 0%-15% reported in different studies.<sup>5,6,12</sup>

Till today, there is not a comprehensive diagnostic criterion for TS. Although Abe and Kondo, Prasad, Segovia Cubero and Pereira Moral,<sup>13</sup> and Kawai mayo clinic criteria are all used worldwide, the latter is more acceptable among authors.<sup>1,5,7</sup> Chest pain and dyspnea are the most common chief complaints in patients referring to emergency departments, but the spectrum of symptoms would be from an asymptomatic one to cardiogenic shock or arrest.<sup>2,3,5,7</sup> The most similar disease in clinical manifestations to it is MI, but other differential diagnosis should be kept in mind which includes the followings: LV apical aneurysm, aortic dissection, pneumothorax, pulmonary embolism and edema, gastrointestinal (GI) problems like gastroesophageal reflux disease (GERD), esophageal spasm, spontaneous esophageal rupture (Boerhaave syndrome), and myocarditis.<sup>3</sup> Stress, either emotional

or physical, is often present in past histories of patients which men mostly experience a physical rather than emotional one, but other rare triggers such as natural disasters or snake bite could also cause TS.<sup>6,14,15</sup>

Five percent of patients had no elevation in cardiac biomarkers during TS; but in majority of them, creatine kinase-MB (CK-MB) and troponin levels would be raised in the acute setting.<sup>7</sup> Our patient had a normal range of troponin level during admission. As today, there is not a definite cut-off point to distinguish TS from MI. In a study done by Apple et al., CK-MB and troponin I greater than 10.5 U/l and 4.5 ng/ml, respectively, could be suggestive of ischemia.<sup>11</sup> Like other cardiac diseases, TS has some ECG findings as follows: ST segment elevations especially in anterior leads, inverted T waves, QT<sub>c</sub> prolongation, and pathological Q waves. T-wave inversion may be with a poorer prognosis.<sup>3,6,7</sup> Although several efforts had been done for finding a way to distinguish TS just on the basis of ECG changes, it was not being successful yet. Some authors observed that ST elevation less than 1.75 mm or 2.5 mm in leads V2 and V3, respectively, has higher specificity for TS. ECG of patients with TS has few pathological Q waves, less ST depression, and longer QT<sub>c</sub> segment. V4-V6/V1-V3 ratio of greater than 1 is highly sensitive and suggestive for TS. All of these ECG alterations usually will be normalized in duration from three weeks to one year after the attack.<sup>6,7,13,16</sup>

Among different imaging techniques, echocardiography is a convenient choice. Typical findings which are almost always present in classic TS are reduced EF and apical akinesia or hypokinesia concurrent with hyperkinesia of basal region, but it will be different in atypical forms due to its specific segment of involvement. Functional valve disturbances like TR, aortic insufficiency (AI), or MR can also occur, but generally all these findings return back to normal ranges during the first one year after TS.<sup>3,4,7</sup> For differentiating TS from MI or even myocarditis, CMR is one of the best tools. Absence of LGE is seen in 95% of patients with TS, while CMR of patients suffering from MI or myocarditis showed LGE.<sup>3,7</sup> If TS is recognized correctly, unlike its resemblance to MI, it will have almost a favorable prognosis. 96% of patients will recover completely during the first weeks or months after the onset.<sup>3</sup> There is not an appropriate guideline for either short or long-term TS treatment. Supportive therapy is the treatment

of choice in acute phase and especially in stable patients.<sup>1,3,4,6</sup> Other therapies like  $\beta$ -blocker or  $\alpha$ -adrenergic drugs had controversial results and complementary studies must have been done to proof them, but the most important point in treatment of patients is individualization of therapy according to their conditions.<sup>4,6</sup>

HF is one of the most common complications which could occur in TS. Other ones, although rare, like ventricular fibrillation (VF), septal perforation, and ventricle or papillary muscle rupture were also reported. Hayashi et al.<sup>17</sup> reported the first LV aneurysm due to TS in presence of ventricular wall thickening.<sup>7</sup> Dissection is less reported as a TS complication and almost all cases were SCADs, but intra-myocardial dissection due to TS is never reported as mostly found as a major complication in patients with MI.<sup>8,9</sup> Due to similar clinical presentations and gender preference with TS, some authors considered them as a single disease; however, others believe the reverse. For instance, Hassan et al. announced a 54-year-old woman with simultaneous SCAD and TS in different cardiac locations.<sup>10</sup> In contrast, Bakhit and Bin Abdulkhak reported a 30-year-old woman presented with probable signs and symptoms of acute coronary syndrome (ACS) which after normal cardiac angiography results, TS was diagnosed and she was discharged. Several days later, she returned back with similar presentations. Further evaluations showed mid to distal coronary left anterior descending (LAD) dissection misdiagnosed as TS in previous admission.<sup>18</sup> TS leading to intra-myocardial dissection and LV apical aneurysm has never been reported and perhaps it is the first case in the literature.

In conclusion, TS is a reversible benign LV systolic dysfunction with favorable prognosis and less significant complications. Intra-myocardial dissection must be categorized as one of rarest TS complication beside LV apical aneurysm and rupture. Further studies are required in order to define the exact etiology and pathophysiological mechanisms.

### Acknowledgments

None.

### Conflict of Interests

Authors have no conflict of interests.

### References

1. Akashi YJ, Goldstein DS, Barbaro G, Ueyama T. Takotsubo cardiomyopathy: A new form of acute,

- reversible heart failure. *Circulation* 2008; 118(25): 2754-62.
2. Guttormsen B, Nee L, Makielski JC, Keevil JG. Transient left ventricular apical ballooning: A review of the literature. *WMJ* 2006; 105(3): 49-54.
  3. Komamura K, Fukui M, Iwasaku T, Hirotani S, Masuyama T. Takotsubo cardiomyopathy: Pathophysiology, diagnosis and treatment. *World J Cardiol* 2014; 6(7): 602-9.
  4. Roshanzamir S, Showkathali R. Takotsubo cardiomyopathy a short review. *Curr Cardiol Rev* 2013; 9(3): 191-6.
  5. Sealove BA, Tiyyagura S, Fuster V. Takotsubo cardiomyopathy. *J Gen Intern Med* 2008; 23(11): 1904-8.
  6. Kurisu S, Kihara Y. Clinical management of Takotsubo cardiomyopathy. *Circ J* 2014; 78(7): 1559-66.
  7. Castillo Rivera AM, Ruiz-Bailen M, Rucabado Aguilar L. Takotsubo cardiomyopathy-a clinical review. *Med Sci Monit* 2011; 17(6): RA135-RA147.
  8. Liu CC, Wang LS, Su ZP, Zhao Y, Gu CX. Intramyocardial dissection with concomitant left ventricular aneurysm as a rare complication of myocardial infarction: A case report. *J Geriatr Cardiol* 2016; 13(7): 632-5.
  9. Xie M, Zhou H, Cheng TO, Wang J, Wang X, Lu Q, et al. Left ventricular apical aneurysm associated with normal coronary arteries following cardiac surgery: echocardiographic features and differential diagnosis. *Int J Cardiol* 2013; 168(4): 3665-70.
  10. Hassan S, Themudo R, Maret E. Spontaneous coronary artery dissection and Takotsubo syndrome: The chicken or the egg causality dilemma. *Catheter Cardiovasc Interv* 2017; 89(7): 1215-8.
  11. Apple FS, Quist HE, Doyle PJ, Otto AP, Murakami MM. Plasma 99<sup>th</sup> percentile reference limits for cardiac troponin and creatine kinase MB mass for use with European Society of Cardiology/American College of Cardiology consensus recommendations. *Clin Chem* 2003; 49(8): 1331-6.
  12. Sharkey SW, Maron BJ. Epidemiology and clinical profile of Takotsubo cardiomyopathy. *Circ J* 2014; 78(9): 2119-28.
  13. Segovia Cubero J, Pereira Moral R. Transient apical ballooning syndrome: A transition towards adulthood. *Rev Esp Cardiol* 2004; 57(3): 194-7.
  14. Murase K, Takagi K. Takotsubo cardiomyopathy in a snake bite victim: A case report. *Pan Afr Med J* 2012; 13: 51.
  15. Watanabe H, Kodama M, Okura Y, Aizawa Y, Tanabe N, Chinushi M, et al. Impact of earthquakes on Takotsubo cardiomyopathy. *JAMA* 2005; 294(3): 305-7.
  16. Ogura R, Hiasa Y, Takahashi T, Yamaguchi K, Fujiwara K, Ohara Y, et al. Specific findings of the standard 12-lead ECG in patients with 'Takotsubo' cardiomyopathy: Comparison with the findings of acute anterior myocardial infarction. *Circ J* 2003; 67(8): 687-90.
  17. Hayashi H, Kimura M, Kato T, Nakasone K, Seko Y, Sekihara T, et al. Reversible left ventricular wall thickening with Takotsubo syndrome sequentially detected by cardiac magnetic resonance imaging. *Intern Med* 2018; 57(4): 517-22.
  18. Bakhit A, Bin Abdulhak A. Spontaneous coronary dissection misdiagnosed as Takotsubo's Cardiomyopathy. *Int J Cardiol* 2016; 225: 384-6.