

## Technical Article

# Phrenic nerve decompression for the management of unilateral diaphragmatic paralysis – preoperative evaluation and operative technique

Reid Hoshide, Justin Brown

Department of Neurosurgery, University of California – San Diego, San Diego, California, USA

E-mail: \*Reid Hoshide - [Rhoshide@ucsd.edu](mailto:Rhoshide@ucsd.edu); Justin Brown - [Jmbrown@ucsd.edu](mailto:Jmbrown@ucsd.edu)

\*Corresponding author

Received: 06 June 17 Accepted: 24 August 17 Published: 24 October 17

## Abstract

**Background:** Unilateral diaphragmatic paralysis (UDP) can be a very disabling, typically causing shortness of breath and reduced exercise tolerance. We present a case of a surgical decompression of the phrenic nerve of a patient who presented with UDP, which occurred following cervical spine surgery.

**Methods:** The workup for the etiology of UDP demonstrated paradoxical movement on “sniff test” and notably impaired pulmonary function tests. Seven months following the onset of the UDP, he underwent a surgical decompression of the phrenic nerve at the level of the anterior scalene.

**Results:** He noted rapid symptomatic improvement following surgery and reversal of the above noted objective findings was documented. At his 4-year follow-up, he had complete resolution of his clinical symptoms. Repeated physiologic testing of his respiratory function had shown a complete reversal of his UDP.

**Conclusions:** Anatomical compression of the phrenic nerve by redundant neck vasculature should be considered in the differential diagnosis of UDP. Here we demonstrated the techniques in workup and surgical management, with both subjective and objective evidence of success.

**Key Words:** Diaphragmatic paralysis, neurolysis, peripheral nerve surgery, phrenic nerve

### Access this article online

**Website:**[www.surgicalneurologyint.com](http://www.surgicalneurologyint.com)**DOI:**

10.4103/sni.sni\_205\_17

**Quick Response Code:**

## INTRODUCTION

Unilateral diaphragmatic paralysis (UDP), secondary to phrenic nerve palsy, can be caused by a multitude of etiologies, but the actual cause is often elusive. It has been recently proposed that vascular compression from traversing vessels at the level of the thoracic outlet may contribute as in other compressive neurapraxias; in such a case surgical decompression may result in functional recovery.

Here we describe the preoperative assessment and the operative technique used to address a unilateral phrenic

nerve palsy. Tightly adherent traversing vessels were identified at the time of exploration, specifically the

This is an open access article distributed under the terms of the Creative Commons Attribution-NonCommercial-ShareAlike 3.0 License, which allows others to remix, tweak, and build upon the work non-commercially, as long as the author is credited and the new creations are licensed under the identical terms.

**For reprints contact:** [reprints@medknow.com](mailto:reprints@medknow.com)

**How to cite this article:** Hoshide R, Brown J. Phrenic nerve decompression for the management of unilateral diaphragmatic paralysis – preoperative evaluation and operative technique. *Surg Neurol Int* 2017;8:254.

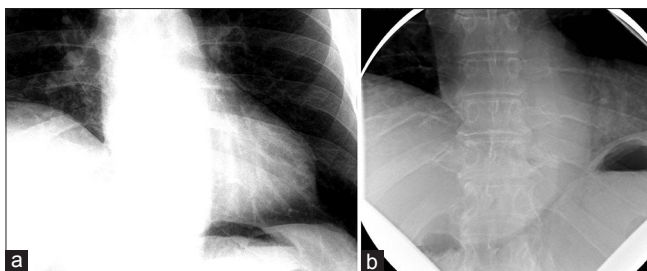
<http://surgicalneurologyint.com/Phrenic-nerve-decompression-for-the-management-of-unilateral-diaphragmatic-paralysis---preoperative-evaluation-and-operative-technique/>

transverse cervical and suprascapular arteries. Following ligation and sacrifice of these traversing vessels with neurolysis of the phrenic nerve over this segment, the patient's clinical symptoms resolved and the previously paralyzed diaphragm recovered.

## PATIENT HISTORY

The patient was a 60-year-old male with a remote history of a motor vehicle accident who originally presented with symptoms of bilateral arm weakness and hyperesthesia, symptoms consistent with central cord syndrome. He underwent an anterior cervical discectomy and fusion at C5-C6 and C6-C7 levels through a left-sided approach. His weakness improved after surgery and he recalled no shortness of breath related to the accident or surgery at that time. Seven years later, he developed progressive myelopathic symptoms and was subsequently taken for a C4 to T2 laminectomy and posterior fusion, which was successful. Shortly following this operation, he began to experience shortness of breath. These symptoms persisted and gradually worsened over the course of 6 months to the point where he no longer had the respiratory stamina to do activities that he used to enjoy previously. At that time, the patient presented to our center and underwent workup for these symptoms. A fluoroscopic sniff test demonstrated paradoxical elevation of the right hemidiaphragm on rapid, forced inspiration with normal excursion of the left hemidiaphragm [Figure 1a]. On deep, forced expiration, the right hemidiaphragm had a paradoxical downward excursion, while the left hemidiaphragm had normal upward excursion [Figure 1b]. Both of these findings were consistent with right hemidiaphragm paralysis.

He additionally underwent pulmonary function tests (PFTs), which demonstrated findings similar to that of restrictive airway disease, as represented by a decreased 1-second forced expiratory volume (FEV1), decreased forced vital capacity (FVC), but with a preserved FEV1/FVC ratio. Moreover, he had a reduced total lung capacity (TLC) and vital capacity (VC). These values had negligible improvement following the



**Figure 1:** (a) Fluoroscopic sniff test on deep inspiration, showing elevation of the right hemidiaphragm with depression of the left hemidiaphragm. (b) Fluoroscopic sniff test on deep expiration, showing depression of the right hemidiaphragm with elevation of the left hemidiaphragm

administration of inhaled albuterol, distinguishing his diaphragmatic paralysis from intrinsic restrictive airway disease [Table 1].

Analysis by electromyography (EMG) demonstrated an isolated, paralysis of the right phrenic nerve as evidenced by a lack of response at the recording lead within the diaphragm at the T8/9 intercostal space when stimulating the phrenic nerve at the level of the sternocleidomastoid [Table 2]. This was determined to be incomplete because direct EMG evaluation at the same location demonstrated few long duration complex motor unit potentials. The left phrenic nerve was intact as verified by both robust stimulation using the same technique and a full interference pattern on needle EMG.

It was concluded that his right hemidiaphragm was paralyzed due to a severe but incomplete right phrenic nerve injury. Due to the chronicity of this incomplete deficit, we offered a phrenic nerve exploration and decompression.

## OPERATIVE TECHNIQUE

At 7 months from the onset of symptoms, the patient was taken for exploration of the phrenic nerve. He was brought to the operating room and placed under general anesthesia. The anesthesia team avoided the use of paralytic agents in order to preserve neuromonitoring capabilities during the case. The patient was positioned supine with his head turned to the left. A small bump was placed vertically between his shoulder blades to allow his shoulder to fall posteriorly, thereby maximizing the

**Table 1: Pulmonary function test measurements of our patient with suspected unilateral diaphragmatic paralysis secondary to phrenic nerve compression**

Measure	Prealbuterol		Postalbuterol		
	Reference	Actual	Actual: Reference (%)	Actual	% Change
FVC (L)	4.33	3.37	55	2.36	0
FEV1 (L)	3.27	1.86	57	1.95	+5
FEV1/FVC (%)	76	79	104	83	+4
VC (L)	4.1	2.46	60	NA	NA
TLC (L)	6.58	3.77	57	NA	NA

**Table 2: Electromyography and nerve conduction testing of the left and right phrenic nerve of our patient with suspected unilateral diaphragmatic paralysis secondary to phrenic nerve compression**

Nerve	Side	Stimulus electrode	Recording electrode	Latency (ms)	Amplitude (mV)
Phrenic	Left	Sternocl eidomastoid	8/9 intercostal space	6.25	0.61
Phrenic	Right	Sternocl eidomastoid	8/9 intercostal space	NR	NR

exposure of the right clavicular area. A 3 cm horizontal linear incision was made of a fingerbreadth superior to the clavicle, centered over the sternocleidomastoid. The platysma was divided, the sternocleidomastoid was retracted medially, and the supraclavicular fat pad was reflected superolaterally, exposing the anterior scalene. The phrenic nerve was identified on the surface of the anterior scalene with associated vessels crossing superficially, horizontally, and in contact with the phrenic nerve. These two arteries were running in parallel fashion immediately adjacent to one another – the suprascapular and transverse cervical arteries.<sup>[10]</sup> These arteries were also intimately impressed upon the phrenic nerve with shared fascial investment. Stimulation of the phrenic nerve proximal and distal to these intersections yielded no observable response of the diaphragm, in accordance with the findings on the preoperative compound muscle action potential (CMAP) study. The suprascapular and transverse cervical arteries were suture-ligated and sacrificed where they crossed the phrenic nerve. Finally, neurolysis of the nerve from these fascial investments at the level of the anterior scalene was performed. Additional stimulation of the phrenic nerve proximal and distal to the arterial contacts was performed, with no appreciable change in stimulatory response from the diaphragm.

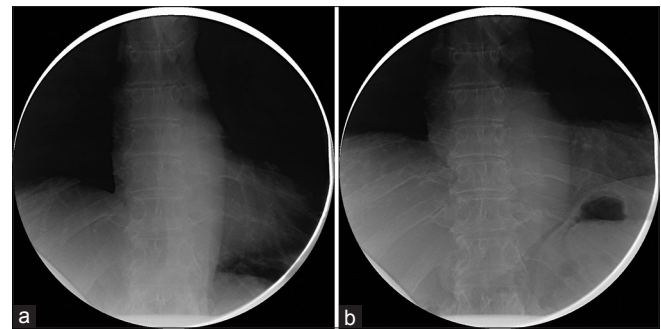
In the immediate postop period, the patient did not endorse any improvement in his symptoms, nor did he describe any complications of the procedure. He was discharged home later that day after a period of postanesthesia observation.

### Follow-up

At his 1-month follow-up, the patient reported that soon after surgery he developed a mild cramping sensation in his right chest wall at the level of the diaphragm, which was exacerbated by deep inspiration. In fact, he described that he would “guard” during deep inspiration due to the cramping pain. No testing was performed at this time.

At his 6-month follow-up, he endorsed that the cramping pains had resolved shortly thereafter and he subjectively felt that his work of breathing improved. He noted that within a few weeks of the prior visit he felt that he was able to take fuller breaths than before. He was subsequently able to return to his normal level of activity, no longer finding himself “winded” when ascending his steep driveway. His incision was well-healed and he tolerated the sacrifice of the compressive arteries well. A sniff test was performed prior to this follow-up, revealing an improved excursion of the right diaphragm, now symmetric with the left diaphragm [Figure 2a and b].

Four years following surgery, he returned to our clinic after obtaining a new sniff test and a new PFT. At this time, the patient reported that he had returned to his baseline exercise tolerance. He had no additional



**Figure 2:** (a) Upon deep inspiration, both the left and right hemidiaphragms move symmetrically downward. (b) Upon deep expiration, both the left and right hemidiaphragms move symmetrically upward

**Table 3: Preoperative and postoperative comparison of pulmonary function measurements following phrenic nerve decompression**

Measure	Preoperative values			Postoperative values (4 years later)			Difference %
	Ref	Actual	%	Ref	Actual	%	
FVC (L)	4.33	3.37	55	4.29	3.47	81	+26
FEV1 (L)	3.27	1.86	57	3.37	2.86	85	+28
FEV1/FVC (%)	76	79	104	78.63	82.58	105	+1
VC (L)	4.1	2.46	60	4.29	3.92	91	+31
TLC (L)	6.58	3.77	57	6.49	5.75	88	+31

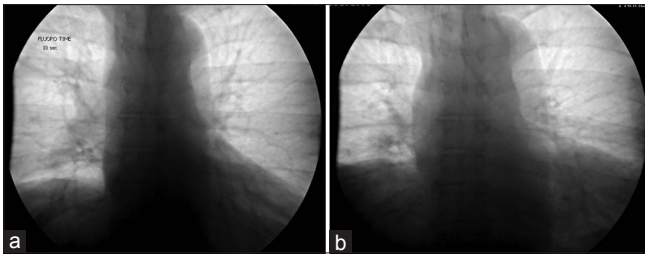
neurological complaints. His PFTs performed at this visit demonstrated a significant improvement in FEV1, FVC, VC, and TLC [Table 3]. The FEV1/FVC ratio was stable from preop and postop, which is a result of both values increasing symmetrically. The ratio was not abnormal preoperatively, but the individual values of the FEV1 and the FVC were below the reference values.

His sniff test demonstrated durable improvement, and was stable compared to the previous sniff test performed 6 months postoperatively. The diaphragmatic excursion was symmetric in both the maximum exhalation and maximum inhalation sequences [Figure 3a and b]. The degree of excursion difference between preoperative and postoperative imaging was not feasible to measure, due to the ambiguity of rib-counting within the focused field of view of the X-rays. However, the paradoxical excursions of the diaphragm were not present on this postoperative sniff test.

Because of his overall improvement in objective measures (PFTs and fluoroscopic sniff test), coupled with his overall clinical subjective improvement, we decided not to pursue a new EMG/NCS study.

### DISCUSSION

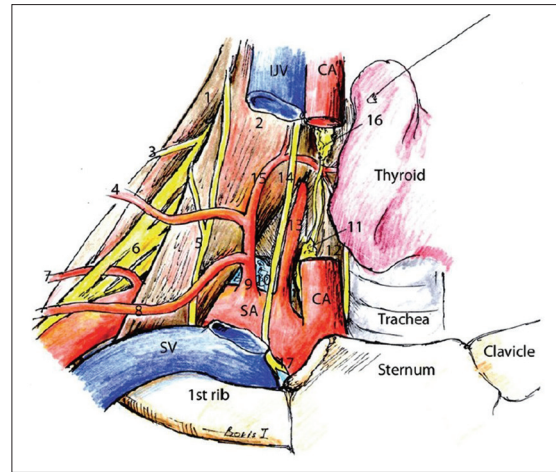
UDP is an uncommon affliction. The most common symptom of UDP is shortness of breath on exertion.



**Figure 3: (a) Upon deep inspiration, both the left and right hemidiaphragms move symmetrically downward. (b) Upon deep expiration, both the left and right hemidiaphragms move symmetrically upward**

However, many patients are asymptomatic and have incidental diagnoses based on chest radiographs for other reasons.<sup>[9]</sup> Iatrogenic injury from cardiothoracic and neck surgery is the most common identifiable cause of phrenic nerve palsies (36%), which is secondary to incidental transection, stretching, or thermal injury to the nerve.<sup>[2]</sup> Other causes of phrenic nerve palsies include tumor compression (19%), inflammation (14%), and trauma (14%).<sup>[1,8]</sup> In many cases, however, the etiology is unknown (17%).<sup>[1]</sup> A new, emerging vascular etiology has been considered, potentially caused by a vascular compression of the phrenic nerve by the transverse cervical artery or suprascapular artery at the level of the thoracic outlet.<sup>[5]</sup> The relationship of the phrenic nerve to these arteries and their surrounding structures is shown in Figure 4.

It was difficult to determine the exact pathophysiologic mechanism behind our patient's UDP. Certainly, patient positioning and shoulder traction in preparation for the surgery could have led to traction of the nerve, particularly given the anatomical arrangement at the level of the anterior scalene. Following anterior cervical discectomy and fusion, there is typically height added to the spine as the large intervertebral disc replacements are placed to distract the foramen. In doing so, the scalene muscles which originate from the transverse processes and insert on the first rib can experience additional traction. In a patient with a history of whiplash injury, the scalene muscles are frequently more fibrotic with thicker fascia and thus have less "give." This could theoretically lead to tensioning of the scalene muscles and associated fascia and the invested structures (arteries), pressing them against adjacent nervous structures (the phrenic nerve in this case). Curiously, his symptoms arose immediately following a posterior cervical spine fusion, which does not typically result in the same type of cervical distraction. Ultimately, it could be inflammatory, such as a Parsonage-Turner Syndrome, or a combination of many different etiologies. In our case the exact cause of the phrenic palsy cannot be clearly identified and whether our intervention was the source of the improvement or simply corresponded temporally



**Figure 4: Illustration of the relationship between the arteries, musculature, and nerves of the clavicular area. (1) Middle scalene muscle, (2) anterior scalene muscle, (3) dorsal scapular nerve, (4) transverse cervical artery, (5) phrenic nerve, (6) brachial plexus, (7) dorsal scapular artery, (8) suprascapular artery, (9) thyrocervical artery, (10) lung, (11) inferior cervical sympathetic ganglion, (12) longus colli muscle, (13) vertebral artery, (14) vagus, (15) inferior thyroid artery, (16) middle cervical sympathetic ganglion, (17) recurrent laryngeal nerve. Original image reprinted from: *Int J Shoulder Surg.* 2010 Jul-Sep; 4 (3): 63–74. Creative Commons Attribution 4.0 (CC BY-SA 4.0). Full terms at <https://creativecommons.org/licenses/by-sa/4.0>**

with the natural recovery of the nerve is impossible to determine.

The pathophysiologic mechanisms of shortness of breath in UDP are two-fold.<sup>[6]</sup> Primarily, the paralysis of the hemidiaphragm increases mechanical respiratory effort. Secondly, there is paradoxical diaphragmatic elevation on the affected side due to a normal downward excursion of the contralateral diaphragm which increases intraabdominal pressures that apply a force to elevate the affected diaphragm. This paradoxical motion antagonizes the work of the accessory muscles of respiration, thereby increasing the work of breathing even further.<sup>[6]</sup> This paradoxical motion was seen on our patient's sniff test and returned to normal motion on postoperative imaging.

Due to the rarity of this disease, there is no single well-studied course of management of patients with UDP. The single-most studied treatment has been diaphragmatic plication.<sup>[3,4,11]</sup> Plication of the diaphragm surgically increases the tensile strength of the diaphragm by removing the redundancy, which prevents paradoxical excursion. Prevention of paradoxical excursion allows movement of the contralateral diaphragm to indirectly pull the ipsilateral diaphragm as it descends. Plication of the diaphragm certainly has intraoperative and postoperative risks.<sup>[11]</sup> The decision for surgical correction must weigh in the manifestation of disease in the patient's day-to-day livelihood. Results of plication have been shown to be quite successful.<sup>[3,4,11]</sup> Though

diaphragmatic plication does not reverse the etiological cause of UDP, it manages the symptoms. Another option more recently introduced has involved transfer of intercostal nerves to the distal phrenic to restore tone to this muscle.<sup>[7]</sup>

Recent advances in surgical technique have aimed at reversing the etiologic causes of UDP. Kaufman *et al.* were the first to describe the concept presented here that ligation of the transverse cervical artery at the phrenic nerve may have contributed to restored diaphragmatic function immediately postoperatively in three patients who they believed suffered from a compressive vascular etiology.<sup>[5]</sup> They also demonstrated intraoperative evidence of a conduction block within the phrenic nerve, in which proximal stimulation elicited no response, whereas distal stimulation did result in robust activation prior to ligation. Here, we presented a case of vascular decompression of the phrenic nerve in a patient with UDP with postoperative resolution of symptoms, which lacked intraoperative confirmation of a conduction block. This case demonstrated postoperative success of decompression of the phrenic nerve by ligation and sacrifice of the transverse cervical and the suprascapular arteries. Symptoms of returning diaphragmatic function appeared very soon after the procedure, making it a feasible explanation for this sudden change after 7 months of paralysis. This case showcases the preoperative workup and the operative technique to decompress the phrenic nerve. Unlike diaphragmatic plication, phrenic nerve decompression targets the etiology rather than the pathophysiology of UDP secondary to phrenic nerve compression, and should be considered in the management of this disabling disease entity.

## Financial support and sponsorship

Nil.

## Conflicts of interest

There are no conflicts of interest.

## REFERENCES

1. Eleftheriades J, Singh M, Tang P, Siegel MD, Kenney B, Pandey A, *et al.* Unilateral diaphragm paralysis: Etiology, impact, and natural history. *J Cardiovasc Surg (Torino)* 2008;49:289-95.
2. Fell SC. Surgical anatomy of the diaphragm and the phrenic nerve. *Chest Surg Clin N Am* 1998;8:281-94.
3. Graham DR, Kaplan D, Evans CC, Hind CR, Donnelly RJ. Diaphragmatic plication for unilateral diaphragmatic paralysis: A 10-year experience. *Ann Thorac Surg* 1990;49:248-51; discussion 252.
4. Higgs SM, Hussain A, Jackson M, Donnelly RJ, Berrisford RG. Long term results of diaphragmatic plication for unilateral diaphragm paralysis. *Eur J Cardiothorac Surg* 2002;21:294-7.
5. Kaufman MR, Willekes LJ, Elkwood AI, Rose MI, Patel TR, Ashinoff RL, *et al.* Diaphragm paralysis caused by transverse cervical artery compression of the phrenic nerve: The Red Cross syndrome. *Clin Neurol Neurosurg* 2012;114:502-5.
6. Ko MA, Darling GE. Acquired paralysis of the diaphragm. *Thorac Surg Clin* 2009;19:501-10.
7. Krieger LM, Krieger AJ. The intercostal to phrenic nerve transfer: An effective means of reanimating the diaphragm in patients with high cervical spine injury. *Plast Reconstr Surg* 2000;105:1255-61.
8. McCool FD, Tzelepis GE. Dysfunction of the diaphragm. *N Engl J Med* 2012;366:932-42.
9. Piehler JM, Pairolero PC, Gracey DR, Bernatz PE. Unexplained diaphragmatic paralysis: A harbinger of malignant disease? *J Thorac Cardiovasc Surg* 1982;84:861-4.
10. Verenna AA, Alexandru D, Karimi A, Brown JM, Bove GM, Daly FJ, *et al.* Dorsal scapular artery variations and relationship to the brachial plexus, and a related thoracic outlet syndrome case. *J Brachial Plex Peripher Nerve Inj* 2016;11:e21-8.
11. Versteegh MI, Braun J, Voigt PG, Bosman DB, Stolk J, Rabe KF, *et al.* Diaphragm plication in adult patients with diaphragm paralysis leads to long-term improvement of pulmonary function and level of dyspnea. *Eur J Cardiothorac Surg* 2007;32:449-56.