

Anal Pain of an Unusual Cause: Role of Endoanal Ultrasound

Ioannis D. Gkegkes^{1,2*}, Apostolos P. Stamatiadis¹

¹Athens Colorectal Laboratory, Athens, Greece, ²Department of Surgery, General Hospital of Attica "KAT", Athens, Greece

Abstract

Anal pain is among the most frequent complaints referred in coloproctology clinic. Nevertheless, this symptom may have a great variety of etiopathogenetic causes. This is the first report that highlights the presence of a rare cause of anal pain, originated by ingested seeds. A 65-year-old male had a 4-day history of fever, anal pain, and discharge. A three-dimensional endoanal ultrasound revealed two perianal abscess cavities with central hyperechogenic areas, in the absence of acoustic shadow. The patient underwent examination under epidural anesthesia, where the two cavities were drained endoanally. Two cereal grains (linseed/sunflower seed) were found during the drainage of the abscess. The utilization of endoanal ultrasound in the investigation of perianal pain is a valuable option. In addition, apart from the size and the exact dimensions of abscesses, endoanal ultrasound also permits the clarification even the most remote etiopathogenetic causes of anal pain.

Keywords: Abscess, anal pain, endoanal ultrasound, perianal sepsis, seed, three-dimensional endoanal ultrasound

INTRODUCTION

Anal pain is among the most frequent complaints referred in coloproctology clinic.^[1] The pain originated from the anal canal or the perianal region may also present great variability as far as the origin of the etiology of this symptom. Anal fissure, perianal fistula, anorectal abscesses as well as perianal hematoma are among the most frequent causes of pain at the perianal region.^[2] Less common causes of anal pain may include pruritus ani, thrombosed piles, Crohn's disease, solitary rectal ulcer syndrome, fecal impaction, proctitis, rectal prolapse, anorectal malignancy, as well as chronic idiopathic syndromes, such as levator ani syndrome, coccygodynia, and proctalgia fugax.^[3] We describe for the first time in the literature a case of an unusual cause of perianal pain, which was diagnosed by the utilization of endoanal ultrasound.

CASE REPORT

A 65-year-old man was presented at our clinic with low-grade fever (T_{\max} : 37.7°C) and with excruciating anal pain at the sitting position, which started 4 days ago. By his medical history, there was no evidence of immunosuppression. During clinical examination, a soft-tissue infection was

noticed at the perianal region with combined intra-anal secretion of pus. Due to pain, anoscopy was not feasible. A three-dimensional (3D) endoanal ultrasound (Hawk type 2050; Bruel and Kjaer Medical, Naerum, Denmark) was performed with the use of a transrectal ultrasound probe (anorectal 3D 2052). The endoanal ultrasound revealed two perianal abscess cavities of 11 mm × 9.3 mm × 6.1 mm and 11.9 mm × 9.4 mm × 8.9 mm [Figures 1 and 2], respectively. In addition, inside these cavities, there were central, well-defined hyperechogenic areas without acoustic shadow, measuring 6 mm × 2.4 mm × 0.5 mm and 4.9 mm × 4.3 mm × 0.6 mm, respectively. A written informed consent was obtained from the patient for publication of this case report. The patient underwent examination under epidural anesthesia, where the two cavities were drained endoanally. Two cereal grains (linseed/sunflower seed) were found during the drainage of the abscess [Figures 3 and 4]. The patient was discharged after 24 h and went home with oral administration of metronidazole (500 mg, tid) for 3 days. After 5 days, the patient took over his habitual activities, showing complete recover.

Address for correspondence: Dr. Ioannis D. Gkegkes,
141, Oropou Str., Nea Ionia, Athens 14232, Greece.
E-mail: ioannisgkegkes@gmail.com

Received: 04-09-2018 Accepted: 18-12-2018 Available Online: 13-02-2019

Access this article online

Quick Response Code:



Website:
www.jmuonline.org

DOI:
10.4103/JMU.JMU_90_18

This is an open access journal, and articles are distributed under the terms of the Creative Commons Attribution-NonCommercial-ShareAlike 4.0 License, which allows others to remix, tweak, and build upon the work non-commercially, as long as appropriate credit is given and the new creations are licensed under the identical terms.

For reprints contact: reprints@medknow.com

How to cite this article: Gkegkes ID, Stamatiadis AP. Anal pain of an unusual cause: Role of endoanal ultrasound. J Med Ultrasound 2019;27:107-9.

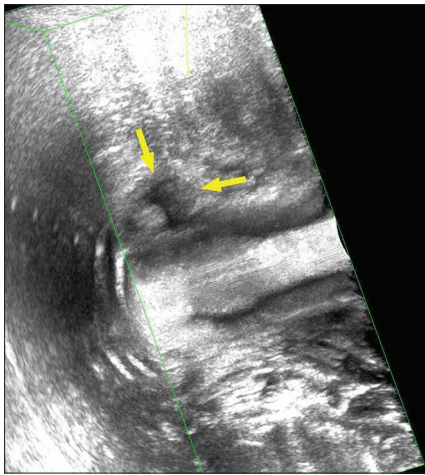


Figure 1: Three-dimensional endoanal ultrasound image of the perianal abscess

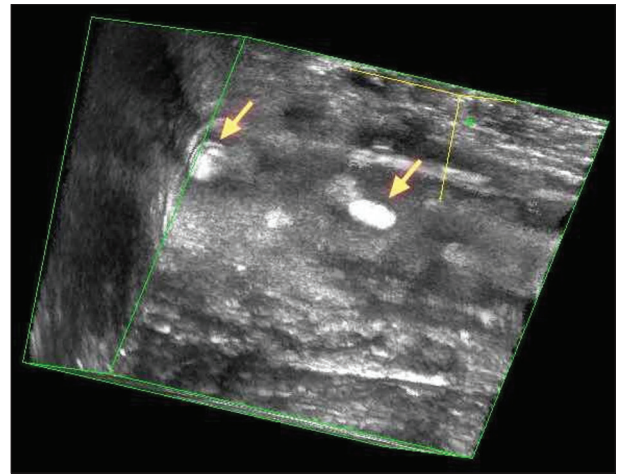


Figure 2: Three-dimensional endoanal ultrasound image of the identified seeds

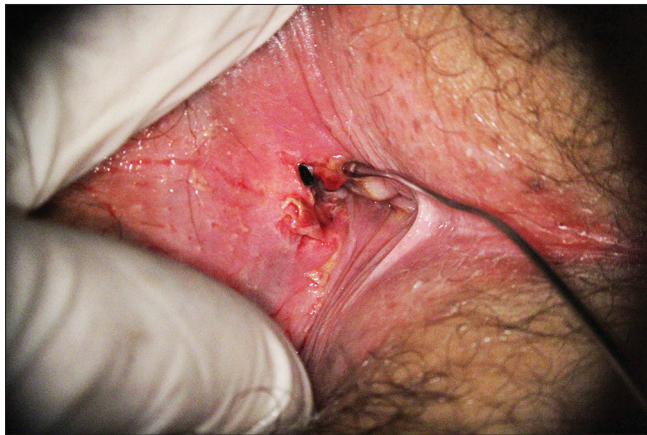

Figure 3: Retrieved linseed from the perianal abscess cavity

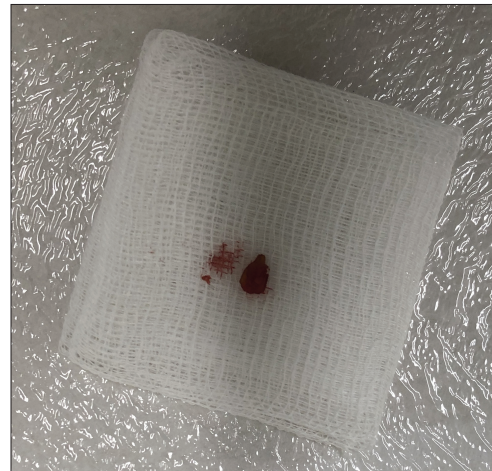

Figure 4: The extracted sunflower seed after the perianal abscess drainage

DISCUSSION

Perianal sepsis is a common benign condition with multiple pathophysiological causes.^[4-6] The selection of the most suitable treatment strategy is in correlation with the origin (cryptoglandular or not), the location as well as with the extension of sepsis.^[7] Moreover, apart from the clinical findings, it is considered prudent for the surgeon to obtain further preoperative information about the perianal sepsis, through adjunctive imaging.^[8]

Imaging, in the cases of anal pain or perianal sepsis, plays a crucial role in identifying the precise etiology of the clinical condition, when the diagnosis is not evident. Endoanal ultrasound is mainly used to evaluate the perianal anatomic structures, such as the anal sphincters and the intersphincteric plane.^[9] During 3D endoanal ultrasound recording, the crystals are automatically moved backward, permitting the representation of the entire anal canal, while longitudinal and vertical distances can also be measured.^[10,11] In comparison to the other most common image modalities, the magnetic resonance imaging (MRI) and endoanal ultrasound represent a more economic and easily available imaging technique

with shorter waiting lists for patients. Furthermore, MRI is a rather bulky equipment on the contrary to endoanal ultrasound which is a portable unit that can be carried around. Diversely, endoanal ultrasound is operator-related method, even though both modalities have shown good agreement regarding the preoperative assessment of the most frequent perianal clinical conditions, such as abscess, fistulas, and sepsis.^[11] Last but not least, an important contraindication is the utilization of MRI in patients who have implanted ferromagnetic objects, such as metal shrapnel or various medical devices while such limitation does not exist in the endoanal ultrasound modality.

In the last decades, endoscopic ultrasound (EUS) was also proposed as a mean to drain pelvic abscesses.^[12,13] Even though EUS has not only diagnostic but also therapeutic use, EUS is not appropriate for investigation of anal disorders due to the problems arising in the acoustic coupling, both with the balloon and with the direct water technique. Reversely, endoanal ultrasound can obtain 3D reconstruction not only of the anal canal but also of the rectum with the use of the ultrasound probe of 25 cm. A water-filled balloon can be

fixed on the probe, so both anal canal and the cavity of rectal ampulla can be visualized. In addition, the 360° axial view transducers of the endoanal ultrasound are more appropriate for the visualization of the cylindrical anal canal, while the majority of the commercially available EUS offer only a maximum 180° visualization.

CONCLUSION

The use of endoanal ultrasound in the investigation of perianal pain is a valuable option. In addition, apart from the size and the exact dimensions of abscesses, endoanal ultrasound also permits the clarification of even the most remote etiopathogenetic causes of anal pain.

Declaration of patient consent

The authors certify that they have obtained all appropriate patient consent forms. In the form the patient(s) has/have given his/her/their consent for his/her/their images and other clinical information to be reported in the journal. The patients understand that their names and initials will not be published and due efforts will be made to conceal their identity, but anonymity cannot be guaranteed.

Financial support and sponsorship

Nil.

Conflicts of interest

There are no conflicts of interest.

REFERENCES

1. Givel JC. Symptomatology of anorectal diseases. In: Marti MC, Givel JC, editors. *Surgery of Anorectal Diseases with Pre- and Postoperative Management*. 2nd ed. Berlin: Springer-Verlag Berlin Heidelberg; 1990. p. 13.
2. Townsend CM, Beauchamp R, Evers B, Mattox K, editors. *Sabiston Textbook of Surgery*. 19th ed. Philadelphia: Elsevier Saunders; 2012.
3. Christiansen J. Chronic idiopathic anal pain. *Eur J Surg* 1998;164:83-8.
4. Delikoukos S, Zacharoulis D, Hatzitheofilou C. Perianal abscesses due to ingested foreign bodies. *Int J Clin Pract* 2005;59:856-7.
5. Murad-Regadas SM, Regadas FS, Rodrigues LV, Holanda Ede C, Barreto RG, Oliveira L, *et al*. The role of 3-dimensional anorectal ultrasonography in the assessment of anterior transsphincteric fistula. *Dis Colon Rectum* 2010;53:1035-40.
6. Ratto C, Grillo E, Parello A, Costamagna G, Doglietto GB. Endoanal ultrasound-guided surgery for anal fistula. *Endoscopy* 2005;37:722-8.
7. Brillantino A, Iacobellis F, Di Sarno G, D'Aniello F, Izzo D, Paladino F, *et al*. Role of tridimensional endoanal ultrasound (3D-EAUS) in the preoperative assessment of perianal sepsis. *Int J Colorectal Dis* 2015;30:535-42.
8. Stamatidis A. Endoanal ultrasound in perianal abscesses. *Dis Colon Rectum* 2002;45:710-1.
9. Youssef AT. Use of ultrasonography in clarifying the etiology of anal pain. *J Med Ultrasound* 2017;25:208-14.
10. Felt-Bersma RJ. Endoanal ultrasound in perianal fistulas and abscesses. *Dig Liver Dis* 2006;38:537-43.
11. Visscher AP, Felt-Bersma RJ. Endoanal ultrasound in perianal fistulae and abscesses. *Ultrasound Q* 2015;31:130-7.
12. Giovannini M, Bories E, Moutardier V, Pesenti C, Guillemain A, Lelong B, *et al*. Drainage of deep pelvic abscesses using therapeutic echo endoscopy. *Endoscopy* 2003;35:511-4.
13. Zator Z, Klinge M, Schraut W, Tsung A, Khalid A. One step endoscopic ultrasound guided management of pelvic abscesses: A case series. *Therap Adv Gastroenterol* 2018;11:1756284818785574.