

Letter to the editor

Infectious aortitis complicating ruptured mycotic aneurysm due to *Aeromonas sobria* bacteremia



Dear Editor,

Non-aneurysmal infectious aortitis is a rare clinical disease that is lethal when surgical intervention is delayed. *Aeromonas* species are common pathogens that cause gastrointestinal disorders; however, the extra-intestinal septic syndrome is rare.^{1,2} Extra-intestinal infections include empyema, meningitis, endocarditis, arthritis, and soft tissue infections.¹⁻⁴ Herein, we present a case of *Aeromonas* bacteremic aortitis complicated by a ruptured mycotic aneurysm. A series of computerized tomography images illustrate the complete development of this disease (Figs. 1 A, B, and C). To the best of our knowledge, this is the first documented case of infectious aortitis caused by *Aeromonas sobria* bacteremia.

A 52-year-old man with liver cirrhosis presented to the emergency department with fever and abdominal pain. Laboratory data revealed leukocytosis and elevated C-reactive protein. Abdominal computerized tomography (Fig. 1A) revealed severe calcified atherosclerosis of the abdominal aorta. Empirical antibiotic therapy with cefuroxime (1.5 g) via an Intravenous drip (ivd) q8h was administered. Three days later, duplicate sets of blood cultures revealed *Aeromonas sobria*, which was sensitive to cefuroxime. The isolate (*A. sobria*) was analyzed by Matrix-Assisted Laser Desorption Ionization-time of Flight mass spectrometry (MALDI-TOF) using Bruker Biotyper (Bruker Daltonik GmbH, Bremen, Germany) and identified as *A. sobria* (score value, 2.18). In order to

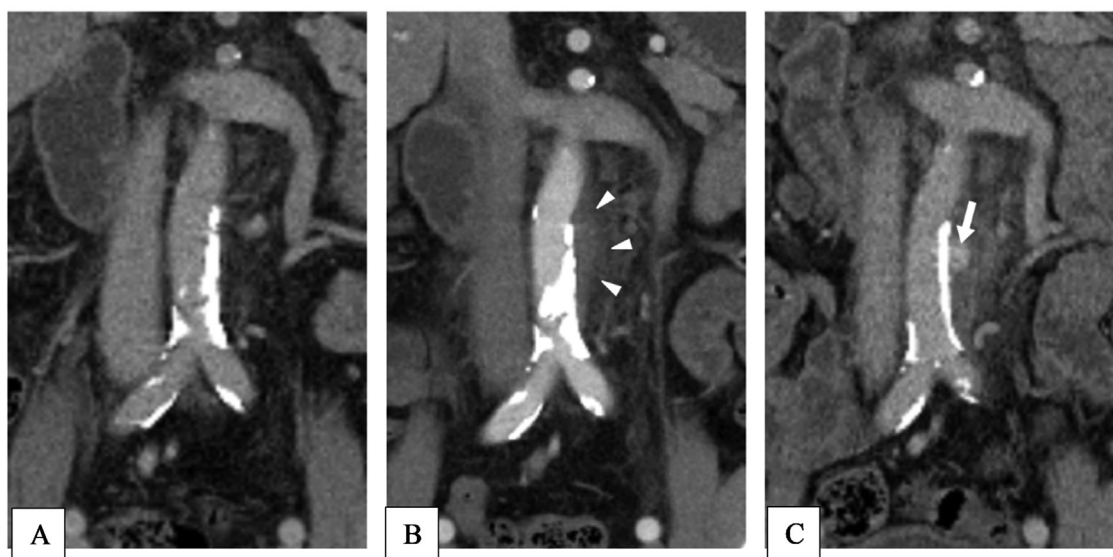


Fig. 1 – (A) The abdominal CT scan reveals the atherosclerotic change of the abdominal aorta and the common iliac artery. **(B)** (without contrast) and **(C)** (with contrast) show extravasation and rupture of the infected abdominal aneurysm at the third admission.

identify aeromonads at species level, a fragment of approximately 1100 bp of the *gyrB* gene from the isolate was amplified by PCR using primers *GyrB3F* and *GyrB14R* in a GeneAmp® PCR System 9700 thermal cycler (Applied biosystems, Foster city, CA, USA). Complete antibiotic therapy was administered for 14 days, and the patient was discharged. One month later, the abdominal pain relapsed. Additionally, severe backache was noted. Echocardiography revealed preserved left ventricular ejection fraction and no vegetation or valvular regurgitation. Again, the blood culture grew *A. sobria*. Hence, conservative treatment with parenteral ceftriaxone (2g) ivd qd was administered because the patient refused surgical intervention. The patient was free from clinical symptoms three days later, and parenteral ceftriaxone was prescribed for 21 days. Oral antibiotics with cefixime 500 mg bid were administered for two weeks after discharge.

However, the patient presented with similar symptoms three months later, including fever and backache. Abdominal CT revealed a mycotic aneurysm with contrast leakage at the level of previous aortitis (arrows, Figs. B and C). Based on the diagnosis of a ruptured mycotic aneurysm, emergent Endovascular Aneurysm Repair (EVAR) surgery was performed. The tissue culture of specimen of mycotic aneurysm also revealed *A. sobria*. Parenteral ceftriaxone (2g) ivd q12h was administered for eight weeks after surgery. After discharge from the hospital, oral ciprofloxacin 500 mg bid and rifampicin 600 mg qd were administered for another eight-week course. The patient was free from relapse even without the antibiotic treatment.

The genus *Aeromonas* is divided into two major groups: *A. hydrophila*, *A. caviae*, *A. veronii*, and *A. sobria*. *Aeromonas* septic syndrome is associated with immunocompromising conditions and contact with fresh water.¹⁻⁴ In a case series study, the one-month mortality rate with *Aeromonas* bacteremia in patients with liver cirrhosis was 55%,^{2,4,5} especially in those who presented with an initial shock status and a history of malignancy.^{3,4}

Infectious aortitis is a rare clinical condition that is most often associated with abdominal aortic atherosclerosis.¹⁻⁴ Most infectious aortic aneurysms are of bacterial origin, among which *Salmonella* infection is the most common, followed by *Staphylococcus aureus*.¹⁻⁵ To the best of our knowledge, there have been no documented cases of infectious aortitis or mycotic aneurysms caused by *A. sobria* infection.

Endovascular repair is a feasible therapeutic option for infectious aortitis because it can prevent the development of bleeding and rupture of aneurysms. In a case series of bacteremia caused by *Aeromonas*, most of the pathogens were not susceptible to ampicillin or first-generation cephalosporins; more than 90% of the clinical isolates were susceptible to third-generation cephalosporins, aminoglycosides, fluoroquinolones, and carbapenem.³⁻⁵ Establishing an accurate diagnosis of aortic infection before aneurysm formation and rupture is very difficult, but it is important in order to prevent devastating complications.³⁻⁵

In conclusion, although rare, *Aeromonas sobria* bacteremic aortitis may occur in immunocompromised patients with

liver cirrhosis. Incomplete antibiotic treatment may cause recurrent bacteremia and mycotic aneurysm rupture. EVAR and prolonged antibiotic treatment are required in complicated cases.

Ethics approval

Ethics approval was not required for this study and all authors consented to participate.

Consent for publication

The patient consent and agree to publication.

Availability of supporting data

The data from the electrical medical record of Taipei Municipal Wan Fang hospital.

Authors' contributions

Ke-Shiuan Ju: collect the data and write manuscript. Wei-Ta Chen: concept of the figure. Ying-Shih Su and Wen-Sen Lee: correct the manuscript and English editing. All authors agree to publish this manuscript.

Funding


No funding support to this study.

Declaration of Competing Interest

The authors declare no conflicts of interest.

REFERENCES

1. Callemeyn J, Daenens K, Derdelinckx I, Dymarkowski S, Fagard K. Conservative treatment of non-aneurysmal infectious aortitis: a case report and review of the literature. *Acta Clin Belg.* 2019;74:86–91.
2. Janda JM, Brenden R. Importance of *aeromonas sobria* in *aeromonas* bacteremia. *J Infect Dis.* 1987;155:589–91.
3. Tang HJ, Lai CC, Lin HL, Chao CM. Clinical manifestations of bacteremia caused by *aeromonas* species in Southern Taiwan. *PLoS One.* 2014;9:e91642.
4. Stano F, Brindicci G, Monno R, et al. *Aeromonas sobria* sepsis complicated by rhabdomyolysis in an HIV-positive patient: case report and evaluation of traits associated with bacterial virulence. *Int J Infect Dis.* 2008;13:e113–8.
5. Rosso F, Cedano JA, Parra-Larab LG, et al. Emerging carbapenem-resistant *Aeromonas* spp. infections in Cali, Colombia. *Braz J Infect Dis.* 2019;23:336–42.

Ke-Shiuan Ju ^a, Wei-Ta Chen ^a, Ying-Shih Su ^b, Wen-Sen Lee  ^{b,c,*}

^a Taipei Medical University, Wan Fang Hospital, Department of Internal Medicine, Division of Cardiovascular Medicine, Taipei, Taiwan

^b Taipei Medical University, Wan Fang Hospital, Department of Internal Medicine, Division of Infectious Disease, Taipei, Taiwan

^c Taipei Medical University, College of Medicine, School of Medicine, Department of Internal Medicine, Taipei, Taiwan

*Corresponding author.

E-mail address: 89425@w.tmu.edu.tw (W.-S. Lee).

Received 10 July 2022

Accepted 5 August 2022

Available online 27 August 2022

<https://doi.org/10.1016/j.bjid.2022.102699>

1413-8670/

© 2022 Sociedade Brasileira de Infectologia. Published by Elsevier España, S.L.U. This is an open access article under the CC BY-NC-ND license

(<http://creativecommons.org/licenses/by-nc-nd/4.0/>)