

# Bilateral Sudden Sensorineural Hearing Loss and Intralabyrinthine Hemorrhage in a Patient With COVID-19

\*†Alexander Chern, ‡Akinrinola O. Famuyide, ‡Gul Moonis, and \*§Anil K. Lalwani

\*Department of Otolaryngology—Head & Neck Surgery, New York-Presbyterian/Columbia University Irving Medical Center and Columbia University Vagelos College of Physicians and Surgeons, New York, New York; †Department of Otolaryngology—Head & Neck Surgery, New York-Presbyterian/Weill Cornell Medical Center, New York, New York; ‡Department of Radiology, Columbia University Irving Medical Center, New York, New York; and §Department of Mechanical Engineering, The Fu Foundation School of Engineering and Applied Science, Columbia University, New York, New York

**Objective:** To describe a case of bilateral sudden sensorineural hearing loss (SSNHL) and intralabyrinthine hemorrhage in a patient with COVID-19.

**Study Design:** Clinical capsule report.

**Setting:** Tertiary academic referral center.

**Patient:** An adult woman with bilateral SSNHL, aural fullness, and vertigo with documented SARS-CoV-2 infection (IgG serology testing).

**Interventions:** High-dose oral prednisone with taper, intratympanic dexamethasone.

**Main Outcome Measures:** Audiometric testing, MRI of the internal auditory canal with and without contrast.

**Results:** A patient presented with bilateral SSNHL, bilateral aural fullness, and vertigo. Serology testing performed several weeks after onset of symptoms was positive for IgG COVID-

19 antibodies. MRI showed bilateral intralabyrinthine hemorrhage (left worse than right) and no tumor. The patient was treated with two courses of high-dose oral prednisone with taper and a left intratympanic dexamethasone injection, resulting in near-resolution of vestibular symptoms, a fluctuating sensorineural hearing loss in the right ear, and a severe to profound mixed hearing loss in the left ear.

**Conclusions:** COVID-19 may have otologic manifestations including sudden SSNHL, aural fullness, vertigo, and intralabyrinthine hemorrhage. **Key Words:** Coronavirus disease 2019—Intralabyrinthine hemorrhage—Severe acute respiratory syndrome coronavirus 2—Sudden sensorineural hearing loss.

*Otol Neurotol* 42:e10–e14, 2021.

---

The SARS-CoV-2 virus has spread globally since first identified in December 2019 in Wuhan, China (1). Coronavirus disease 2019 (COVID-19), the disease caused by the virus, has been declared a pandemic; as of May 28, 2020, there have been over 5.7 million cases and over 350,000 reported deaths worldwide (2). Clinical sequelae vary from mild, self-limited upper respiratory infection symptoms to complications of acute respiratory

distress syndrome, pneumonia, multi-organ failure, and death (1). COVID-19 often initially presents with otolaryngological manifestations, including cough, sore throat, dyspnea, anosmia, and dysgeusia (3,4). However, there is a paucity of reports in the literature documenting otologic manifestations of the disease. One report demonstrated worse high frequency pure-tone thresholds and transient evoked otoacoustic emissions when comparing asymptomatic COVID-19 polymerase chain reaction (PCR)-positive subjects and non-infected subjects (5). Another limited case report presented an elderly patient with COVID-19 and accompanying sensorineural hearing loss (SNHL); however, no audiometric findings or imaging studies were provided (6).

We report a case of an 18-year-old patient who presented with symptoms of bilateral sudden sensorineural hearing loss (SSNHL), aural fullness, and vertigo with documented SARS-CoV-2 infection on immunoglobulin G (IgG) serology testing. Magnetic resonance imaging (MRI) demonstrated bilateral intralabyrinthine hemorrhage. To our knowledge, there have been no well-documented cases of SSNHL in patients with COVID-19 described in the literature.

---

Address correspondence and reprint requests to Anil K. Lalwani, M.D., Department of Otolaryngology—Head and Neck Surgery, Columbia University Vagelos College of Physicians and Surgeons, New York-Presbyterian/Columbia University Irving Medical Center, 180 Fort Washington Ave, HP8, New York, NY 10032; E-mail: ak12144@cumc.columbia.edu

Financial Material & Support: None.

Institutional Review Board Approval: AAAT0206: Neuroimaging Manifestations of COVID-19.

Conflict(s) of Interest:

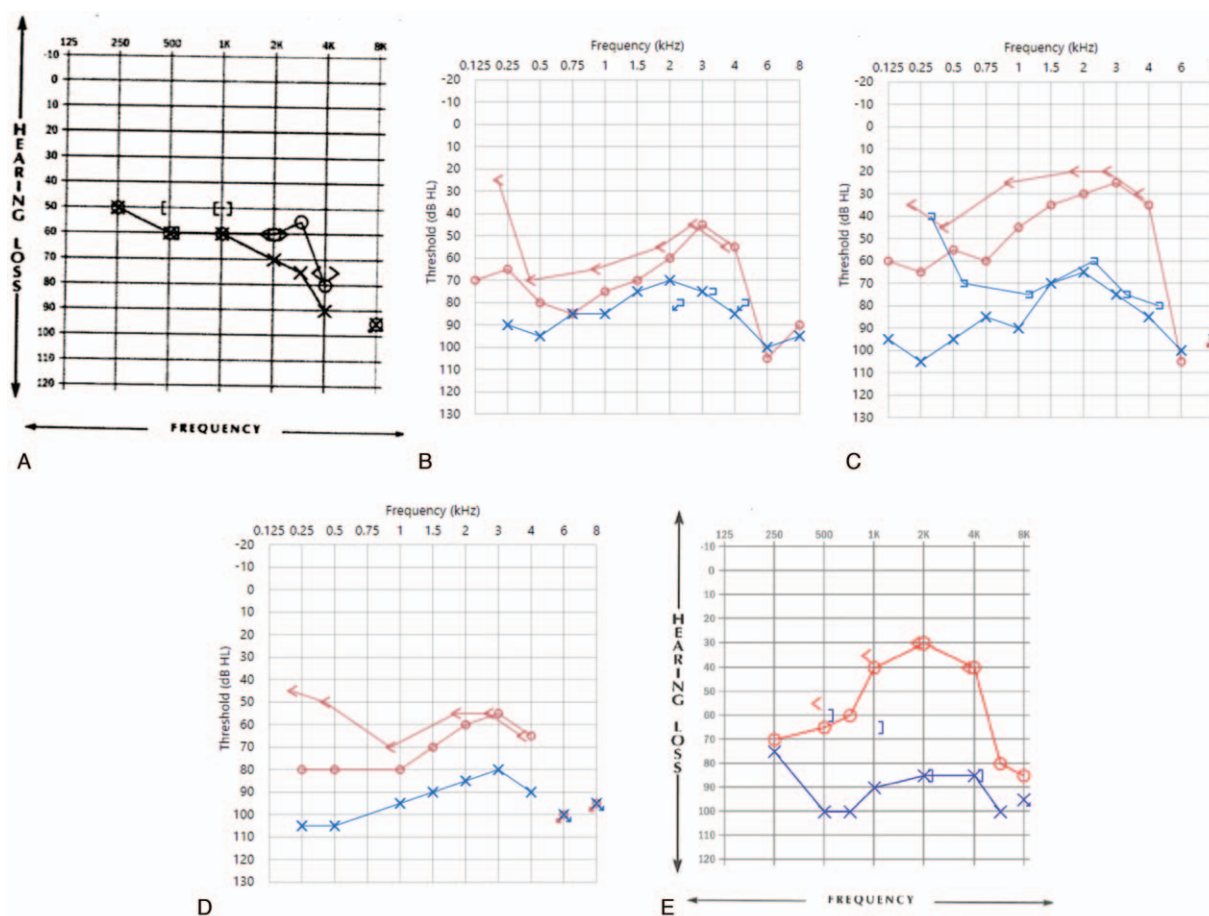
Alexander Chern, M.D.: none.

Akinrinola O. Famuyide, M.D.: none.

Gul Moonis, M.D.: none.

Anil K. Lalwani, M.D.: advisory board (Advanced Bionics, Med El, Spiral Therapeutics).

DOI: 10.1097/MAO.0000000000002860



**FIG. 1.** Interval audiograms. *A*, AD: moderate to severe SNHL, AS: moderate to profound SNHL. *B*, AD: severe to moderate to profound SNHL, AS: profound to severe to profound SNHL. *C*, AD: moderately severe to normal to profound SNHL, AS: profound to moderately severe to profound MHL. *D*, AD: severe to moderate to profound SNHL, AS: profound HL. *E*, AD: severe to mild to profound SNHL, AS: severe to profound MHL. AD indicates right ear; AS, left ear; HL, hearing loss; MHL, mixed hearing loss; SNHL, sensorineural hearing loss.

### CLINICAL CAPSULE

An 18-year-old woman presented to the otology clinic with a 7-week history of bilateral SSNHL, intermittent bilateral aural fullness, and vertigo with associated nausea and vomiting. She also noted new-onset loss of taste and olfaction. Her father tested positive for COVID-19 antibodies. Otomicroscopic examination was normal. Initial audiometric testing performed at an outside institution 1 week previous showed moderate to severe SNHL, pure-tone average (PTA) of 60 dB in the right ear and moderate to profound SNHL, PTA of 63 dB in the left ear. Word recognition scores (WRS) were 88% on the right and 80% on the left (Fig. 1A, Tables 1 and 2). Tympanometry was normal. Patient exhibited no other neurological symptoms such as weakness of the extremities, diplopia, headache, dysarthria, or cranial neuropathy. The patient denied previous history of hearing loss (HL), ear infections, ear surgery, tinnitus, vertigo, or exposure to ototoxic drugs. The patient also denied history of travel, barotrauma, or drug use. Her past

medical and surgical history was significant for tonsillectomy at 5 years. Family history was negative for sudden SNHL, vertigo, or Menière's disease. She was not taking any medications and had no drug allergies.

### INTERVENTION AND RESULTS

The patient underwent two courses of high-dose oral prednisone with taper and subsequent salvage left intratympanic (IT) steroid injection. The second course of oral steroids was given as salvage therapy at the family's request because they believed the first course initially helped the patient's hearing. Interval audiometric testing demonstrated a right-sided fluctuating SNHL and a progressive left-sided HL resulting in a severe to profound mixed hearing loss (MHL) (Fig. 1, Tables 1 and 2). She also noted near-resolution of her vestibular symptoms and significant improvement in her balance. Laboratory testing performed 3 weeks after her initial visit (approximately 10 weeks after symptom onset) showed an elevated white blood cell count, serum albumin,

**TABLE 1.** Right ear audiometric data

Corresponding Audiogram	Weeks After Symptom Onset	Hearing Thresholds	Pure-Tone Average (dB)	Word Recognition Score (%)	Tympanometry
1A	6	Moderate to severe SNHL	60	88	Normal
1B	8 (while on oral steroids)	Severe to moderate to profound SNHL	72	56	Normal
1C	9 (s/p oral steroids, L IT steroid injection)	Moderately severe to normal to profound SNHL	43	96	Normal
1D	10	Severe to moderate to profound SNHL	73	40	Normal
1E	12 (s/p 2nd course oral steroids)	Severe to mild to profound SNHL	45	96	Normal

dB indicates decibels; SNHL, sensorineural hearing loss.

erythrocyte sedimentation rate (ESR) and antinuclear antibodies (ANA) titer (1:80), consistent with an infection. Hemoglobin, hematocrit, D-dimer, platelet count, and prothrombin time were normal. Serology testing was positive for IgG COVID-19 antibodies; nucleic acid amplification (NAA) testing was negative for SARS-CoV-2.

MRI of the brain and internal auditory canal (IAC) was performed approximately 8 weeks after onset of otologic symptoms (see Fig. 2). Post-contrast three-dimensional fluid-attenuated inversion recovery (3D-FLAIR) MRI images demonstrated high signal in the left cochlea, vestibule, as well as lateral and superior semicircular canals. Subtle 3D-FLAIR signal abnormality was also noted in the basal turn of the right cochlea and right lateral semicircular canal. Pre-contrast T1-weighted images demonstrated hyperintensity in these regions, likely due to the presence of methemoglobin from blood. Lack of additional hyperintensity indicating enhancement of these lesions on post-contrast T1-weighted images made the presence of an inflammatory process or tumor less likely. There is no mass or abnormal enhancement in the internal auditory canals. Overall, these findings are consistent with left greater than right bilateral intralabyrinthine hemorrhage.

## DISCUSSION

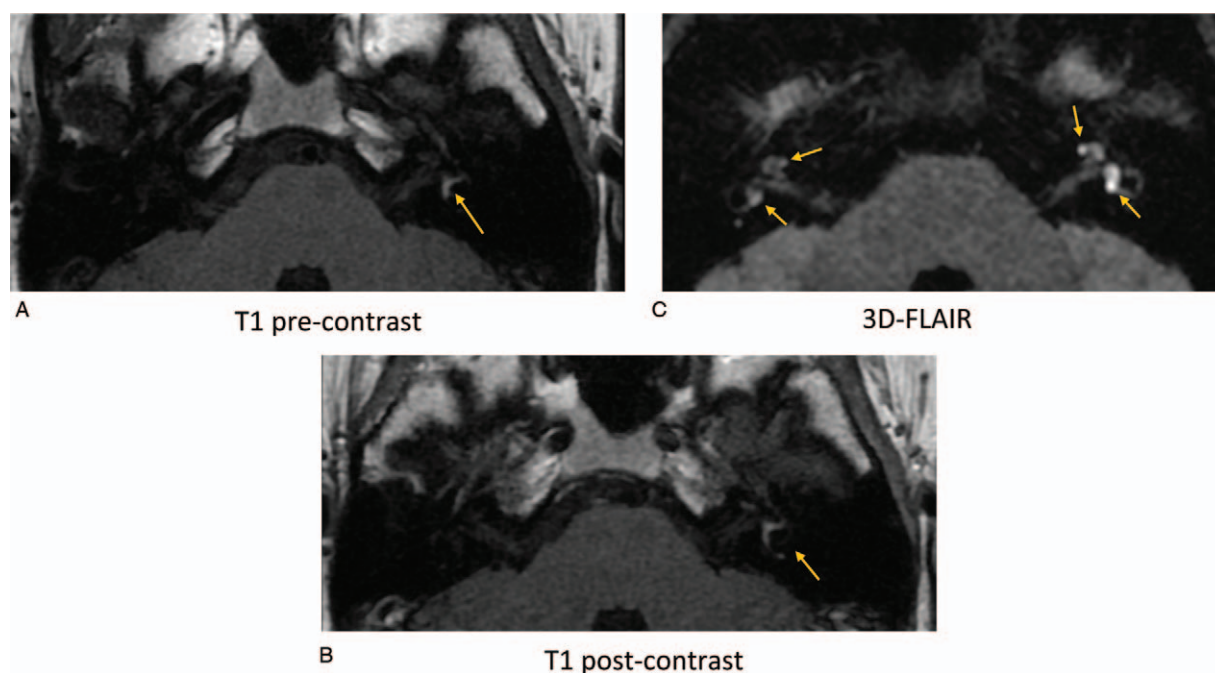
Bilateral SSNHL is relatively rare (7) and raises concern for a vascular, metabolic, autoimmune, infectious, neoplastic, toxic, traumatic, or inflammatory cause

(8). This case report highlights a unique case of bilateral SSNHL, aural fullness, and vertigo in a patient with a documented SARS-CoV-2 infection (positive IgG serology testing) and bilateral intralabyrinthine hemorrhage on MRI. The patient completed two courses of oral high-dose prednisone with taper and a left IT injection. Her right ear demonstrated a fluctuating SNHL with improvement after each course of steroids, suggesting possible steroid responsiveness. Her left ear demonstrated a progressive HL, resulting in a severe to profound MHL with a very poor word recognition score. The conductive overlay of the left MHL may be due to sequelae of the IT injection, including residual fluid, myringosclerosis, or tympanosclerosis. She also demonstrated near-resolution of her vestibular symptoms. Of note, her initial course of oral steroids was started approximately 6 weeks after symptoms began; this is beyond the 2-week window for initiating treatment for SSNHL recommended by the American Academy of Otolaryngology—Head and Neck Surgery clinical practice guidelines (8). The patient did not undergo an NAA test for an acute COVID-19 infection at the onset of her otologic symptoms because she was otherwise asymptomatic; serology testing performed during follow-up (approximately 10 weeks after symptom onset) was positive for COVID-19 IgG antibodies. Since IgG antibodies are typically detectable 2 to 3 weeks after symptom onset, this suggests that her infection likely coincided with the onset of her otologic symptoms several weeks before initial presentation to the otology clinic (9). Thus, the patient's otologic symptoms are likely due to COVID-19 infection and associated

**TABLE 2.** Left ear audiometric data

Corresponding Audiogram	Weeks After Symptom Onset	Hearing Thresholds	Pure-Tone Average (dB)	Word Recognition Score	Tympanometry
1A	6	Moderate to profound SNHL	63	80	Normal
1B	8 (while on oral steroids)	Profound to severe to profound SNHL	83	24	Normal
1C	9 (s/p oral steroids, L IT steroid injection)	Profound to moderately severe to profound MHL	83	24	Type B tympanogram, large ear canal volume
1D	10	Profound HL	95	8	Normal
1E	12 (s/p 2nd course oral steroids)	Severe to profound MHL	92	0	Type B tympanogram, normal ear canal volume

dB indicates decibels; HL, hearing loss; IT, intratympanic; MHL, mixed hearing loss; SNHL, sensorineural hearing loss.



**FIG. 2.** Axial MRI of the internal auditory canal. *A*, Axial pre-contrast T1-weighted image demonstrates increased signal intensity due to subacute blood in the labyrinth; *B*, Axial post-contrast T1-weighted image does not reveal enhancement to indicate an inflammatory process or tumor; *C*, Addition of 3D-FLAIR provides improved sensitivity for evaluation of inner ear structures, revealing a subtle signal abnormality suggestive of hemorrhagic lesions in the right cochlea and lateral semicircular canal that are less obvious on the T1 pre-contrast image. 3D-FLAIR indicates three-dimensional fluid-attenuated inversion recovery; MRI, magnetic resonance imaging.

bilateral intralabyrinthine hemorrhage. Other less likely causes on the differential diagnosis include Menière's disease, autoimmune inner ear disease, Cogan syndrome, and hyperviscosity syndromes (8).

There is a paucity of reports in the literature documenting otologic manifestations of COVID-19. Reports of HL in patients with COVID-19 are limited. One report demonstrated worse high frequency pure-tone thresholds and transient evoked otoacoustic emissions in asymptomatic COVID-19 PCR-positive subjects compared to non-infected subjects (5). Another presented an patient with COVID-19 and accompanying sensorineural hearing loss (SNHL); no audiometric findings or imaging studies were provided (6). Others' reports have been largely anecdotal within the otologic community. To our knowledge, there are no reports of COVID-associated vestibular symptomatology. Non-specific neurologic symptoms including dizziness are fairly common; one large case study described dizziness as a symptom in 16.8% of patients with COVID-19 (10). Though the mechanism by which COVID-19 may cause of dizziness is unclear, the disease does appear to be associated with individual cranial neuropathies resulting in anosmia (4) and ophthalmoparesis (11). It is possible that a COVID-19 infection could cause labyrinthitis or vestibular neuritis, which are commonly caused by viral infections.

There is strong evidence for viral infection as a cause of idiopathic SSNHL. Proposed mechanisms include direct viral invasion of the labyrinth or cochlear nerve, reactivation

of a latent virus within the spiral ganglion, and immune-mediated mechanism in a systemic viral infection (8,12). Though the fluctuating SNHL seen in the patient's right ear is atypical for classic SSNHL, it is characteristic in pathology such as Menière's disease. Since viral infection has been advocated as a potential cause of Menière's disease (13,14), this presentation still implicates the SARS-CoV-2 virus as a potential cause of her SSNHL.

Cases describing SSNHL in patients with intralabyrinthine hemorrhages have been reported in the literature, most notably in patients with an underlying coagulopathy (15–17). Normal blood supply to the cochlea is essential for maintaining ion and fluid balance to the inner ear; sensory hair cells are particularly vulnerable to ischemia. An insult to cochlear microcirculation (e.g., intralabyrinthine hemorrhage) can result in disruption of the endocochlear potential, ion transport, and endolymphatic fluid balance essential for normal hearing function (18). Of note, 3D-FLAIR MRI sequences suppress high water and CSF signal, and have been shown to be useful for early detection of inner ear pathology, such as intralabyrinthine hemorrhage (19). One study reported that very high signal intensity in the inner ear on pre-contrast 3D-FLAIR MRI is associated with a poor hearing prognosis (20). Though these findings may not apply to this specific case where post-contrast 3D-FLAIR was performed, 3D-FLAIR findings may still be useful for assessing hearing prognosis in patients with intrabyrinthine hemorrhage.

Pulmonary (21) and cerebral (22) microhemorrhages have been reported in patients with COVID-19, who

often have an associated coagulopathy. During the immune response to infection, overproduction of pro-inflammatory cytokines can deregulate coagulation and fibrinolysis pathways. Defective procoagulant–anticoagulant balance can predispose for formation of microthrombi and microhemorrhage; this is seen in coagulopathies such as disseminated intravascular coagulation (DIC), where consumption of platelets and coagulation proteins from clot formation can cause bleeding (23). Indeed, evidence suggests the coagulopathy associated with COVID-19 is a combination of low-grade DIC and pulmonary thrombotic microangiopathy (24). Though the patient demonstrated normal D-dimer, platelet count, and prothrombin time (coagulation markers which can be abnormal in critically ill patients with COVID-19), testing was conducted 10 weeks after onset of otologic symptoms (24). Moreover, the patient was otherwise largely asymptomatic. Other viruses (i.e., those that cause viral hemorrhagic fever, including Ebola, dengue, and yellow fever) are also characterized by hemorrhagic phenomena due to a variety of mechanisms, including liver injury, altered vascular permeability, and DIC (25).

### CONCLUSION

Though there are few anecdotal and extremely limited reports of SSNHL during the COVID-19 pandemic (5,6), no studies have documented a strong connection. This clinical capsule reports a case of bilateral SSNHL, aural fullness, and vertigo in a patient with bilateral intralabyrinthine hemorrhage and documented SARS-CoV-2 infection on IgG serology testing. The otologic symptoms observed in this patient can likely be attributed to intralabyrinthine hemorrhage from COVID-19-associated coagulopathy and/or direct viral invasion of the labyrinth or cochlear nerve.

### REFERENCES

- Zhou F, Yu T, Du R, et al. Clinical course and risk factors for mortality of adult inpatients with COVID-19 in Wuhan, China: a retrospective cohort study. *Lancet* 2020;395:1054–62.
- COVID-19 Dashboard by the Center for Systems Science and Engineering (CSSE) at Johns Hopkins University (JHU); 2020. Available at: <https://coronavirus.jhu.edu/map.html>. Accessed May 28, 2020.
- Krajewska J, Krajewski W, Zub K, Zatoński T. COVID-19 in otolaryngologist practice: a review of current knowledge. *Eur Arch Otorhinolaryngol* 2020;277:1885–97.
- Vaira LA, Salzano G, Deiana G, De Riu G. Anosmia and Ageusia: common findings in COVID-19 patients. *Laryngoscope* 2020;130:1787.
- Mustafa MWM. Audiological profile of asymptomatic Covid-19 PCR-positive cases. *Am J Otolaryngol* 2020;41:102483.
- Sriwijitalai W, Wiwanitkit V. Hearing loss and COVID-19: a note. *Am J Otolaryngol* 2020;41:102473.
- Byl FM. Sudden hearing loss: eight years' experience and suggested prognostic table. *Laryngoscope* 1984;94 (5 pt 1):647–61.
- Chandrasekhar SS, Tsai Do BS, Schwartz SR, et al. Clinical practice guideline: sudden hearing loss (Update). *Otolaryngol Head Neck Surg* 2019;161:S1–45.
- CDC. Interim Guidelines for COVID-19 Antibody Testing in Clinical and Public Health Settings; 2020. Available at: <https://www.cdc.gov/coronavirus/2019-ncov/lab/resources/antibody-tests-guidelines.html>. Accessed May 28, 2020.
- Mao L, Jin H, Wang M, et al. Neurologic Manifestations of Hospitalized Patients with Coronavirus Disease 2019 in Wuhan, China. *JAMA Neurol* 2020;77:1–9.
- Dinkin M, Gao V, Kahan J, et al. COVID-19 presenting with ophthalmoparesis from cranial nerve palsy. *Neurology* 2020. doi: 10.1212/wnl.0000000000009700.
- Merchant SN, Durand ML, Adams JC. Sudden deafness: is it viral? *Otorhinolaryngol Relat Spec* 2008;70:52–60. discussion 60–2.
- Williams LL, Lowery HW, Shannon BT. Evidence of persistent viral infection in Meniere's disease. *Arch Otolaryngol Neck Surg* 1987;113:397–400.
- Vrabec JT. Herpes simplex virus and Meniere's disease. *Laryngoscope* 2003;113:1431–8.
- Schuknecht HF, Igarashi M, Chasin WD. Inner Ear Hemorrhage in Leukemia. *Laryngoscope* 1965;75:662–8.
- Vakkalanka S, Ey E, Goldenberg RA. Inner ear hemorrhage and sudden sensorineural hearing loss. *Am J Otol* 2000;21:764–5.
- Hegarty JL, Patel S, Fischbein N, Jackler RK, Lalwani AK. The value of enhanced magnetic resonance imaging in the evaluation of endocochlear disease. *Laryngoscope* 2002;112:8–17.
- Shi X. Physiopathology of the cochlear microcirculation. *Hear Res* 2011;282:10–24.
- Chen XH, Zeng CJ, Fang ZM, Zhang R, Cheng JM, Lin C. The natural history of labyrinthine hemorrhage in patients with sudden sensorineural hearing loss. *Ear, Nose Throat J* 2019;98:E13–20.
- Yoshida T, Sugiura M, Naganawa S, Teranishi M, Nakata S, Nakashima T. Three-dimensional fluid-attenuated inversion recovery magnetic resonance imaging findings and prognosis in sudden sensorineural hearing loss. *Laryngoscope* 2008;118:1433–7.
- McGonagle D, O'Donnell JS, Sharif K, Emery P, Bridgewood C. Immune mechanisms of pulmonary intravascular coagulopathy in COVID-19 pneumonia. *Lancet Rheumatol* 2020. doi: 10.1016/S2665-9913(20)30121-1.
- Radmanesh A, Derman A, Lui YW, et al. COVID-19 – associated diffuse leukoencephalopathy and microhemorrhages. *Radiology* 2020;202040. doi: 10.1148/radiol.2020202040.
- Hunt BJ. Critical care medicine: bleeding and coagulopathies in critical care. *N Engl J Med* 2014;370:847–59.
- Levi M, Thachil J, Iba T, Levy JH. Coagulation abnormalities and thrombosis in patients with COVID-19. *Lancet Haematol* 2020;7:e438–40.
- Basler CF. Molecular pathogenesis of viral hemorrhagic fever. *Semin Immunopathol* 2017;39:551–61.