

Scientific Research Report

Developmental Abnormalities of Teeth in Children With Nephrotic Syndrome

Paula Piekoszewska-Ziętek^a, Dorota Olczak-Kowalczyk^{a*}, Małgorzata Pańczyk-Tomaszewska^b, Dariusz Gozdowski^c^a Department of Paediatric Dentistry, Medical University of Warsaw, Warsaw, Poland^b Paediatrics and Nephrology Cathedra and Clinic, Medical University of Warsaw, Warsaw, Poland^c Department of Experimental Statistics and Bioinformatics, Warsaw University of Life Science, Warsaw, Poland

ARTICLE INFO

Article history:

Received 6 September 2021

Received in revised form

25 November 2021

Accepted 29 November 2021

Available online 8 March 2022

Key words:

Nephrotic syndrome

Glucocorticoids

Developmental defects of enamel

Oral cavity

ABSTRACT

Introduction: Treatment with glucocorticoids in children with nephrotic syndrome can be the cause of developmental disorders of the masticatory organ and bone or teeth abnormalities. The aim was to assess the frequency and type of dental abnormalities and the correlation of their occurrence with a dosage of glucocorticoids and treatment time in children with idiopathic nephrotic syndrome.

Methods: The study group consisted of 31 patients aged 5 to 17 diagnosed with idiopathic steroid-sensitive nephrotic syndrome and 33 overall healthy children. The studies included clinical evaluation of dentition, radiologic diagnostics, and statistical analysis.

Results: In the study group, 77.4% of patients were diagnosed with abnormalities in dental development. Tooth number disorders, presence of persistent deciduous teeth and impacted teeth, abnormal crown or root shape, developmental defects of enamel, pulp stones, and bone structure disorders were identified. Statistical analysis showed significant differences in the average treatment time of glucocorticoids in patients without and with tooth developmental abnormalities.

Conclusions: Long-term use of glucocorticoids in children with nephrotic syndrome promotes the occurrence of developmental abnormalities of the teeth, calcification of the pulp, and disorders of bone tissue metabolism. For this reason, patients with steroid-sensitive nephrotic syndrome should be under the constant care of a dentist.

© 2021 The Authors. Published by Elsevier Inc. on behalf of FDI World Dental Federation.

This is an open access article under the CC BY-NC-ND license

[\(http://creativecommons.org/licenses/by-nc-nd/4.0/\)](http://creativecommons.org/licenses/by-nc-nd/4.0/)

Introduction

Nephrotic syndrome (NS) is a clinical condition that occurs with proteinuria of severity that exceeds the compensating possibilities of the organism (50 mg/kg/d), due to increased permeability of glomerules for plasma proteins. A characteristic of NS is its recurrence, sometimes even every few months.^{1,2} Children mostly experience idiopathic NS as a result of minimal change disease, treated by glucocorticoids.^{3,4} The symptoms of the disease occur before the age of 12; the average age of development is between 3 and 5 years. The frequency of NS cases for children younger than 16 years old is estimated between 2

and 7 new cases for every 100,000 children. The average frequency is 16 cases for every 100,000 people.⁵

Proteinuria that leads to hypoproteinaemia, loss of minerals with urine and glucocorticoid treatment, is burdened with the risk of calcium and vitamin D3 metabolism abnormalities. Children with NS often experience hypocalcaemia and a reduction in D3 vitamin metabolite levels. However, there can also be an increase in immunoreactive parathyroid hormone.^{6–8} These disorders can occur even when the glomerular filtration rate is normal.^{8,9} This increases the risk of metabolic bone diseases and can also disrupt the process of odontogenesis, which begins around the eighth weeks of foetal life. Protein deficiencies are likely to impede formation of the protein matrix of dental tissues, and disruptions of the calcium-phosphate balance can inhibit dental mineralisation.^{10,11} Mineralisation of deciduous teeth crowns begins in the fourth month of foetal life and lasts to about the twelfth month of a child's

* Corresponding author. Dorota Olczak-Kowalczyk, Binięckiego 6, 02-097 Warszawa, Poland.

E-mail address: dorota.olczak-kowalczyk@wum.edu.pl (D. Olczak-Kowalczyk).

<https://doi.org/10.1016/j.identj.2021.11.014>

0020-6539/© 2021 The Authors. Published by Elsevier Inc. on behalf of FDI World Dental Federation. This is an open access article under the CC BY-NC-ND license (<http://creativecommons.org/licenses/by-nc-nd/4.0/>)

life. Mineralisation of the permanent teeth crowns begins in the perinatal period and lasts until the seventh or even eighth year of a child's life (not counting the third molars).^{11,12} This means that disruptions of the calcium-phosphate, protein, and lipid metabolism that occur during this period can lead to various tooth and bone development abnormalities. The type of these abnormalities and their severity depend on the child's age and, consequently, the phase of masticatory organ development which pathological factor affected, its duration, and power of influence.

The use of glucocorticoids in children with NS can be the cause of not only predisposition to infections but also developmental disorders of the masticatory organ, bone and teeth abnormalities, and calcification of soft tissues.^{7,12-17} According to Bublitz et al.,¹⁴ children with NS are likely to have a high incidence of enamel hypoplasia and discolouration of permanent teeth. It has been observed that their presence was not associated with a child's age at NS onset but rather the total dose of prednisone received by the age of 7, when the amelogenesis process is usually completed. In turn, according to Oliver et al.¹² there is a correlation between the age of patients with severe kidney disease and estimated age at which enamel development anomalies may occur. Other tooth implications of long-term glucocorticoid treatment are changes in excessive forming and fibrosis of dentin¹⁷ and also obliteration of pulp chambers and occurrence of pulp stones.¹⁵

The aim of the study was to assess the frequency and type of dental abnormalities and the correlation of their occurrence with the dosage of glucocorticoids and treatment time in children diagnosed with idiopathic NS.

Materials and methods

A favourable opinion for this study was given by the Medical University of Warsaw's Bioethical Commission (number of ethics approval: KB/187/2011). The study complies with STROBE guidelines and Declaration of Helsinki principles.

Patients

The study group consisted of 31 patients aged 5 to 17 diagnosed with idiopathic steroid-sensitive NS, who were under the custody of the Department of Paediatric Dentistry at the Medical University of Warsaw and Paediatrics and Nephrology Cathedra and Clinic of the Medical University of Warsaw. The control group consisted of 33 overall healthy children aged 5 to 17. The group was recruited amongst patients attending regular dental checkups in the Clinic of the Paediatric Dentistry Department. The inclusion criteria included

written consent of the child or/and their parents/legal guardians and the absence of coexisting diseases. Patients who did not fully comply with all the criteria were excluded from participation.

Study methods

The studies included analysis of medical records, clinical evaluation of dentition, radiologic diagnostics, and statistical analysis of the obtained results. Clinical and radiologic findings were evaluated by 2 examiners after calibration (inter- and intra-examiner reliability was assessed using Cohen's kappa coefficient, and in all cases it was >0.8). Clinical assessments of the dentition were conducted under the terms of the World Health Organisation standard protocol.¹⁸ The dental examination was carried out in the conditions of a dentist's office, on a dentist's chair, in the light of its lamp, using a blunt-ended probe, a mirror, and a dental syringe. The number of teeth and their disruptions and the presence of developmental abnormalities of the teeth, related to their anatomical structure (size, shape)¹⁹ and to the enamel, were noted (in accordance with the modified developmental defects of enamel (DDE) Index: discolouration, opacities, and hypoplasia/quantitative loss of the enamel tissue).²⁰

Radiologic examinations were performed in which orthopantomogram (OPG) radiographs of patients were taken. The presence of tooth germs, impacted teeth, teeth with anatomical abnormalities, calcifications in chambers and root canals, and bone structure anomalies were assessed.

Statistical analysis

The results obtained were analysed statistically. The average comparisons between 2 groups were made using the t test, whilst the fractions (percentages) were compared using the chi-square test. Spearman correlation was calculated to assess the relationship between variable pairs. The significance level was set to .05. Analyses were performed using Statistica 13 Software.

Results

Sixty-four patients (53.1% of whom were boys) participated in the study. The average patient age (SD) was 11.6 (3.5) years. Patients in the study group were treated with glucocorticoids, and some were additionally treated with cyclosporine A. Patients in the control group did not take any medications permanently. The detailed characteristics of the study and control groups are given in [Table 1](#).

Table 1 – Characteristics of the patients involved in the study.

Study group, n = 31	Average age (SD)	11.3 (3.8) years
	Average age when disease was diagnosed (SD)	5.3 (4.2) years
	Average duration of disease (SD)	73.7 (60.4) months
	Medications taken (n/%)	Glucocorticoids 31/100
		Cyclosporine A 15/48.4
	Average dose of glucocorticoids (SD)	30.13 (22.41) mg
Control group, n = 33	Average glucocorticoid treatment time (SD)	63.2 (60.5) months
	Average age (SD)	12.0 (3.3) years

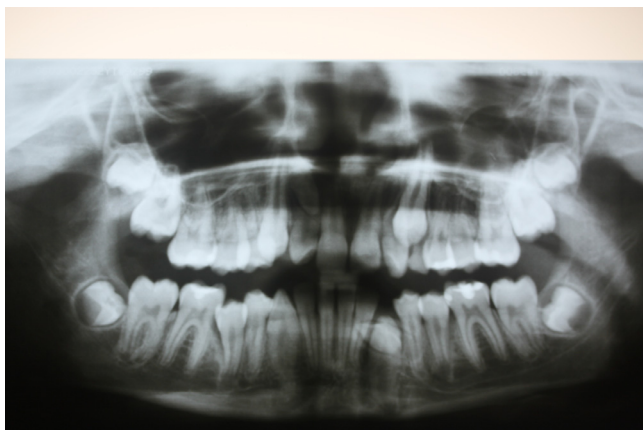


Fig. 1 – Panoramic x-ray: supernumerary teeth (in the region of 11-12 and 33). In the picture, there are also impacted teeth 23 and 33 and pulp stones in molars.

In the dental examination, in the study group, 24 patients (77.4%) were diagnosed with abnormalities in dental development, including 18 (58.1%) who had more than one malformation. These problems were found in the control group in 14 (42.4%; $P = .004$) and 3 (9.1%; $P < .001$) patients, respectively. The tooth number disorders, including hypodontia, hyperdontia (Figure 1), and presence of persistent deciduous teeth and impacted teeth (Figure 2), were identified in 9 patients (29%) in the study group and 2 patients (6.1%; $P = .015$) in the control group. In 12 patients (38.7%) in the study group and 4 (12.1%; $P = .014$) in the control group, abnormal crown or root shape (Figure 3) were identified. Developmental defects of enamel, evaluated by the DDE-Index, were reported in 16 patients (51.6%) in the study group and 8 patients (24.2%; $P = .024$) in the control group. A majority of these were associated with enamel hypomineralisation. Details are provided in Table 2.

Disorders regarding dental pulp mineralisation (pulp stones) occurred in 20 patients (31.3%), 17 of whom were in the study group and 3 of whom were in the control group ($P < .001$). More than one abnormality of this type involved 13

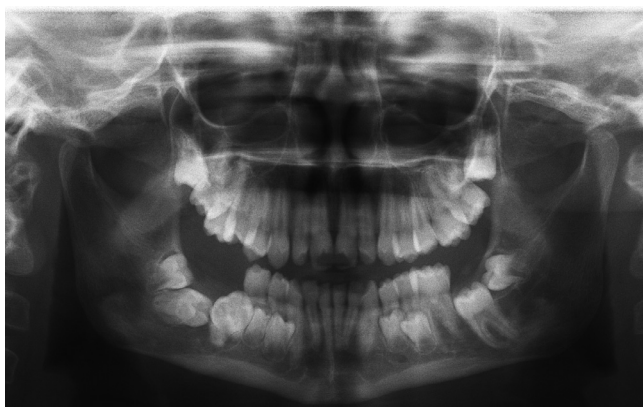

Fig. 2 – Panoramic x-ray: impacted teeth (37, 46, and 47). In the picture, there are also persistent deciduous teeth (74, 84, 75, and 85) and visible talon cusps of 13-23.

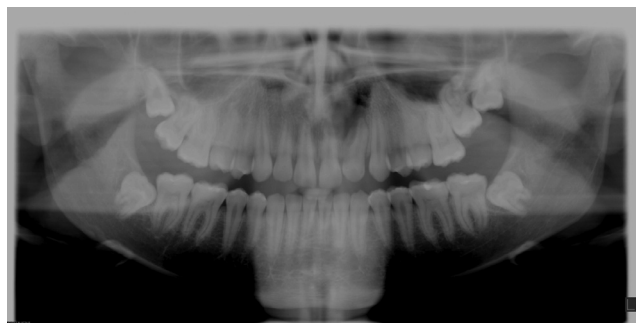

Fig. 3 – Panoramic x-ray: abnormal root shape (tooth 22). (The tooth has 2 roots.)

(41.9%) subjects in the study group and 1 (3%) in the control group. Bone structure abnormalities (localised changes of bone density) were observed in 8 (25.8%) patients in the study group, whilst the control group did not have any such disorders ($P = .002$).

Of the 15 patients receiving cyclosporine in addition to glucocorticoids, 11 had dental abnormalities. These were mainly bone structure abnormalities (4 out of 8 cases); pulp stones (6 out of 20 cases); hyperdontia (3 out of 5 cases); abnormal crown or root shape (3 cases); and retained teeth (2 out of 7 cases).

Table 2 – Tooth number and structure abnormalities and developmental defects of enamel reported in examined children.

Type of abnormality	Study group, n = 31 n/%	Control group, n = 33	P
Hypodontia	1/3.2	2/6.1	.592
Hyperdontia	5/16.1	0/0	.016
(mesiodens, other supernumerary teeth)			
Persistent deciduous teeth	2/6.5	0/0	.138
Impacted teeth	7/22.6	0/0	.004
More than 1 tooth number disorder	4/12.9	0/0	.033
Barrel-shaped crowns of the incisors	5/16.1	0/0	.016
Talon cusps	4/12.9	1/3	.141
Root shape abnormalities	2/6.5	0/0	.138
Dens invaginatus	1/3.2	0/0	.306
Enameloma	1/3.2	0/0	.306
Taurodontism	3/9.7	3/9.1	.936
More than 1 tooth structure disorder	3/9.7	0/0	.067
Opacities			

(hypomineralisation)14/45.26/18.2.020Discolouration1/3.21/3.964Hypoplasia3/9.71/3.272More than 1 developmental defect of enamel2/6.50/0.138

Developmental defects of enamel were found in incisors, premolars, and molars (including second molars) and, in some patients, even in the whole dentition. Tooth invagination was detected in a premolar. Root malformations concerned incisors. Enameloma was found in molars. Taurodontism concerned molars and premolars. These lesions are most probably connected with NS or glucocorticoid intake during the development of mineralised tissue of teeth. Mineralisation of first molars begins perinatally, and the crown is fully developed at around 4 years of age; mineralisation of incisors and canines begins in the first year of life, and crown formation lasts until 4 to 5 years of age in the case of incisors and 6 to 7 years of age in the case of canines; mineralisation of premolars and second molars starts between 1 and 3 years of age and lasts until 7 to 8 years of age. The development of the root lasts 3 to 4 years after eruption. The remaining findings, like pulp stones, were generally detected in molars, but they can develop even when the tooth is mature. Similarly, the occurrence of persistent teeth or changes in bone structure are independent.

Statistical analysis showed significant differences in average treatment time of glucocorticoids in patients with and without tooth developmental abnormalities. The longest average treatment time was in patients with more than one tooth developmental defect: 85 (63.93) months, compared to patients with no dental abnormalities at 29.57 (27.83) months ($P = .039$). Significant differences were also noted for pulp stone: an average of 85.11 (62.92) months of treatment compared to 36.48 (45.58) months of treatment in patients without pulp stones ($P = .022$). No significant differences were observed when considering the average dose of glucocorticoids.

Spearman correlation analysis carried out amongst all subjects revealed significant positive correlations between steroid-sensitive NS incidence and the number of tooth development defects found ($r = 0.460$; $P \leq .001$), impacted teeth ($r = 0.259$; $P = .05$), tooth structure abnormalities ($r = 0.373$; $P = .002$), pulp stones ($r = 0.488$; $P \leq .001$), and bone structure abnormalities ($r = 0.505$; $P \leq .001$). In the study group (patients with NS), these observations were confirmed with respect to the glucocorticoid treatment time in patients: number of tooth developmental defects ($r = 0.357$; $P = .049$), presence of impacted teeth ($r = 0.548$; $P = .001$), structural abnormalities ($r = 0.385$; $P = .032$), pulp stones presence ($r = 0.392$; $P = .029$), bone structure abnormalities ($r = 0.379$; $P = .035$), and more than 1 tooth development abnormality ($r = 0.439$; $P = .014$).

Discussion

One of the most basic classifications of NS is based on the clinical response to steroid therapy, differentiating it as steroid-sensitive and steroid-resistant. This study involved patients with idiopathic steroid-sensitive NS. The treatment is based on glucocorticoids, administered through specific protocols, depending on treatment response or recurrence.²¹ Glucocorticoids are strong medications with immunosuppressive and anti-inflammatory effects, prolonged use of which may lead to a number of adverse reactions. According to Adcock et al.,²² chronic use is the most important risk

factor for side effects; however, other important factors are the dosage, characteristics of the medicine specifically used, and individual variability. The most common side effects of glucocorticoids include tissue atrophy and delayed wound healing, adrenal suppression, osteoporosis and osteonecrosis, hypertension, diabetes, and increased risk of infection.^{22,23}

In NS, clinical implications are commonly observed in the oral cavity. Studies conducted by various authors report changes in the development of enamel, oral inflammation, mucosal lesions, reduced saliva flow, or xerostomia.^{24,25} Developmental defects of enamel are common in patients with chronic kidney diseases.²⁶ Nunn et al.²⁷ suggested that such changes could be related to poor calcium and phosphate metabolism in patients with kidney diseases and therefore poor enamel mineralisation, which is manifested by opacities. These type of changes were also observed in the study (more than 45% of patients in the study group). These results are similar to those obtained by authors in the research conducted previously by Publitz et al.,¹⁴ Oliver et al.,¹² and Subramaniam et al.²⁸ Kidney impairment at an early stage of human development may be crucial for developing enamel malformations. Changes in deciduous teeth indicate damage affecting the activity of ameloblasts that occurs prior to or shortly after birth. Calcium, phosphate, and vitamin D metabolism and absorption are disturbed, which, paired with proteinuria, may cause disturbances in the formation or maturation of the enamel.^{8,28}

The chronic effects of glucocorticoids on the tissues of the masticatory organ also cause changes in bones, such as the reduction of the alveolar process, reduction of the osteoid matrix and osteoblasts, and the transformation of bone tissue into fibrous tissue which may result in the loss of bone basis. Beeraka et al.¹⁶ reported significant oral bone density reduction in adult patients using steroids for an average of 10.58 ± 4.24 months at a daily dose of 7.04 ± 3.56 mg on average. Changes in bone structure, based on OPG images, were also observed in patients participating in the present study. Aceto et al.⁷ examined bone structure changes in children and adolescents with diagnosed steroid-sensitive NS. A long-term study showed that chronic high doses of glucocorticoids were associated with the degree of bone mineralisation, which was at the lower limit of the standard in most treated patients, whilst approximately 25% had a reduction in bone mineralisation below the standard (with long-term lasting treatment for at least several years). The authors emphasise the need to monitor the bones of patients undergoing chronic glucocorticoid treatment because of the increased risk of fractures, including those concerning facial bones.⁷

Long-term treatment with steroids may also lead to disturbances affecting tooth pulp, including a significant expansion of blood vessels, calcification of pulp, and reduction of pulp chambers due to the deposit of a bone-like tissue by poorly organised osteoblasts. Also, secondary dentin deposition and tissue fibrosis are increased.^{15,17} In the study presented above, we have noted changes of this type in the form of pulp stones that occurred in nearly 55% of patients in the study group. These observations are confirmed by a study conducted by Ashwini et al.,¹⁵ which revealed partial or total

obliteration of the pulp chambers during long-term (2-3 years) steroid therapy in 90% of patients.

The present study also revealed disturbances in the number or structure of teeth, including significantly frequent incidences of hyperdontia, presence of impacted teeth, and abnormal crown shapes. However, changes of this type were not reported in the available literature. It is interesting to find that hyperdontia was discovered in patients with NS. The exact cause of hyperdontia is unknown. Several theories have been suggested for its occurrence, such as the phylogenetic theory, the dichotomy theory, and occurrence due to hyperactive dental lamina and due to a combination of genetic and environmental factors.²⁹ In NS, we are dealing with proteinuria, in which patients lose proteins from their bodies.² For this reason, it would seem that they would be more likely to experience hypodontia, as proteins are the main elements of the tooth matrix. Hyperdontia in our patients seems not to be connected with the primary disease and is more likely a random anomaly. On the other hand, NS is also connected to infectious complications. Perhaps the patients had severe infectious disease with a fever, which speeds up metabolism and may lead to over-reactivity of dental lamina. However, this is only a hypothesis, the truthfulness of which should be confirmed by further investigations.

In summary, based on our own observations and reference literature, the dental implications of glucocorticoid treatment in patients with steroid-sensitive NS are usually due to long-term use rather than to the dosage used.^{16,22} The study confirms that long-term use of glucocorticoids is associated with numerous dental complications, which patients are usually not aware of, as the doctors involved in the treatment primarily inform of common side effects such as obesity, hypertension, and diabetes. Dental implications are no less important, as they can cause a variety of complications or difficulties in dental treatment in such patients. It would be a good idea to prepare a guide for patients with NS who have dental abnormalities to make them more aware of the issue. Opacities caused by hypomineralisation often create an aesthetic problem. There is some available advice, depending on the stage of advancement, which for mild lesions includes the application of fluoride, CPP-ACP (casein phosphopeptide–amorphous calcium phosphate complex), or resin infiltration (for example, the ICON system). For more advanced lesions, the treatment may include abrasion and conservative treatment or prosthodontic treatment (veneers or crowns). The issue of impacted teeth is also common, so a radiologic examination should be performed when a tooth does not appear in the oral cavity after the estimated time of eruption. Dentists should also emphasise the role of prophylaxis to eliminate caries and avoid endodontic treatment (which can be difficult when pulp stones are present). However, knowing these implications, dentists should remember that treatment of NS is more important and their role is to help patients when dental complications occur, rather than interfere with glucocorticoid therapy to avoid such difficulties.

Conflict of interest

None disclosed.

REFERENCES

- Larkins NG, Liu ID, Willis NS, et al. Non-corticosteroid immunosuppressive medications for steroid-sensitive nephrotic syndrome in children. *Cochrane Database Syst Rev* 2020;4: CD002290. doi: 10.1002/14651858.CD002290.pub5.
- Orth SR, Ritz E. The nephrotic syndrome. *N Engl J Med* 1998;338:1202–11.
- Hahn D, Hodson EM, Willis NS, et al. Corticosteroid therapy for nephrotic syndrome in children. *Cochrane Database Syst Rev* 2015;3:CD001533. doi: 10.1002/14651858.CD001533.pub5.
- Lombel RM, Gipson DS, Hodson EM. Treatment of steroid-sensitive nephrotic syndrome: new guidelines from KDIGO. *Pediatr Nephrol* 2013;28:415–26.
- Eddy AA, Symons JM. Nephrotic syndrome in childhood. *Lancet* 2003;362:629–39.
- Białynicki-Birula R, Sidorowicz-Białynicka A. Profilaktyka osteoporozy posteroideowej w praktyce lekarza dermatologa. Zalecenia diagnostyczne i terapeutyczne. *Dermatologia Kliniczna* 2008;10(4):231–3.
- Aceto G, D'Addato O, Messina G, et al. Bone health in children and adolescents with steroid-sensitive nephrotic syndrome assessed by DXA and QUS. *Pediatr Nephrol* 2014;29(11):2147–55.
- Esmaeili M, Azarfar A, Hoseinalizadeh S. Calcium and vitamin D metabolism in pediatric nephrotic syndrome; an update on the existing literature. *Int J Pediatr* 2015;3(suppl 1):103–9.
- Pańczyk-Tomaszewska M, Adamczuk D, Kisiel A, et al. Markers of bone metabolism in children with nephrotic syndrome treated with corticosteroids. *Adv Exp Med Biol* 2015;840:21–8.
- McKee MD, Hoac B, Addison WN, et al. Extracellular matrix mineralization in periodontal tissues: noncollagenous matrix proteins, enzymes, and relationship to hypophosphatasia and X-linked hypophosphatemia. *Periodontol* 2000 2013;63(1):102–22.
- Caruso S, Bernardi S, Pasini M, et al. The process of mineralisation in the development of human tooth. *Eur J Paediatr Dent* 2016;17(4):322–6.
- Oliver WJ, Owings CL, Brown WE, et al. Hypoplastic enamel associated with the nephrotic syndrome. *Pediatrics* 1963;32:399.
- Yamaguti PM, Arana-Chavez VE, Acevedo AC. Changes in amelogenesis in the rat incisor following short-term hypocalcaemia. *Arch Oral Biol* 2005;50(2):185–8.
- Bublitz A, Machat E, Scharer K, et al. Changes in dental development in paediatric patients with chronic kidney disease. *Proc EDTA* 1981;18:517–23.
- Ashwini P, Meena N, Santosh R, et al. Effect of long-term corticosteroids on dental pulp. *World J Dent* 2010;1(1):17–20.
- Beeraka SS, Natarajan K, Patil R, et al. Clinical and radiological assessment of effects of long-term corticosteroid therapy on oral health. *Dent Res J (Isfahan)* 2013;10(5):666–73.
- Yoshiho C, Tateo D, Makoto M, et al. Dental pulp changes observed in patient on long-term corticosteroids. *J Hard Tissue Biol* 2007;16(1):31–5.
- WHO. *Oral Health Surveys—basic methods* (5th ed.). 2013;47:31–3.
- Neville DW, Damm DD, Allen CM, et al. *Oral and maxillofacial pathology*. 2nd ed. Philadelphia, PA: Elsevier; 2005. p. 49–89.
- Clarkson J, O'Mullane D. A modified DDE Index for use in epidemiological studies of enamel defects. *J Dent Res* 1989;68:445.
- Noone DG, Iijima K, Parekh R. Idiopathic nephrotic syndrome in children [published correction appears in *Lancet*. 2018 Jul 28;392(10144):282]. *Lancet* 2018;392(10141):61–74.

22. Adcock IM, Mumby S. Glucocorticoids. *Handb Exp Pharmacol* 2017;237:171–96.
23. Schacke H, Docke WD, Asadullah K. Mechanisms involved in the side effects of glucocorticoids. *Pharmacol Ther* 2002;96(1):23–43.
24. Babu NSV, Jana S. Assessment of oral health status in children suffering from nephrotic syndrome. *Int J Sci Stud* 2014;2(2):19–23.
25. Gupta M, Gupta M, Abhishek. Oral conditions in renal disorders and treatment considerations – a review for pediatric dentist. *Saudi Dent J* 2015;27(3):113–9.
26. Koch MJ, Bühner R, Pioch T, et al. Enamel hypoplasia of primary teeth in chronic renal failure. *Pediatr Nephrol* 1999;13(1):68–72.
27. Nunn JH, Sharp J, Lambert HJ, et al. Oral health in children with renal disease. *Pediatr Nephrol* 2000;14(10–11):997–1001.
28. Subramaniam P, Gupta M, Mehta A. Oral health status in children with renal disorders. *J Clin Pediatr Dent* 2012;37(1):89–93.
29. Parolia A, Kundabala M, Dahal M, et al. Management of supernumerary teeth. *J Conserv Dent* 2011;14(3):221–4.