



Case report

Insidious development of pulmonary embolism in asymptomatic patients with COVID-19: Two rare case-reports



Abdulrahman Alharthy^a, Abdullah Balhamar^a, Fahad Faqihi^a, Rayan Alshaya^a, AlFateh Noor^a, Feisal Alaklobi^a, Ziad A. Memish^b, Dimitrios Karakitsos^{a,*}

^a Critical Care Department, King Saud Medical City, Riyadh, Saudi Arabia

^b Research and Innovation Centre, King Saud Medical City, Riyadh, Saudi Arabia

ARTICLE INFO

Keywords:

COVID-19
Asymptomatic disease
Thromboinflammation
Pulmonary embolism
Deep vein thrombosis
Anticoagulation therapy

ABSTRACT

Scarce data exist regarding the clinical sequelae of COVID-19 and/or the prevalence of thromboembolic disease in asymptomatic patients. Surely, there is increased prevalence of thromboembolic disease and pulmonary embolism (PE) in critically ill patients with COVID-19; hence the administration of even enhanced thromboprophylaxis was suggested. However, the administration of regular thromboprophylaxis in asymptomatic outpatients is an entirely different matter. Herein, we present the clinical story of insidious PE development in two asymptomatic COVID-19 female patients. Issues regarding the pathogenesis of thromboembolism in COVID-19 and the clinical management are equally discussed.

1. Introduction

The novel coronavirus SARS-CoV-2 disease (COVID-19) pandemic emerged in China and spread worldwide. The dominant transmission mode of COVID-19 is human-to-human transmission with most cases being asymptomatic [1]. However, life-threatening disease can occur, in a few patients, which is usually characterized by acute respiratory distress syndrome, sepsis, multi-system organ failure, neurological manifestations, and thromboembolic disease [1–4]. An increased prevalence of pulmonary embolism (PE) and thromboembolic phenomena were described in critically ill mechanically ventilated patients with COVID-19 [5,6]. The development of a hypercoagulable state with associated vascular dysfunction and cytokine storm, promoting thus thromboinflammation was suggested [7,8]. This exaggerated inflammatory immune response and thrombotic microangiopathy resulting in multi-organ dysfunction and death was confirmed by post-mortem studies [9]. PE was mainly described in COVID-19 patients with concomitant lung parenchymal injury, which was characterized, in the majority of cases, by peripheral ground-glass opacities in chest computed tomography (CT) studies [10–14]. Asymptomatic carriers of COVID-19 were discovered among close contacts of confirmed cases [15]; however, the epidemiological significance of asymptomatic

infections remains obscure. Also, scarce data exist regarding the clinical sequelae of COVID-19 and/or the prevalence of thromboembolic disease in asymptomatic patients [16,17]. Herein, we present two rare cases of insidious PE development in two asymptomatic COVID-19 female carriers.

2. Case presentation

2.1. Case 1

A previously healthy 50 year old female was tested for COVID-19 by Real-Time-Polymerase-Chain-Reaction (RT-PCR) assays [18–20], performed on nasopharyngeal swabs, using QuantiNova Probe RT-PCR kit (Qiagen) in a Light-Cycler 480 real-time PCR system (Roche, Basel, Switzerland) as per Saudi Ministry of Health [21], and World Health Organization (WHO) guidelines [22]. The patient was tested due to close unprotected contact with her husband who recovered from COVID-19. She was asymptomatic but was evaluated in the emergency department and underwent chest CT scan to exclude any pulmonary involvement nevertheless [23–25]. The patient tested positive for COVID-19, while her husband's test was negative at that time (baseline). She was entirely asymptomatic; while her chest CT scan and laboratory findings were normal. We discharged her to home isolation and prescribed

* Corresponding author. Critical Care Dept., King Saud Medical City, PO Box 331905, 11373, Shemaisi, Riyadh, Saudi Arabia.

E-mail addresses: a_almshal@hotmail.com (A. Alharthy), abdullahbalahmar@gmail.com (A. Balhamar), dr.faqihi677@gmail.com (F. Faqihi), rasa_944@hotmail.com (R. Alshaya), alf.1000@yahoo.com (A. Noor), falaklobi@ksmc.med.sa (F. Alaklobi), zmemish@yahoo.com (Z.A. Memish), karakitsosdimitrios@gmail.com (D. Karakitsos).

<https://doi.org/10.1016/j.rmcr.2020.101186>

Received 24 July 2020; Accepted 6 August 2020

Available online 11 August 2020

2213-0071/© 2020 The Author(s).

Published by Elsevier Ltd.

This is an open access article under the CC BY-NC-ND license

(<http://creativecommons.org/licenses/by-nc-nd/4.0/>).

Abbreviations

SARS-CoV-2 disease	COVID-19
ICU	intensive care unit
RT-PCR	Real-Time-Polymerase-Chain-Reaction
CT	computed tomography
HFNC	high flow nasal cannula
DVT	deep vein thrombosis
PE	pulmonary embolism
WHO	World Health Organization
FiO ₂	Fraction of inspired oxygen
SpO ₂	saturation of peripheral oxygen
RAAS	renin-angiotensin-aldosterone system

multivitamins including vitamin C and zinc. However, after twenty days, the female patient was readmitted to the emergency department due to recent onset shortness of breath, chest pain and leg swelling (Fig. 1). Physical examination was normal apart from the swelling of the right lower limb. The saturation of peripheral oxygen (SpO₂) was 80% (room air). She was connected to a high flow nasal cannula [(HFNC) with a flow of 60 L/min, and fraction of inspired oxygen (FiO₂) of 40%] maintaining SpO₂ of 94%. Repeat RT-PCR test for COVID-19 was positive. Deep vein thrombosis (DVT) was clinically suspected and thereafter confirmed by Duplex ultrasound examination. The latter revealed acute thrombosis of the right external iliac and common femoral veins (Fig. 1). Echocardiography and cardiac enzymes were normal. Contrast chest CT scan revealed pulmonary embolism but no parenchymal lung involvement (Fig. 1). She was admitted to a negative pressure isolation room in the intensive care unit (ICU) for close observation. Baseline laboratory findings were normal apart from lymphocytopenia ($0.55 \times 10^9/L$, normal: $1.1-3.2 \times 10^9/L$), and increased C-reactive protein (81 mg/liter, normal: 0-7 mg/liter), and D-dimers (7.5 mcg/ml, normal: 0 to 0.5 mcg/ml). We administered empiric treatment with ribavirin/interferon beta-1b, and therapeutic anticoagulation adjusted to her body weight as per hospital protocol [21] (Padua prediction score = 4). A full diagnostic work-up for other viral and systemic disorders including thrombophilia screening was negative. On day-22 post-ICU admission, RT-PCR test for COVID-19 and microbiology were negative. She was discharged to home isolation. Oral rivaroxaban was prescribed for three months, and the patient is closely followed-up by her cardiologist [26].

2.2. Case 2

A previously healthy 56 year old female was tested for COVID-19 by Real-Time-Polymerase-Chain-Reaction (RT-PCR) assays, performed on nasopharyngeal swabs, as described in aforementioned paragraphs [18-22]. The patient was admitted to the emergency department as she was worried of SARS-CoV-2 infection after close unprotected contact with her daughter who recovered from COVID-19. She tested positive for COVID-19 although she was entirely asymptomatic (baseline). Chest CT scan and laboratory examinations were normal. The patient was discharged to home isolation. After thirty five days, the patient was readmitted to the emergency department due to shortness of breath, chest pain, and low-grade fever (Fig. 2). Physical examination was normal. The saturation of peripheral oxygen (SpO₂) was 79% (room air). She was connected to HFNC with a flow of 60 L/min, and fraction of inspired oxygen (FiO₂) of 40%] maintaining SpO₂ of 92%. Repeat RT-PCR test for COVID-19 was positive. We suspected PE, which was confirmed by contrast chest CT, but no lung parenchymal involvement was documented (Fig. 2). Also, DVT was excluded by Duplex ultrasound examination. Echocardiography and cardiac enzymes were normal. Although the patient was hemodynamically stable, she was admitted to a negative pressure ICU isolation room for observation. Baseline laboratory findings were normal apart from lymphocytopenia ($0.62 \times 10^9/L$, normal: $1.1-3.2 \times 10^9/L$), and increased C-reactive protein (101 mg/liter, normal: 0-7 mg/liter), and D-dimers (7.1 mcg/ml, normal: 0 to 0.5 mcg/ml). We administered empiric treatment with ribavirin/interferon beta-1b, and therapeutic anticoagulation adjusted to her body weight as per hospital protocol (Padua prediction score = 4). A full diagnostic work-up for other viral, microbial and systemic disorders including thrombophilia screening was negative. On day-19 post-ICU admission, RT-PCR test for COVID-19 and microbiology were negative. She was discharged to home isolation, and oral rivaroxaban was prescribed for three months. The patient is followed-up by her family physician.

3. Discussion

The clinical sequelae of COVID-19 and/or the prevalence of thromboembolic disease in asymptomatic patients remain partially studied. PE and thromboembolic disease were linked to critically ill patients with COVID-19. These pathologies can have a detrimental effect on morbidity and mortality [27]. The pathology of COVID19 is not yet elucidated, but it is acknowledged there is a thromboinflammatory basis, which is characterized by lymphocytopenia, and increased levels of D-dimer,

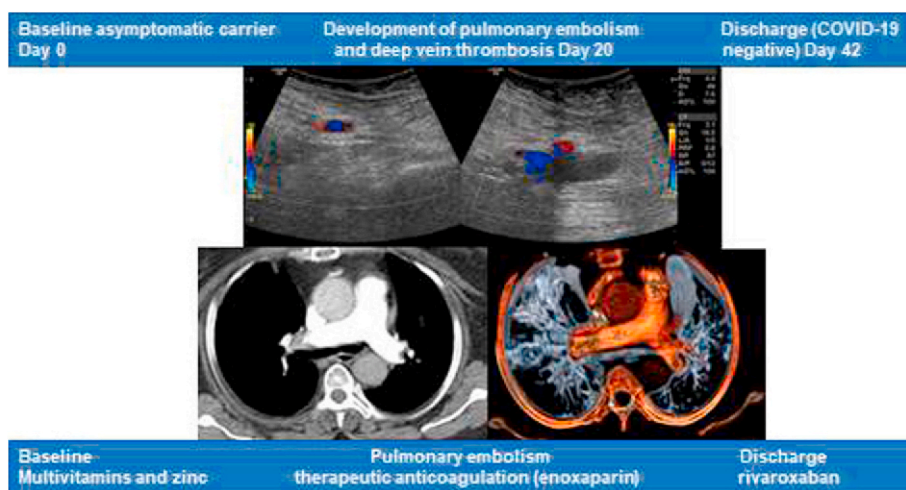


Fig. 1. Clinical course of our asymptomatic COVID-19 patient (case 1) from baseline to the development of deep vein thrombosis of the right external iliac and femoral veins as depicted by duplex ultrasound; and pulmonary embolism as depicted by contrast chest computed tomography, which revealed filling defects of segmental and lower lobular branches of the right pulmonary artery. Finally the patient was discharged on rivaroxaban therapy.

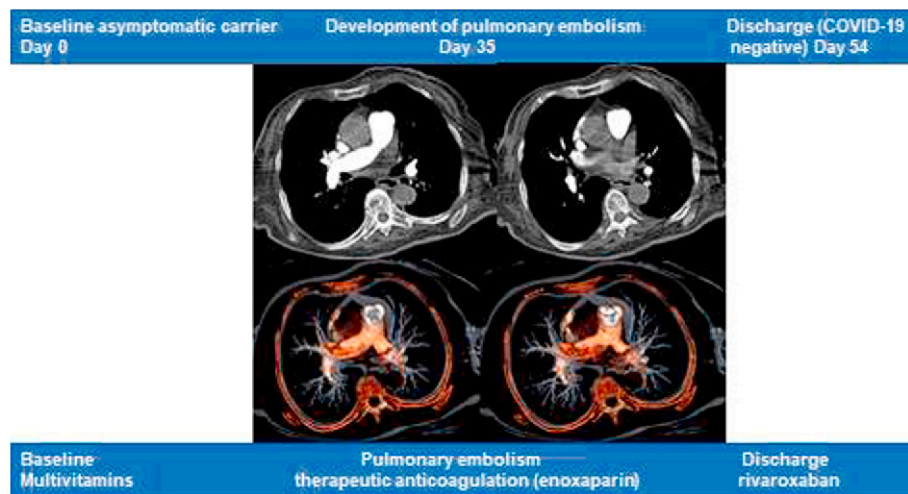


Fig. 2. Clinical course of our asymptomatic COVID-19 patient (case 2) from baseline to the development of pulmonary embolism as depicted by contrast chest computed tomography, which revealed multiple filling defects of segmental and lower lobular branches of the right pulmonary artery. Finally the patient was discharged on rivaroxaban therapy.

CRP, other inflammatory mediators, and cytokines (i.e., interleukin-6) [7–9,28–31]. We present two asymptomatic female COVID-19 carriers, which were initially infected with SARS-CoV-2 due to unprotected contact with patients who were living with them. The first case presented with acute DVT and PE without any lung parenchymal involvement, twenty days after she initially tested positive for COVID-19. We are uncertain whether the persistent COVID-19 status might be attributed to a putative reinfection or, most probably, to recurrently positive RT-PCR results. DVT with accompanying PE in COVID-19 was described in various studies; however patients were symptomatic and/or critically ill [6,27,32]. Our second case presented with the same clinical features, but with “isolated” PE without any DVT. The aforementioned concerns apply to this case as well regarding the COVID-19 status from baseline to the presentation of PE.

Our patients were both asymptomatic and had no predisposing factors for thromboembolic disease. They presented with lymphocytopenia, and increased levels of D-dimer, while their Padua prediction score was 4. Recently, the administration of enhanced anticoagulation in patients with severe COVID-19, and Padua prediction score ≥ 4 or D-dimer > 3.0 $\mu\text{g}/\text{mL}$ was suggested [33]. Although prophylactic anticoagulation should be applied on all hospitalized COVID-19 patients [33,34], we are uncertain whether this could be also considered for outpatients with mild disease or no symptoms. SARS-CoV-2 can bind via its spike protein to the angiotensin-converting enzyme 2 (ACE2) receptor resulting thus in endothelial inflammation [35]. Hence, the underlying pathophysiology may range from direct viral toxicity and thromboinflammation to dysregulated immune system and renin-angiotensin-aldosterone system (RAAS) responses. Moreover, it was suggested that the organotropism of SARS-CoV-2 could be mediated via the dysregulated RAAS response and associated cytokine storm [7,8,35]. Our group recently developed the theory of “fragile endothelium” in an effort to explain the versatile attack of the virus on several vascular territories [36]. We speculated that a vascular topographic viral tropism exists and could be partially mediated via the dysregulated immune and RAAS response and other neurochemical alterations. This theory might at least partially explain the diverse features of thromboembolic disease in COVID-19 (attack on different vascular territories based on the viral tropism creating thus different areas of “fragile endothelium” that is prone to thromboinflammation), which is further observed in clinical and post-mortem studies [4,6,8–10,29,32,37,38]. Whether the application of immunomodulation such as interleukin-6 blockade via tozilizumab, and plasma exchange therapies may reduce the risk of developing thromboembolism in COVID-19 remains unclear and should be further investigated [28,

39–42].

These two rare-case reports, albeit their limitations, describe the insidious development of PE in asymptomatic COVID-19 patients who did not have any other risk factors for thromboembolic disease. Surely, the administration of enhanced anticoagulation in critically ill patients with COVID-19 and increased Padua prediction score and/or elevated D-dimers warrants further attention bearing in mind that a risk of bleeding also exists. However, the administration of prophylactic anticoagulation to asymptomatic carriers is an entirely new subject that needs to be further clarified. The natural course of SARS-CoV-2 viremia remains obscure as reinfections and/or recurrently positive RT-PCR results were previously described [43–46]. We have prescribed a new oral anticoagulant that may be useful in preventing future thromboembolic phenomena as SARS-CoV-2 reinfection and/or natural immunity remain obscure [26,27]. Currently, both patients are under follow-up to determine any side-effects of therapy (i.e., bleeding episodes). In conclusion, asymptomatic COVID-19 patients may exhibit versatile underlying pathophysiology, which could promote the insidious onset of thromboembolic phenomena related to their COVID-19 status. Future large prospective studies are clearly required to refute or confirm the present findings.

Credit authorship contribution statement

Abdullah Balahmar: Validation, Writing-original draft.
 Abdulrahman Alharthy: Conceptualization, Investigation, Validation, and Writing-original draft.
 Fahad Faqih: Investigation, Validation, Writing-original draft.
 Rayan Alshaya: Investigation, Validation, Writing-original draft.
 Alfateh Noor: Investigation, Validation, and Data Analysis.
 Feisal AlAklobi: Investigation, Validation, Writing-original draft.
 Ziad A Memish: Validation, Supervision, review & editing the final draft.
 Dimitrios Karakitsos: Conceptualization, review & editing the final draft.

Funding

This research did not receive any specific grant from funding agencies in the public, commercial, or not-for-profit sectors.

Ethical approval

The study was approved by the Institutional Review Board of King Saud Medical City, Riyadh, Kingdom of Saudi Arabia [H-01-R-053, IORG0010374, H1RI-7-20-01]. Written informed consent was obtained from the patients.

Declaration of competing interest

The authors declare that they have no known competing financial interests or personal relationships that could have appeared to influence the work reported in this paper.

References

- W.J. Guan, Z.Y. Ni, Y. Hu, et al., China medical treatment expert group for covid-19 clinical characteristics of coronavirus disease 2019 in China, *N. Engl. J. Med.* 382 (18) (2020); Apr 30) 1708–1720.
- F. Zhou, T. Yu, R. Du, et al., Clinical course and risk factors for mortality of adult inpatients with COVID-19 in Wuhan, China: a retrospective cohort study, *Lancet* 395 (10229) (2020); Mar 28) 1054–1062.
- G. Grasselli, A. Zangrillo, A. Zanella, et al., COVID-19 lombardy ICU network. Baseline characteristics and outcomes of 1591 patients infected with SARS-CoV-2 admitted to ICUs of the lombardy region, Italy, *J. Am. Med. Assoc.* 323 (16) (2020 Apr 6) 1574–1581.
- Y. Deng, W. Liu, K. Liu, et al., Clinical characteristics of fatal and recovered cases of coronavirus disease 2019 (COVID-19) in Wuhan, China: a retrospective study, *Chin. Med. J.* 133 (11) (2020 Jun 5) 1261–1267, <https://doi.org/10.1097/CM9.0000000000000824>.
- G. Hékimian, G. Lebreton, N. Bréchet, C.E. Luyt, M. Schmidt, A. Combes, Severe pulmonary embolism in COVID-19 patients: a call for increased awareness, *Crit. Care* 24 (2020) 274.
- M. Fraissé, E. Logre, O. Pajot, H. Mentec, G. Plantefève, D. Contou, Thrombotic and hemorrhagic events in critically ill COVID-19 patients: a French monocenter retrospective study, *Crit. Care* 24 (2020) 275.
- Z. Varga, A.J. Flammer, P. Steiger, et al., Endothelial cell infection and endotheliitis in COVID-19, *Lancet* 395 (10234) (2020 May 2) 1417–1418, [https://doi.org/10.1016/S0140-6736\(20\)30937-5](https://doi.org/10.1016/S0140-6736(20)30937-5). Epub 2020 Apr 21.
- Y. Zhang, M. Xiao, S. Zhang, et al., Coagulopathy and antiphospholipid antibodies in patients with Covid-19, *N. Engl. J. Med.* 382 (2020) e38.
- T. Menter, J.D. Haslbauer, R. Nienhold, et al., Post-mortem examination of COVID-19 patients reveals diffuse alveolar damage with severe capillary congestion and variegated findings of lungs and other organs suggesting vascular dysfunction, *Histopathology* (2020); May 4, <https://doi.org/10.1111/his.14134> (in press).
- C. Bao, X. Liu, H. Zhang, Y. Li, J. Liu, Coronavirus disease 2019 (COVID-19) CT findings: a systematic review and meta-analysis, *J. Am. Coll. Radiol.* 17 (2020) 701–709.
- H. Shi, X. Han, N. Jiang, et al., Radiological findings from 81 patients with COVID-19 pneumonia in Wuhan, China: a descriptive study, *Lancet Infect. Dis.* 20 (2020) 425–434.
- J. Wu, X. Wu, W. Zeng, et al., Chest CT Findings in patients with corona virus disease 2019 and its relationship with clinical features, *Invest. Radiol.* 55 (2020) 257–261.
- X. Xu, C. Yu, J. Qu, et al., Imaging and clinical features of patients with 2019 novel coronavirus SARS-CoV-2, *Eur. J. Nucl. Med. Mol. Imag.* 47 (2020) 1275–1280.
- Y.H. Xu, J.H. Dong, W.M. An, et al., Clinical and computed tomographic imaging features of novel coronavirus pneumonia caused by SARS-CoV-2, *J. Infect.* 80 (2020) 394–400.
- Diamond princess (ship), Available at: https://en.wikipedia.org/wiki/Diamond_Princess, 2020 (ship).
- Z. Hu, C. Song, C. Xu, et al., Clinical characteristics of 24 asymptomatic infections with COVID-19 screened among close contacts in nanjing, China, *Sci. China Life Sci.* 63 (5) (2020 May) 706–711, <https://doi.org/10.1007/s11427-020-1661-4>. Published Online March 04 2020.
- L. Zou, F. Ruan, M. Huang, et al., SARS-CoV-2 viral load in upper respiratory specimens of infected patients, *N. Engl. J. Med.* 382 (2020) 1177–1179.
- A.K. Nalla, A.M. Casto, HuangMW, et al., Comparative performance of SARS-CoV-2 detection assays using seven different primer/probe sets and one assay kit, *J. Clin. Microbiol.* 58 (6) (2020 May 26) e00557–20, <https://doi.org/10.1128/JCM.00557-20>. Print 2020 May 26.
- WangW, Y. Xu, R. Gao, et al., Detection of SARS-CoV-2 in different types of clinical specimens, *J. Am. Med. Assoc.* 323 (18) (2020 Mar 11) 1843–1844, <https://doi.org/10.1001/jama.2020.3786>.
- V.M. Corman, O. Landt, M. Kaiser, et al., Detection of 2019 novel coronavirus (2019-nCoV) by real-time RT-PCR, *Euro Surveill.* 25 (3) (2020) pii2000045.
- Saudi Ministry of Health, Coronavirus Diseases 19 (COVID-19) guidelines. (revised version 1.7). <https://covid19.moh.gov.sa>, May 25th, 2020.
- World Health Organization, Corona-virus disease (COVID-19) technical guidance: laboratory testing for 2019-nCoV in humans, Available at: <https://www.who.int/emergencies/diseases/novel-coronavirus-2019/technical-guidance/laboratory-guidance>.
- X. Xie, Z. Zhong, W. Zhao, et al., Chest CT for typical 2019-nCoV pneumonia: relationship to negative RT-PCR testing, *Radiology* (2020) 200343.
- Y. Fang, H. Zhang, J. Xie, et al., Sensitivity of chest CT for COVID-19: comparison to RT-PCR, *Radiology* (2020), 200432.
- T. Zhu, Y. Wang, S. Zhou, N. Zhang, L. Xia, A comparative study of chest computed tomography features in young and older adults with corona virus disease (COVID-19), *J. Thorac. Imag.* 35 (4) (2020 Jul) W97–W101, <https://doi.org/10.1097/RTI.0000000000000513>.
- J.I. Weitz, G.E. Rascob, A. Spyropoulos, et al., Thromboprophylaxis with rivaroxaban in acutely ill medical patients with renal impairment: insights from the MAGELLAN and MARINER trials, *Thromb. Haemostasis* 120 (3) (2020 Mar) 515–524.
- I. Paranjpe, V. Fuster, A. Lala, et al., Association of treatment dose anticoagulation with in-Hospital survival among hospitalized patients with COVID-19, *JACC (J. Am. Coll. Cardiol.)* 76 (1) (2020 May 15) 123–124, <https://doi.org/10.7326/M20-3255>. M20-3255.
- A. Faqih, A. Alharthy, M. Alodat, et al., Therapeutic plasma exchange in adult critically ill patients with life-threatening SARS-CoV-2 disease: a pilot study, *J. Crit. Care* (2020); August) (in press).
- A. Alharthy, F. Faqih, M. Abuhamdah, et al., A prospective, longitudinal evaluation of point-of-care lung ultrasound in critically ill patients with severe COVID-19 pneumonia, *J. Ultrasound Med.* (2020); August) (in press).
- C. Zhang, Z. Wu, J.W. Li, H. Zhao, G.Q. Wang, The cytokine release syndrome (CRS) of severe COVID-19 and Interleukin-6 receptor (IL-6R) antagonist Tocilizumab may be the key to reduce the mortality, *Int. J. Antimicrob. Agents* 29 (2020); Mar) 105954.
- Puja Mehta, F. McAuley Daniel, M. Brown, E. Sanchez, R.S. Tattersall, J.J. Manson, HLH Across Specialty Collaboration, UK, COVID-19: consider cytokine storm syndromes and immunosuppression, *Lancet* 395 (10229) (2020) 1033–1034.
- L. Zhang, X. Feng, D. Zhang, et al., Deep vein thrombosis in hospitalized patients with coronavirus disease 2019 (COVID-19) in wuhan, China: prevalence, risk factors, and outcome, *Circulation* 10 (2020) 1161.
- N. Tang, H. Bai, X. Chen, J. Gong, D. Li, Z. Sun, Anticoagulant treatment is associated with decreased mortality in severe coronavirus disease 2019 patients with coagulopathy, *J. Thromb. Haemostasis* 18 (2020) 1094–1099.
- F.A. Klok, M.J.H.A. Kruip, N.J.M. van der Meer, et al., Incidence of thrombotic complications in critically ill ICU patients with COVID-19, *Thromb. Res.* 191 (2020 Jul) 145–147.
- D. Wrapp, N. Wang, K.S. Corbett, et al., Cryo-EM structure of the 2019-nCoV spike in the prefusion conformation, *Science* 367 (6483) (2020 Mar 13) 1260–1263, <https://doi.org/10.1126/science.abb2507>. Epub 2020 Feb 19.
- Alharthy A, Faqih A, Memish ZA, Karakitsos D. Fragile endothelium and brain dysregulated neurochemical activity in COVID-19. *ACS Chem. Neurosci.* doi: 10.1021/acschemneuro.0c00437.
- C. Deshpande, Thromboembolic findings in COVID-19 autopsies: pulmonary thrombosis or embolism? *Ann. Intern. Med.* (2020) <https://doi.org/10.7326/M20-3255>.
- S.E. Fox, A. Akmatbekov, J.L. Harbert, G. Li, J. Quincy Brown, R.S. Vander Heide, Pulmonary and cardiac pathology in African American patients with COVID-19: an autopsy series from New Orleans, *Lancet Respir. Med.* 8 (7) (2020 Jul) 681–686, [https://doi.org/10.1016/S2213-2600\(20\)30243-5](https://doi.org/10.1016/S2213-2600(20)30243-5).
- B. Liu, M. Li, Z. Zhou, X. Guan, Y. Xiang, Can we use interleukin-6 (IL-6) blockade for coronavirus disease 2019 (COVID-19)-induced cytokine release syndrome (CRS)? *J. Autoimmun.* 10 (2020); Apr) 102452.
- P. Luo, Y. Liu, L. Qiu, X. Liu, D. Liu, J. Li, Tocilizumab treatment in COVID-19: a single center experience, *J. Med. Virol.* 92 (7) (2020); Jul) 814–881.
- J.B. Moore, C.H. June, Cytokine release syndrome in severe COVID-19, *Science* 368 (6490) (2020) 473–474.
- L. Li, W. Zhang, Y. Hu, X. Tong, et al., Effect of convalescent plasma therapy on time to clinical improvement in patients with severe and life-threatening COVID-19: a randomized clinical trial, *J. Am. Med. Assoc.* (2020 Jun 3), e2010044, <https://doi.org/10.1001/jama.2020.10044>.
- L. Lan, D. Xu, G. Ye, et al., Positive RT-PCR test results in patients recovered from COVID-19, *J. Am. Med. Assoc.* 323 (15) (2020 Feb 27) 1502–1503, <https://doi.org/10.1001/jama.2020.2783>.
- L. Zou, F. Ruan, M. Huang, et al., SARS-CoV-2 viral load in upper respiratory specimens of infected patients, *N. Engl. J. Med.* 382 (2020) 1177–1179.
- K.I. Zheng, X.B. Wang, X.H. Jin, et al., A case series of recurrent viral RNA positivity in recovered COVID-19 Chinese patients. Version 2, *J. Gen. Intern. Med.* 35 (7) (2020 Jul) 2205–2206.
- R. Hu, Z. Jiang, H. Gao, et al., Recurrent positive reverse transcriptase-polymerase chain reaction results for coronavirus disease 2019 in patients discharged from a hospital in China, *JAMA Netw. Open* 3 (5) (2020 May 1), e2010475, <https://doi.org/10.1001/jamanetworkopen.2020.10475>.