



STING-associated vasculopathy with onset in infancy: a familial case series report and literature review

Yan Wang^{1#}, Fan Wang^{1,2#}, Xiaolei Zhang^{1,3,4,5}

¹Department of Pulmonary and Critical Care Medicine, Center of Respiratory Medicine, China–Japan Friendship Hospital, Beijing, China; ²The Sixth Medical Center of PLA General Hospital, Beijing, China; ³Institute of Respiratory Medicine, Chinese Academy of Medical Sciences, Peking Union Medical College, Beijing, China; ⁴Capital medical university, Beijing, China; ⁵Peking University Health Science Center, Beijing, China

#These authors contributed equally to this work.

Correspondence to: Professor Xiaolei Zhang. Department of Pulmonary and Critical Care Medicine, Center of Respiratory Medicine, China–Japan Friendship Hospital, 2 East Yinghua (Cherry Blossom) Road, Hepingli, Chaoyang District, Beijing 100029, China. Email: yutian728@sina.com.

Abstract: Stimulator of interferon genes (*STING1*) is a key intermediary in activating the type I IFN response. *STING*-associated vasculopathy with onset in infancy (SAVI) is a very rare autoinflammatory disease that is caused by heterozygous gain-of-function mutations in *STING1*. SAVI typically manifests as neonatal-onset systemic inflammation, interstitial lung disease (ILD), and severe cutaneous vasculopathy located in acral regions, including fingers, toes, ears, and nose. Severity of ILD and recurrent pulmonary infections are crucial for the prognosis. Therapeutic options for SAVI are quite limited, and JAK inhibitors are considered to be a promising treatment according to several recent case reports. We report on a familial case series of SAVI with the R281Q mutation in the *STING1* gene with predominant ILD manifestations, absence of cutaneous lesions, and poor response to ruxolitinib. Moreover, we reviewed all the case reports of SAVI in English published in the PubMed database. The atypical phenotype of the current cases adds to the growing list of inflammatory syndromes associated with SAVI. The literature analysis suggests that the severity and natural courses of the disease seem to be independent of the mutation type. Although JAK inhibitors may be a promising treatment, the therapeutic effect for different phenotypes and disease statuses of SAVI warrants further investigation.

Keywords: *STING*-associated vasculopathy with onset in infancy (SAVI); Janus kinase inhibitors (JAK inhibitors); interstitial lung disease (ILD)

Submitted Aug 30, 2020. Accepted for publication Dec 18, 2020.

doi: 10.21037/atm-20-6198

View this article at: <http://dx.doi.org/10.21037/atm-20-6198>

Introduction

Stimulator of interferon genes (*STING*), which is encoded by the gene transmembrane protein 173 (*STING1*), is a key intermediary in activating the type I interferon (IFN) response (1). Pathogenic heterozygous gain-of-function (GOF) variants in *STING1* result in constitutive activation of *STING* and the clinical syndrome known as *STING*-associated vasculopathy with onset in infancy (SAVI) (2). SAVI is characterized by early-onset systemic inflammation, cutaneous vasculopathy, and interstitial lung disease (ILD).

The severity of ILD and the presence of repeated lung infections determine the prognosis of the disease (3).

Therapeutic management of SAVI is challenging. It has been reported that systemic corticosteroids are partially effective in some cases; however, most patients respond poorly to disease-modifying therapies, such as corticosteroids, immunosuppressants and biologic agents (1). In addition, the prognosis of SAVI is generally poor, especially in patients with severe lung involvement with high mortality in the first two decades of life. In light of the encouraging results obtained with the use of Janus kinase (JAK) inhibitors in

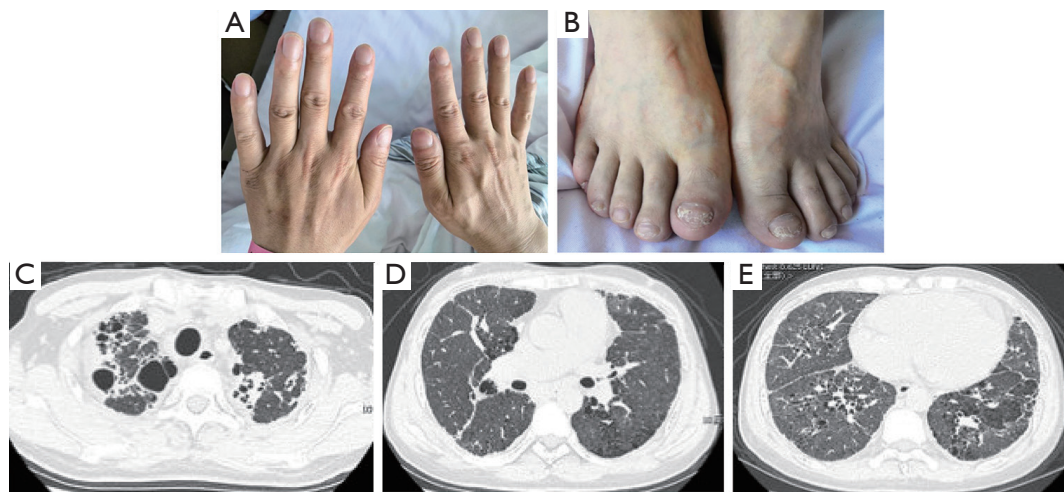


Figure 1 Clinical manifestations and chest image of case 1. (A) Clubbing fingers of case 1. (B) Nail dystrophy of toes in case 1. (C-E) Chest high-resolution computed tomography scan of case 1. The presence of cystic airspaces in upper lobes, and bilateral reticular and ground-glass opacities in the lower lobes in case 1.

some SAVI cases (4,5), this treatment is presumed to be the most promising therapy for patients with different *STING1* variants. Here, we present the first familial SAVI case series with the R281Q variant with severe pulmonary involvement, in which treatment with the JAK1/2 inhibitor ruxolitinib showed poor response. We present the following cases in accordance with the CARE reporting checklist (available at <http://dx.doi.org/10.21037/atm-20-6198>).

Case presentation

All procedures performed in studies involving human participants were in accordance with the ethical standards of our institutional ethics committee and with the Helsinki Declaration (as revised in 2013). Written informed consent was obtained from the patient.

Case 1

A 37-year-old male presented with progressively exertional dyspnea. He had an 18-year history of abnormal imaging on chest radiograph. Four months prior, he was admitted to the local hospital due to severe cough, expectoration, dyspnea (NYHA III), nausea and vomiting. He was diagnosed as ILD accompanied by pneumonia and received antibiotics (penicillin and levofloxacin, 2 weeks) and systemic corticosteroids (methylprednisolone 40 mg, 4 weeks) without symptom improvement. Clubbing fingers

and nail dystrophy were evident (*Figure 1A,B*). No rashes, livedo reticularis or telangiectasias were observed.

Laboratory tests found an elevated C-reactive protein (CRP) level (5.53 mg/dL, reference range: <0.8 mg/dL). The autoimmune workup was positive for antinuclear antibody, anti-dsDNA antibody, anti-cyclic citrullinated peptide (CCP) antibody, anti-Jo-1 antibody and IgG antibody to phospholipids (49; reference range, <20). Immunological testing revealed elevated levels of IgA (494 mg/dL) and positive for rheumatoid factor (RF). Increased CD8+ T lymphocytes counts and normal CD4+ T lymphocytes counts were identified. High-resolution CT (HRCT) scanning of the chest exhibited bilateral ground-glass and reticular opacities as well as cystic changes (*Figure 1C,D,E*). The arterial blood gases analysis (breathing room air) revealed hypoxemia [partial pressure of oxygen (pO_2) 65 mmHg] and partial pressure of carbon dioxide (pCO_2) of 33.9 mmHg. Pulmonary function tests showed a severe restrictive pattern [total lung capacity (TLC); 47.5% of predicted] with a decreased diffusing capacity for carbon monoxide (DLCO) (22.4% of predicted). The echocardiogram demonstrated signs of right ventricle pressure overload and estimated significantly elevated systolic pulmonary pressure (84 mmHg).

Case 2

Both sons of our index case suffered from recurrent dyspnea, cough and wheezing associated with exertion after two

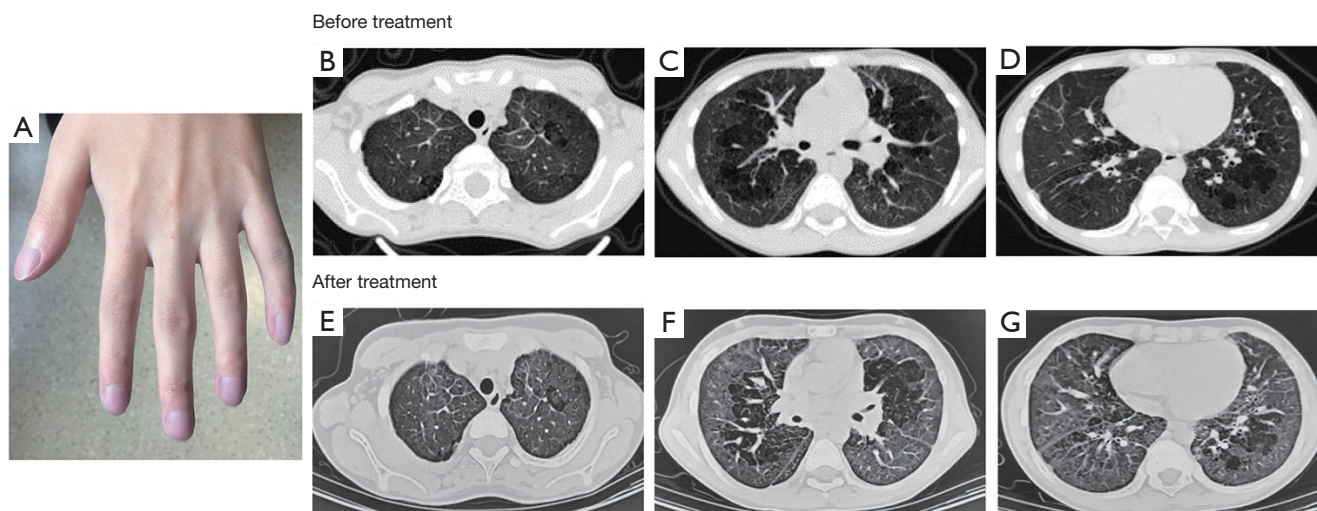


Figure 2 Clinical manifestations and chest image of case 2. (A) Clubbing fingers of case 2. (B-G) Chest high-resolution computed tomography scan of case 2. Diffused ground-glass opacities and focal lung hyperinflation in case 2.

years of age. Case 2, a 13-year-old son, displayed retarded growth with a height and weight below the 3rd percentiles for age (131.5 cm and 31.5 kg, respectively). He exhibited finger clubbing and suffered from recurrent migratory polyarthritis involving the interphalangeal, wrist, knee and ankle joints with impaired motion of the wrists (*Figure 2A*). Elevated antinuclear antibody titer (1:1,280) were detected. Pulmonary function tests exhibited a restrictive pattern with TLC 61.5% and DLCO 48.8% predicted. HRCT revealed diffuse ground-glass opacities (*Figure 2B,C,D*). After the treatment of ruxolitinib (JAK1/2 inhibitor), HRCT of the chest was shown in *Figure 2E,F,G*.

Case 3

The six-year-old son (case 3) also had failure to thrive with a height of 114 cm (between the 3rd and 10th percentiles) and weight of 16.25 kg (below the 3rd percentile). He did not have skin lesions or symptoms of arthritis. Clubbing fingers were observed (*Figure 3A*). The antinuclear antibody titer was 1:320. Diffused ground-glass and fine reticular opacities were demonstrated on HRCT of the chest (*Figure 3B,C,D*). He did not receive any treatment. After one year of follow-up, HRCT of the chest did not show obvious difference (*Figure 3E,F,G*).

Genetic analysis of the three cases by Sanger sequencing demonstrated a heterozygous *STING1* (NM_198282) variant c.841G>A, p.Arg 281 Gln, p.R281Q, which has

previously been described to cause an autosomal dominant form of SAVI (6). Genetic testing of the parents of case 1 revealed that the pathogenic variant had occurred de novo. All 3 cases were heterozygous carriers of this variant (*Figure 4A,B*). IFN proteins and the levels of circulating inflammatory cytokines, which were detected via ELISA (Human IFN 9-Plex ELISA Kit, PBL Assay Science, USA), were significantly increased in these cases compared to controls (*Figure 5*). The control group consisted of 8 healthy adult men with an average age of 42 years. The three cases received the diagnose of SAVI.

Due to low platelet levels ($<100 \times 10^9/L$), case 1 and case 2 underwent treatment with ruxolitinib (JAK1/2 inhibitor) at doses of 5 mg (0.20 mg/kg/d) and 2.5 mg (0.16 mg/kg/d), respectively, twice per day. Increased dosing of ruxolitinib was poorly tolerated due to unusual bleeding or bruising. Case 3 did not take ruxolitinib. Case 1 died four months later due to progressive ILD and heart failure. After one year of therapy, polyarthritis and arthralgia in case 2 were not ameliorated. The interstitial abnormalities on HRCT scan revealed no improvement for case 2 (*Figure 2E,F,G*). The antinuclear antibody titer remained high in case 2 and case 3 (1:320 and 1:160, respectively). IFN proteins as well as circulating inflammatory cytokines did not improve (*Figure 5*).

Literature review

Among all the English literature on the PubMed database

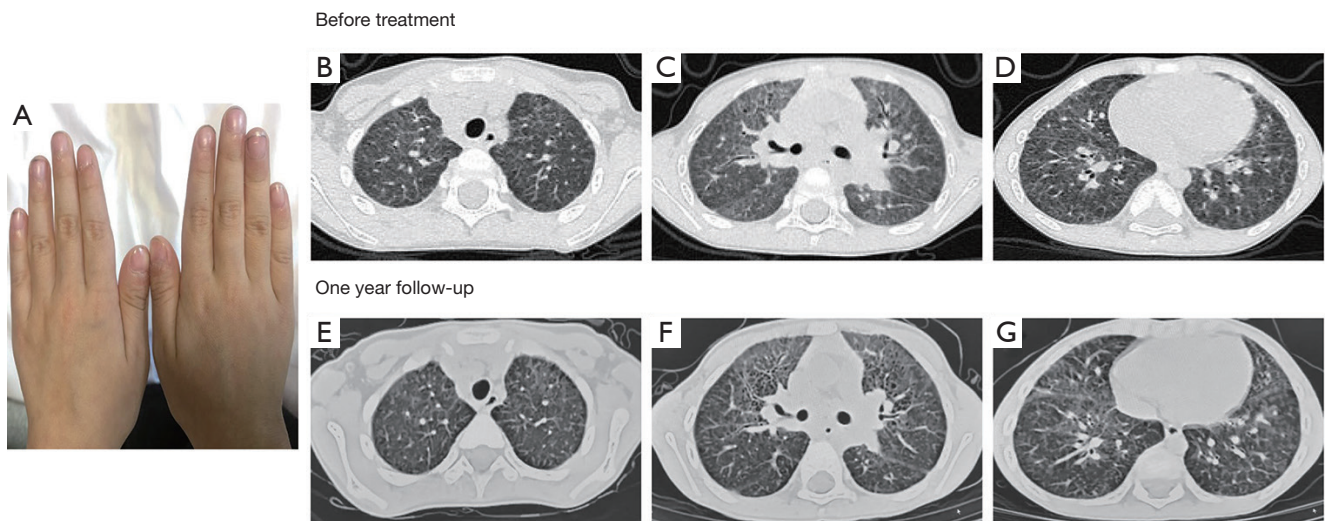


Figure 3 Clinical manifestations and chest image of case 3. (A) Clubbing fingers of case 3. (B-G) Chest high-resolution computed tomography scan of case 3. Diffused ground-glass and fine reticular opacities in case 3.

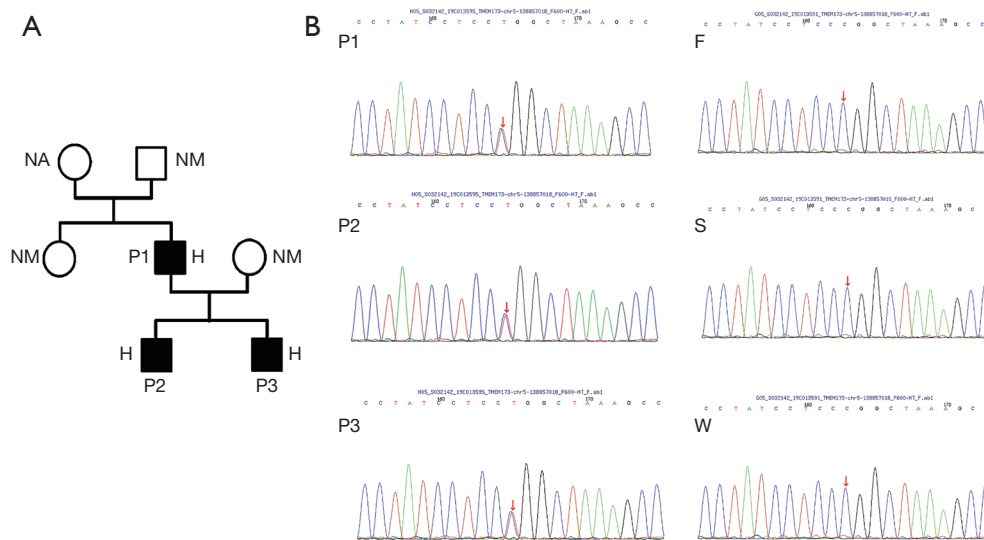


Figure 4 The genetic analysis of the three cases. (A) Family pedigrees of the 3 cases with the R281Q pathogenic variant in *STING1*. Solid symbols indicate affected relatives, open symbols indicate unaffected relatives, squares represent male persons, and circle represent female persons. H denotes heterozygous mutated gene, NA denotes not available, NM denotes nonmutated gene. (B) Whole-exome sequencing (WES) filtering was performed on patients and his relatives. P denotes the case; F denotes the father of case 1; S denotes the sister of case 1; W denotes the wife of case 1.

from 1980 to November 2020, only 56 cases of SAVI have been reported to date (Table 1), including these three newly identified cases (Table 2). Among the published case reports, the age at presentation ranged from 1 day to 65 years. There were 30 (54%) males, 22 (39%) females, and 4 patients without sex information. The prominent

clinical manifestations included ILD (39 cases, 70%), developmental retardation (28 cases, 50%), and skin lesions (43 cases, 78%). In addition, 5 cases (9%) had pulmonary hypertension, 4 cases exhibited hypothyroidism (8%), and 9 cases (18%) were asymptomatic in the respiratory system. All nine reported fatalities from SAVI were due to

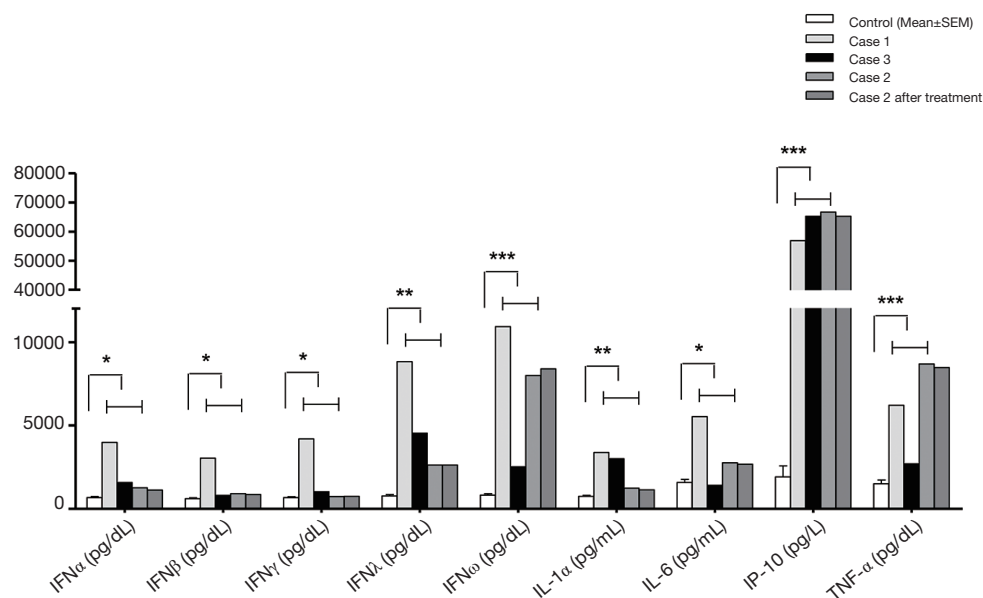


Figure 5 The activation of IFN proteins and inflammatory cytokines. The circulating IFN proteins and released inflammatory cytokines were measured via ELISA. Compared with controls (n=10), serum levels of IFN proteins (IFN α , IFN β , IFN γ , IFN λ 1/2 and IFN ω) and inflammatory cytokines (IL-1 α , IL-6, IP-10 and TNF- α) were significantly increased. After ruxolitinib treatment, no obvious reductions in IFN proteins (IFN α , IFN β , IFN γ , IFN λ 1/2 and IFN ω) and inflammatory cytokines (IL-1 α , IL-6, IP-10 and TNF- α) were observed in case 2. The data were analyzed by the unpaired t test. The symbols (*), (**) and (***) indicate statistically significant changes at P<0.05, P<0.01, and P<0.001, respectively.

pulmonary complications.

Either inherited or *de novo*, 12 types of activating *STING1* pathogenic variants were identified in SAVI patients. The most common mutation was p.V155M (19 cases, 35%). Only one case was found to have double mutations (p. S102P and p.F279L) (3). In addition to our three patients, there was another reported case with a heterozygous R281Q mutation with both ILD and evident skin lesions (6). Lin *et al.* recently reported 6 SAVI patients from 4 unrelated families with the recessive homozygous *STING1* variant p.R281W (22). The severity and natural courses of the disease seem to be independent of the mutation type. For instance, a 25-year-old SAVI patient with R284G pathogenic variant had no lung involvement (6). However, another 9-month-old patient with the same location of pathogenic variant died shortly due to respiratory failure (13).

Information on treatment was available in 37 cases. Corticosteroids were used in 25 cases, and only 11 cases had limited evidence of improvement. Immunosuppressive agents were combined with corticosteroids in 16 cases without a significant additional effect. Recently, JAK

inhibitors have been gradually brought to the forefront (2). Among the 20 patients receiving JAK inhibitors, the skin lesions and/or pulmonary impairment were variously improved in 10 cases. Additionally, 1 case received lung transplantation (3), and 1 case was prescribed salicylic acid. However, both exhibited poor responses (6).

Discussion

STING is a key player in the upstream regulation of the type I IFN response. Activated *STING* serves as an adaptor to induce the production and secretion of type I interferons (IFNs). Binding of IFNs to their receptors activates Janus kinases (JAKs) to upregulate the transcription of interferon-stimulated genes. Specifically, JAK1 was involved in IFN beta and IFN alpha signaling. Therefore, the release of interferon leads to a positive feedback loop that further upregulates *STING* and the transcription of other proinflammatory cytokines. In patients with SAVI, constitutively activated *STING* leads to increased transcription of the type 1 interferon gene IFNB1, which encodes interferon- β . Binding of interferon- β to its receptor activates JAKs, including

Table 1 Review of reported SAVI patients

Study, year of publication	Case number (sex distribution), age onset	Lung involvement [number of patients afflicted]	Developmental retardation	Cutaneous and other presentations [number of patients afflicted]	Inflammatory markers	Immune perturbation	Autoantibody profile [number of patients afflicted]	Gene variant [number of patients afflicted]	Treatment	Prognosis
Liu <i>et al.</i> , 2014 (1)	6 (3 F/3 M), 1 day to 8 w	ILD [5], paratracheal adenopathy [6], lung fibrosis [3]	Unknown	Acral violaceous plaques [6], skin nodules [6], nail dystrophy or loss [6], nasal-septum perforation [4]	Unknown	Unknown	ANA+ [3], Antiphospholipid antibodies+ [5], c-ANCA+ [1]	<i>de novo</i> p.N154S [4], <i>de novo</i> p.V155M [1], <i>de novo</i> p.V147L [1]	Glucocorticoid, DMARD, Biologic agent	No response or incomplete response
Omoyinmi <i>et al.</i> , 2015 (7)	1 (M), 1 w	ILD, pulmonary hypertension	Unknown	Ulceration of the extremities	Increased levels of CRP, ESR	Unknown	Anticardiolipin IgG+, lupus anticoagulant+	<i>de novo</i> p.V155M	Corticosteroids, cyclophosphamide, azathioprine, methotrexate, rituximab and infliximab	Deceased (at 16y)
Jeremiah <i>et al.</i> , 2014 (8)	1 (M), 65 y (proband's grandpa)	Normal	Yes	Unknown	Increased levels of CRP, ESR	Unknown	ANA 1:340	pV155M	Nil	Unknown
	1 (M), 29 y (proband's father)	ILD	Yes	Unknown	Increased levels of CRP, ESR	Unknown	ANA 1:640	Inherited pV155M	Nil	Deceased
	1 (M), 33 y (proband's uncle)	ILD	Yes	Unknown	Increased levels of CRP, ESR	Unknown	ANA 1:320	Inherited pV155M	Nil	Unknown
	1 (F), 4 y (proband)	ILD	Yes	Unknown	Increased levels of CRP, ESR	Unknown	ANA 1:200-1:800	Inherited pV155M	Nil	Unknown
Munoz, <i>et al.</i> , 2015 (9)	1 (M), 38 w	ILD stable	Yes	Skin necrosis, gangrene, Nasal septum perforation	Normal	Unknown	ANCA 1:200-1:400	<i>de novo</i> p.V147M	Methylprednisolone, prednisone, clopidogrel bisulfate, nifedipine	Pulmonary feature stable, skin lesions worse
Picard, <i>et al.</i> , 2016 (3)	1 (M), 12 y	Pulmonary fibrosis	Yes	Telangiectasia and chilblains	Increased levels of CRP, ESR	CD4+ lymphopenia, NK cell decreased, hypergammaglobulinemia (IgG, IgA)	ANA+	<i>de novo</i> p.V155M	Nil	Unknown
	1 (F), 20 y	Pulmonary fibrosis, emphysema	Unknown	Acral telangiectasia, atrophic plaques, nail dystropy	Unknown	CD4+ lymphopenia, NK cell decreased, hypergammaglobulinemia (IgG)	ANA+, c-ANCA+	<i>de novo</i> p.V155M	Lung transplantation	Deceased
	1 (M), 5 m	ILD	Yes	Telangiectasia and chilblains	Increased levels of CRP, ESR	CD4+ and CD8+ lymphopenia, hypergammaglobulinemia (IgG)	Nil	<i>de novo</i> p.V155M	Nil	Unknown
Frémond <i>et al.</i> , 2016 (4)	1 (M), 12 y (reported by Picard, <i>et al.</i> , 2016)	Lung fibrosis	Yes	Chilblains of the feet and left ear	Increased levels of CRP, ESR	CD4+ lymphopenia, NK cell decreased, hypergammaglobulinemia (IgG, IgA)	ANA+	<i>de novo</i> p.V155M	Hydroxychloroquine, steroids, ruxolitinib	Improved for lung symptoms but not skin lesions
	1 (F), neonate (reported by Jeremiah <i>et al.</i> , 2014)	ILD	Yes	Occasional erythema of the cheeks	Increased levels of CRP, ESR	Unknown	ANA 1:200-1:800	Inherited pV155M	Steroids, MMF, anti-CD20 monoclonal antibodies, ruxolitinib	Improvement of interstitial pneumonitis
Seo, <i>et al.</i> , 2017 (10)	1 (M), 9 y	Obliterative bronchiolitis	Unknown	Perforated nasal septum, gangrenous lesions	Increased levels of CRP, ESR	CD4+ lymphopenia, monocytes increased	Unknown	<i>de novo</i> p.S102P, <i>de novo</i> p.F279L	Tofacitinib	Only skin lesions improved
Clarke <i>et al.</i> , 2016 (11)	1 (M), 5 w	ILD	Unknown	Maculo papular, erythematous lesions	Increased levels of CRP	IgG and IgA increased	SSA+	<i>de novo</i> p.V155M	Methylprednisolone and immunoglobulin	Improved

Table 1 (continued)

Table 1 (continued)

Study, year of publication	Case number (sex distribution), age onset	Lung involvement [number of patients afflicted]	Developmental retardation	Cutaneous and other presentations [number of patients afflicted]	Inflammatory markers	Immune perturbation	Autoantibody profile [number of patients afflicted]	Gene variant [number of patients afflicted]	Treatment	Prognosis
Melki <i>et al.</i> , 2017 (6)	1 (F), 25 y	Normal	Yes	Livido Acrocyanosis, palatal/nasal septum necrosis	Normal	Unknown	ANA 1:160, ANCA-	<i>de novo</i> p.R284G	Nil	Unknown
	1 (F), 3 m	ILD	Yes	Early-onset malar rash	Increased of inflammatory markers	Unknown	Nil	<i>de novo</i> p.R281Q	Steroids, methotrexate, anti-TNF α	No efficacy
	1 (M), 15 y	Normal	No	Livedo and dark purple marbling on the limbs, painful acralerosions on the ear helices and digits	Normal	Normal	Nil	<i>de novo</i> p.C206Y	Nifedipin, pentoxifyllin, acetyl, salicylic acid	Limited efficacy for skin lesions
Saldanha <i>et al.</i> , 2018 (12)	1 (M), 3 y	ILD, pulmonary hypertension	Yes	Acral erythema-tous papules, livedo racemosa	Increased levels of CRP, ESR, ferritin, IL-6, and IL-1 β	CD4+ and CD8+ lymphopenia	Unknown	<i>de novo</i> p.R284S	Ruxolitinib (5 mg daily) and oral prednisolone (2 mg/kg daily)	Exercise capacity improved, complete loss of nasal septum
Konno <i>et al.</i> , 2018 (13)	1 (M), 9 m	Normal	No	No	Increased level of IL-6	Unknown	Unknown	<i>de novo</i> p.R284S	Nil	Deceased
Sanchez <i>et al.</i> , 2018 (5)	4 (unknown), 0–18 y	ILD [4]	Yes	Cutaneous vasculitis [4], ulcers [3],	Increased levels of CRP, ESR	Unknown	Unknown	<i>de novo</i> p.N154S	Baricitinib	Improved for lung function
Yu <i>et al.</i> , 2018 (14)	1 (M), 2 m	ILD	Yes	Cold-induced violaceous papules or plaques on ears	Increased levels of CRP, ESR, IL-6 and TNF- α	Hypergammaglobulinemia (IgG, IgA)	RF+	<i>de novo</i> p.V155M	Tofacitinib	Improved for lung function
Shoman <i>et al.</i> , 2019 (15)	1 (F), 5 y	ILD	Yes	Atrophic scars, destructed nasal septum, destructed nails	Increased levels of CRP, ESR	Unknown	ANA+	<i>de novo</i> p.N154S	Methotrexate, prednisolone	Improved for lung disease and cutaneous lesions
Volpi <i>et al.</i> , 2019 (2)	1 (F), 8 m	ILD	Yes	Maculopapular lesions evolving to ulcers	Increased levels of CRP, ESR	Normal	ANA+, p-ANCA+, PR3+	<i>de novo</i> p.V155M	Ruxolitinib	Improved for lung disease and cutaneous lesions
	1 (F), 3 m	ILD	Yes	Malar rash	Increased level of ESR	Normal	cANCA+, anti-cardiolipin+, B2GLG+	<i>de novo</i> p.R281Q	Ruxolitinib	Skin lesions and ILD worsened
	1 (F), 3 m	ILD	Yes	Erythematous vesicular rash	Increased levels of CRP, ESR	Normal	cANCA+, PL+, anti-cardiolipin+, PT+	<i>de novo</i> p.N154S	Ruxolitinib	Transient improvement for lung disease and skin lesions, and then lapse of ILD
Balci <i>et al.</i> , 2019 (16)	1 (M), 6 m	ILD	No	Purplish red non-indurating plaques and pustular lesions	Increased levels of CRP, ESR	Normal	Nil	<i>de novo</i> p.N154S	Ruxolitinib switch to baricitinib	Greatly improved for lung and cutaneous lesions
Tang <i>et al.</i> , 2020 (17)	1 (F), 4 m	ILD	Yes	No	Increased level of ESR	Hypergammaglobulinemia IgG and decreased NK cells, decreased CD3+ lymphocytes and CD3+CD8+ lymphocytes	ANCA+ (25 m after the onset), ANA 1:80	<i>de novo</i> p.V155M	Corticosteroids, IVIG	Improved for lung and cutaneous lesions
	1 (F), 3 m	ILD	Yes	Angioelectasis, chilblain lesions	Normal	Hypergammaglobulinemia IgG, decreased NK cells, decreased CD3+ lymphocytes and CD3+CD8+ lymphocytes	Unknown	<i>de novo</i> p.V155M	Corticosteroids, IVIG, tofacitinib	Deceased

Table 1 (continued)

Table 1 (continued)

Study, year of publication	Case number (sex distribution), age onset	Lung involvement [number of patients afflicted]	Developmental retardation	Cutaneous and other presentations [number of patients afflicted]	Inflammatory markers	Immune perturbation	Autoantibody profile [number of patients afflicted]	Gene variant [number of patients afflicted]	Treatment	Prognosis
	1 (M), 54 m	ILD	No	Angiotelectasis, erythematous, purpuric or scaling rashes	Increased levels of CRP, ESR	Hypergammaglobulinemia IgG and decreased NK cells	RF+, CCP+	<i>de novo</i> p.V155M	Corticosteroids, IVIG, CTX, tofacitinib	Respiratory symptoms improved but rashes worsened
Keskitalo <i>et al.</i> , 2019 (18)	1 (M), birth	Normal	Unknown	Livedo reticularis, skin vasculitis, nasal septal perforation, facial erythema, UV sensitivity, alopecia, skin infections	Unknown	Decreased CD19+ B cells and NK cells, increased IgE	Negative	Inherited p. G207E	Prednisolone combined with azathioprine or methotrexate, cyclosporine, baricitinib	Improved for alopecia and over-all well being
	1 (F), birth	Recurrent pneumonia	Unknown	Livedo reticularis, skin vasculitis, nasal septal perforation, facial erythema, UV sensitivity, alopecia, skin infections, autoimmune thyroiditis	Unknown	Increased IgE	Negative	Inherited p. G207E	Antibiotics, prednisolone and cyclosporine	Improved for skin infection
	1 (F), birth	Normal	Unknown	Livedo reticularis, facial erythema, UV sensitivity, alopecia, skin infections, hypothyroid	Unknown	Increased IgE	Negative	Inherited p. G207E	Unknown	Unknown
	1 (F), birth	Normal	Unknown	Livedo reticularis, nasal septal perforation, facial erythema, UV sensitivity, alopecia, autoimmune thyroiditis	Unknown	Normal	Negative	Inherited p. G207E	Unknown	Unknown
	1 (F), birth	Normal	Unknown	Livedo reticularis, facial erythema, UV sensitivity, skin infections, periodontitis	Unknown	Increased IgE	Negative	Inherited p. G207E	Unknown	Unknown
	1 (F), birth	Normal	Unknown	Livedo reticularis, UV sensitivity, alopecia, autoimmune thyroiditis, periodontitis	Unknown	Increased IgE	Negative	Inherited p. G207E	Radioiodine treatment, thyroid hormone substitution, calcium and vitamin D- replacement therapy	Improved for alopecia
	1 (F), birth	Normal	Unknown	Livedo reticularis, UV sensitivity, alopecia, autoimmune thyroiditis, periodontitis	Unknown	Increased IgE	Negative	Inherited p. G207E	Radioiodine treatment, thyroid hormone substitution, calcium and vitamin D- replacement therapy	Improved for alopecia
Cao <i>et al.</i> , 2019 (19)	1 (M), 2 m	ILD	Yes	Rash	Increased levels of CRP, ESR	Increased IgE, hypergammaglobulinemia IgA,	Negative	<i>de novo</i> p.V155M	Unknown	Unknown
	1 (M), 1 m	ILD	Yes	Telangiectatic skin lesions	Increased levels of CRP, ESR	Increased IgE, hypergammaglobulinemia IgA, decreased IgG and IgM	CCP+	<i>de novo</i> p.N154S	Unknown	Unknown
Clarke <i>et al.</i> , 2020 (20)	1 (F), neonate	ILD	Yes	No	Increased level of CRP	Hypergammaglobulinemia I(IgG, IgA and IgM)	Anti-smooth muscle+	Inherited p.V155M	Methylprednisolone, IVIG, baricitinib	Improved for lung diseases

Table 1 (continued)

Table 1 (continued)

Study, year of publication	Case number (sex distribution), age onset	Lung involvement [number of patients afflicted]	Developmental retardation	Cutaneous and other presentations [number of patients afflicted]	Inflammatory markers	Immune perturbation	Autoantibody profile [number of patients afflicted]	Gene variant [number of patients afflicted]	Treatment	Prognosis
	1 (F), 22 m	ILD	Unknown	Rash	Normal	Hypergammaglobulinemia (IgG, IgA and IgM)	ANA 1:320, RF+	Inherited p.V155M	Oral prednisolone, rituximab, baricitinib	Improved for lung diseases
	1 (F), 16 y	ILD	Unknown	Unknown	Normal	Hypergammaglobulinemia IgA	ANA 1:80/negative, Anti-dsDNA+, RF+	<i>de novo</i> p.V155M	Oral and intravenous steroids	Deceased
Abid <i>et al.</i> , 2020 (21)	1 (M), 4 w	ILD	Yes	Blisters, ulcers, digital ischemia, nephroticrange proteinuria	Increased levels of inflammatory markers	Unknown	Unknown	<i>de novo</i> p.V147L	Ruxolitinib, methylprednisolone	Transient improvement for skin lesions and lung disease
Lin <i>et al.</i> , 2020 (22)	1 (M), 4 w, proband A	ILD	Yes	Maculopapular violaceous rash with a livedoid appearance	Unknown	Unknown	Unknown	p.R281W	Steroids, tofacitinib	Deceased
	1 (M), 18 m (proband A's brother)	Chronic cough	Yes	Unknown	Unknown	Unknown	Unknown	Unknown	Unknown	Deceased
	1 (M), 3 m, proband B	ILD	Unknown	Erythematous rash	Unknown	Unknown	Unknown	p.R281W	Ruxolitinib	Unknown
	1 (M), 6 m (proband B's brother)	Unknown	Unknown	Unknown	Unknown	Unknown	Unknown	p.R281W	Steroids, baricitinib	Unknown
	1 (F), 2 m	ILD, recurrent lung infections and pulmonary hypertension	Unknown	Erythematous rash and polyarthritis	Unknown	Unknown	Unknown	p.R281W	Baricitinib	Clinical improvement, still oxygen dependence
	1 (M), 8 m	Unknown	Yes	Intermittent vasculitic rashes and polyarthritis	Unknown	Unknown	Unknown	p.R281W	Unknown	Unknown

F, female; M, male; m, months; y, years; w, weeks; ILD, Interstitial lung disease; ANA, anti-nuclear antibodies; ANCA, Anti-neutrophil cytoplasmic antibodies; DMARD, Disease modifying anti-rheumatic drugs; CRP, C-reactive protein; ESR, Erythrocyte sedimentation rate; MMF, mycophenolate mofetil; SSA, anti-Sjögren's-syndrome-related antigen A antibodies; TNF α , Tumor necrosis factor- α ; IL-6, Interleukin 6; IL-1 β , Interleukin 1 β ; IgG, Immunoglobulin G; IgA, Immunoglobulin A; IgE, Immunoglobulin E; IgM, Immunoglobulin M; RF, Rheumatoid factor; PR3, anti-proteinase 3 antibodies; B2GLG, anti-beta2 glycoprotein; PL, anti-phospholipid antibodies; PT, anti-prothrombin antibodies; CCP, anti-cyclic citrullinated peptide antibodies; IVIG, Intravenous immune globulin; CTX, cyclophosphamide; UV, ultraviolet; dsDNA, double-stranded deoxyribonucleic acid.

Table 2 Clinical characteristics of the 4 patients with R281Q pathogenic variant reported in the literature and this study

Case	Age onset	Current age	Sex	Cutaneous	Lung	Other systems	Growth retardation	Frequent infection	inflammatory markers	Antibody status	Treatments and prognosis
Previous reported case (4)	3 m	7 y	Female	Early-onset malar rash	ILD, PAH	Necrotizing granulomatous hepatitis	Yes	Pneumonia and skin infections	Elevated	Nil	Limited efficacy with steroids, methotrexate, and anti-TNF- α
Case 1	19 y	37 y	Male	Clubbing fingers, nail, dystrophy of toes	ILD, PAH	No	No	No	Elevated	Multiple positive antibodies	Died 4 months after ruxolitinib treatment
Case 2	2 y	13 y	Male	Malar rash	ILD	Polyarthritis	Yes	No	Elevated	ANA (+)	No improvement in polyarthritis
Case 3	2 y	6 y	Male	Angiotelectasis	ILD	No	Yes	No	Elevated	ANA (+)	Nil

m, months; y, years; ILD, Interstitial lung disease; PAH, pulmonary artery hypertension; ANA, anti-nuclear antibodies; TNF- α , tumor necrosis factor- α .

JAK1 and tyrosine kinase 2 (TYK2), which subsequently results in receptor phosphorylation. This process allows the binding of the DNA-binding proteins signal transducers and activators of transcription 1 (STAT1) and 2 (STAT2) to the receptor, whereupon they become phosphorylated (P). Phosphorylation allows them to dimerize, and the dimer translocates to the nucleus, where it upregulates transcription of interferon-response genes, including interferon regulatory factor 7-dependent transcription of type 1 interferon genes. The synthesis and release of interferons and their binding to interferon receptors further upregulate *STING* and the transcription of other proinflammatory cytokine genes in a positive feedback loop. In our three cases, p.R281Q pathogenic variant in *STING1* activated IFN protein upregulation, which may further stimulate the release of inflammatory cytokines, such as IL-6, IL-1 α , IP-10 and TNF- α . In addition, JAKs itself can directly act on downstream inflammatory effectors of *STING*.

The observed GOF of the *STING* autoactivating and disease-causing mutations was recently “explained” by 2 structural models (22). One model is that the binding of cGAMP to the *STING* dimer leads to a 180° rotation of the ligand-binding domain and further releases inhibitors, such as p. N154S and p.V155M. Another model refers to mutations in the polymer interface (R281 and R284 mutant) directly resulting in inability of inhibitor binding, which

causes *STING* autoactivation. In addition, as the p.Arg281 and p.Arg284 lie on the surface of the protein outside of the *STING* dimerization domain (6), these two mutations induce a conformational change in *STING*, plausibly enabling ER-Golgi trafficking and TBK1/IRF3 phosphorylation in the absence of cGAMP binding. It has been reported that a JAK inhibitor (tofacitinib) failed to inhibit dsDNA-triggered, *STING*-dependent IRF3 phosphorylation in reconstituted cells expressing R284S *in vitro* (13). Volpi *et al.* reported worsening of interstitial disease after transient amelioration in a patient with c.842G>A p. Arg281Gln mutation (2). For the two patients receiving JAK inhibitors in Lin *et al.*'s report (22), one patient exhibited clinical improvement with continued oxygen dependence, and the other patient died of respiratory failure disease despite steroid therapy and short-term treatment with the JAK inhibitor tofacitinib. The above studies may provide some explanations for the observed unsatisfactory response of JAK inhibitors for patients with 281 or 284 mutants; however, there is no robust evidence to support the linkage between the treatment response and mutation type since too few patients have been reported in the literature. It has been reported recently that the stimulation of AMPK activity releases ULK1-mediated phosphorylation of *STING*, which inhibits *STING*'s ability to phosphorylate IRF3. Therefore, ULK1 regulators may be an alternative therapeutic option for

STING-induced inflammatory diseases (13), which should be further studied.

In our case report, the two patients seemed to exhibit poor response to JAK inhibitors ruxolitinib and IFN proteins, and the circulating inflammatory cytokines did not decrease with treatment in case 2. One possible explanation is that the low dose of ruxolitinib may not be sufficient to modulate the expression of the IFN signature, and it cannot be excluded that the non-responsiveness to ruxolitinib might be attributed to a dosing problem. It should also be noted that the measurement of IFN protein with ELISAs may not be sensitive or reliable enough to detect the changes in these biomarkers. In addition, disease severity may also play a role, and the reported variable clinical response to JAK inhibitor therapy may be related to different disease statuses. The limited effects of ruxolitinib, especially in case 1, may be due to advanced ILD/heart failure beyond any therapeutic measures, and an earlier introduction of ruxolitinib may still improve or limit the evolution of SAVI. Further investigation should focus on the early intervention effect of JAK inhibitors in patients with SAVI.

In conclusion, some crucial issues of SAVI require further exploration. Although it has been hypothesized that *STING* gain-of-function pathogenic variants cause disease through type I interferon signaling, the extent to which type I IFNs and IFN-induced genes promote disease manifestations or simply provide a surrogate signature of nucleic acid sensor activation remains controversial. Moreover, the therapeutic effect of JAK inhibitors on different phenotypes and disease statuses of SAVI warrants further investigation.

Acknowledgments

Funding: National Science Foundation for Young Scientists of China: (Grant No. 81700001).

Footnote

Reporting Checklist: The authors have completed the CARE reporting checklist. Available at <http://dx.doi.org/10.21037/atm-20-6198>

Conflicts of Interest: All authors have completed the ICMJE uniform disclosure form (available at <http://dx.doi.org/10.21037/atm-20-6198>). The authors have no conflicts of interest to declare.

Ethical Statement: The authors are accountable for all

aspects of the work in ensuring that questions related to the accuracy or integrity of any part of the work are appropriately investigated and resolved. All procedures performed in studies involving human participants were in accordance with the ethical standards of our institutional ethics committee and with the Helsinki Declaration (as revised in 2013). Written informed consent was obtained from the patient.

Open Access Statement: This is an Open Access article distributed in accordance with the Creative Commons Attribution-NonCommercial-NoDerivs 4.0 International License (CC BY-NC-ND 4.0), which permits the non-commercial replication and distribution of the article with the strict proviso that no changes or edits are made and the original work is properly cited (including links to both the formal publication through the relevant DOI and the license). See: <https://creativecommons.org/licenses/by-nc-nd/4.0/>.

References

1. Liu Y, Jesus AA, Marrero B, et al. Activated *STING* in a vascular and pulmonary syndrome. *N Engl J Med* 2014;371:507-18.
2. Volpi S, Insalaco A, Caorsi R, et al. Efficacy and Adverse Events During Janus Kinase Inhibitor Treatment of SAVI Syndrome. *J Clin Immunol* 2019;39:476-85.
3. Picard C, Thouvenin G, Kannengiesser C, et al. Severe Pulmonary Fibrosis as the First Manifestation of Interferonopathy (TMEM173 Mutation). *Chest* 2016;150:e65-71.
4. Fremont ML, Rodero MP, Jeremiah N, et al. Efficacy of the Janus kinase 1/2 inhibitor ruxolitinib in the treatment of vasculopathy associated with TMEM173-activating mutations in 3 children. *J Allergy Clin Immunol* 2016;138:1752-5.
5. Sanchez GAM, Reinhardt A, Ramsey S, et al. JAK1/2 inhibition with baricitinib in the treatment of autoinflammatory interferonopathies. *J Clin Invest* 2018;128:3041-52.
6. Melki I, Rose Y, Uggetti C, et al. Disease-associated mutations identify a novel region in human *STING* necessary for the control of type I interferon signaling. *J Allergy Clin Immunol* 2017;140:543-52.e5.
7. Omoyinmi E, Melo Gomes S, Nanthapaisal S, et al. Stimulator of interferon genes-associated vasculitis of infancy. *Arthritis Rheumatol* 2015;67:808.
8. Jeremiah N, Neven B, Gentili M, et al. Inherited *STING*-

- activating mutation underlies a familial inflammatory syndrome with lupus-like manifestations. *J Clin Invest* 2014;124:5516-20.
9. Munoz J, Rodière M, Jeremiah N, et al. Stimulator of Interferon Genes-Associated Vasculopathy With Onset in Infancy: A Mimic of Childhood Granulomatosis With Polyangiitis. *JAMA Dermatol* 2015;151:872-7.
 10. Seo J, Kang JA, Suh DI, et al. Tofacitinib relieves symptoms of stimulator of interferon genes (STING)-associated vasculopathy with onset in infancy caused by 2 de novo variants in TMEM173. *J Allergy Clin Immunol* 2017;139:1396-9.e12.
 11. Clarke SL, Pellowe EJ, de Jesus AA, et al. Interstitial Lung Disease Caused by STING-associated Vasculopathy with Onset in Infancy. *Am J Respir Crit Care Med* 2016;194:639-42.
 12. Saldanha RG, Balka KR, Davidson S, et al. A Mutation Outside the Dimerization Domain Causing Atypical STING-Associated Vasculopathy With Onset in Infancy. *Front Immunol* 2018;9:1535.
 13. Konno H, Chinn IK, Hong D, et al. Pro-inflammation Associated with a Gain-of-Function Mutation (R284S) in the Innate Immune Sensor STING. *Cell Rep* 2018;23:1112-23.
 14. Yu ZX, Zhong LQ, Song HM, et al. Stimulator of interferon genes-associated vasculopathy with onset in infancy: first case report in China. *Zhonghua Er Ke Za Zhi* 2018;56:179-85.
 15. Shoman W, El Chazli Y, ElSawy I, et al. First Egyptian patient with STING-associated vasculopathy with onset in infancy. *Scand J Rheumatol* 2019;48:338-9.
 16. Balci S, Ekinici RMK, de Jesus AA, et al. Baricitinib experience on STING-associated vasculopathy with onset in infancy: A representative case from Turkey. *Clin Immunol* 2020;212:108273.
 17. Tang X, Xu H, Zhou C, et al. STING-Associated Vasculopathy with Onset in Infancy in Three Children with New Clinical Aspect and Unsatisfactory Therapeutic Responses to Tofacitinib. *J Clin Immunol* 2020;40:114-22.
 18. Keskitalo S, Haapaniemi E, Einarsdottir E, et al. Novel TMEM173 Mutation and the Role of Disease Modifying Alleles. *Front Immunol* 2019;10:2770.
 19. Cao Y, Jiang LP. The Challenge of Diagnosing SAVI: Case Studies. *Pediatr Allergy Immunol Pulmonol* 2019; 32:167-72.
 20. Clarke SLN, Robertson L, Rice GI, et al. Type 1 interferonopathy presenting as juvenile idiopathic arthritis with interstitial lung disease: report of a new phenotype. *Pediatr Rheumatol Online J* 2020;18:37.
 21. Abid Q, Best Rocha A, Larsen CP, et al. APOL1-Associated Collapsing Focal Segmental Glomerulosclerosis in a Patient With Stimulator of Interferon Genes (STING)-Associated Vasculopathy With Onset in Infancy (SAVI). *Am J Kidney Dis* 2020;75:287-90.
 22. Lin B, Berard R, Al Rasheed A, et al. A novel STING1 variant causes a recessive form of STING-associated vasculopathy with onset in infancy (SAVI). *J Allergy Clin Immunol* 2020;146:1204-8.e6.

Cite this article as: Wang Y, Wang F, Zhang X. STING-associated vasculopathy with onset in infancy: a familial case series report and literature review. *Ann Transl Med* 2021;9(2):176. doi: 10.21037/atm-20-6198