

Virilization caused by ovarian nodular hyperthecosis in a postmenopausal woman

Togas Tulandi MD MHCM, Oriana Hoi Yun Yu MD, Louis-Martin Boucher MD, Lili Fu MD, Jocelyne Arseneau MD

■ Cite as: *CMAJ* 2022 December 12;194:E1647-9. doi: 10.1503/cmaj.220685

A 55-year-old woman (gravida 0) was referred to the endocrine clinic with increasing facial hair necessitating laser removal, acne, deepening of voice and increased libido for more than 1 year. Although menopause had occurred 5 years earlier, she did not have hot flushes. She was not taking any anabolic-androgenic steroids or progestins but was taking candesartan, hydrochlorothiazide and amlodipine for high blood pressure, and levothyroxine for hypothyroidism. On physical examination, she had facial acne, receding hairline and coarse hair on her lip, chin, chest, upper abdomen, lower abdomen, upper arm, forearm, thigh, lower leg, upper back and lower back. Her body mass index was 30. The remainder of her examination, including pelvic examination, was normal.

Initial hormonal evaluation showed an elevated blood total testosterone of 9.3 (normal 0.35–2.7) nmol/L and androstenedione of 11.8 (normal 1.5–10.1) nmol/L. Her sex hormone binding globulin, 17-hydroxyprogesterone and adrenocorticotropic hormone (ACTH) levels were within normal limits. Her follicle-stimulating hormone and luteinizing hormone levels were in the menopausal range. A dexamethasone suppression test showed cortisol at 37 nmol/L after 1 mg dexamethasone (normal response < 50 nmol/L). Repeat testosterone levels confirmed elevated levels (5.96, 7.33 and 8.51 nmol/L). Transvaginal ultrasound and a magnetic resonance imaging (MRI) examination of her abdomen and pelvis showed a small uterine leiomyoma of 11 × 8 × 13 mm, and normal small ovaries. We saw no ovarian tumour or adrenal mass. These results suggested that the source of elevated blood testosterone was her ovaries.

Given the possibility of an androgen-producing tumour in the patient's ovaries

Key points

- In perimenopausal and especially postmenopausal women, rapidly progressing hirsutism and virilization could be a result of ovarian hyperthecosis or androgen-secreting ovarian tumour.
- The incidence of ovarian hyperthecosis, adrenal or androgen-producing ovarian tumour among hyperandrogenic women is less than 1%.
- The diagnosis is made by peripheral blood tests for ovarian and adrenal hormones and imaging and, if possible, with adrenal and ovarian vein blood sampling.
- In young women, unilateral ovarian hyperthecosis can be treated with just unilateral oophorectomy, whereas postmenopausal women are treated with bilateral salpingo-oophorectomy with or without hysterectomy to reduce the incidence of ovarian cancer.

that appeared normal on imaging, we referred her to a reproductive surgeon (T.T.). We also referred her to an interventional radiologist (L.-M.B.), who performed ovarian and adrenal venous blood sampling (Figure 1A). Testosterone levels from her right adrenal, left adrenal and left ovarian vein were 8.26, 13.34 and 46.26 nmol/L, respectively, and from her right ovarian vein were very high (970.56 nmol/L).

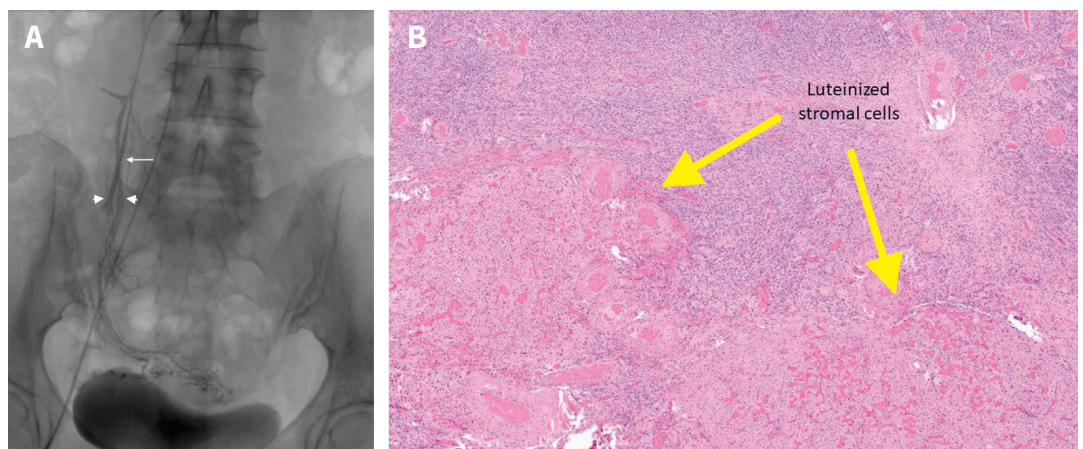


Figure 1: (A) Blood sampling from the right ovarian vein of a 55-year-old woman. White arrowheads: Ovarian veins. White arrow: tip of blood sampling microcatheter. (B) Nodular hyperthecosis: luteinized stromal cells (yellow arrows).

The patient had laparoscopic removal of her uterus and both adnexae. She chose hysterectomy because this would allow her to have estrogen replacement therapy without progesterone, and bilateral salpingectomy would reduce the incidence of epithelial ovarian cancer by half.¹

Her right and left ovaries measured $4.2 \times 1.5 \times 1.3$ cm and $3.8 \times 1.2 \times 0.9$ cm, respectively, within normal limits. Histopathologic examination showed nodular hyperthecosis, with the largest cluster of 1 cm in the right ovary and 0.8 cm in the left ovary (Figure 1B).

Three weeks after surgery, the patient reported improvement of her acne, and her total testosterone level was less than 0.35 nmol/L. She started to have hot flushes and we prescribed 0.06% estradiol gel, 1.25 g/d. Her blood pressure and anti-hypertensive medications remained unchanged. At 6 months' follow-up, her acne had completely disappeared, with just a few remaining facial hairs.

Discussion

Androgens in women are produced by the adrenal glands or ovaries.² The most common cause of hyperandrogenism is polycystic ovarian syndrome, which occurs in women of reproductive age, with only a slight increase of testosterone level and polycystic ovaries seen on imaging. Another possibility is nonclassic congenital adrenal hyperplasia, in which the level of 17-hydroxyprogesterone is elevated.³ Congenital adrenal hyperplasia is found in 1%–2% of premenopausal women with hyperandrogenism.⁴ In our patient, finding a normal level of ACTH with appropriate cortisol suppression after 1 mg dexamethasone ruled out Cushing syndrome. Although rare, an adrenal tumour was a remote possibility, but there was no adrenal abnormality on MRI (Table 1).

By collecting venous blood from the ovaries and adrenal glands, we could determine the source of elevated androgen.⁵ Interventional radiologists may sample the adrenal vein to

detect an aldosterone-producing adrenal adenoma in patients with hypertension.⁶ Gonadal vein blood sampling is not done routinely, although we often cannulate the ovarian veins when treating pelvic congestion syndrome in order to embolize and sclerose the veins.

In perimenopausal and especially postmenopausal women, rapidly progressing hirsutism and virilization may be a result of ovarian hyperthecosis or an androgen-secreting ovarian tumour.⁷ Nests of luteinized theca cells in the ovarian stroma may form distinct nodules, which produce androgen. The affected ovary is usually enlarged, but not always. Unlike ovarian tumours, hyperthecosis is not associated with hypervascularization and, because luteinized stromal cells and normal ovarian stroma have similar consistency, it can be difficult to identify the problem on ultrasound and Doppler ultrasound. Our patient had “normal small ovaries” on ultrasound but, as postmenopausal ovaries are smaller than those in women of reproductive age, they may in fact have been relatively enlarged. The incidence of ovarian hyperthecosis or adrenal or androgen-producing ovarian tumours among hyperandrogenic women is less than 1%.

As testosterone is aromatized to estradiol, our patient experienced menopausal symptoms only after removal of her ovaries. Unopposed elevated estrogen levels increase the risk of endometrial hyperplasia or cancer.⁸ In younger patients, we could treat unilateral ovarian hyperthecosis with unilateral oophorectomy, but patients who are postmenopausal may have bilateral salpingo-oophorectomy with or without hysterectomy, to reduce the incidence of ovarian cancer.

Hirsutism is fairly common. However, virilization or severe hirsutism with evidence of masculinization should be further investigated as it may be a result of adrenal or ovarian tumour. The diagnostic pathway includes peripheral blood tests for ovarian and adrenal hormones, imaging, and adrenal and ovarian blood sampling, if possible.

Table 1: Causes of hirsutism and virilization*

Cause	Clinical feature
Iatrogenic	
Exogenous anabolic-androgenic steroids or progestins	Hirsutism to virilization
Adrenal source	
Congenital adrenal hyperplasia	Hirsutism
Cushing disease	Hirsutism
Androgen-producing adrenal tumour	Virilization
Ovarian source	
Polycystic ovarian syndrome	Hirsutism
Androgen-producing ovarian tumour	Rapidly progressing hirsutism to virilization
Ovarian hyperthecosis	Rapidly progressing hirsutism to virilization

*Virilization is severe hirsutism with evidence of masculinization.

References

1. Yoon SH, Kim SN, Shim SH, et al. Bilateral salpingectomy can reduce the risk of ovarian cancer in the general population: a meta-analysis. *Eur J Cancer* 2016; 55:38-46.
2. Ala-Fossi SL, Mäenpää J, Aine R, et al. Ovarian testosterone secretion during perimenopause. *Maturitas* 1998;29:239-45.
3. Moran C, Azziz R, Carmina E, et al. 21-Hydroxylase-deficient nonclassic adrenal hyperplasia is a progressive disorder: a multicenter study. *Am J Obstet Gynecol* 2000;183:1468-74.
4. Dennedy MC, Smith D, O'Shea D, et al. Investigation of patients with atypical or severe hyperandrogenaemia including androgen-secreting ovarian teratoma. *Eur J Endocrinol* 2010;162:213-20.
5. Dickerson RD, Putman MJ, Black ME, et al. Selective ovarian vein sampling to localize a Leydig cell tumor. *Fertil Steril* 2005;84:218.
6. Duan L, Yang Y, Gu Y, et al. The utility of adrenal and ovarian venous sampling in a progesterone-producing adrenal tumor and review of the literature. *Endocrine* 2019;66:319-25.
7. Meczekalski B, Szeliga A, Maciejewska-Jeske M, et al. Hyperthecosis: an underestimated nontumorous cause of hyperandrogenism. *Gynecol Endocrinol* 2021;37:677-82.
8. Yamada S, Tanimoto A, Wang K-Y, et al. Stromal luteoma and nodular hyperthecosis of the bilateral ovaries associated with atypical endometrial hyperplasia of the uterus. *Pathol Int* 2009;59:831-3.

Competing interests: Oriana Hoi Yun Yu reports participating in a consultancy meeting for Rybelsus (outside the submitted work). No other competing interests were declared.

This article has been peer reviewed.

The authors have obtained patient consent.

Affiliations: Departments of Obstetrics and Gynecology (Tulandi), Medicine (Yu), Radiology (Boucher) and Pathology (Fu, Arseneau), McGill University, Montréal, Que.

Contributors: All of the authors contributed to the conception and design of the work. Togas Tulandi drafted the manuscript. All of the authors revised it critically for important intellectual content, gave final approval of the version to be published and agreed to be accountable for all aspects of the work.

Content licence: This is an Open Access article distributed in accordance with the terms of the Creative Commons Attribution (CC BY-NC-ND 4.0) licence, which permits use, distribution and reproduction in any medium, provided that the original publication is properly cited, the use is noncommercial (i.e., research or educational use), and no modifications or adaptations are made. See: <https://creativecommons.org/licenses/by-nc-nd/4.0/>

Correspondence to: Togas Tulandi, togas.tulandi@mcgill.ca

The section Cases presents brief case reports that convey clear, practical lessons. Preference is given to common presentations of important rare conditions, and important unusual presentations of common problems. Articles start with a case presentation (500 words maximum), and a discussion of the underlying condition follows (1000 words maximum). Visual elements (e.g., tables of the differential diagnosis, clinical features or diagnostic approach) are encouraged. Consent from patients for publication of their story is a necessity. See information for authors at www.cmaj.ca.