



## Case report

## Langerhans cell histiocytosis of the rib in an adult: A case report and review of the literature

Shengliang Zhao, Chao Luo, Bo Tang, Liang Chen, Mingzhang Xiang, Jigang Dai, Hua Li<sup>\*</sup>

Department of Thoracic Surgery, Xinqiao Hospital, Army Medical University (Third Military Medical University), Chongqing 400037, China



## ARTICLE INFO

## Keywords:

Langerhans cell histiocytosis  
Rib  
Tumorous lesion  
Biopsy

## ABSTRACT

**Introduction and importance:** Langerhans cell histiocytosis (LCH) is a rare neoplastic hyperplasia with an unknown etiology. It is clinically rare for patients with solitary rib lesion and pathological fracture. In this article, we report a case of LCH in solitary involvement of rib and provide a review of the available literature.

**Case presentation:** A 24-year-old female patient complained of right chest and back pain for 10 days. CT showed a fracture in the right 6th rib. Findings on X-ray, and CT were suggestive of homogeneous osteolytic lesion of the right 6th rib. The rib tumor was then resected and the surrounding muscles and soft tissues were accordingly resected.

**Clinical discussion:** The patient was diagnosed with pathological rib fracture, and the patient was pathologically diagnosed with LCH. After surgery, no local recurrence or distant metastasis was reported during the one-year follow-up.

**Conclusions:** Most of the solitary tumorous lesions in rib in adults call for various differential diagnoses. Although single-site, single-system LCH of the rib is one of the rarest causes of bone tumor in adults, it can be treated successfully with surgical intervention. LCH should be considered in the diagnosis of an adult patient with a rib mass.

## 1. Introduction

Langerhans cell histiocytosis (LCH), known as eosinophilic granuloma of bone, is a rare neoplastic hyperplasia having an unknown etiology. LCH has a highly variable clinical presentation, ranging from a single lesion to potentially fatal disseminated disease. It is clinically rare for patients with solitary rib lesion and pathological fracture, and its diagnosis and treatment are quite difficult. In this study, we report a patient with LCH presenting with pathological rib fracture. This article has been reported in line with the SCARE criteria [1].

## 2. Case presentation

A 24-year-old female patient complained of right chest and back pain for 10 days. The patient had no history of trauma or other diseases. Physical examination indicated slight tenderness in the right back and normal breathing sounds in both lungs. Outpatient chest computed tomography (CT) showed local decrease in bone mineral density and partial bone destruction, and thickening of adjacent chest wall soft

tissue, which could not rule out the possibility of pathological fractures (Fig. 1a). Thus, relevant examinations were performed. PET-CT presented abnormal radio active concentrations in the right 6th rib (Fig. 1b). Three-dimensional reconstruction of the rib showed bone destruction and defect of the right sixth posterior rib (Fig. 1c). No abnormalities were then revealed on the head magnetic resonance imaging (MRI) or color doppler ultrasound of the liver, gallbladder, pancreas, and spleen. The patient was diagnosed with the right 6th rib lesion. Because of the reduced effect that surgical resection had on respiratory function, the rib tumor was resected and surrounding muscles and soft tissues were accordingly resected. Postoperative pathology indicated massive Langerhans cell infiltration (Fig. 2a, b). Immunohistochemistry demonstrated CD1a (+) and S-100 (+). Therefore, the patient was diagnosed with LCH, after surgery, no local recurrence or distant metastasis was reported during the one-year follow-up.

## 3. Discussion

Langerhans cell histiocytosis (LCH) refers to a group of diseases of

<sup>\*</sup> Corresponding author at: No. 183, Xinqiaozheng Street, Shapingba District, Chongqing, China.

E-mail address: [zhaosl0312@sina.com](mailto:zhaosl0312@sina.com) (H. Li).

<https://doi.org/10.1016/j.ijscr.2022.107432>

Received 28 May 2022; Received in revised form 14 July 2022; Accepted 17 July 2022

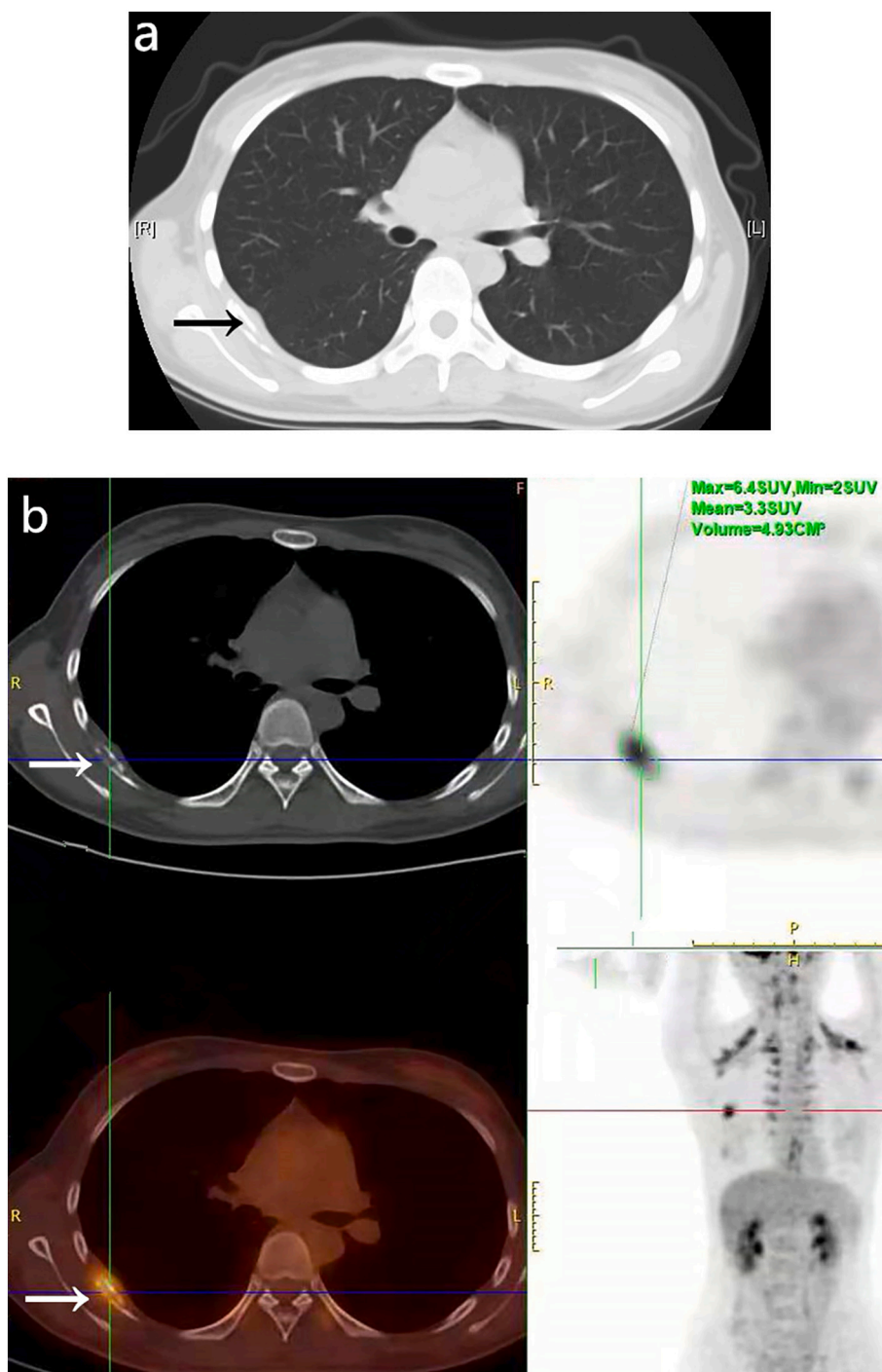
Available online 21 July 2022

2210-2612/© 2022 Published by Elsevier Ltd on behalf of IJS Publishing Group Ltd. This is an open access article under the CC BY-NC-ND license (<http://creativecommons.org/licenses/by-nc-nd/4.0/>).

unknown etiology that manifest as the proliferation and accumulation of Langerhans cells in damaged organs. The disease can manifest in one or more organ systems, including bones, lungs, pituitary gland, mucous membranes, skin, lymph nodes, and liver. The disease is also known as histiocytosis X and eosinophilic granuloma. Pulmonary involvement is commonly observed in 40 % of patients diagnosed with LCH, which can present in either a single lung or in multiple organs. In patients with multiple organ damage, the most commonly affected sites include bones and the pituitary gland [2,3]. As for bones, the skull, long bone, and flat bone are the most susceptible. The mortality rate of patients with

multiorgan LCH is 10–20 % [4]. LCH is the most common histiocytic disorder in children, with a prevalence of approximately 5–9 cases per 1 million children under the age of 15 years [5,6]. Whether LCH represents a benign neoplasm, cancer, or an immune disorder remains under debate, and the underlying pathogenic mechanism remains unclear. Recent findings of a mutation in BRAF [7] and MAP2K1 [8] have led to the assumption of its neoplastic origin, at least in some subgroups.

The clinical manifestations of LCH are nonspecific, and this lack of specificity makes its diagnosis difficult. In this case, the patient had no clinical symptoms in the early stage, and radiated pain in the chest and



**Fig. 1.** a. CT showed local decrease in bone mineral density and partial bone destruction, and thickening of adjacent chest wall soft tissue.  
 b. PET-CT presented abnormal radio active concentrations in the right 6th rib.  
 c. Three-dimensional reconstruction of the rib showed bone destruction and defect of the right sixth posterior rib.

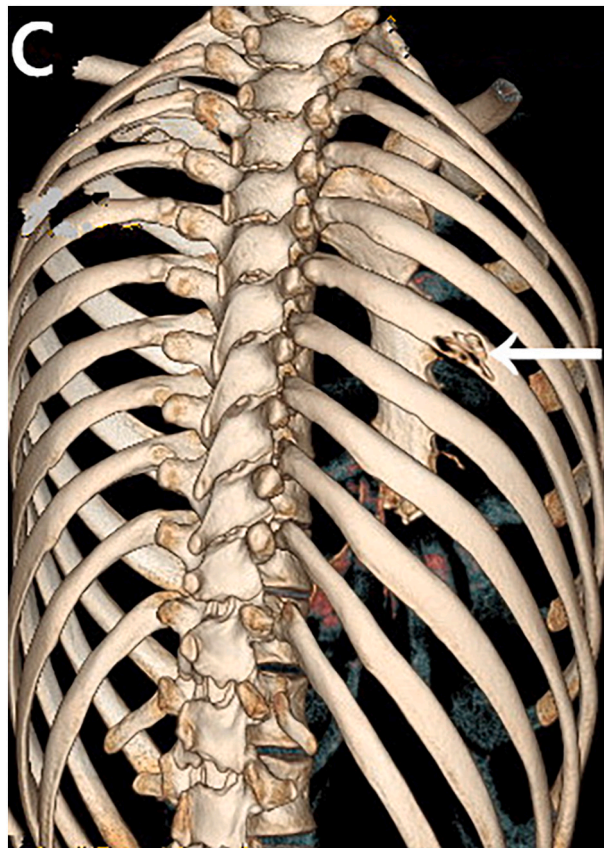


Fig. 1. (continued).

back after the rib fracture. Pathological fracture was considered in the early diagnosis of this case, and we did not give special treatment, which delayed the treatment of the patient. At the same time, the differential diagnosis should also include osteomyelitis; benign tumors, such as chondroma and osteochondroma; malignancies such as Ewing's sarcoma, osteosarcoma, lymphoma and leukemia. Utilization of PET-CT for LCH has been reported in a number of studies, and efficacy has been shown for overall disease extension and posttreatment assessment. It is superior to bone scintigraphy, where only 35 % of the cases are detected, but it does not lead to a definitive diagnosis [9]. However, once LCH is considered as a possibility, the diagnosis can then be confirmed by biopsy.

In general, the treatment methods of LCH include follow-up, intrathecal steroid injection, chemotherapy or radiotherapy, and surgical resection [10]. In terms of surgery, most of the surgical methods are removing the affected soft tissue, bone and appropriately rebuilding the defect [11]. A study has demonstrated that only 2 of 61 patients with LCH of single bone had a recurrence after surgical resection [12]. Another study has demonstrated that the four-year survival rate of patients with LCH of single bone is >90 % [13].

#### 4. Conclusions

Most of the solitary tumorous lesions in rib in adults call for various differential diagnoses. Although single-site, single-system LCH of the rib is one of the rarest causes of bone tumor in adults, it can be treated successfully with surgical intervention. LCH should be considered in the diagnosis of an adult patient with a rib mass.

#### Consent for publication

Not applicable.

#### Availability of data and materials

The datasets used and analyzed during the current study are available from the corresponding author upon reasonable request.

#### Ethical approval

The Medical Research Ethics Committee of Xinqiao Hospital, Army Medical University approved the study, and this study obtained written informed consent from the families of patient.

#### Funding

Not applicable.

#### Guarantor

Sheng liang Zhao and Hua Li are the guarantors.

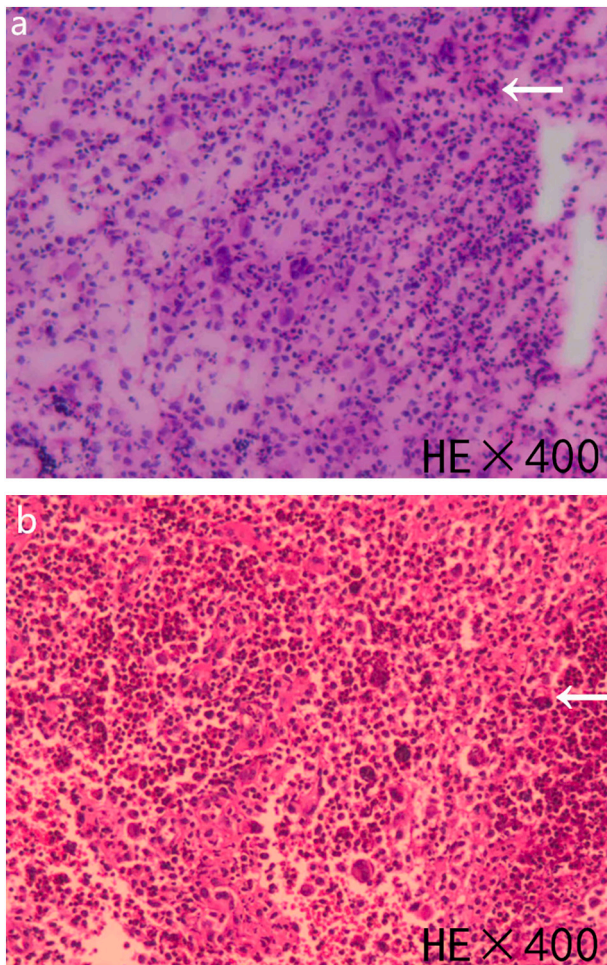
#### Research registration number

No.

#### CRediT authorship contribution statement

LH and ZSL analyzed and interpreted the patient data regarding Langerhans Cell Histiocytosis. LC, CL, and TB were responsible for part of the design of the paper. XMZ, DJG, ZSL, and LH performed for the surgery. ZSL and LH were major contributors in writing the manuscript. All authors read and approved the final manuscript.





**Fig. 2.** a, b. Postoperative pathology indicated massive Langerhans cell infiltration.

#### Declaration of competing interest

The authors declare that they have no competing interests.

#### Acknowledgments

Not applicable.

#### References

- [1] R.A. Agha, T. Franchi, C. Sohrabi, G. Mathew, for the SCARE Group, The SCARE 2020 guideline: updating consensus Surgical Case REport (SCARE) guidelines, *International Journal of Surgery* 84 (2020) 226–230.
- [2] W. Richard Webb, C.B. Higgins, in: *Thoracic Imaging: Pulmonary and Cardiovascular Radiology 3 E*, Wolter Kluwer, 2017, pp. 645–657.
- [3] W. Richard Webb, N.L. Muller, D.P. Naidich, in: *High – Resolution CT of the Lung 5 E*, Wolter Kluwer, 2015, pp. 492–516.
- [4] S.H. Kim, M.Y. Choi, Langerhans cell histiocytosis of the rib in an adult: a case report, *Case Rep. Oncol.* 9 (1) (2016) 83–88.
- [5] A. Guyot-Goubin, J. Donadieu, M. Barkaoui, et al., Descriptive epidemiology of childhood langerhans cell histiocytosis in France, 2000–2004, *Pediatr. Blood Cancer* 51 (1) (2008) 71–75.
- [6] H. Stålemark, E. Laurencikas, J. Karis, et al., Incidence of langerhans cell histiocytosis in children: a population-based study, *Pediatr. Blood Cancer* 51 (1) (2008) 76–81.
- [7] G. Badalian-Very, J.A. Vergilio, B.A. Degar, L.E. MacConaill, B. Brandner, M. L. Calicchio, F.C. Kuo, A.H. Ligon, K.E. Stevenson, S.M. Kehoe, L.A. Garraway, W. C. Hahn, M. Meyerson, M.D. Fleming, B.J. Rollins, Recurrent BRAF mutations in langerhans cell histiocytosis, *Blood* 116 (2010) 1919–1923.
- [8] N.A. Brown, L.V. Furtado, B.L. Betz, M.J. Kiel, H.C. Weigelin, M.S. Lim, K. S. Elenitoba-Johnson, High prevalence of somatic MAP2K1 mutations in BRAF V600E-negative langerhans cell histiocytosis, *Blood* 124 (2014) 1655–1658.
- [9] M. Phillips, C. Allen, P. Gerson, K. McClain, Comparison of FDG-PET scans to conventional radiography and bone scans in management of langerhans cell histiocytosis, *Pediatr. Blood Cancer* 52 (2009) 97–101.
- [10] J. Braier, D. Rosso, D. Pollono, et al., Symptomatic bone langerhans cell histiocytosis treated at diagnosis or after reactivation with indomethacin alone, *J Pediatric Hematol/Oncol.* 36 (5) (2014), 280e284.
- [11] Hwan Park Tae, Kim June-kyu, Yun Oh. Tae, Joo Park Yun, Solitary Langerhans cell histiocytosis arising from sternum: a case report, *J Pediatr Surg.* 49 (1) (2012), e9ee12.
- [12] R.F. Jubran, A. Marachelian, F. Dorey, M. Malogolowkin, Predictors of outcome in children with Langerhans cell histiocytosis, *Pediatr Blood Cancer* 45 (37–42) (2005) 11. Wester SM, Beabout JW.
- [13] K.K. Unni, D.C. Dahlin, Langerhans' cell granulomatosis (histiocytosis X) of bone in adults, *Am. J. Surg. Pathol.* 6 (1982) 413–426.