

How to manage lung infiltrates in adults suffering from haematological malignancies outside allogeneic haematopoietic stem cell transplantation

Georg Maschmeyer¹ and J. Peter Donnelly²

¹Department of Haematology, Oncology and Palliative Care, Klinikum Ernst von Bergmann, Potsdam, Germany and ²Department of Haematology, Radboud University Medical Centre, Nijmegen, The Netherlands

Summary

Pulmonary complications affect up to 40% of patients with severe neutropenia lasting for more than 10 d. As they are frequently associated with fever and elevation of C-reactive protein or other signs of inflammation, they are mostly handled as pneumonia. However, the differential diagnosis is broad, and a causative microbial agent remains undetected in the majority of cases. Pulmonary side effects from cytotoxic treatment or pulmonary involvement by the underlying malignancy must always be taken into account and may provide grounds for invasive diagnostic procedures in selected patients. *Pneumocystis jirovecii* (in patients not receiving co-trimoxazole as prophylaxis), multi-resistant gram-negative bacilli, mycobacteria or respiratory viruses may be involved. High-risk patients may be infected by filamentous fungi, such as *Aspergillus* spp., but these infections are seldom proven when treatment is initiated. Microorganisms isolated from cultures of blood, bronchoalveolar lavage or respiratory secretions need careful interpretation as they may be irrelevant for determining the aetiology of pulmonary infiltrates, particularly when cultures yield coagulase-negative staphylococci, enterococci or *Candida* species. Non-culture based diagnostics for detecting *Aspergillus* galactomannan, beta-D-glucan or DNA from blood, bronchoalveolar lavage or tissue samples can facilitate the diagnosis, but must always be interpreted in the context of clinical and imaging findings. Systemic antifungal treatment with mould-active agents, given in combination with broad-spectrum antibiotics, improves clinical outcome when given pre-emptively. Co-trimoxazole remains the first-line treatment for *Pneumocystis* pneumonia, while cytomegalovirus pneumonia will respond to ganciclovir or foscarnet in most cases. The clinical outcome of acute res-

piratory failure can also be successful with proper intensive care, when indicated.

Keywords: lung infiltrates, pneumonia, neutropenia, fever, diagnosis.

Epidemiology of pulmonary complications in patients with haematological malignancies

Respiratory symptoms or signs such as dyspnoea, cough, sputum, chest pain, rales, haemoptysis, impaired oxygenation and/or pulmonary infiltrates on chest radiographs (CXR) or computerized tomography (CT) scans are frequent among patients with haematological malignancies (HM). Up to 30% of patients undergoing chemotherapy for acute leukaemia may be affected (Chaoui *et al*, 2004; Garcia *et al*, 2013), particularly those with pre-existing pulmonary disease and those who smoke. Around 12–15% of severely neutropenic patients with first fever will present with lung infiltrates (LI) (Maschmeyer *et al*, 1994), and half of patients without abnormalities on CXR, who remain febrile after at least 48 h of broad-spectrum antibacterial treatment, will show LI on pulmonary CT scans (Heussel *et al*, 1999). Respiratory complications are also frequent among patients with chronic lymphocytic leukaemia, and often run a complicated clinical course due to the complex immunodeficiency. Respiratory events (RE) affect less than 1 in 10 of autologous stem cell transplant recipients (Reich *et al*, 2001). However, this proportion may be as high as 15%, particularly among patients with myeloma who experience 7 or more days of severe neutropenia with a substantial associated mortality.

Typically, publications on the causes of LI are based upon clinical data, imaging procedures and microbiological findings. Garcia *et al* (2013) retrospectively analysed the clinical course of over 800 patients undergoing chemotherapy for acute myeloid leukaemia (AML; *n* = 645), acute lymphoblastic leukaemia (ALL; *n* = 121) or high-risk myelodysplastic syndrome (MDS; *n* = 35) undergoing chemotherapy at their institution between 2005 and 2009. They found a pre-treatment

Correspondence: Georg Maschmeyer, Department of Haematology, Oncology and Palliative Care, Klinikum Ernst von Bergmann, Charlottenstr. 72, D-14467 Potsdam, Germany.
E-mail: gmaschmeyer@klinikumebv.de

prevalence of pneumonia of 11% and the occurrence of pneumonia in further 21%, with an overall fatality rate of 17%. The cumulative incidence was highest among patients with MDS (29.4%) and intermediate in AML patients (21.6%). Patients with pneumonia also had a much higher overall 33-d mortality (>20%) than did those without pneumonia (<5%).

In a small series of 65 patients with *de novo* or secondary acute leukaemias, Chaoui *et al* (2004) identified 30 (46%) with respiratory events. Cardiac failure was the predominant non-infectious cause, while aspergillosis and bacterial pneumonia due to gram-negative bacilli were the main causes of LI with an infectious origin. The majority of RE occurred within 10 d of leukaemia diagnosis, and the outcome of the affected patients was significantly poorer than for those patients without RE (Chaoui *et al*, 2004).

Over 9 years, RE among patients with chronic lymphocytic leukaemia was associated with a poor prognosis and a fatality rate of 40% (Ahmed *et al*, 2003). A quarter of these complications were not caused by pneumonia, but by pleural effusion or lung infiltration by the underlying malignancy (9%), pulmonary leucostasis (4%), secondary malignancies, aggressive transformation (Richter syndrome) (3%) or bronchial obstruction (2%). With respect to prognosis, granulocytopenia and renal failure had an unfavourable impact on clinical outcome.

Histopathological findings are only available in a minority of cases, and may show a variety different causes of LI, including fungi, alveolar bleeding, infiltration by the underlying malignancy, cryptogenic organizing pneumonia, immune reconstitution syndrome and lung damage from chemotherapy or radiation (Shorr *et al*, 2004; Camus & Costabel, 2005). Drug-induced LI should also be kept in mind, however, only a small number of chemotherapeutic agents are likely to cause LI among the febrile neutropenic patients discussed here, e.g., all-trans retinoic acid (ATRA), BCNU (carmustine), bleomycin, cyclophosphamide, high-dose cytosine arabinoside, etoposide, gemcitabine, fludarabine, melphalan or methotrexate.

Lung infiltrates due to leucostasis or leukaemic infiltration of the lungs

Some newly diagnosed acute leukaemia patients present with fever and LI, occasionally requiring immediate intensive care (Chaoui *et al*, 2004; Darmon *et al*, 2005). These patients are particularly challenging, because it is unclear if the infiltrates are due to pulmonary involvement of leukaemia or to an infection resulting from the underlying immunosuppression (Koh *et al*, 2005). In cases where an informative lung biopsy (or autopsy) has been obtained, leukaemic infiltration along the lymphatics in the peribronchovascular, septal, and pleural interstitial tissue represents the typical pattern (Koh *et al*, 2005), and the majority of patients affected do not have pulmonary leucostasis caused by hyperleucocytosis (Potenza *et al*, 2003). An acute lysis pneumopathy associated with

diffuse alveolar damage may occur during or shortly following the initiation of cytotoxic chemotherapy (Tryka *et al*, 1982).

ATRA syndrome (differentiation syndrome)

The differentiation syndrome in patients with acute promyelocytic leukaemia (APL) treated with all-trans retinoic acid (ATRA syndrome) will not be addressed here in detail. It may be associated with fever in up to 80% of patients, but does not typically occur in the setting of fever and severe neutropenia (Luesink & Jansen, 2010). It is primarily induced by chemokines released from differentiating APL cells and is not managed with antimicrobial therapy, but glucocorticosteroids.

Lung infiltrates in severely neutropenic patients with fever

Lung infiltrates may be found in up to 30% of febrile neutropenic patients. Conventional CXR of patients with first fever in neutropenia may miss LI, while pulmonary CT scans obtained under the same circumstances most probably will show LI in a larger proportion of patients (Heussel *et al*, 1999). These LI are more likely to prove fatal as compared with other documented infections in febrile neutropenic patients (Maschmeyer *et al*, 1994) and their treatment is more complex and costly (Kuderer *et al*, 2006; Garcia *et al*, 2013). Clinical outcome deteriorates with increasing patient age and is particularly dismal for patients with bacteraemia and shock, especially when appropriate antimicrobial treatment is delayed (Carratalà *et al*, 1998).

A favourable clinical response to antibacterial treatment is achieved in less than 1 in 3 patients with pulmonary infiltrates during febrile neutropenia (Maschmeyer *et al*, 1994; Raad *et al*, 1996) with a high fatality rate (Al Ameri *et al*, 2010), while the addition upfront of mould-active systemic antifungals, such as amphotericin B or voriconazole, increases the response rate to up to 78% (Schiel *et al*, 2006). Additional findings indicate that the majority of LI among severely neutropenic patients are caused by filamentous fungi, particularly *Aspergillus* spp., including a reduction in the incidence of LI in a small study of voriconazole prophylaxis in patients with acute leukaemia (Vehreschild *et al*, 2007), histopathological and molecular findings (Lass-Flörl *et al*, 2007) and autopsy studies (Chamilos *et al*, 2006).

Lung infiltrates among patients who have been treated with nucleoside analogues, such as fludarabine, may involve a range of microorganisms, such as cytomegalovirus, mycobacteria or yeasts, that are more typically observed during prolonged T cell suppression (Samonis & Kontoyiannis, 2001) as well as *Staphylococcus aureus*, *Pseudomonas aeruginosa*, *Aspergillus* spp. and pneumococci (Ahmed *et al*, 2003).

Respiratory viruses, including Influenza A and Respiratory Syncytial Virus (RSV), have occasionally been identified as causes of pulmonary infiltrates in hospitalized, febrile

neutropenic adults (Martino *et al*, 2003), predominantly during wintertime. However, at least during febrile neutropenia, virological diagnostic tests are seldom ordered because of uncertainty about their relevance and the lack of effective agents to treat these infections. The vast majority of RSV infections occur among haematopoietic stem cell transplant recipients, while reports on viral pneumonia in other patients mainly involve out-patients and show conflicting results with regard to their clinical importance (Lehners *et al*, 2013). Human metapneumovirus (hMPV) was identified in the early 2000s and affects up to 9% of adult patients with HM and symptoms of respiratory tract infection (Williams *et al*, 2005), but the outcome tends to be favourable despite the absence of effective anti-hMPV antivirals (Godet *et al*, 2014). However, a recent outbreak of pulmonary hMPV infections among haematology patients was associated with fatality rate of 4 out of 15 patients (27%) (Hoellein *et al*, 2015).

What imaging technique should I order?

Conventional CXR show abnormalities in less than 2% of febrile neutropenic patients who have no obvious clinical signs or symptoms lower respiratory tract infection (Navigante *et al*, 2002; Oude Nijhuis *et al*, 2003). It is not unreasonable to assume that many more of these patients would have abnormalities detected on CT scans, but no prospective randomized studies to compare the yield of CT scan *versus* CXR have been conducted. However, among neutropenic patients with fever persisting despite more than 48 h of broad-spectrum antibacterial therapy, only about 10% of CXR show abnormalities, while high-resolution CT scans taken at the same time show pathological findings in approximately 50% of patients (Heussel *et al*, 1999). Abnormalities seen on CXR indicate a CT scan should be done to more specifically identify the most likely aetiology. Hence, a CXR is of very limited value, as a pulmonary CT scan (without contrast media) must be ordered anyway as soon as possible, preferably as part of the investigation of fever during neutropenia.

Is the pattern of lung infiltrates on pulmonary CT scans informative for differential diagnosis?

Detecting LI on CT scan has three prognostically important consequences:

- The early detection of lesions indicating invasive mould disease or *Pneumocystis* pneumonia (PcP) facilitates targeted bronchoalveolar lavage (BAL) and prompt institution of pre-emptive antimicrobial treatment, resulting in improved survival of these patients (Guo *et al*, 2014);
- CT findings, such as consolidation, small nodules with or without a typical or reversed 'halo sign' and 'air-crescent sign', may be important signs of filamentous fungal disease. The 'halo sign', i.e., a dense nodular infiltrate

surrounded by an area of ground-glass opacity representing an infarction and a haemorrhage, has been described as characteristic for neutropenic patients with invasive pulmonary aspergillosis (IPA) (Bruno *et al*, 2007). The 'reversed halo sign', showing a focal rounded area of ground-glass opacity surrounded by a crescent or complete ring of consolidation, has been reported to be relatively specific for fungal pneumonia due to mucormycosis (Georgiadou *et al*, 2011; Legouge *et al*, 2014). However, it also may also be associated with other lung diseases, such as tuberculosis, sarcoidosis, or cryptogenic organizing pneumonia (Godoy *et al*, 2012);

- The pattern of LI on the CT scan may also help to distinguish fungal from other aetiologies of LI (Caillot *et al*, 1997; Heussel *et al*, 2004). PcP typically causes diffuse perihilar infiltrates, areas of ground-glass attenuation, cysts and septal thickening, consolidation and centrilobular nodules (Kanne *et al*, 2012; Vogel *et al*, 2012). However, this 'classical PcP pattern' has also been described for LI from acute leukaemia (Potenza *et al*, 2003). Nodular or cavitory lesions indicate an invasive 'mould' disease, while differential diagnoses include pneumonia caused by other microorganisms, such as mycobacteria (in patients from high prevalence areas), *Nocardia*, *Pneumocystis jirovecii* or *Pseudomonas aeruginosa* and infiltrates by the underlying malignancy (Shorr *et al*, 2004).

Combining CT scan with angiography has been reported to increase the diagnostic specificity in some cases with suspected pulmonary mould diseases (Stanzani *et al*, 2015), because vessel occlusion is better seen than with native scans. However, this procedure is not only more labour-intensive, but is also more burdensome for the patients due to the use of contrast media, and its added value to other CT findings has not yet been established. Magnetic resonance tomography (MRI) may be an alternative to a CT scan, but it appears to be inferior to CT in visualizing ground-glass opacities (Attenberger *et al*, 2014).

Follow-up CT scans should usually only be ordered after at least 7 d have elapsed after starting antimicrobial therapy, because otherwise, the course of LI may be misinterpreted. Patients with invasive pulmonary aspergillosis may show increasing LI volumes during the first week despite effective antifungal therapy (Caillot *et al*, 2001). This may create a false impression that the current antifungal medication is ineffective and should be changed. A regression of the 'halo' sign and the appearance of an 'air-crescent' sign, however, usually indicate a favourable response (Brodoefel *et al*, 2006).

Can I make a microbiological diagnosis? How useful is it to order a prompt bronchoscopy?

The microbiological aetiology is never established in the majority of febrile neutropenic patients with LI. Microbiolog-

ically documented cases are frequently based upon findings from bronchial secretions or BAL fluid and even blood cultures obtained contemporaneously. The diagnostic relevance of these culture results, however, is often difficult to assess (Boersma *et al*, 2007; Azoulay *et al*, 2008), because bronchial samples from these patients may contain microorganisms that have no aetiological significance, such as *Candida* species, coagulase-negative staphylococci, viridans streptococci and enterococci. Moreover, bacteraemia due to these bacteria seldom, if ever, results in pneumonia. At the same time, as many as 3 of 4 cases of invasive fungal disease found at autopsy had not been detected *ante mortem* (Chamilos *et al*, 2006). By contrast, isolation of *Aspergillus* spp. or other filamentous fungi from oropharyngeal or upper respiratory tract specimens from severely immunocompromised patients is regarded as a sign of pulmonary mould infection (Perfect *et al*, 2001).

The importance of bronchoscopy and BAL among febrile neutropenic patients with LI is controversial. The diagnostic yield is low and the clinical outcome of these patients has not yet been shown to be improved by invasive diagnostic procedures including BAL (Azoulay *et al*, 2010). However, a detection rate of 25% has been reported for potential pathogens in BAL samples from patients with cancer (Jain *et al*, 2004; Boersma *et al*, 2007), with bacteria accounting for about a third of them, *P. jirovecii* for 15% among patients not receiving co-trimoxazole prophylaxis, and filamentous fungi, predominantly *Aspergillus* spp., for 5–10%. There is no diagnostic 'gold standard' (as biopsy is seldom justified) so it is impossible to estimate the number of false-positive and false-negative findings in BAL samples, and the benefit or failure of 'pathogen-directed' antimicrobial treatment therefore remain obscure. A list of microorganisms that should generally be regarded as irrelevant for the aetiology of LI is given in Table I.

Do non-culture based diagnostic methods (antigen detection, polymerase chain reaction) help?

Cytomegalovirus (CMV) and respiratory viruses

Respiratory viruses may be the cause of LI among patients with profound cellular immunosuppression, so BAL and nasopharyngeal and oral swabs should include investigations for CMV, Influenza, Parainfluenza, RSV, Coronavirus, Rhinovirus and hMPV (Williams *et al*, 2005; Hirsch *et al*, 2013). CMV polymerase chain reaction (PCR) is recommended for BAL samples from febrile neutropenic patients with LI, as the test has a high negative predictive value, so CMV can be excluded. However, the positive predictive value is low (Hohenthal *et al*, 2005), so rapid culture, immediate early antigen, direct fluorescent antibody tests, DNA hybridization or cytology is required to confirm the diagnosis of CMV pneumonia (Boeckh, 2011).

Table I. Microbiological findings generally not aetiologically relevant for lung infiltrates.

1	Any microorganism isolated from skin, faeces or urine cultures*
2	From any specimen
	i Coagulase-negative staphylococci
	ii Viridans streptococci
	iii Enterococci
	iv Coryneform bacteria
3	Isolates from specimens from skin, saliva, sputum or tracheal aspirates
	i <i>Candida</i> spp.†

*Recent recovery, by culture of highly resistant bacteria, such as extended-spectrum beta-lactamase producing gram-negative bacilli, may have an impact on the selection of the appropriate antibacterial agent.

†*Candida* spp. isolated from skin biopsies of septic patients indicates invasive candidiasis, which may be associated with haematogeneous dissemination to the lungs.

Pneumocystis jirovecii

Microscopy has been the classical reference method for detecting *P. jirovecii*, but this has largely been replaced by PCR for early detection as it exhibits high sensitivity. It is essential to distinguish infection from colonization as this may affect over half of individuals without any signs or symptoms of PcP (Ponce *et al*, 2010). Meta-analysis of PCR showed the test to exhibit both high sensitivity (99%) and specificity (90%) (Lu *et al*, 2011). Hence, a negative test result on a BAL sample indicates that anti-Pneumocystis therapy is unnecessary. More recently, quantitative PCR assays have been shown to boost the specificity. A report on non-HIV 71 patients with proven PcP showed a positive predictive value of 98% when more than 1450 organisms per ml were detected in BAL samples (Mühlethaler *et al*, 2012), however, this threshold has not yet been prospectively evaluated in clinical studies, and in individual patients with severe PcP, a much lower copy number may be present. Determining beta-D-glucan in serum can also help in the differential diagnosis, because a negative result effectively rules out a diagnosis of PcP (Karageorgopoulos *et al*, 2013).

Filamentous fungi

Numerous methods have been developed for detecting fungal cell antigens, such as *Aspergillus* galactomannan (GM), 1,3-beta-D-glucan and nuclear amplification assays including PCR, to identify fungal DNA for the early detection of filamentous fungi in febrile neutropenic patients with LI of undetermined aetiology (Maertens *et al*, 1999; Spiess *et al*, 2003). Currently, an optical density (OD) index >0.5 from blood samples is regarded as the threshold for detecting GM, whereas a cut-off of ≥ 1.0 is more appropriate for BAL

samples (Zou *et al*, 2012), as this indicates probable invasive fungal disease in severely immunocompromised patients. Whether *Aspergillus* GM will be detected in blood earlier than finding suggestive infiltrates in a chest CT scan is contentious (Weisser *et al*, 2005). The GM test is also prone to yield false-positive results in blood samples obtained from patients treated with semisynthetic beta-lactam antibiotics, such as amoxicillin-clavulanate, piperacillin-tazobactam, carbapenems, ceftriaxone or ceftazidime (Boonsarngsuk *et al*, 2010), those given enteral nutrition (Girmenia *et al*, 2011) and those with other fungal infections, such as fusariosis (Tortorano *et al*, 2012). False-positive GM can also be found in BAL samples obtained using specific lavage solutions, such as Plasmalyte™ (Hage *et al*, 2007), and may also be due to blood products (Martín-Rabadán *et al*, 2012). Systemic antifungal prophylaxis with a mould-active azole, such as posaconazole, also reduces the reliability of the *Aspergillus* GM test (Duarte *et al*, 2014). A significant decline in GM OD indices was noted to result after storage of serum samples, but not BAL samples, so that the time from taking a blood sample to testing should be minimized (Johnson *et al*, 2013).

Details on antigen testing for fungal infection other than aspergillosis have been reviewed elsewhere (Ruhnke *et al*, 2012).

Studies on panfungal or *Aspergillus*-specific PCR assays indicate that BAL samples may be superior to blood samples, particularly when patients are receiving systemic antifungal therapy (Spiess *et al*, 2003; Musher *et al*, 2004). PCR also appears useful for lung biopsy specimens in addition to histopathology and culture as it allows identification of the pathogen (Rickerts *et al*, 2007). The lack of standardization of PCR for blood and BAL samples was the primary reason for not incorporating these assays in the European Organization for Research and Treatment of Cancer (EORTC)/Mycoses Study Group (MSG) definitions for invasive fungal diseases. However, progress is being made by the European *Aspergillus* PCR Initiative (<http://www.eapcri.eu>), and a cogent argument has recently been published for now including PCR in the EORTC/MSG definitions (White *et al*, 2015). It also seems likely that PCR will be incorporated into diagnostic work-ups for LI alongside thoracic CT scans, serology and conventional microbiology from blood and BAL samples (White *et al*, 2015). The combination of *Aspergillus* PCR and GM in BAL samples enhances diagnosis because the detection of both GM and PCR make the diagnosis of pulmonary aspergillosis highly likely, as has been confirmed by meta-analyses (Avni *et al*, 2012). Nonetheless, previous exposure to antifungal therapy may reduce the sensitivity of quantitative PCR assays as well as *Aspergillus* GM tests (McCulloch *et al*, 2012).

Legionella pneumophila serogroup 1 antigen

Nosocomial legionellosis among patients with cancer is fortunately very rare though a single centre report in 2007 recom-

mended that a test for *Legionella* be included in the differential diagnosis (Gudiol *et al*, 2007). Testing urine for *Legionella pneumophila* serogroup 1 antigen helps to make a rapid diagnosis but there are no proper clinical studies to support routine testing.

Can I rely on biomarkers such as C-reactive protein, procalcitonin or Interleukin 6?

Pro-inflammatory serum markers, such as C-reactive protein (CRP), interleukin 6 (IL6), interleukin 8 (IL8), tumour necrosis factor-alpha and procalcitonin (Robinson *et al*, 2011) have been evaluated, but the results are very heterogeneous, making a valid conclusion impossible. These markers have not yet been studied prospectively in febrile neutropenic patients with LI. In clinical practice, the serial measurement of CRP and IL6 typically parallels the clinical course of infection and can be used to guide therapeutic decisions together with clinical and imaging findings. Persistent fever, progressive or newly emerged LI and rising pro-inflammatory parameters typically indicate the need to change the antimicrobial treatment regimen (Robinson *et al*, 2011).

Procalcitonin is most useful for its negative predictive value, as repeated failure to detect the biomarker in the context of LI, fever and high inflammatory markers (CRP, IL6) despite broad-spectrum antimicrobial treatment suggests the infiltrate may be due to the underlying haematological malignancy, and therefore a reason to start chemotherapy (Bele *et al*, 2011).

Practical clinical management in neutropenic patients

An algorithm for the clinical management of febrile neutropenic patients with LI has been proposed in a recent guideline by the Infectious Diseases Working Party of the German Society of Haematology and Medical Oncology (Maschmeyer *et al*, 2015). Figure 1 depicts a clinical pathway reflecting these recommendations.

Diagnostic procedures

In patients with AML or MDS undergoing aggressive myelosuppressive chemotherapy expecting severe neutropenia lasting ≥ 10 d, serial monitoring of *Aspergillus* GM from blood samples is recommended. If patients with fever of unknown origin do not respond to an empirical first-line therapy with an antipseudomonal beta-lactam antibiotic after 72–96 h, they should undergo thorough physical re-examination, imaging and microbiological diagnostics including a (mostly native, i.e., without contrast media) thoracic CT scan. When LI are present and/or *Aspergillus* GM is positive, non-invasive diagnostic tests should be repeated and bronchoscopy and BAL using a standardized protocol (Sampsonas *et al*, 2011) be arranged within a maximum of 24 h. Microbiological

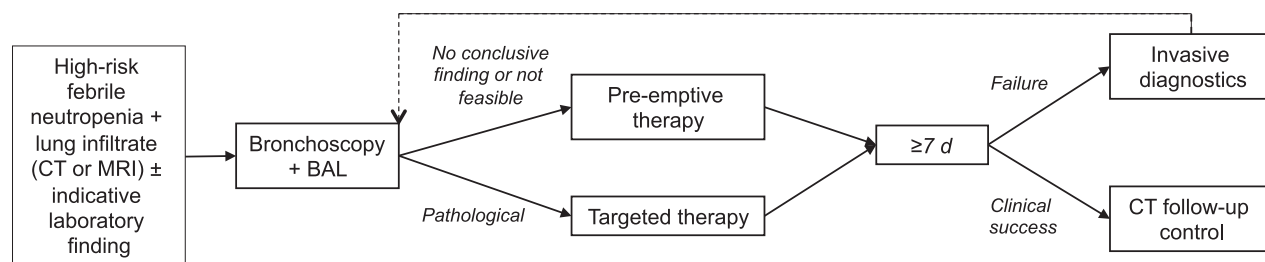


Fig 1. Algorithm for the clinical management of febrile neutropenic high-risk adult haematology patients with lung infiltrates (outside allogeneic haematopoietic stem cell transplantation). CT, pulmonary computerized tomography; MRI, pulmonary magnetic resonance imaging; BAL, bronchoalveolar lavage.

laboratory work-up of BAL samples should be started within 4 h. Recommended routine microbiological procedures are listed in Table II. Additional assays may be added, e.g. molecular tests for respiratory viruses. In individual cases when pneumonia has been acquired before hospitalization, invasive procedures, such as open lung or percutaneous core needle biopsy, should be considered in patients with undetermined LI who urgently require histological identification while bronchoscopy and BAL have failed.

Antimicrobial therapy in patients without microbiological proof

Considering the dismal prognosis of febrile neutropenic patients with LI not treated promptly with an appropriate antimicrobial regimen, it is recommended to start therapy on the basis of clinical, imaging and/or laboratory findings indicative of a particular infection in patients at risk for, but without proof of this infection. The type of underlying malignancy or immunosuppression has an instrumental impact on the selection of antimicrobial agents suitable for systemic therapy. In patients without a conclusive microbiological finding and a lack of response to antimicrobial treatment, re-assessment including thoracic CT scan and eventually also bronchoscopy and BAL should be arranged after 7 d.

Table II. Standard programme for microbiological work-up of BAL samples.

- 1 Cytospin preparations (May-Grünwald Giemsa) for microscopy
- 2 Gram stain
- 3 *M. tuberculosis* PCR
- 4 PCR for *Pneumocystis jirovecii*; quantitative if positive
- 5 Calcofluor white or equivalent (fungi, *Pneumocystis jirovecii*)
- 6 Direct immunofluorescence test for *Pneumocystis jirovecii* (confirmatory)
- 7 Aspergillus antigen (Galactomannan Sandwich ELISA)
- 8 Bacterial and fungal cultures

PCR, polymerase chain reaction; ELISA, enzyme-linked immunosorbent assay.

Severely neutropenic AML patients with LI

Clinical outcome of proven invasive mould infection (aspergillosis or mucormycosis) in neutropenic patients is poor (Lin *et al*, 2001), so that early mould-active antifungal treatment should be added to a broad-spectrum anti-pseudomonal beta-lactam in patients whose LI do not have the typical radiological pattern of PcP or lobar bacterial pneumonia (Maschmeyer *et al*, 2015). It has been shown that patients with invasive aspergillosis treated with voriconazole or liposomal amphotericin B had superior response and survival rates when treated early vs. later in the course of the disease. In patients pre-treated with voriconazole or posaconazole for systemic antifungal prophylaxis, in whom a breakthrough filamentous fungal pneumonia is presumed, antifungal drug levels should be checked, invasive diagnostic procedures be taken into consideration, and antifungal treatment be switched to liposomal amphotericin B.

In patients who have a thoracic CT scan suggesting PcP and a rapid and otherwise unexplained rise of serum lactate dehydrogenase, prompt start of high-dose co-trimoxazole is recommended (see below). BAL will remain positive for *P. jirovecii* over several days despite appropriate antimicrobial therapy (Roger *et al*, 1998). This recommendation, however, is only valid for patients who did not receive anti-*Pneumocystis* prophylaxis.

In this group of patients, antiviral agents, glycopeptides, fluoroquinolones or macrolide antibiotics should not be routinely given without a convincing diagnosis from clinically significant samples.

Patients undergoing autologous haematopoietic stem cell transplantation (AHSCT)

Patients undergoing high-dose chemotherapy and AHSCT have a low risk of fungal pneumonia (Post *et al*, 2007). Therefore, early antifungal therapy is not recommended. If myeloma patients have been pre-treated with bortezomib, or if total body irradiation, alemtuzumab, anti-thymocyte globulin or fludarabine has been used for conditioning, CMV disease may be considered (Fassas *et al*, 2001; Ljungman *et al*, 2005; Marchesi *et al*, 2014) and BAL checked for this

pathogen. A positive rapid culture or 'immediate early antigen' should prompt antiviral treatment (Konoplev *et al*, 2001). Importantly, the quantitative measurement of CMV copies in blood samples does not correlate with the risk of CMV pneumonia (Ng *et al*, 2005). First-choice antiviral treatment options are foscarnet or ganciclovir. The latter may cause critical myelosuppression, while (reversible) nephrotoxicity is the typical side effect of foscarnet.

Antimicrobial treatment in patients with documented pathogens

Complicated bacterial pneumonias

Antimicrobial treatment of pneumonia caused by bacteria not typically susceptible to standard broad-spectrum beta-lactam antibiotics must be individualized. Apart from a critical discussion of the causative role of a pathogen isolated from a diagnostic sample (see above), *in vitro* susceptibility patterns and pharmacokinetic aspects (penetration to lung tissue, possible inactivation by surfactant) must always be included in this selection. In patients with multi-resistant gram-negative pathogens, aerosolized colistin has been successfully used as part of the antimicrobial strategy. *Stenotrophomonas maltophilia* rarely causes pneumonia in haematological patients and is more frequently associated with blood stream infections in case of an infected venous access. Treatment recommendations for some selected bacterial pneumonias are listed in Table III.

Treatment of fungal pneumonia

Aspergillus species and *Mucorales* are the typical pathogenic fungi causing LI in severely neutropenic patients. *Candida*

spp. are frequently isolated from respiratory tract samples, but represent the cause of LI only in rare cases of disseminated *Candida* fungaemia with haematogenous spread to the lungs (Kontoyiannis *et al*, 2002). Updated recommendations for the treatment of documented mucormycosis are provided in evidence-based guidelines (Mousset *et al*, 2013; Cornely *et al*, 2014; Schelenz *et al*, 2015). First-line treatment of invasive pulmonary aspergillosis is intravenous voriconazole (6 mg/kg every 12 h day 1, 4 mg/kg every 12 h thereafter) or liposomal amphotericin B (3 mg/kg/d), while for mucormycosis (zygomycosis), liposomal amphotericin B at a dose of ≥ 5 mg/kg/d is preferred. Most patients need more than 7–10 d of full-dose antifungal therapy to show clinical improvement (defervescence, decreasing inflammatory parameters, declining dyspnoea, better oxygenation), whereas CT scans taken after the first week of treatment often show an increasing volume of LI (Caillot *et al*, 2001). Antifungal treatment should not be changed at this point, unless new LI emerge at previously normal pulmonary sites and clinical deterioration is obvious. A second infection, immune reconstitution syndrome, infiltrates caused by the underlying malignancy or toxic side effects from cancer treatment should be revisited (Segal *et al*, 2008).

Treatment of *Pneumocystis pneumonia* (PcP)

If PcP is suspected, treatment with co-trimoxazole (trimethoprim/sulfamethoxazole; TMP/SMX) at a dosage of TMP 15–20 mg/kg plus SMX 75–100 mg/kg/d should be initiated after BAL or induced sputum samples have been obtained. Treatment delay may enhance mortality (Guo *et al*, 2014). Blood gas analysis should be done before the start of antimicrobial therapy. If oxygen partial pressure is ≥ 70 mm Hg or alveolar-arterial oxygen difference < 45 mm Hg, upfront oral

Table III. Treatment recommendations for selected bacterial pneumonias.

Pathogen	First-line antimicrobial agent	Comment
<i>Pseudomonas aeruginosa</i>	Piperacillin \pm tazobactam Imipenem-cilastatin Meropenem Ceftazidime Cefepime	Combination with aminoglycoside or ciprofloxacin may be considered depending upon local resistance patterns
<i>Escherichia coli</i> , <i>Klebsiella</i> spp. or <i>Serratia</i> spp. with extended-spectrum beta-lactamase (ESBL) production	Imipenem-cilastatin Meropenem Ertapenem	Ertapenem is not active against <i>Pseudomonas aeruginosa</i>
Multi-resistant gram-negative bacilli, such as <i>Acinetobacter baumannii</i>	Colistin Fosfomycin Tigecycline	Individual decision required
<i>Stenotrophomonas maltophilia</i>	High-dose co-trimoxazole	In-vitro susceptibility testing may not reliably predict clinical efficacy (Carroll <i>et al</i> , 1998)
<i>Staphylococcus aureus</i> (oxacillin-susceptible; MSSA)	Flucloxacillin Oxacillin	Vancomycin inferior (McDanel <i>et al</i> , 2015)
<i>Staphylococcus aureus</i> (oxacillin-resistant; MRSA)	Vancomycin Teicoplanin Linezolid	Linezolid may cause thrombocytopenia

therapy may be considered, otherwise intravenous treatment is indicated. Treatment should be continued for at least 2 weeks. Clinical improvement is expected after 5–8 d, otherwise a second infection should be considered and diagnostic procedures be repeated. If TMP/SMX is not tolerated or ineffective, clindamycin (600 mg three times daily or 450 mg four times daily) plus primaquine (30 mg/d orally) appear to be the most effective option (Smego *et al*, 2001). Other potential salvage regimens include atovaquone oral suspension (750 mg twice daily orally with meal) or intravenous pentamidine (4 mg/kg/d). Subsequently, patients should be given secondary prophylaxis with TMP/SMX 160/800 mg given orally on 3 d per week or monthly pentamidine inhalation at a dose of 300 mg. In patients with respiratory failure, the use of systemic corticosteroids is controversial, as recent (non-randomized) studies did not show a clinical benefit (Moon *et al*, 2011) or were associated with increased mortality (Lemiale *et al*, 2013).

Should I start G-CSF in critically ill neutropenic patients with LI?

A clear benefit from the adjunctive administration of granulocyte colony-stimulating factor (G-CSF) (or granulocyte-macrophage colony-stimulating factor, which is no longer available in some European countries) in terms of response or survival rates has not been demonstrated. Hence, the use of these drugs is not recommended. Indeed, there have been reports of pulmonary function deteriorating after treatment with G-CSF (Karlin *et al*, 2005).

Should I refer leukaemia patients with acute respiratory failure to the intensive care unit?

In contrast to widespread opinions, neutropenic patients with respiratory failure may have a favourable outcome

under appropriate intensive care including mechanical ventilation (Maschmeyer *et al*, 2003), even if invasive aspergillosis is identified as the underlying complication. A particular problem arises in patients whose clinical condition deteriorates due to haematopoietic recovery. This may happen in one-third of patients with LI emerging during neutropenia, especially in those with acute leukaemia and previous severe neutropenia lasting for more than 10 d, and result in acute respiratory distress syndrome. It is important not to misinterpret this worsening as a failure of antimicrobial therapy and consequently switch to irrational antimicrobial polypharmacotherapy (drug combinations), but rather optimize supportive care and try to lead the patient through this critical period of immune recovery.

How long should antimicrobial treatment be continued?

There are very sparse data on the duration of antimicrobial treatment in patients with LI who have responded to this treatment, so that decisions on the duration of treatment are influenced by the nature of the pneumonia and the results of an interim response assessment. In patients with PcP, 2–3 weeks are recommended (see above), for bacterial pneumonia a resolution of clinical and laboratory signs of active infection should be documented (typically after 10–14 d of treatment), and for CMV pneumonia, 2–4 weeks of treatment appear sufficient. With respect to their high risk of relapse, patients with invasive pulmonary mould infection should receive systemic antifungal treatment until haematopoietic recovery and regression of clinical and radiological signs of infection.

References

- Ahmed, S., Siddiqui, A.K., Rossoff, L., Sison, C.P. & Rai, K.R. (2003) Pulmonary complications in chronic lymphocytic leukemia. *Cancer*, **98**, 1912–1917.
- Al Ameri, A., Koller, C., Kantarjian, H., Ravandi, F., Verstovsek, S., Borthakur, G., Pierce, S. & Mattiuzzi, G. (2010) Acute pulmonary failure during remission induction chemotherapy in adults with acute myeloid leukemia or high-risk myelodysplastic syndrome. *Cancer*, **116**, 93–97.
- Attenberger, U.I., Morelli, J.N., Henzler, T., Buchheidt, D., Fink, C., Schoenberg, S.O. & Reichert, M. (2014) 3Tesla proton MRI for the diagnosis of pneumonia/lung infiltrates in neutropenic patients with acute myeloid leukemia: initial results in comparison to HRCT. *European Journal of Radiology*, **83**, e61–e66.
- Avni, T., Levy, I., Sprecher, H., Yahav, D., Leibovici, L. & Paul, M. (2012) Diagnostic accuracy of PCR alone compared to galactomannan in bronchoalveolar lavage fluid for diagnosis of invasive pulmonary aspergillosis: a systematic review. *Journal of Clinical Microbiology*, **50**, 3652–3658.
- Azoulay, E., Mokart, D., Rabbat, A., Pene, F., Kouatchet, A., Bruneel, F., Vincent, F., Hamidfar, R., Moreau, D., Mohammedi, I., Epinette, G., Beduneau, G., Castelain, V., de Lassence, A., Gruson, D., Lemiale, V., Renard, B., Chevret, S. & Schlemmer, B. (2008) Diagnostic bronchoscopy in hematology and oncology patients with acute respiratory failure. *Critical Care Medicine*, **36**, 100–107.
- Azoulay, E., Mokart, D., Lambert, J., Lemiale, V., Rabbat, A., Kouatchet, A., Vincent, F., Gruson, D., Bruneel, F., Epinette-Branche, G., Lafabrie, A., Hamidfar-Roy, R., Cracco, C., Renard, B., Tonnelier, J.M., Blot, F., Chevret, S. & Schlemmer, B. (2010) Diagnostic strategy for hematology and oncology patients with acute respiratory failure: randomized controlled trial. *American Journal of Respiratory and Critical Care Medicine*, **182**, 1038–1046.
- Bele, N., Darmon, M., Coquet, I., Feugeas, J.P., Legriel, S., Adaoui, N., Schlemmer, B. & Azoulay, E. (2011) Diagnostic accuracy of procalcitonin in critically ill immunocompromised patients. *BMC Infectious Diseases*, **11**, 224.
- Boeckh, M. (2011) Complications, diagnosis, management, and prevention of CMV infections: current and future. *Hematology*, **2011**, 305–309.
- Boersma, W.G., Erjavec, Z., van der Werf, T.S., de Vries-Hosper, H.G., Gouw, A.S. & Manson, W.L. (2007) Bronchoscopic diagnosis of pulmonary infiltrates in granulocytopenic patients with hematologic malignancies: BAL versus PSB and PBAL. *Respiratory Medicine*, **101**, 317–325.

- Boonsarngsuk, V., Niyompattama, A., Teosirimongkol, C. & Sriwanichrak, K. (2010) False-positive serum and bronchoalveolar lavage *Aspergillus* galactomannan assays caused by different antibiotics. *Scandinavian Journal of Infectious Diseases*, **42**, 461–468.
- Brodoefel, H., Vogel, M., Hebart, H., Einsele, H., Vonthein, R., Claussen, C. & Horger, M. (2006) Long-term CT follow-up in 40 non-HIV immunocompromised patients with invasive pulmonary aspergillosis. *American Journal of Roentgenology*, **187**, 404–413.
- Bruno, C., Minniti, S., Vassanelli, A. & Pozzi-Mucelli, R. (2007) Comparison of CT features of *Aspergillus* and bacterial pneumonia in severely neutropenic patients. *Journal of Thoracic Imaging*, **22**, 160–165.
- Caillot, D., Casasnovas, O., Bernard, A., Couaillier, J.F., Durand, C., Cuisenier, B., Solary, E., Piard, F., Petrella, T., Bonnin, A., Couillault, G., Dumas, M. & Guy, H. (1997) Improved management of invasive pulmonary aspergillosis in neutropenic patients using early thoracic computed tomographic scan and surgery. *Journal of Clinical Oncology*, **15**, 139–147.
- Caillot, D., Couaillier, J.F., Bernard, A., Casasnovas, O., Denning, D.W., Mannone, L., Lopez, J., Couillault, G., Piard, F., Vagner, O. & Guy, H. (2001) Increasing volume and changing characteristics of invasive pulmonary aspergillosis on sequential thoracic computed tomography scans in patients with neutropenia. *Journal of Clinical Oncology*, **19**, 253–259.
- Camus, P. & Costabel, U. (2005) Drug-induced respiratory disease in patients with hematological diseases. *Seminars in Respiratory and Critical Care Medicine*, **26**, 458–481.
- Carratalà, J., Rosón, B., Fernández-Sevilla, A., Alcaide, F. & Gudiol, F. (1998) Bacteremic pneumonia in neutropenic patients with cancer: causes, empirical antibiotic therapy, and outcome. *Archives of Internal Medicine*, **158**, 868–872.
- Carroll, K.C., Cohen, S., Nelson, R., Campbell, D.M., Claridge, J.D., Garrison, M.W., Kramp, J., Malone, C., Hoffmann, M. & Anderson, D.E. (1998) Comparison of various in vitro susceptibility methods for testing *Stenotrophomonas maltophilia*. *Diagnostic Microbiology and Infectious Diseases*, **32**, 229–235.
- Chamilos, G., Luna, M., Lewis, R.E., Bodey, G.P., Chemaly, R., Tarrand, J.J., Safdar, A., Raad, I.I. & Kontoyiannis, D.P. (2006) Invasive fungal infections in patients with hematologic malignancies in a tertiary care cancer center: an autopsy study over a 15-year period (1989–2003). *Haematologica*, **91**, 986–989.
- Chaoui, D., Legrand, O., Roche, N., Cornet, M., Lefebvre, A., Peffault de Latour, R., Sanhes, L., Huchon, G., Marie, J.P. & Rabbat, A. (2004) Incidence and prognostic value of respiratory events in acute leukemia. *Leukemia*, **2004**, 670–675.
- Cornely, O.A., Arian-Akdagli, S., Dannaoui, E., Groll, A.H., Lagrou, K., Chakrabarti, A., Lanternier, F., Pagano, L., Skiada, A., Akova, M., Arendrup, M.C., Boekhout, T., Chowdhary, A., Cuenca-Estrella, M., Freiburger, T., Guinea, J., Guarro, J., de Hoog, S., Hope, W., Johnson, E., Kathuria, S., Lackner, M., Lass-Flörl, C., Lortholary, O., Meis, J.F., Meletiadis, J., Muñoz, P., Richardson, M., Roilides, E., Tortorano, A.M., Ullmann, A.J., van Diepeningen, A., Verweij, P. & Petrikos, G. (2014) ESCMID and ECMM joint clinical guidelines for the diagnosis and management of mucormycosis 2013. *Clinical Microbiology and Infectious Diseases*, **20**, 5–26.
- Darmon, M., Thiery, G., Ciroldi, M., de Miranda, S., Galicier, L., Raffoux, E., Le Gall, J.R., Schlemmer, B. & Azoulay, E. (2005) Intensive care in patients with newly diagnosed malignancies and a need for cancer chemotherapy. *Critical Care Medicine*, **33**, 2488–2493.
- Duarte, R.F., Sánchez-Ortega, I., Cuesta, I., Arnan, M., Patiño, B., Fernández de Sevilla, A., Gudiol, C., Ayats, J. & Cuenca-Estrella, M. (2014) Serum galactomannan-based early detection of invasive aspergillosis in hematology patients receiving effective antimold prophylaxis. *Clinical Infectious Diseases*, **59**, 1696–1702.
- Fassas, A.B., Bolaños-Meade, J., Buddharaju, L.N., Rapoport, A., Cottler-Fox, M., Chen, T., Lovchik, J.C., Cross, A. & Tricot, G. (2001) Cytomegalovirus infection and non-neutropenic fever after autologous stem cell transplantation: high rates of reactivation in patients with multiple myeloma and lymphoma. *British Journal of Haematology*, **112**, 237–241.
- García, J.B., Lei, X., Wierda, W., Cortes, J.E., Dickey, B.F., Evans, S.E. & Ost, D.E. (2013) Pneumonia during remission induction chemotherapy in patients with acute leukemia. *Annals of the American Thoracic Society*, **10**, 432–440.
- Georgiadou, S.P., Sipsas, N.V., Marom, E.M. & Kontoyiannis, D.P. (2011) The diagnostic value of halo and reversed halo signs for invasive mold infections in compromised hosts. *Clinical Infectious Diseases*, **52**, 1144–1155.
- Girmenia, C., Santilli, S., Ballarò, D., Del Giudice, I., Armiento, D. & Mauro, F.R. (2011) Enteral nutrition may cause false-positive results of *Aspergillus* galactomannan assay in absence of gastrointestinal diseases. *Mycoses*, **54**, e883–e884.
- Godet, C., Le Goff, J., Beby-Defaux, A., Robin, M., Raffoux, E., Arnulf, B., Roblot, F., Frat, J.P., Maillard, N., Tazi, A. & Bergeron, A. (2014) Human metapneumovirus pneumonia in patients with hematological malignancies. *Journal of Clinical Virology*, **61**, 593–596.
- Godoy, M.C., Viswanathan, C., Marchiori, E., Truong, M.T., Benveniste, M.F., Rossi, S. & Marom, E.M. (2012) The reversed halo sign: update and differential diagnosis. *British Journal of Radiology*, **85**, 1226–1235.
- Gudiol, C., Verdager, R., Angeles Domínguez, M., Fernández-Sevilla, A. & Carratalà, J. (2007) Outbreak of Legionnaires' disease in immunosuppressed patients at a cancer centre: usefulness of universal urine antigen testing and early levofloxacin therapy. *Clinical Microbiology and Infection*, **13**, 1125–1128.
- Guo, F., Chen, Y., Yang, S.L., Xia, H., Li, X.W. & Tong, Z.H. (2014) Pneumocystis pneumonia in HIV-infected and immunocompromised non-HIV infected patients: a retrospective study of two centers in China. *PLoS One*, **9**, e101943.
- Hage, C.A., Reynolds, J.M., Durkin, M., Wheat, L.J. & Knox, K.S. (2007) Plasmalyte as a cause of false-positive results for *Aspergillus* galactomannan in bronchoalveolar lavage fluid. *Journal of Clinical Microbiology*, **45**, 676–677.
- Heussel, C.P., Kauczor, H.U., Heussel, G.E., Fischer, B., Begrich, M., Mildenerger, P. & Thelen, M. (1999) Pneumonia in febrile neutropenic patients and in bone marrow and blood stem-cell transplant recipients: use of high-resolution computed tomography. *Journal of Clinical Oncology*, **17**, 796–805.
- Heussel, C.P., Kauczor, H.U. & Ullmann, A.J. (2004) Pneumonia in neutropenic patients. *European Radiology*, **14**, 256–271.
- Hirsch, H.H., Martino, R., Ward, K.N., Boeckh, M., Einsele, H., Ljungman, P. & Fourth European Conference on Infections in Leukaemia (ECIL-4). (2013) Guidelines for diagnosis and treatment of human respiratory syncytial virus, parainfluenza virus, metapneumovirus, rhinovirus, and coronavirus. *Clinical Infectious Diseases*, **56**, 258–266.
- Hoellein, A., Hecker, J., Hoffmann, D., Göttle, F., Protzer, U., Peschel, C. & Götz, K. (2015) Serious outbreak of human metapneumovirus in patients with hematologic malignancies. *Leukemia and Lymphoma*, **2015**, 1–5. [Epub ahead of print]
- Hohenthal, U., Itälä, M., Salonen, J., Sipilä, J., Rantakokko-Jalava, K., Meurman, O., Nikoskelainen, J., Vainionpää, R. & Kotilainen, P. (2005) Bronchoalveolar lavage in immunocompromised patients with haematological malignancy. Value of new microbiological methods. *European Journal of Haematology*, **74**, 203–211.
- Jain, P., Sandur, S., Meli, Y., Arroliga, A.C., Stoller, J.K. & Mehta, A.C. (2004) Role of flexible bronchoscopy in immunocompromised patients with lung infiltrates. *Chest*, **125**, 712–722.
- Johnson, G.L., Sarker, S.J., Hill, K., Tsitsikas, D.A., Morin, A., Bustin, S.A. & Agrawal, S.G. (2013) Significant decline in galactomannan signal during storage of clinical serum samples. *International Journal of Molecular Sciences*, **14**, 12970–12977.
- Kanne, J.P., Yandow, D.R. & Meyer, C.A. (2012) *Pneumocystis jirovecii* pneumonia: high-resolution CT findings in patients with and without HIV infection. *American Journal of Roentgenology*, **198**, W555–W561.
- Karageorgopoulos, D.E., Qu, J.M., Korbila, I.P., Zhu, Y.G., Vasileiou, V.A. & Falagas, M.E. (2013) Accuracy of β -D-glucan for the diagnosis of *Pneumocystis jirovecii* pneumonia: a meta-analysis. *Clinical Microbiology and Infection*, **19**, 39–49.

- Karlin, L., Darmon, M., Thiery, G., Ciroidi, M., de Miranda, S., Lefebvre, A., Schlemmer, B. & Azoulay, E. (2005) Respiratory status deterioration during G-CSF-induced neutropenia recovery. *Bone Marrow Transplantation*, **36**, 245–250.
- Koh, T.T., Colby, T.V. & Müller, N.L. (2005) Myeloid leukemias and lung involvement. *Seminars in Respiratory and Critical Care Medicine*, **26**, 514–519.
- Konoplev, S., Champlin, R.E., Giral, S., Ueno, N.T., Khouri, I., Raad, I., Rolston, K., Jacobson, K., Tarrand, J., Luna, M., Nguyen, Q. & Whimbey, E. (2001) Cytomegalovirus pneumonia in adult autologous blood and marrow transplant recipients. *Bone Marrow Transplantation*, **27**, 877–881.
- Kontoyiannis, D.P., Reddy, B.T., Torres, H.A., Luna, M., Lewis, R.E., Tarrand, J., Bodey, G.P. & Raad, I.I. (2002) Pulmonary candidiasis in patients with cancer: an autopsy study. *Clinical Infectious Diseases*, **34**, 400–403.
- Kuderer, N.M., Dale, D.C., Crawford, J., Cosler, L.E. & Lyman, G.H. (2006) Mortality, morbidity, and cost associated with febrile neutropenia in adult cancer patients. *Cancer*, **106**, 2258–2266.
- Lass-Flörl, C., Resch, G., Nachbaur, D., Mayr, A., Gastl, G., Auberger, J., Bialek, R. & Freund, M.C. (2007) The value of computed tomography-guided percutaneous lung biopsy for diagnosis of invasive fungal infection in immunocompromised patients. *Clinical Infectious Diseases*, **45**, e101–e104.
- Lougou, C., Caillot, D., Chrétien, M.L., Lafon, I., Ferrant, E., Audia, S., Pagès, P.B., Roques, M., Estivalet, L., Martin, L., Maitre, T., Bastie, J.N. & Dalle, F. (2014) The reversed halo sign: pathognomonic pattern of pulmonary mucormycosis in leukemic patients with neutropenia? *Clinical Infectious Diseases*, **58**, 672–678.
- Lehners, N., Schnitzler, P., Geis, S., Puthenparambil, J., Benz, M.A., Alber, B., Luft, T., Dreger, P., Eisenbach, C., Kunz, C., Benner, A., Buchholz, U., Aichinger, E., Frank, U., Heeg, K., Ho, A.D. & Egerer, G. (2013) Risk factors and containment of respiratory syncytial virus outbreak in a hematology and transplant unit. *Bone Marrow Transplantation*, **48**, 1548–1553.
- Lemiale, V., Debrumetz, A., Delannoy, A., Alberti, C. & Azoulay, E. (2013) Adjunctive steroid in HIV-negative patients with severe Pneumocystis pneumonia. *Respiratory Research*, **14**, 87.
- Lin, S.J., Schranz, J. & Teutsch, S.M. (2001) Aspergillosis case-fatality rate: systematic review of the literature. *Clinical Infectious Diseases*, **32**, 358–366.
- Ljungman, P., von Döbeln, L., Ringholm, L., Lewensohn-Fuchs, I., Klingspor, L. & Sparrelid, E. (2005) The value of CMV and fungal PCR for monitoring for acute leukaemia and autologous stem cell transplant patients. *Scandinavian Journal of Infectious Diseases*, **37**, 121–127.
- Lu, Y., Ling, G., Qiang, C., Ming, Q., Wu, C., Wang, K. & Ying, Z. (2011) PCR diagnosis of Pneumocystis pneumonia: a bivariate meta-analysis. *Journal of Clinical Microbiology*, **49**, 4361–4363.
- Luesink, M. & Jansen, J.H. (2010) Advances in understanding the pulmonary infiltration in acute promyelocytic leukaemia. *British Journal of Haematology*, **151**, 209–220.
- Maertens, J., Verhaegen, J., Demuyne, H., Brock, P., Verhoef, G., Vandenberghe, P., Van Eldere, J., Verbist, L. & Boogaerts, M. (1999) Autopsy-controlled prospective evaluation of serial screening for circulating galactomannan by a sandwich enzyme-linked immunosorbent assay for hematological patients at risk for invasive aspergillosis. *Journal of Clinical Microbiology*, **37**, 3223–3228.
- Marchesi, F., Mengarelli, A., Giannotti, F., Tendas, A., Anaclerio, B., Porrini, R., Picardi, A., Cerchiara, E., Dentamaro, T., Chierichini, A., Romeo, A., Cudillo, L., Montefusco, E., Tirindelli, M.C., De Fabritiis, P., Annino, L., Petti, M.C., Monarca, B., Arcese, W., Avvisati, G. & Rome Transplant Network. (2014) High incidence of post-transplant cytomegalovirus reactivations in myeloma patients undergoing autologous stem cell transplantation after treatment with bortezomib-based regimens: a survey from the Rome Transplant Network. *Transplant Infectious Diseases*, **16**, 158–164.
- Martino, R., Rámila, E., Rabella, N., Muñoz, J.M., Peyret, M., Portos, J.M., Laborda, R. & Sierra, J. (2003) Respiratory virus infections in adults with hematologic malignancies: a prospective study. *Clinical Infectious Diseases*, **36**, 1–8.
- Martín-Rabadán, P., Gijón, P., Alonso Fernández, R., Ballesteros, M., Anguita, J. & Bouza, E. (2012) False-positive Aspergillus antigenemia due to blood product conditioning fluids. *Clinical Infectious Diseases*, **55**, e22–e27.
- Maschmeyer, G., Link, H., Hiddemann, W., Meyer, P., Helmerking, M., Eisenmann, E., Schmitt, J. & Adam, D. (1994) Pulmonary infiltrations in febrile patients with neutropenia. Risk factors and outcome under empirical antimicrobial therapy in a randomized multicenter study. *Cancer*, **73**, 2296–2304.
- Maschmeyer, G., Bertschat, F.L., Moesta, K.T., Hausler, E., Held, T.K., Nolte, M., Osterziel, K.J., Papstein, V., Peters, M., Reich, G., Schmutzler, M., Sezer, O., Stula, M., Wauer, H., Wörtz, T., Wischnewsky, M. & Hohenberger, P. (2003) Outcome analysis of 189 consecutive cancer patients referred to the intensive care unit as emergencies during a 2-year period. *European Journal of Cancer*, **39**, 783–792.
- Maschmeyer, G., Carratalà, J., Buchheidt, D., Hamprecht, A., Heussel, C.P., Kahl, C., Lorenz, J., Neumann, S., Rieger, C., Ruhnke, M., Salwender, H., Schmidt-Hieber, M. & Azoulay, E. (2015) Diagnosis and antimicrobial therapy of lung infiltrates in febrile neutropenic patients (allogeneic SCT excluded): updated guidelines of the Infectious Diseases Working Party (AGIHO) of the German Society of Hematology and Medical Oncology (DGHO). *Annals of Oncology*, **26**, 21–33.
- McCulloch, E., Ramage, G., Rajendran, R., Lappin, D.F., Jones, B., Warn, P., Shrief, R., Kirkpatrick, W.R., Patterson, T.F. & Williams, C. (2012) Antifungal treatment affects the laboratory diagnosis of invasive aspergillosis. *Journal of Clinical Pathology*, **65**, 83–86.
- McDanel, J.S., Perencevich, E.N., Diekema, D.J., Herwaldt, L.A., Smith, T.C., Chrischilles, E.A., Dawson, J.D., Jiang, L., Goto, M. & Schweizer, M.L. (2015) Comparative effectiveness of beta-lactams versus vancomycin for treatment of methicillin-susceptible *Staphylococcus aureus* bloodstream infections among 122 hospitals. *Clinical Infectious Diseases*, **61**, 361–367.
- Moon, S.M., Kim, T., Sung, H., Kim, M.N., Kim, S.H., Choi, S.H., Jeong, J.Y., Woo, J.H., Kim, Y.S., Lee, S.O. (2011) Outcomes of moderate-to-severe Pneumocystis pneumonia treated with adjunctive steroid in non HIV-infected patients. *Antimicrobial Agents and Chemotherapy*, **55**, 4613–4618.
- Mousset, S., Buchheidt, D., Heinz, W., Ruhnke, M., Cornely, O.A., Egerer, G., Krüger, W., Link, H., Neumann, S., Ostermann, H., Panse, J., Penack, O., Rieger, C., Schmidt-Hieber, M., Silling, G., Südhoff, T., Ullmann, A.J., Wolf, H.H., Maschmeyer, G. & Böhme, A. (2013) Treatment of invasive fungal infections in cancer patients—updated recommendations of the Infectious Diseases Working Party (AGIHO) of the German Society of Hematology and Oncology (DGHO). *Annals of Hematology*, **93**, 13–32.
- Mühlenthaler, K., Bögli-Stuber, K., Wasmer, S., von Garnier, C., Dumont, P., Rauch, A., Mühlemann, K. & Garzoni, C. (2012) Quantitative PCR to diagnose Pneumocystis pneumonia in immunocompromised non-HIV patients. *European Respiratory Journal*, **39**, 971–978.
- Musher, B., Fredricks, D., Leisenring, W., Balajee, S.A., Smith, C. & Marr, K.A. (2004) Aspergillus galactomannan enzyme immunoassay and quantitative PCR for diagnosis of invasive aspergillosis with bronchoalveolar lavage fluid. *Journal of Clinical Microbiology*, **42**, 5517–5522.
- Navigante, A.H., Cerchiotti, L.C., Costantini, P., Salgado, H., Castro, M.A., Lutteral, M.A. & Cabalar, M.E. (2002) Conventional chest radiography in the initial assessment of adult cancer patients with fever and neutropenia. *Cancer Control*, **9**, 346–351.
- Ng, A.P., Worth, L., Chen, L., Seymour, J.F., Prince, H.M., Slavin, M. & Thursky, K. (2005) Cytomegalovirus DNAemia and disease: incidence, natural history and management in settings other than allogeneic stem cell transplantation. *Haematologica*, **90**, 1672–1679.
- Oude Nijhuis, C.S., Gietema, J.A., Vellenga, E., Daenen, S.M., De Bont, E.S., Kamps, W.A., Groen, H.J., van der Jagt, E.J. & van der Graaf, W.T. (2003) Routine radiography does not have a role in the diagnostic evaluation of ambulatory adult febrile neutropenic cancer patients. *European Journal of Cancer*, **39**, 2495–2498.

- Perfect, J.R., Cox, G.M., Lee, J.Y., Kauffman, C.A., de Repentigny, L., Chapman, S.W., Morrison, V.A., Pappas, P., Hiemenz, J.W., Stevens, D.A. & Mycoses Study Group. (2001) The impact of culture isolation of *Aspergillus* species: a hospital-based survey of aspergillosis. *Clinical Infectious Diseases*, **33**, 1824–1833.
- Ponce, C.A., Gallo, M., Bustamante, R. & Vargas, S.L. (2010) Pneumocystis colonization is highly prevalent in the autopsied lungs of the general population. *Clinical Infectious Diseases*, **50**, 347–353.
- Post, M.J., Lass-Floerl, C., Gastl, G. & Nachbaur, D. (2007) Invasive fungal infections in allogeneic and autologous stem cell transplant recipients. *Transplant Infectious Diseases*, **9**, 189–195.
- Potenza, L., Luppi, M., Morselli, M., Tonelli, S., D'Apollo, N., Facchini, L., Torricelli, P., Tazzoli, G., Saviola, A., Bresciani, P., Longo, G. & Torelli, G. (2003) Leukaemic pulmonary infiltrates in adult acute myeloid leukaemia: a high-resolution computerized tomography study. *British Journal of Haematology*, **120**, 1058–1061.
- Raad, I.L., Whimby, E.E., Rolston, K.V., Abi-Said, D., Hachem, R.Y., Pandya, R.G., Ghaddar, H.M., Karl, C.L. & Bodey, G.P. (1996) A comparison of aztreonam plus vancomycin and imipenem plus vancomycin as initial therapy for febrile neutropenic cancer patients. *Cancer*, **77**, 1386–1394.
- Reich, G., Mapara, M.Y., Reichardt, P., Dörken, B. & Maschmeyer, G. (2001) Infectious complications after high-dose chemotherapy and autologous stem cell transplantation: comparison between patients with lymphoma or multiple myeloma and patients with solid tumors. *Bone Marrow Transplantation*, **27**, 525–529.
- Rickerts, V., Mousset, S., Lambrecht, E., Tintelnot, K., Schwerdtfeger, R., Presterl, E., Jacobi, V., Just-Nübling, G. & Bialek, R. (2007) Comparison of histopathological analysis, culture, and polymerase chain reaction assays to detect invasive mold infections from biopsy specimens. *Clinical Infectious Diseases*, **44**, 1078–1083.
- Robinson, J.O., Lamoth, F., Bally, F., Knaup, M., Calandra, T. & Marchetti, O. (2011) Monitoring procalcitonin in febrile neutropenia: what is its utility for initial diagnosis of infection and reassessment in persistent fever? *PLoS One*, **6**, e18886.
- Roger, P.M., Vandenbos, F., Pugliese, P., De Salvador, F., Durant, J., Le Fichoux, Y. & Dellamonica, P. (1998) Persistence of *Pneumocystis carinii* after effective treatment of *P. carinii* pneumonia is not related to relapse or survival among patients infected with human immunodeficiency virus. *Clinical Infectious Diseases*, **26**, 509–510.
- Ruhnke, M., Böhme, A., Buchheidt, D., Cornely, O., Donhuijsen, K., Einsele, H., Enzensberger, R., Hebart, H., Heussel, C., Horger, M., Hof, H., Karthaus, M., Krüger, W., Maschmeyer, G., Penack, O., Ritter, J. & Schwartz, S. (2012) Diagnosis of invasive fungal infections in hematology and oncology. Guidelines from the Infectious Diseases Working Party in Haematology and Oncology of the German Society for Haematology and Oncology (AGIHO). *Annals of Oncology*, **23**, 823–833.
- Samonis, G. & Kontoyiannis, D.P. (2001) Infectious complications of purine analog therapy. *Current Opinion in Infectious Diseases*, **14**, 409–413.
- Sampsonas, F., Kontoyiannis, D.P., Dickey, B.F. & Evans, S.E. (2011) Performance of a standardized bronchoalveolar lavage protocol in a comprehensive cancer center: a prospective 2-year study. *Cancer*, **117**, 3424–3433.
- Schelenz, S., Barnes, R.A., Barton, R.C., Cleverley, J.R., Lucas, S.B., Kibbler, C.C., Denning, D.W. & British Society for Medical Mycology. (2015) British Society for Medical Mycology best practice recommendations for the diagnosis of serious fungal diseases. *The Lancet Infectious Diseases*, **15**, 461–474.
- Schiel, X., Link, H., Maschmeyer, G., Glass, B., Cornely, O.A., Buchheidt, D., Wilhelm, M., Silling, G., Helmerking, M., Hiddemann, W., Ostermann, H. & Hentrich, M. (2006) A prospective, randomized multicenter trial of the empirical addition of antifungal therapy for febrile neutropenic cancer patients: results of the Paul Ehrlich Society for Chemotherapy (PEG) Multicenter Trial II. *Infection*, **34**, 118–126.
- Segal, B.H., Herbrecht, R., Stevens, D.A., Ostrosky-Zeichner, L., Sobel, J., Viscoli, C., Walsh, T.J., Maertens, J., Patterson, T.F., Perfect, J.R., Dupont, B., Wingard, J.R., Calandra, T., Kauffman, C.A., Graybill, J.R., Baden, L.R., Pappas, P.G., Bennett, J.E., Kontoyiannis, D.P., Cordonnier, C., Viviani, M.A., Bille, J., Almyroudis, N.G., Wheat, L.J., Graninger, W., Bow, E.J., Holland, S.M., Kullberg, B.J., Dismukes, W.E. & De Pauw, B.E. (2008) Defining responses to therapy and study outcomes in clinical trials of invasive fungal diseases: Mycoses Study Group and European Organization for Research and Treatment of Cancer consensus criteria. *Clinical Infectious Diseases*, **47**, 674–683.
- Shorr, A.F., Susla, G.M. & O'Grady, N.P. (2004) Pulmonary infiltrates in the non-HIV-infected immunocompromised patient: etiologies, diagnostic strategies, and outcomes. *Chest*, **125**, 260–271.
- Smego, R.A. Jr, Nagar, S., Maloba, B. & Popara, M. (2001) A meta-analysis of salvage therapy for *Pneumocystis carinii* pneumonia. *Archives of Internal Medicine*, **161**, 1529–1533.
- Spiess, B., Buchheidt, D., Baust, C., Skladny, H., Seifarth, W., Zeifelder, U., Leib-Mosch, C., Morz, H. & Hehlmann, R. (2003) Development of a LightCycler PCR assay for detection and quantification of *Aspergillus fumigatus* DNA in clinical samples from neutropenic patients. *Journal of Clinical Microbiology*, **41**, 1811–1818.
- Stanzani, M., Sassi, C., Lewis, R.E., Tolomelli, G., Bazzocchi, A., Cavo, M., Vianelli, N. & Battista, G. (2015) High resolution computed tomography angiography improves the radiographic diagnosis of invasive mold disease in patients with hematological malignancies. *Clinical Infectious Diseases*, **60**, 1603–1610.
- Tortorano, A.M., Esposto, M.C., Prigitano, A., Grancini, A., Ossi, C., Cavanna, C. & Cascio, G.L. (2012) Cross-reactivity of Fusarium spp. in the *Aspergillus* galactomannan enzyme-linked immunosorbent assay. *Journal of Clinical Microbiology*, **50**, 1051–1053.
- Tryka, A.F., Godleski, J.J. & Fanta, C.H. (1982) Leukemic cell lysis pneumonopathy. A complication of treated myeloblastic leukemia. *Cancer*, **50**, 2763–2770.
- Vehreschild, J.J., Böhme, A., Buchheidt, D., Arenz, D., Harnischmacher, U., Heussel, C.P., Ullmann, A.J., Mousset, S., Hummel, M., Frommolt, P., Wassmer, G., Drziszga, I. & Cornely, O.A. (2007) A double-blind trial on prophylactic voriconazole or placebo during induction chemotherapy for acute myelogenous leukaemia. *Journal of Infection*, **55**, 445–449.
- Vogel, M.N., Vatlach, M., Weissgerber, P., Goepfert, B., Claussen, C.D., Hetzel, J. & Horger, M. (2012) HRCT-features of *Pneumocystis jirovecii* pneumonia and their evolution before and after treatment in non-HIV immunocompromised patients. *European Journal of Radiology*, **81**, 1315–1320.
- Weisser, M., Rausch, C., Droll, A., Simcock, M., Sendi, P., Steffen, I., Buitrago, C., Sonnet, S., Gratwohl, A., Passweg, J. & Flückiger, U. (2005) Galactomannan does not precede major signs on a pulmonary computerized tomographic scan suggestive of invasive aspergillosis in patients with hematological malignancies. *Clinical Infectious Diseases*, **41**, 1143–1149.
- White, P.L., Wingard, J.R., Bretagne, S., Löffler, J., Patterson, T.F., Slavin, M.A., Barnes, R.A., Pappas, P.G. & Donnelly, J.P. (2015) *Aspergillus* polymerase chain reaction: systematic review of evidence for clinical use in comparison with antigen testing. *Clinical Infectious Diseases*, **61**, 1293–1303.
- Williams, J.V., Martino, R., Rabella, N., Otegui, M., Parody, R., Heck, J.M. & Crowe, J.E. Jr (2005) A prospective study comparing human metapneumovirus with other respiratory viruses in adults with hematologic malignancies and respiratory tract infections. *Journal of Infectious Diseases*, **192**, 1061–1065.
- Zou, M., Tang, L., Zhao, S., Zhao, Z., Chen, L., Chen, P., Huang, Z., Li, J., Chen, L. & Fan, X. (2012) Systematic review and meta-analysis of detecting galactomannan in bronchoalveolar lavage fluid for diagnosing invasive aspergillosis. *PLoS One*, **7**, e43347.