

Non-osteotomy and osteotomy large animal fracture models in orthopedic trauma research

Sebastian Decker,¹ Janin Reifenrath,²
Mohamed Omar,¹ Christian Krettek,¹
Christian W. Müller¹

¹Trauma Department, Hannover Medical School; ²Small Animal Clinic, University of Veterinary Medicine Hannover, Germany

Abstract

Large animal fracture models are important in the field of orthopedic trauma research. New implants are tested in animals before being implanted into humans. Large animals like sheep or swine often are more properly to simulate conditions in humans, *e.g.* biomechanical demands, compared to rodents. Cited articles mainly analyze shock or fracture healing. Both osteotomy and non-osteotomy fracture models have been used in the past. However, comparative studies are rare and clear recommendation when to use which model are missing. This review will summarize large animal fracture models putting special emphasis on non-osteotomy fracture models.

Introduction

Fractures of weight-bearing bones are important in the field of orthopedic trauma surgery, and many operative techniques are available. The aim of current studies is to accelerate fracture consolidation for faster rehabilitation and to minimize complications, such as deep venous thrombosis.

Prior to testing new implants in humans *in vivo*, they must pass through an experimental phase consisting of biomechanical analysis, cadaveric bones, and *in vivo* testing in rodents and/or large animals. However, this phase varies according to the institution, experiment, and assumed experimental result, as well as the local ethical review committee.

Experiments with large animals can be suggestive and are necessary because biomechanical conformability with humans is better compared to small rodents. For example, the bone metabolism and postoperative behavior with a propensity for immediate weight-bearing in sheep is more in accordance with humans than the conditions in rodents.¹⁻³ In addition, the bones of large animals are often more suitable for instrumentation with nails, plates, or external fixators, and mechanical testing is

easier compared to rodents. Furthermore, the weight of large animals is more similar to humans than rodents, which is a big advantage when testing new implants and biomechanical stability. Therefore, validity is often much better and the results can better be interpreted in large animals compared to rodents with regard to implantation into humans. However, data as to the transfer from data of animal fractures to humans are limited and comparative studies are missing, especially as to the bone biology of different animals compared to humans.

Numerous fracture models exist for rodents, such as mice or rats.⁴ For large animals, fracture models mainly include osteotomy models and *real* fracture models for the analysis of primary fractures, as well as defect models and bone segment transport models to study how bone heals in the presence of a defect under various treatment options (*e.g.*, to simulate the treatment of non-union).^{5,6} To the best of our knowledge, no summary article yet reveals the known weight-bearing large animal fracture models, including sheep, dog, and swine. This review outlines the published options in this field of orthopedic trauma research.

Animal experiments: annotation

Authors support the 3R concept introduced by William M.S. Russel and Rex L. Burch in 1959.⁷ The concept involves reduction of the total number of laboratory animals, refinement to reduce suffering, and replacement to explore new research approaches that minimize distress. Alternatives to animal experiments should be used whenever possible.

Search strategy and exclusion criteria

We searched PubMed Medline for articles describing large animal fracture models. Different query syntaxes were used to ensure that no large animal fracture or osteotomy model was missed: [*sheep* and *osteosynthesis*], [*sheep* and *fracture* and *model*], [*sheep* fracture model], [*dog* and *fracture* and *model*], [*pig* and *fracture* and *model*], [*horse* and *fracture* and *model*], [*cow* and *fracture* and *model*], [*porcine* and *fracture* and *model*], [*swine* and *fracture* and *model*], [*equine* and *fracture* and *model*], [*bovine* and *fracture* and *model*] and [*large animal* and *fracture* and *model*]. We also screened the reference lists of selected articles and articles provided by the *Related Citations* function in PubMed Medline.

No restriction was made for language, jour-

Correspondence: Sebastian Decker, Trauma Department, Hannover Medical School, Carl-Neuberg Strasse 1, 30625 Hannover, Germany. Tel.: +49.511.532.2050 - Fax: +49.511.532.5877. E-mail: decker.sebastian@mh-hannover.de

Key words: fracture, large animal, sheep, fracture healing, non-osteotomy fracture model.

Acknowledgements: this work was funded by the Deutsche Forschungsgemeinschaft (DFG, SFB 599, TP D10). The authors would like to thank the DFG for their support.

Contributions: SD, CWM, conception, literature research, writing; JR, conception, literature research; MO, CK, literature research, correction.

Conflict of interests: the authors declare no potential conflict of interests.

Received for publication: 28 July 2014.

Revision received: 12 October 2014.

Accepted for publication: 18 October 2014.

This work is licensed under a Creative Commons Attribution NonCommercial 3.0 License (CC BY-NC 3.0).

©Copyright S. Decker et al., 2014
Licensee PAGEPress, Italy
Orthopedic Reviews 2014; 6:5575
doi:10.4081/or.2014.5575

nal of publication, or the time of publication. All resulting articles not referring to any mature large animal fracture model or osseous fracture model (*e.g.*, dental crown fractures) were excluded, followed by papers describing fracture models in non-weight-bearing bones, such as the mandible. Moreover all papers not providing detailed information, *e.g.* a description of the operative technique, were excluded.

Appropriate large animals for fracture models

The decision regarding which large animal best creates a fracture model does not depend only on similarity to humans, but also on ethical aspects, effort, and cost. Strict guidelines are still missing. To the best of our knowledge, no study has compared different large animal fracture models to investigate which large animal is most suitable with respect to the transferability of results to humans. Most researchers seem to prefer sheep and swine, but for the most part precise substantiations are missing. Because different fracture models are described in the journal articles, we also searched for a comparison of the different methods for creating a fracture to simulate fracture healing, roughly osteotomy *vs.* bend-

ing or shooting techniques, as little is known about whether extrapolating from osteotomy models to the live fracture healing process is appropriate. Dumont *et al.* compared monocortical osteotomy combined with a manual fracture of the opposite corticalis to a *random fracture*. Bone healing after saw osteotomy is comparable to the healing of *normal* fractures, but vascular density, fragment resorption, fragment remodeling, and callus remodeling are reduced at the osteotomy site.⁸ Moreover it has to be considered, that specific characteristics of bone differ between animals and humans. Sheep bone provides similar macrostructure, however microstructure differs from humans, the same applies for pigs. In contrast, dogs bone seems to be more similar with human bone.⁹

No study was found to analyze these aspects in large animals. However, Park *et al.* compared the healing process in an open osteotomy model and closed fracture model using rabbit tibiae fixed with four-pin double-bar external fixators. Fracture healing was retarded in the osteotomy group. Striking differences were found in hematoma formation, periosteal damage, muscle laceration, and callus formation, finally leading to different biomechanical characteristics of the *new* built bone.¹⁰ Based on this previous work, we focused on non-osteotomy fracture models as the results seem to be better compared to human fracture healing.

Fracture models

Although many researchers are familiar with small animal models, for different reasons the experiments with large animal fractures are done by only a minority of investigators. We wanted to provide a detailed description of operative techniques used to create large animal fracture models. Here, test experiments are described in the detail provided by the cited authors. We distinguish between fracture and osteotomy models for the simulation of fracture healing as comparability is still doubtful, though Dumont *et al.* stated that results from osteotomy fracture models can be compared to random fractures.⁸

Three different animals were used in 20 publications describing non-osteotomy large animal fracture models: dogs (n=1), sheep (n=10), and swine (n=9) (Table 1).¹¹⁻³⁰ The objectives of the experiments were different, and not all authors focused on fracture healing. The following aspects were analyzed in the studies: the use of blood products and transfusion during the treatment of trauma, shock, and resuscitation, trauma-associated coagulation and blood flow, fracture healing in general, compartment syndrome, shock, and the development of a new model for combat-related injury.

Operative technique

Basically, two non-osteotomy large animal

fracture models are described in the literature, roughly bending *vs.* shooting techniques. The described details vary widely.

Dogs

Moed and Strom present a technique for creating a canine spiral tibia fracture model. First, the intramedullary canal was opened using an awl, followed by the insertion of a drill in the oblique position to perforate the cortex of the tibia shaft at a predetermined breaking point. Next, a *manual torsional force* was applied to complete the fracture through the intramedullary stress riser, and reamed intramedullary nailing was performed.¹¹ The process was achieved as published by Hansen *et al.*³¹ Moed and Strom used a 9-mm cloverleaf-shaped open segment nail. The complete process was documented by X-rays. Intra-operatively, alignment was assured manually. In dogs, this study was the only investigation describing a weight-bearing fracture model.

Sheep

In contrast, nine studies have been published on sheep. Schemitsch *et al.* presented a fracture model in sheep tibiae. For optimal access during the procedure, the sheep were in the supine position. The scrub and cover were similar to that used in humans. An anteromedial incision in the lower leg down to the distal tibial metaphysis was made starting medial to the patellar tendon and proximal to the tibial tubercle, followed by deep dissection. For optimal exposure of the tibial cortical sur-

Table 1. Non-osteotomy fracture models.

Author [Ref.]	Year	N. animals	Weight of animals (kg)	Medication for anesthesia	Fractured bone	Fixing technique	Medication for euthanization
Dog							
Moed <i>et al.</i> [11]	1991	20	34.02	General anesthesia	Tibia	Nailing	*
Sheep							
Baumgaertel <i>et al.</i> [16]	1998	36	*	*	Femur	Plating	*
Gray <i>et al.</i> [19]	2009	24	45.75	Etomidate, midazolam, halothane	Femur	External fixation/nailing	Pentobarbital
Klein <i>et al.</i> [20]	2010	16	*	*	Tibia	Nailing	*
Kregor <i>et al.</i> [17]	1995	18	30-40	Thiamylal sodium, halothane	Tibia	Plating	Pentobarbital
Schemitsch <i>et al.</i> [13]	1994	11	33-40	Thiamylal sodium, halothane	Tibia	Nailing	Potassium chloride, pentobarbital sodium
Schemitsch <i>et al.</i> [14]	1995	10	33-38	Thiamylal sodium, halothane	Tibia	Nailing	Potassium chloride, pentobarbital sodium
Schemitsch <i>et al.</i> [15]	1996	10	33-40	Thiamylal sodium, halothane	Tibia	Nailing	Potassium chloride, pentobarbital sodium
Schemitsch <i>et al.</i> [12]	1998	10	33-40	Thiamylal sodium, halothane	Tibia	Nailing	Potassium chloride, pentobarbital sodium
White <i>et al.</i> [18]	2006	21	35-50	Etomidate, midazolam, halothane	Femur/tibia	Nailing	Pentobarbital
Högel <i>et al.</i> [30]	2011	24	65-70	Isoflurane	Tibia	Nailing	*
Swine							
Alam <i>et al.</i> [28]	2009	21	36.29-54.43	Telazol, atropine, isoflurane	Femur	*	Sodium pentobarbital
Alam <i>et al.</i> [29]	2009	60	35-45	Telazol, atropine, isoflurane	Femur	*	Sodium pentobarbital
Cho <i>et al.</i> [26]	2009	37	38.6-40.8	Telazol, atropine, isoflurane	Femur	*	*
Patel <i>et al.</i> [24]	2007	20	30-35	Ketamine, xylazine, fentanyl	Femur	*	*
Shuja <i>et al.</i> [23]	2008	24	36.29-54.43	Telazol, atropine, isoflurane	Femur	*	Sodium pentobarbital
Shuja <i>et al.</i> [22]	2011	14	36.29-54.43	Telazol, atropine, isoflurane	Femur	*	Sodium pentobarbital
Spoerke <i>et al.</i> [25]	2009	32	*	Telazol, atropine, isoflurane	Femur	*	*
Swiontkowski <i>et al.</i> [27]	1993	10	50-70	Azaperon, atropine sulfate, ketamine, halothane	Femoral neck	Kirschner wire/screw	Barbiturate
White <i>et al.</i> [20]	2010	26	40-50	Ketamine, xylazine, sodium pentathol, alphachloralose,	Femur	*	Potassium chloride

*No information provided or obtained during the study.

face when creating the fracture, Schemitsch *et al.* performed a longitudinal incision in the periosteum on top of the medial diaphysis cortex of the tibia, and split the fascia medial to the patellar tendon (30 mm) for exposition of the cortex proximal to the tibial tubercle. Finally, the periosteum was elevated and shifted sideways, anteriorly, and posteriorly. The circumference of the midtibial diaphysis was exposed subperiosteally. A 1-mm-deep predetermined breaking point was created in the exact middle of the tibia in a 45° angle at the medial cortical surface using an oscillating saw. The leg was fixed in external rotation and a fracture apparatus (Tepic and Predieri, Laboratory for Experimental Surgery, Davos, Switzerland) placed in position subperiosteally. The apparatus was released to create a short, reproducible spiral fracture (Figure 1A). The underlying process was three-point bending with torsional force. The complete detachment of the fragments (including the endosteum) was controlled, and accomplished using forceps if necessary. For osteosynthesis, fractures were reduced and fixed by intramedullary reamed and unreamed nailing using an AO tibial rod. For the procedure, the knee was flexed and the patellar tendon retracted laterally to create a portal to the medullary canal using an awl. Interlocking was performed both proximally and distally. At the end of the procedure, the wound was irrigated and then closed in layers, including the periosteum.¹²⁻¹⁵ Klein *et al.* also presented a tibia fracture model in sheep. Animals were positioned in the supine position for the procedure. After scrubbing and shaving, a longitudinal skin incision was made. The tibia was prepared without damage to the periosteum and a predetermined breaking point created 11 cm proximal to the medial malleolus one-third the thickness of the tibial diameter using a saw with liquid cooling. The fracture was created using four-point bending. Hand-drills were used to access the medullary cavity. Intramedullary nailing using a static interlocking nail was performed after optional reaming. Two interlocking screws were inserted. The procedure efficiency was evaluated by X-rays.²⁰ The same operative technique was used by Högel *et al.* who also studied intramedullary nailing.³⁰

Kregor *et al.* also described a tibia fracture model in sheep. A medial incision (12 cm) exposed the periosteum medially. Dissection was performed using sharp devices and electrocautery for hemostasis. The periosteum was incised longitudinally in the midline of the medial tibia. At the ends, transverse incisions were made in the periosteum before circumferential elevation and mounting the three-point bending fracture apparatus (Tepic and Predieri, Laboratory for Experimental Surgery, Davos, Switzerland). A reproducible spiral oblique tib-

ial fracture was created after generating a breakage similar to that of Schemitsch *et al.*, but deeper (2 mm *vs.* 1 mm), in the medial part of the tibia. After creating the fracture, it was reduced and medial plating performed after insertion of an interfragmentary lag screw. Finally, the wound was closed in layers.¹⁷

In contrast to the previously cited authors, Gray *et al.* reported a model for creating femoral shaft fractures. After stabilization of the femora according to White *et al.* a 4-cm longitudinal skin incision was made distally from the level of the greater trochanter.^{18,19} The proximal femur was exposed and a femoral stabilizing subtrochanteric cable fixed. Gray *et al.* chose a muscle-splitting approach. Distal femora were fixed with a knee clamp and correct positioning of the sheep, implying minimal potential movement, was assured. A pneumatic fracture device (Norgren Limited, Staffordshire, United Kingdom) was used to create shaft fractures with additional overlying soft-tissue trauma (Figure 1B). A pressure of

1.1 MPa was used to generate a force of 8600 N. Gray *et al.* stabilized the fractures by either external fixation or intramedullary nailing. The external fixator was fixed via two pins proximal and distal to the fracture and connected unilaterally. For intramedullary nailing, a 3 to 4-cm anterior midline incision was made above the knee, and access to the medullary canal was obtained through a medial parapatellar approach. After reaming, nails were inserted in a retrograde manner. The fracture model reported by Gray *et al.* was described first by White *et al.*, but in less detail. In addition to the procedure reported by Gray *et al.*, White *et al.* also created tibial fractures using the same technique. For osteosynthesis, both performed an arthrotomy of the knee, reamed the tibia, and inserted an intramedullary nail. Femoral fractures were fixed by external fixation.^{18,19} Baumgaertel *et al.* developed a fracture model for a reproducible subtrochanteric femoral fracture. Osteosynthesis was done by plating, with or without prior reduction.¹⁶

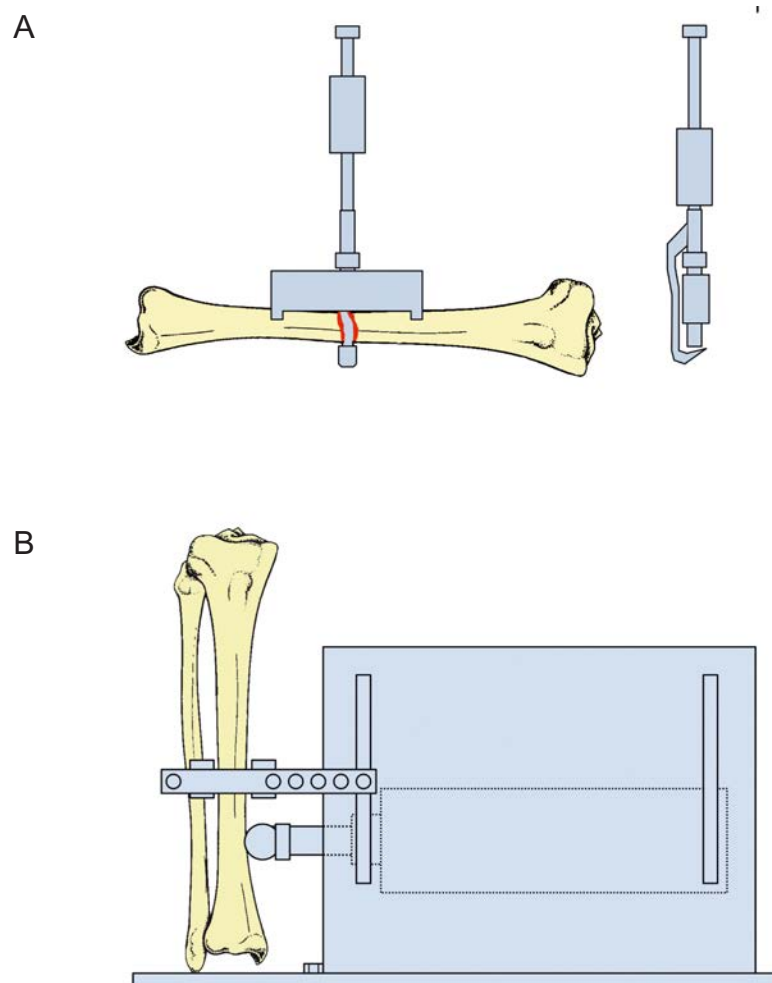


Figure 1. A) Fracture apparatus by Tepic and Predieri. The bone was broken using 3-point-bending. B) Pneumatic fracture device. The bone/leg was fixed and the trigger used to initiate the impact head impinging on the leg/bone.

Swine

Shuja *et al.* described a femoral fracture model. After localization of the mid-shaft of the femur, a cruciate incision was made and a captive bolt gun (Model RS22, Ramset-Powder Fastening System, Glendale Heights, IL, USA) applied. Triggering resulted in a mid-shaft multi-fragment femoral fracture and soft tissue injury. The femur fracture was confirmed manually by palpation. No osteosynthesis was performed.²²⁻²³ A similar technique was used by Cho *et al.*, with the use of another captive bolt gun (Schermer Stunner Model MKL, Karl Schermer and Co, Karlsruhe, Germany).²⁶ Alam *et al.* also generated a femur shaft fracture using the technique of Cho *et al.* and Shuja *et al.* with no modifications mentioned.^{28,29} White *et al.* and Patel *et al.* also reported the same technique.^{21,24} Spoerke *et al.* also directly referred to Cho *et al.*²⁵

These fracture models in swine were all created using a captive bolt gun to create femoral shaft fractures. Swiontkowski *et al.* described a technique to simulate a femoral neck fracture. After scrubbing, the authors performed an anterolateral approach to the hip joint and proximal femur. The femoral head was distracted from the acetabulum 2 to 3 mm using a distractor spanned between two pins, one in the ilium and one in the midshaft of the femur. The fracture was created by grooving the superior, posterior, and anterior neck in the middle of the femoral neck using an oscillating saw. Next, an osteotomy was used for completion. Fixation of the fracture was achieved using 2.0-mm Kirschner wires and 4.0-mm cancellous screws. Previous distraction allowed the surgeon to ensure that the screws or wires were not perforating the femoral head into the hip joint. This technique of creating a fracture could also be assigned to osteotomy models, but in this review we allocate it to fracture models.²⁷

Recovery protocol after operation

Recovery protocols are dependent on the study type and previous operations. Consequently, they cannot be copied without appropriate preservation. Many of the cited studies euthanized the animals directly after the procedure or did not provide details as to the recovery protocol.

Sheep

Schemitsch *et al.* wrapped the operated legs of the sheep in a tensor bandage pressure dressing for 3 days. As already described, an antibiotic prophylaxis was given. For analgesia, animals received i.m. oxymorphone twice daily for 3 days postoperatively. No restrictions were made regarding weight-bearing and activity. Animals were held in individual cages for recovery. The authors assessed full weight-bearing from day 7 to 10.¹²⁻¹⁵ Kregor *et al.* also

administered an antibiotic prophylaxis, as well as 0.005 mg/kg buprenorphine hydrochloride twice daily for 48 hours. Individual cages were used for 2 days with food and water available *ad libitum*.¹⁷

Swine

Only Swiontkowski *et al.* included postoperative survival in swine. However, the details of the recovery protocol were not described. Animals started a *four-pointed gait* on postoperative day 3 to 4.²⁷

Euthanization

Some study protocols included the euthanization of the treated animals at the end of the procedure.

Sheep

Kregor *et al.*, White *et al.*, and Gray *et al.* used an i.v. overdose of pentobarbital sodium for euthanization. The animals in Gray *et al.* and White *et al.* were under general anesthesia when killed.¹⁷⁻¹⁹ In contrast, Schemitsch *et al.* used an i.v. overdose of potassium chloride and pentobarbital sodium while the sheep were narcotized.¹²⁻¹⁵ Kregor *et al.* reported 1.3 grains/kg pentobarbital, and Gray *et al.* reported 60 mg/kg pentobarbital.¹⁹

Swine

Shuja *et al.* and Alam *et al.* reported the use of 100 mg/kg sodium pentobarbital under anesthesia.^{22,23,28,29} In contrast, White *et al.* reported the use of i.v. potassium chloride under anesthesia. No additional barbiturate was used.²¹ Spoerke *et al.* only stated that animals were killed *chemically*.²⁵ Detailed information about euthanization was not provided by Patel *et al.* or Cho *et al.*^{24,26}

Osteotomy models

Osteotomy models are another option for simulating fractures in large animals and are always open fracture models. Most authors who create large animal fracture models appear to use osteotomies, which are standardized and can be performed similarly in each animal. Therefore, comparability is expected to be high. Extrapolation from osteotomy results to *normal* fractures in large animals is reasonable based on current knowledge. Dumont *et al.* compared monocortical osteotomies and manual fractures of the opposite corticalis with proper fractures in sheep and found slight differences, including reduced vascular density, fragment resorption, and reduced fragment and callus remodeling in the osteotomy group.⁸ Park *et al.* tested transferability in rodents and reported delayed healing in the open osteotomy group compared to the closed fracture group.¹⁰

Different aspects influence fracture healing and are dependent on the fracture model used. In osteotomy models, the cut surfaces are smooth and not as manifold as in real fractures. The periosteum is cut and the bone damaged by frictional heat, which affects the healing process. Irrigation during sawing minimizes the frictional heat but also flushes away the initial hematoma, which itself is very important for fracture healing.³² Though few studies describing fracture models have been published thus far, many can be found describing techniques comprising osteotomy models.

Authors prefer sheep for the simulation of fracture healing in non-osteotomy models. The variety of used long bones is larger in the literature as to osteotomy models. For example, in different large animals osteotomies have been performed in the femur, tibia, metatarsus, and radius (Table 2).³³⁻⁶¹

The operative technique is usually similar. After skin incision and preparation down to the bone, an oscillating saw or osteotome is used to cut through the bone. Irrigation may or may not be applied for cooling. Either the complete bone is cut through, or just half of it followed by manual breakage of the opposite side.^{8,33} Details about the preparation vary depending on the animal, specific bone, and operative approach. Although most authors seem to agree with using osteotomy to simulate fractures in large animals, two different techniques are found in the literature: oblique and transverse osteotomy.³³⁻³⁵ Differentiation is important as the technique first has to be adjusted to the implant used. For example, an interfragmentary compression screw can better be tested in an oblique osteotomy. Moreover, differently shaped osteotomies simulate different human fracture types. This distinction is important because, for example, transverse long bone fractures (classified AO A3) exhibit less potential for fracture healing but a higher rate of non-union, presumably because the surfaces of the fragments are smaller in transverse fractures.

In large animals, osteotomies have been performed to simulate fractures in different bones and animals. Though the technique for osteotomy is always more or less similar, the method of fixation differs widely. All fixation devices known from human surgery can also be tested in large animals. A short exemplary overview of osteotomy models published thus far for the simulation of fresh fractures in large animals is given in Table 2; no segmental defect or bone transport models are included, or models with purposely created gaps greater than 3 mm. Fracture gaps with a width of 3 mm are supposed to allow micromovement, which itself has been shown to improve fracture healing. Therefore, many authors explicitly mention that they created a gap as described by Goodship and Kenwright.³⁶

Table 2. Animals, bones, and techniques used in osteotomy large animal fracture models.

Author [Ref.]	Year of publication	Bone	Osteotomy shape	Fixing technique	Weight of animals (kg)
Dog					
An <i>et al.</i> [37]	1998	Femur	Transverse/oblique	Screw	~25
Gilbert <i>et al.</i> [38]	1989	Tibia	Transverse	External fixation	26-32
Sheep					
Aguilar <i>et al.</i> [39]	2002	Tibia	Transverse	Nailing	40-50
Challis <i>et al.</i> [40]	2006	Tibia	Transverse	Kirschner wire	25.5-44
Christel <i>et al.</i> [41]	1984	Metatarsus	Transverse	Nailing	*
Claes <i>et al.</i> [42]	1999	Metatarsus	Wedge fragments	Plating, nailing, external fixation, screws	~53
Dumont <i>et al.</i> [8]	2008	Metatarsus	Transverse/oblique	Plating	67-98
Duwelius <i>et al.</i> [43]	1997	Metatarsus	Oblique	Nailing	45-60
Goebel <i>et al.</i> [44]	2009	Metatarsus	*	External fixation	62-84
Goodship <i>et al.</i> [36]	1985	Metatarsus	Transverse	External fixation	*
Hantes <i>et al.</i> [35]	2004	Metatarsus	Transverse	External fixation	45-55
Hill <i>et al.</i> [45]	2002	Metatarsus	Chevron	Nailing	55-80
Högel <i>et al.</i> [46]	2010	Femur	Transverse	Nailing	*
Klaue <i>et al.</i> [47]	1991	Femur	Oblique	Plating	50-65
Klaue <i>et al.</i> [48]	2000	Femur	*	Plating	48-64
Kostopoulos <i>et al.</i> [49]	1994	Radius	Transverse	Plating	33-38
Lu <i>et al.</i> [50]	2009	Radius	Transverse	Nailing, Braid system	69.7-75.3
Mayer <i>et al.</i> [51]	1983	Tibia	Transverse	External fixation	*
Mousavi <i>et al.</i> [52]	2002	Tibia	Transverse	Nailing	30-47
Plecko <i>et al.</i> [53]	2012	Tibia	Oblique	Plating	52-94
Schaer <i>et al.</i> [33]	2012	Tibia	Transverse	Plating	*
Seligson <i>et al.</i> [55]	1997	Tibia	*	Plating	*
Stoffel <i>et al.</i> [34]	2000	Tibia	Oblique	Plating	45-72
van der Elst <i>et al.</i> [57]	1998	Femur	Transverse	Nailing	*
Wolinsky <i>et al.</i> [58]	1996	Femur	*	Nailing	*
Zoltie <i>et al.</i> [59]	1988	Femur	Oblique	Plating	*
Swine					
Hasegawa <i>et al.</i> [60]	2002	Tibia	Crank-shaped	Screws	22-27
Seiler <i>et al.</i> [61]	1996	Femoral neck	Transverse	Screws	40-60

*No information provided or obtained during the study.

Summary and conclusions

Weight-bearing large animal fracture models are of great interest in the field of orthopedic trauma research.

Published articles report two non-osteotomy options to simulate a fracture: bending techniques and shooting techniques. Though bending techniques seem to be used to test bone healing, shooting techniques have been used to simulate shock models as the combination with accompanying soft tissue injuries seems to be more realistic for simulating circumstances in multiple injury patients. Moreover, the cited studies favored sheep for analyzing fracture healing, whereas swine were used for shock research. Study execution varied greatly. However, the information on anesthesia is comparable to humans, at least with respect to the medications used. Operative techniques were performed as they are in humans. Most authors used nailing for fracture fixation in the non-osteotomy fracture models. Shock models did not include any fracture fixation. For euthanization, authors preferred an overdose of barbiturates. Little has

been reported regarding the recovery protocols, which have to be adjusted to the study being performed and include sufficient analgesia, as well as antibiotic prophylaxis if appropriate.

Many authors created osteotomy models in large animals that are now standardized. Both oblique and transverse osteotomies have been performed. In contrast, less is known about non-osteotomy fracture models. Thus far only one author analyzed and confirmed the transferability of results from osteotomy and non-osteotomy large animal fracture models to real fractures.⁸ In contrast, one study examined this context in small animals; Park *et al.* showed that non-osteotomy fracture models are more realistic for simulating human fracture healing.¹⁰ Data about the *perfect* fracture model design in large animals are still missing, giving rise to prospective research. As operative techniques like intramedullary nailing or plating are often more easily performed in large animals and more comparable to humans, this aspect of research is of great interest for developing new techniques to simulate fracture healing.

References

1. Simmons DJ. In: Bourne GH, ed. The biochemistry and physiology of bone. New York: Academic Press; 1976. p. 445.
2. Nunamaker DM. Experimental models of fracture repair. Clin Orthop Relat Res 1998;S56-65.
3. Staller GS, Richardson DW, Nunamaker DM, Provost M. Contact area and static pressure profile at the plate-bone interface in the nonluted and luted bone plate. Vet Surg 1995;24:299-307.
4. Histing T, Garcia P, Holstein JH, et al. Small animal bone healing models: standards, tips, and pitfalls results of a consensus meeting. Bone 2011;49:591-9.
5. Sarkar MR, Augat P, Shefelbine SJ, et al. Bone formation in a long bone defect model using a platelet-rich plasma-loaded collagen scaffold. Biomaterials 2006;27:1817-23.
6. Knothe Tate ML, Ritzman TF, Schneider E, Knothe UR. Testing of a new one-stage bone-transport surgical procedure exploiting the periosteum for the repair of long-

- bone defects. *J Bone Joint Surg Am* 2007; 89:307-16.
7. Russell WMS, Burch RL. The principles of humane experimental technique. London: Methuen; 1959.
 8. Dumont C, Kauer F, Bohr S, et al. Long-term effects of saw osteotomy versus random fracturing on bone healing and remodeling in a sheep tibia model. *J Orthop Res* 2009;27:680-6.
 9. Pearce AI, Richards RG, Milz S et al. Animal models for implant biomaterial research in bone: a review. *Eur Cell Mater* 2007;13:1-10.
 10. Park SH, O'Connor K, Sung R, et al. Comparison of healing process in open osteotomy model and closed fracture model. *J Orthop Trauma* 1999;13:114-20.
 11. Moed BR, Strom DE. Compartment syndrome after closed intramedullary nailing of the tibia: a canine model and report of two cases. *J Orthop Trauma* 1991;5:71-7.
 12. Schemitsch EH, Turchin DC, Kowalski MJ, Swiontkowski MF. Quantitative assessment of bone injury and repair after reamed and unreamed locked intramedullary nailing. *J Trauma* 1998;45: 250-5.
 13. Schemitsch EH, Kowalski MJ, Swiontkowski MF, Senft D. Cortical bone blood flow in reamed and unreamed locked intramedullary nailing: a fractured tibia model in sheep. *J Orthop Trauma* 1994;8:373-82.
 14. Schemitsch EH, Kowalski MJ, Swiontkowski MF, Harrington RM. Comparison of the effect of reamed and unreamed locked intramedullary nailing on blood flow in the callus and strength of union following fracture of the sheep tibia. *J Orthop Res* 1995;13:382-9.
 15. Schemitsch EH, Kowalski MJ, Swiontkowski MF. Soft-tissue blood flow following reamed versus unreamed locked intramedullary nailing: a fractured sheep tibia model. *Ann Plast Surg* 1996;36:70-5.
 16. Baumgaertel F, Buhl M, Rahn BA. Fracture healing in biological plate osteosynthesis. *Injury* 1998;29:C3-6.
 17. Kregor PJ, Senft D, Parvin D, et al. Cortical bone perfusion in plated fractured sheep tibiae. *J Orthop Res* 1995;13:715-24.
 18. White TO, Clutton RE, Salter D, et al. The early response to major trauma and intramedullary nailing. *J Bone Joint Surg Br* 2006;88:823-7.
 19. Gray AC, White TO, Clutton E, et al. The stress response to bilateral femoral fractures: a comparison of primary intramedullary nailing and external fixation. *J Orthop Trauma* 2009;23:90-9.
 20. Klein C, Sprecher C, Rahn BA, et al. Unreamed or RIA reamed nailing: an experimental sheep study using comparative histological assessment of affected bone tissue in an acute fracture model. *Injury* 2010;41:S32-7.
 21. White NJ, Martin EJ, Brophy DF, Ward KR. Coagulopathy and traumatic shock: characterizing hemostatic function during the critical period prior to fluid resuscitation. *Resuscitation* 2010;81:111-6.
 22. Shuja F, Finkelstein RA, Fukudome E, et al. Development and testing of low-volume hyperoncotic, hyperosmotic spray-dried plasma for the treatment of trauma-associated coagulopathy. *J Trauma* 2011;70:664-71.
 23. Shuja F, Shults C, Duggan M, et al. Development and testing of freeze-dried plasma for the treatment of trauma-associated coagulopathy. *J Trauma* 2008;65:975-85.
 24. Patel MB, Earle SA, Majetschak M. Dynamics of tissue ubiquitin pools and ubiquitin-proteasome pathway component activities during the systemic response to traumatic shock. *Physiol Res* 2007;56:547-57.
 25. Spoerke N, Zink K, Cho SD, et al. Lyophilized plasma for resuscitation in a swine model of severe injury. *Arch Surg* 2009;144:829-34.
 26. Cho SD, Holcomb JB, Tieu BH, et al. Reproducibility of an animal model simulating complex combat-related injury in a multiple-institution format. *Shock* 2009;31:87-96.
 27. Swiontkowski MF, Tepic S, Rahn BA, et al. The effect of fracture on femoral head blood flow. Osteonecrosis and revascularization studied in miniature swine. *Acta Orthop Scand* 1993;64:196-202.
 28. Alam HB, Shuja F, Butt MU, et al. Surviving blood loss without blood transfusion in a swine poly-trauma model. *Surgery* 2009;146:325-33.
 29. Alam HB, Bice LM, Butt MU, et al. Hemostatic resuscitation research group. Testing of blood products in a polytrauma model: results of a multi-institutional randomized preclinical trial. *J Trauma* 2009; 67:856-64.
 30. Högel F, Schlegel U, Südkamp N et al. Fracture healing after reamed and unreamed intramedullary nailing in sheep tibia. *Injury* 2011;42:667-74.
 31. Hansen ST, Veith RG. In: Browner BD, Edwards CC, eds. Closed Kuntscher nailing of the tibia. The Science and practice of intramedullary nailing. Philadelphia: Lea & Febiger; 1987. pp 267-279.
 32. Rhinelander FW. Tibial blood supply in relation to fracture healing. *Clin Orthop Relat Res* 1974;34:81.
 33. Schaer TP, Stewart S, Hsu BB, Klibanov AM. Hydrophobic polycationic coatings that inhibit biofilms and support bone healing during infection. *Biomaterials* 2012;33:1245-54.
 34. Stoffel K, Klaue K, Perren SM. Functional load of plates in fracture fixation in vivo and its correlate in bone healing. *Injury* 2000;31:SB37-50.
 35. Hantes ME, Lavrodontidis AN, Zalavras CG, et al. Low-intensity transosseous ultrasound accelerates osteotomy healing in a sheep fracture model. *J Bone Joint Surg Am* 2004;86A:2275-82.
 36. Goodship AE, Kenwright J. The influence of induced micromovement upon the healing of experimental tibial fractures. *J Bone Joint Surg Br* 1985;67:650-5.
 37. An YH, Friedman RJ, Powers DL, et al. Fixation of osteotomies using bioabsorbable screws in the canine femur. *Clin Orthop Relat Res* 1998;300:11.
 38. Gilbert JA, Dahners LE, Atkinson MA. The effect of external fixation stiffness on early healing of transverse osteotomies. *J Orthop Res* 1989;7:389-97.
 39. Aguilar MM, Battistella FD, Owings JT, et al. Posttraumatic lymphocyte response: a comparison between peripheral blood T cells and tissue T cells. *J Trauma* 1998;45:14-8.
 40. Challis MJ, Gaston P, Wilson K, et al. Cyclic pneumatic soft-tissue compression accelerates the union of distal radial osteotomies in an ovine model. *J Bone Joint Surg Br* 2006;88:411-5.
 41. Christel P, Meunier A, Abols Y, et al. Callus characteristics following intramedullary nailing with stainless steel or epoxy-carbon nails. *Arch Orthop Trauma Surg* 1984;103:131-6.
 42. Claes L, Heitemeyer U, Krischak G, et al. Fixation technique influences osteogenesis of comminuted fractures. *Clin Orthop Relat Res* 1999;221-9.
 43. Duwelius PJ, Huckfeldt R, Mullins RJ, et al. The effects of femoral intramedullary reaming on pulmonary function in a sheep lung model. *J Bone Joint Surg Am* 1997;79:194-202.
 44. Goebel S, Lienau J, Rammoser U, et al. FGF23 is a putative marker for bone healing and regeneration. *J Orthop Res* 2009;27:1141-6.
 45. Hill PF, Clasper JC, Parker SJ, Watkins PE. Early intramedullary nailing in an animal model of a heavily contaminated fracture of the tibia. *J Orthop Res* 2002;20:648-53.
 46. Högel F, Gerlach UV, Südkamp NP, Müller CA. Pulmonary fat embolism after reamed and unreamed nailing of femoral fractures. *Injury* 2010;41:1317-22.
 47. Klaue K, Kowalski M, Perren SM. Internal fixation with a self-compressing plate and

- lag screw: improvements of the plate hole and screw design. 2. In vivo investigations. *J Orthop Trauma* 1991;5:289-96.
48. Klaue K, Fengels I, Perren SM. Long-term effects of plate osteosynthesis: comparison of four different plates. *Injury* 2000;31:SB51-62.
 49. Kostopoulos V, Vellios L, Fortis AP, et al. Comparative study of callus performance achieved by rigid and sliding plate osteosynthesis based upon dynamic mechanical analysis. *J Med Eng Technol* 1994;18:61-6.
 50. Lu Y, Nemke B, Lorang DM, et al. Comparison of a new braid fixation system to an interlocking intramedullary nail for tibial osteotomy repair in an ovine model. *Vet Surg* 2009;38:467-76.
 51. Mayer G, Wolf E. Animal experiments to examine the histology of fracture healing in osteosynthesis with external fixation and compression. *Arch Orthop Trauma Surg* 1983;101:111-20.
 52. Mousavi M, David R, Schwendenwein I, et al. Influence of controlled reaming on fat intravasation after femoral osteotomy in sheep. *Clin Orthop Relat Res* 2002;263-70.
 53. Plecko M, Lagerpusch N, Pegel B, et al. The influence of different osteosynthesis configurations with locking compression plates (LCP) on stability and fracture healing after an oblique 45° angle osteotomy. *Injury* 2012;43:1041-51.
 54. Schaer TP, Stewart S, Hsu BB, Klivanov AM. Hydrophobic polycationic coatings that inhibit biofilms and support bone healing during infection. *Biomaterials* 2012;33:1245-54.
 55. Seligson D, Mehta S, Mishra AK, et al. In vivo study of stainless steel and Ti-13Nb-13Zr bone plates in a sheep model. *Clin Orthop Relat Res* 1997;213-23.
 56. Stoffel K, Klaue K, Perren SM. Functional load of plates in fracture fixation in vivo and its correlate in bone healing. *Injury* 2000;31:SB37-50.
 57. van der Elst M, Bramer JA, Klein CP, et al. Biodegradable interlocking nails for fracture fixation. *Clin Orthop Relat Res* 1998;192-204.
 58. Wolinsky PR, Sciadini MF, Parker RE, et al. Effects on pulmonary physiology of reamed femoral intramedullary nailing in an open-chest sheep model. *J Orthop Trauma* 1996;10:75-80.
 59. Zoltie N, Katsaros J, Tan E. The sheep as a model for grade III human tibial trauma. *J Reconstr Microsurg* 1988;4:399-402.
 60. Hasegawa Y, Sakano S, Iwase T, Warashina H. The long-term behavior of poly-L-lactide screws in a minipig fracture model: preliminary report. *J Biomed Mater Res* 2002;63:679-85.
 61. Seiler JG 3rd, Kregor PJ, Conrad EU 3rd, Swiontkowski MF. Posttraumatic osteonecrosis in a swine model. Correlation of blood cell flux, MRI and histology. *Acta Orthop Scand* 1996;67:249-54.