



ELSEVIER

Contents lists available at [ScienceDirect](https://www.sciencedirect.com)

# Trauma Case Reports

journal homepage: [www.elsevier.com/locate/tcr](http://www.elsevier.com/locate/tcr)

## Case Report

# Case report: Forearm infected non-united fracture managed with the Masquelet technique in a 71-year-old female patient

Eleanor Goldstein<sup>a</sup>, George D. Chloros<sup>a</sup>, Peter V. Giannoudis<sup>a,b,\*</sup><sup>a</sup> Academic Department of Trauma and Orthopaedics, School of Medicine, University of Leeds, United Kingdom<sup>b</sup> NIHR Leeds Biomedical Research Center, Chapel Allerton Hospital, Leeds, United Kingdom

## ARTICLE INFO

### Keywords:

Forearm  
 Infected non-union  
 Masquelet  
 Cement spacer  
 RIA graft

## ABSTRACT

Infected non-union status post forearm fracture fixation is a challenge to treat and may be associated with unpredictable outcomes. The management of such a case involving a 71-year-old female suffering from Parkinson's disease is reported herein. The patient referred to our unit for a second opinion while she was under consideration for amputation at her local hospital. Utilising the two stage Masquelet technique successful limb salvage and excellent function were achieved.

## Introduction

Bone infections continue to be the most common post fracture fixation complication [1]. Their management involves bone and soft tissue debridement, soft tissue reconstruction, bone stabilisation and bone defect reconstruction when asepsis has been achieved using bone transport or other surgical techniques in association with regenerative based therapies.

The induced membrane/Masquelet technique was reported more than 20 years ago involving 2 stages for defect bone reconstruction [2]. During the first stage, adequate soft tissue and bone debridement is essential for controlling the infection, followed by the management of the dead space with a cement spacer and adequate bone stabilisation. The cement spacer induces a membrane (foreign body reaction) which contains abundant osteoprogenitor cells and has the capacity to secrete growth factors. Six to eight weeks later, the cement spacer is removed while the membrane is protected from damage and autologous grafting is implanted into the defect area for bone reconstruction. The membrane helps to contain the graft and to support its vascularization and mineralization eventually integrating and restoring the defect with normal bone.

The technique has been used successfully for bone defect treatment of both the upper and lower extremities. Herein, we report on the management of an infected forearm non-union in an elderly 71-year-old female patient.

## Case report

A 71-year-old female with a past medical history of Parkinson's disease presented to our department for a second opinion on the recommendation of an amputation below the elbow. The patient had previously sustained a closed, undisplaced midshaft ulna fracture associated with a displaced proximal radius fracture (Fig. 1). The patient requested non-operative treatment and she was treated in a plaster of Paris. Eight weeks later as she was experiencing a lot of pain, the forearm fractures were managed with Nancy nails (Fig. 2).

\* Corresponding author at: Academic Department of Trauma & Orthopaedic Surgery, School of Medicine, University of Leeds, Clarendon Wing, Floor D, Great George Street, Leeds General Infirmary, LS1 3EX Leeds, United Kingdom.

E-mail address: [pgiannoudi@aol.com](mailto:pgiannoudi@aol.com) (P.V. Giannoudis).

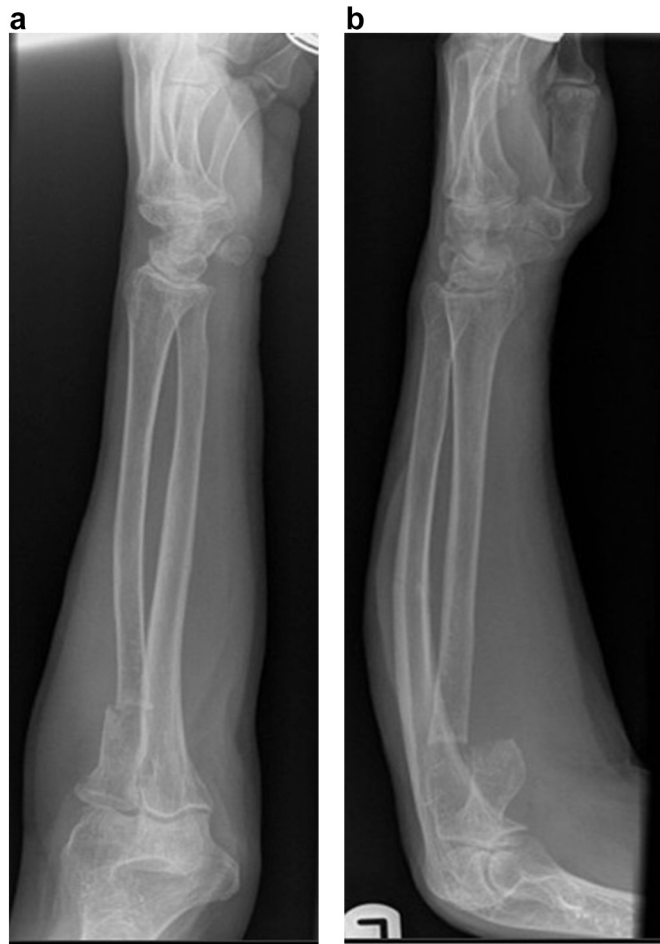<https://doi.org/10.1016/j.tcr.2021.100562>

Received 6 August 2021; Received in revised form 21 November 2021; Accepted 22 November 2021

Available online 27 November 2021

2352-6440/© 2021 The Authors. Published by Elsevier Ltd. This is an open access article under the CC BY-NC-ND license

(<http://creativecommons.org/licenses/by-nc-nd/4.0/>).



**Fig. 1.** A–B: AP and lateral radiographs showing the original proximal radius fracture associated with an undisplaced ulna fracture.

However, 12 weeks later as there was no progress of healing the Nancy nails were removed and a decision was taken to reconstruct only the ulna fracture with plating. Four months later, she was seen in the clinic at the local hospital with ongoing pain following a fall and she was diagnosed with a fracture at the most proximal screw of the plate (peri-implant) and a broken plate at the previous level of the ulna fracture (Fig. 3). She was taken back to theatre and underwent double plating of the ulna and plating of the radial non-union (Fig. 4). However, 3 months later the ulna wound broke down and started discharging pus. While a discussion took place for a possible forearm amputation at the local hospital, she was referred to the authors' institution for a second opinion. On examination there was pus discharging from the ulna wound but there was no neurovascular deficit present. Her CRP was 65 (normal range <10 pg/ml) and WCC 12,500 (normal range <10,500). After a lengthy discussion, it was the patient's choice to proceed with salvage instead of amputation. Therefore, she was taken to theatre and the ulna wound was debrided as well as the underlying bone generating a 4 cm bone defect. Using an anterior forearm incision, the radial plate was also removed, the bone debrided, leaving a 2 cm bone defect. Cement spacers loaded with vancomycin were inserted in both the ulna and radius and the forearm was stabilised with an external fixator (Fig. 5). Methicillin resistant staphylococcus (MRSA) was identified from the bone cultures taken during debridement. The patient was treated with iv vancomycin for a period of 3 weeks and then she was prescribed linezolid orally for another 3 weeks after which time her infection markers became normalised. Eight weeks after the first stage she was taken back to theatre and underwent removal of external fixator and cement spacers and plating of the both the ulna and radius. RIA graft was harvested from the left femur. The RIA graft was mixed with autologous bone marrow aspirate harvested from the left iliac crest and autologous platelet rich plasma (PRP). The composite bone graft was implanted at the areas of the bone defects (Fig. 6). The graft was contained with mobilisation and stitching of the Masquelet membrane. Bone tissues sent to microbiology during the second stage were negative for ongoing infection. Gentle rehabilitation of the left forearm and shoulder was encouraged. The patient had an uncomplicated post-operative course and was discharged home. Three months later clinical and radiological follow up examination at the clinic revealed clinical signs and radiological features of union (Fig. 7). The patient had a full and pain free range of motion.

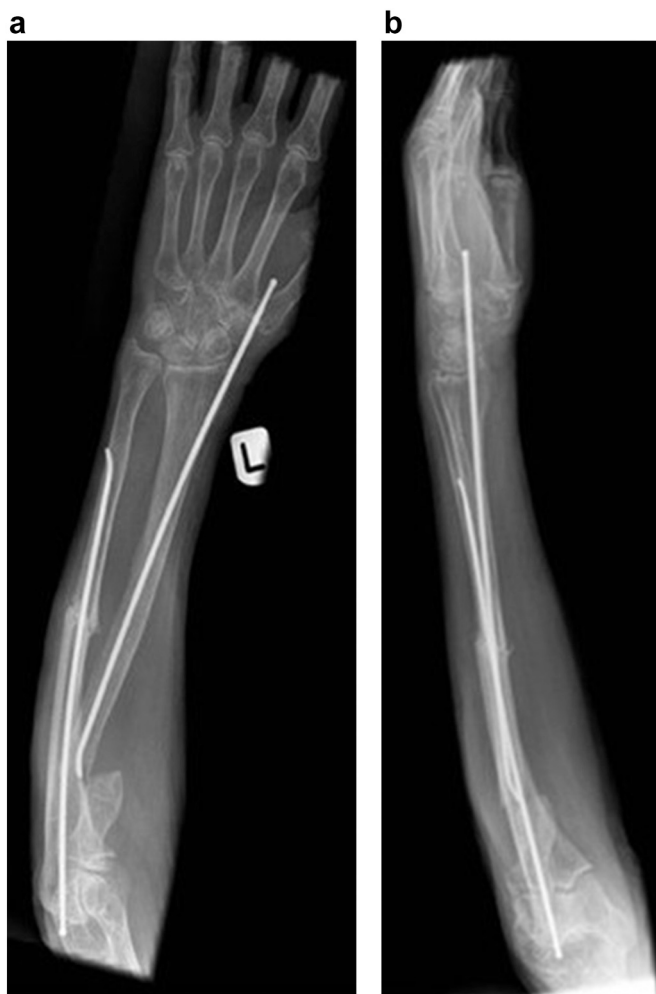

Fig. 2. A–B: AP and lateral radiographs showing failed treatment with Nancy nails.

## Discussion

Although the data is more scarce compared to periprosthetic joint infection, infection following fracture fixation has an estimated 1–2% incidence [1] and may be up to 30% for open fractures [1,3], and predisposes to nonunion [4]. The management of infected nonunions following fracture fixation can be typically long lasting and challenging for both patient and surgeon. In addition the impact to society is huge as many of those patients lose their ability to return to work, may have profound quality of life and psychological sequelae and considerable burden to the healthcare system [4,5].

Forearm infected nonunions are relatively rare, but particularly challenging to treat. The close relationship and smooth motion of the radius and ulna need to be restored by addressing the anatomy, including the shaft length [6]. In the setting of an infected nonunion, all of the hardware needs to be removed, and cultures should be sent for analysis, and temporary stabilisation of the fracture should be undertaken, most commonly in the form of the external fixation or splinting, to avoid further soft tissue damage, creation of dead space, and decreased vascularization. Usually, a two-stage approach is considered with the second stage being definitive fixation following appropriately indicated culture-based antibiotic treatment and normalization of the inflammatory markers. During the first stage, thorough irrigation and debridement at the infected nonunion site may create a bone defect. In such cases, the Masquelet technique may be useful in order to fill the gap and/or improve healing potential [2,7].

Successful use of the Masquelet technique has been reported in cases of infected forearm nonunions. Dhar et al., had excellent results in 12 forearm bones, with mean defect of 5 cm and reported a 100% union rate, with a mean 7.8 months union time, a near normal range of motion at 12 months minimum time followup [6]. Similarly, Walker et al., reported a 100% union rate in 9 patients who had segmental bone defects (mean 4.7 cm) including 5 with acute open fractures and 4 with nonunion (3 infected). Of those, only one patient underwent a revision for hardware failure that went on to union subsequently [8]. Luo et al., reported on 7 patients with mean defects of 5.8 cm and 5.5 cm for the radius and ulna respectively at a minimum followup of 41 months. Only 1 patient had to be regrafted (union rate 85%) for graft resorption and all patients were finally cleared with unrestricted activity [9].

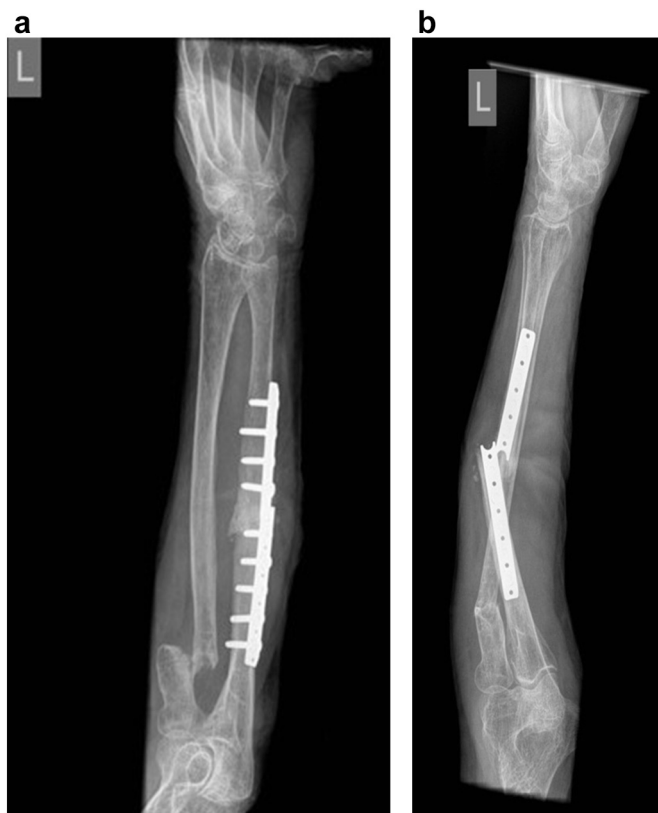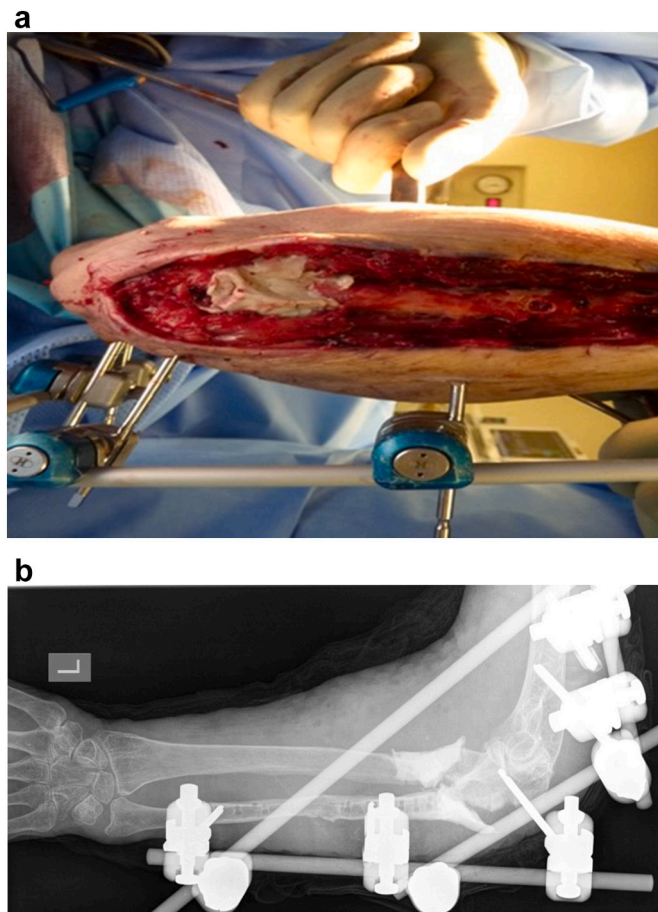


Fig. 3. A-B: Radiographs showing breakage of ulna plate.

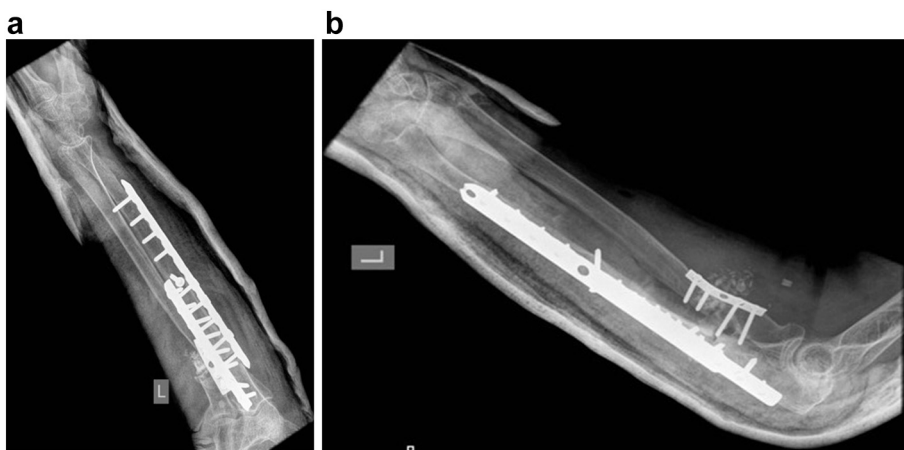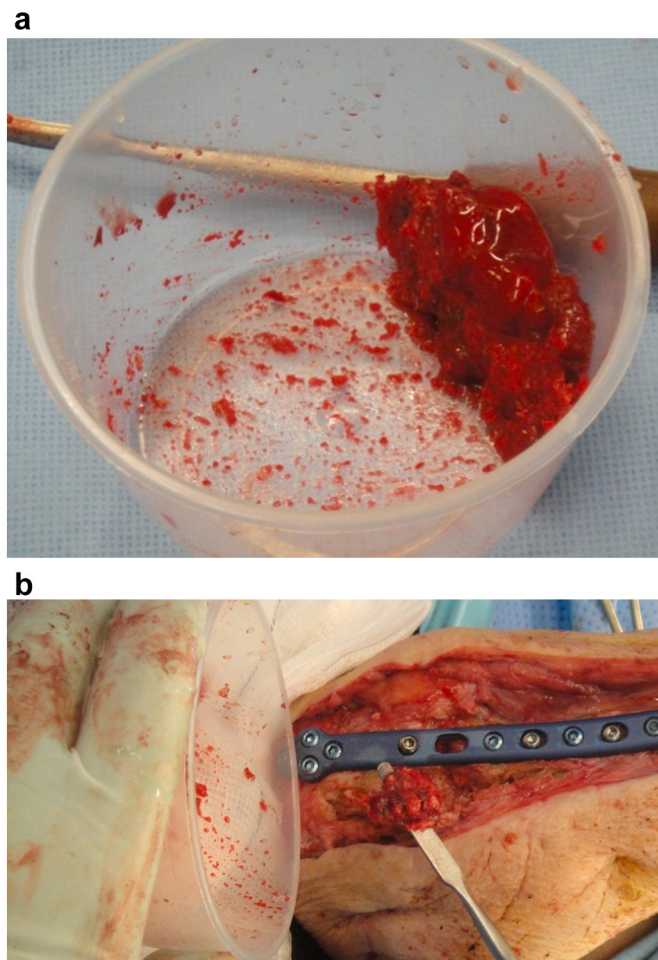


Fig. 4. A-B: Radiographs showing further revision surgery with double plating of the ulna and plating of the radial nonunion.

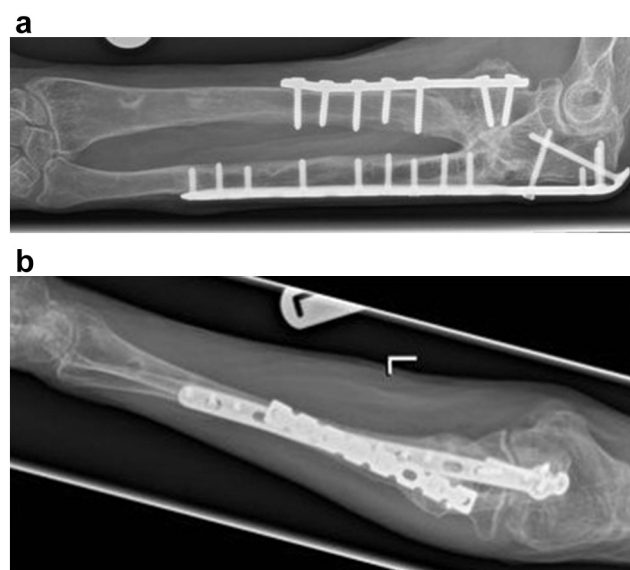
Other potential options for addressing bone defects in the forearm, may include primary cancellous autograft with plate fixation [10], non-vascularized fibular strut allograft with plate fixation [11], free fibular grafting [12], bone transport [13], and staged bulk allograft with intramedullary fixation [14]. All of the above options are potentially viable, with various results and complications/limitations reported in the literature; however, one advantage of the Masquelet technique is the local, continuous antibiotic release over a long period of time [15].



**Fig. 5.** A-B: A. Intraoperative image showing cement spacer placement (1<sup>st</sup> stage Masquelet technique) and B. Corresponding radiograph



**Fig. 6.** A-B: A. Intraoperative images showing the RIA bone graft mixed with bone marrow aspirate concentrate, and B. implantation in the areas of the bone defects (2nd stage Masquelet technique).



**Fig. 7.** A-B: AP and lateral radiographs demonstrating union at 3 years post initial injury.

In the patient presented, there were multiple operative attempts to achieve union that definitely predisposed to the infected nonunion. At this point, limb amputation was offered as a last resort from the treating surgeon from another institution. However, secondary to the Masquelet technique, it was feasible to not only salvage the limb but also provide the patient with her previous forearm function.

## Funding

No funding has been received.

## Declaration of competing interest

Authors declare no conflict of interest regarding the present manuscript.

## References

- [1] S. Steinmetz, D. Wernly, K. Moerenhout, A. Trampuz, O. Borens, Infection after fracture fixation, *EFORT Open Rev.* 4 (2019) 468–475.
- [2] A. Masquelet, F. Fitoussi, T. Begue, G. Muller, Reconstruction des os longs par membrane induite et autogreffe spongieuse, *Annales de chirurgie plastique et esthétique* (2000) 346–353.
- [3] A. Trampuz, W. Zimmerli, Diagnosis and treatment of infections associated with fracture-fixation devices, *Injury* 37 (Suppl 2) (2006) S59–S66.
- [4] G. Hoit, M. Bonyun, A. Nauth, Hardware considerations in infection and nonunion management: when and how to revise the fixation, *Ota International* (2020) 3.
- [5] G.D. Chloros, N.K. Kanakaris, J.S.H. Vun, A. Howard, P.V. Giannoudis, Scoring systems for early prediction of tibial fracture non-union: an update, *Int. Orthop.* 45 (2021) 2081–2091.
- [6] S.A. Dhar, T.A. Dar, N.A. Mir, Management of infected nonunion of the forearm by the masquelet technique, *Strateg. Trauma Limb Reconstr.* 14 (2019) 1.
- [7] I. Morelli, L. Drago, D.A. George, E. Gallazzi, S. Scarponi, C.L. Romanò, Masquelet technique: myth or reality? A systematic review and meta-analysis, *Injury* 47 (2016) S68–S76.
- [8] M. Walker, B. Sharareh, S.A. Mitchell, Masquelet reconstruction for posttraumatic segmental bone defects in the forearm, *J. Hand Surg. Am.* 44 (4) (2019) 342.e1–342.e8.
- [9] T. Luo, F. Nunez Jr., A. Lomer Jr., F. Nunez Sr., Management of recalcitrant osteomyelitis and segmental bone loss of the forearm with the Masquelet technique, *Journal of Hand Surgery (European Volume)* 42 (2017) 640–642.
- [10] D. Ring, C. Allende, K. Jafarima, B.T. Allende, J.B. Jupiter, Ununited diaphyseal forearm fractures with segmental defects: plate fixation and autogenous cancellous bone-grafting, *JBJS* 86 (2004) 2440–2445.
- [11] C. Faldini, S. Pagkrati, M. Nanni, S. Menachem, S. Giannini, Aseptic forearm nonunions treated by plate and opposite fibular autograft strut, *Clin. Orthop. Relat. Res.* 467 (2009) 2125–2134.
- [12] M.B. Wood, A.T. Bishop, Massive bone defects of the upper limb: reconstruction by vascularized bone transfer, *Hand Clin.* 23 (2007) 49–56.
- [13] Q. Zhang, P. Yin, M. Hao, J. Li, H. Lv, T. Li, et al., Bone transport for the treatment of infected forearm nonunion, *Injury* 45 (2014) 1880–1884.
- [14] J.A. Davis, A. Choo, D.P. O'Connor, M.R. Brinker, Treatment of infected forearm nonunions with large complete segmental defects using bulk allograft and intramedullary fixation, *J. Hand Surg.* 41 (2016) 881–887.
- [15] T. Raven, A. Moghaddam, C. Ermisch, F. Westhauser, R. Heller, T. Bruckner, et al., Use of masquelet technique in treatment of septic and atrophic fracture nonunion, *Injury* 50 (2019) 40–54.