

A Late Case of Ischemic Cerebral Event after Resection of a Left Atrial Myxoma

Reginald Lafleur^a Justyna Watkowska^{a, b} Guoping Zhou^a
Phenix Alcide^a Henock Saint-Jacques^{a, b}

^aHarlem Cardiology, and ^bNew York University, School of Medicine, New York, N.Y., USA

Key Words

Atrial myxoma · Cerebral ischemia · Primary tumor

Abstract

Atrial myxoma is one of the most common primary cardiac tumors reported in the literature. In very rare instances, stroke has been the sequelae after a myxomatous tumor resection. We report this unique case of late ischemic cerebral event in a 46-year-old female some days after resection of a left atrial myxoma.

© 2016 The Author(s)
Published by S. Karger AG, Basel

Introduction

Cardiac myxoma is reported in the literature as the most common primary cardiac tumor, and the left atrium (LA) is the most common tumor location [1, 2]. Clinical pathologic studies have identified two specific types of cardiac myxoma, type 1 and type 2. A soft and villous like outer surface characterizes type 1 and is most likely to give rise to embolization to various organs. Type 2 has a more compact consistency and even surface [3–5]. Long-term prognosis after total resection is usually exceptional with sporadic cases of tumor recurrence [6, 7]. This case report describes the late occurrence of a cerebral vascular ischemic event in a 46-year-old female after surgical resection of a left atrial myxoma.

Case Report

A 46-year-old female with a history of dyslipidemia and nephrolithiasis presented to a urology clinic with complaint of recurrent pelvic pain (preoperative day 7). The patient was evaluated and referred for an abdominal and pelvic computer tomography (CT) for further evaluation. CT showed a 3.49 × 2.74-cm mass in the region of the left adnexa, suggestive of an ovarian cyst (preoperative day 6). Abdominal and transvaginal ultrasounds were recommended. The CT of the urinary tract was normal with no evidence of calculi, masses, or obstructive uropathy. CT imaging at the level of the lower thorax incidentally showed a low-density mass in the LA, which measured 2.88 × 2.94 cm, suggestive of a possible myxoma, lymphoma, or thrombus. Transthoracic echocardiogram was done (preoperative day 5) and showed a large-sized (3.6 × 2.9 cm) mobile, heterogeneous mass in the LA attached at the level of the fossa ovalis in the atrial septal wall (fig. 1). LA was mildly dilated and other chambers were within normal size and function with a calculated left ventricular ejection fraction of 63%. Mild-to-moderate tricuspid regurgitation was also noted. Cardiothoracic surgery was consulted and the patient was subsequently scheduled for the atrial mass resection 5 days later (postoperative day 0). A minimally invasive removal of the left atrial mass through mini right thoracotomy at the fourth intercostal space was performed. The left atrial mass was removed by dissecting a stalk from the interatrial wall. Pathology reports confirmed the excised mass to be a myxomatous tumor. Three days after discharge (postoperative day 3), the patient developed progressive back pain and bilateral pleuritic chest pain and was admitted to another hospital. Her chest X-ray showed significant bilateral pleural effusions; costophrenic angles completely obscured, suggestive of pneumonia complicated with parapneumonic effusion (fig. 2). The patient underwent ultrasound-guided thoracocentesis. A total of 50 ml of serosanguinous fluid was removed and the initial pleural gram stain was continuously negative. Additional pleural fluid studies showed 2,300 WBC, 20,000 RBC, LDH 880, glucose 116 and a TP fluid/serum of 0.6, and the patient was treated with piperacillin/tazobactam, vancomycin, azithromycin and discharged on levofloxacin after 3 days (postoperative day 6) for completion of antibiotic therapy. Four days later (postoperative day 11), while at home the patient developed slurred speech and right-sided weakness. She was rushed by ambulance to a local hospital. A stroke team was activated. A CT of the head showed no acute hemorrhage. There was hyperdensity of the left middle cerebral artery (MCA) at the distal M1/proximal M2 level. A small area of faintly diminished attenuation involving the left lentiform nucleus that is compatible with evolving infarct was also observed. The patient was diagnosed with left-sided cerebral vascular accident. CT angiogram and CT perfusion imaging showed left MCA and M1 occlusion with hypoperfusion of the of the left MCA territory (fig. 3) with a National Institute of Health Stroke Scale (NIHSS) score of 11. Due to the recent surgery, the patient was judged not a candidate for thrombolysis. She underwent mechanical thrombectomy with a MERCI Retriever within 8 h from the time of initial presentation. On the next day following the thrombectomy (postoperative day 13), the patient's right-sided motor function was fully recovered. Total neurological recovery occurred several months after discharge from an acute rehabilitation center.

Discussion

The reported cases of cardiac emboli leading to cerebral ischemia have primarily occurred from atrial fibrillation, patent foramen ovale, followed by myxomas and lipomas [2, 8]. Cardiac myxomas are benign primary tumors of mesenchymal origin, with a 2:1 female-

to-male ratio and usually occur during the third to sixth decades of life [5, 9]. Signs and symptoms leading to cardiac myxomas include normal to abnormal auscultation findings on physical examination (tumor plops), unexplained syncopal episode and in most cases sudden cerebral ischemia. Two specific types of myxoma are known based on pathologic findings, type 1 and type 2. Type 1 is generally soft in consistency and has an irregular villous outer surface that makes it morphologically prone to embolization [5, 10]. The annual incidence of myxoma in the general population is less than 1 in 1 million. The LA is the most commonly reported location, and transthoracic echocardiogram is the most prevalent method of diagnosis [2, 6, 11, 12].

The uniqueness of this case is the occurrence of cerebral ischemia some days after surgical resection of myxoma. According to the literature, in very rare instances stroke has been the sequelae of surgical resection [8, 11, 13]. This 46-year-old female had no documented history of atrial fibrillation or prior history of cerebral vascular accident. In addition, the patient had neither evidence nor history of left ventricle mural thrombus resulting from previous myocardial infarction as those conditions can increase susceptibility for embolic stroke event. Calcified and infected valves disease are other culprits reported in the literature as possible causes of embolic neurovascular events which were not reported in this patient's medical history. The patient underwent mechanical embolectomy, an accepted alternative in patients with absolute thrombolytic contraindication. Prior to the procedure, a cerebral angiogram showed a complete occlusion of the left MCA, mid and distal M1 segment with a thrombolysis in cerebral infarction (TICI) score equal to 0. A postembolectomy angiogram performed through the left internal carotid artery demonstrated a cerebral flow improvement from a TICI score of 0 to a TICI score of 2a. A potential complication with the MERCI retriever procedure includes vessels perforation, intramural arterial dissection, or embolization of a previously uninvolved territory [12, 14].

Occurrence of stroke following surgical resection of myxoma is uncommon. Short- and long-term outcome of myxoma-related stroke, prior to surgical resection of the tumor is usually favorable. Most patients recover fully with minimal residual deficits [4, 5]. In our case, although rare in incidence, the stroke occurred late following the mechanical resection of the tumor and also resulted in a good outcome with no residual neurological sequelae. Within 3 months of rehabilitation therapy, the patient was back to her usual daily activities. The cause for this late cerebral vascular event is unclear. Possible etiology includes: residual cardiac tumor debris, circulating thrombotic fragments from tumor washed out during the cardiac procedure, thrombus formed during the surgical procedure or other combinations of thrombogenic risk factors. More data from observational or investigational studies are needed to establish etiology of a late ischemic cerebral event after surgical resection of myxomas that may provide better guidance on perioperative management of the disease.

Statement of Ethics

The authors have no ethical conflicts to disclose.

Disclosure Statement

The authors declare that they have no competitive interest.

References

- Burke AP, Tazelaar H, Gomez-Roman JJ, et al: Cardiac myxoma; in Travis WD, Brambilla E, Muller-Hermelink HK, Harris CC (eds): Pathology and Genetics of Tumours of the Lung, Pleura, Thymus and Heart. Lyon, IARC Press, 2004, pp 260–263.
- Reynen K: Cardiac myxomas. *N Engl J Med* 1995;333:1610–1617.
- Acebo E, Val-Bernal JF, Gomez-Roman JJ, Revuelta JM: Clinicopathologic study and DNA analysis of 37 cardiac myxomas: a 28-year experience. *Chest* 2003;123:1379–1385.
- Wang JG, Li YJ, Liu H, Li NN, Zhao J, Xing XM: Clinicopathologic analysis of cardiac myxomas: seven years' experience with 61 patients. *J Thorac Dis* 2012;4:272–283.
- Zheng Z, Guo G, Xu L, Lei L, Wei X, Pan Y: Left atrial myxoma with versus without cerebral embolism: length of symptoms, morphologic characteristics, and outcomes. *Tex Heart Inst J* 2014;41:592–595.
- Ravikumar E, Pawar N, Gnanamuthu R, Sundar P, Cherian M, Thomas S: Minimal access approach for surgical management of cardiac tumors. *Ann Thorac Surg* 2000;70:1077–1079.
- Vistarini N, Alloni A, Aiello M, Vigano M: Minimally invasive video-assisted approach for left atrial myxoma resection. *Interact Cardiovasc Thorac Surg* 2010;10:9–11.
- Yoo M, Graybeal DF: An echocardiographic-confirmed case of atrial myxoma causing cerebral embolic ischemic stroke: a case report. *Cases J* 2008;1:96
- Habbab L, Alfaraidi H, Lamy A: Surviving catastrophic disintegration of a large left atrial myxoma: the importance of multi-disciplinary team. *J Surg Case Rep* 2014;2014(9). pii: rju093.
- Abe M, Kohama A, Takeda T, Ishikawa A, Yamada Y, Kawase Y, Ishii Y, Bessho R, Oaki Y, Haruta S, Ohashi T: Effective intravenous thrombolytic therapy in a patient with cerebral infarction associated with left atrial myxoma. *Intern Med* 2011;50:2401–2405.
- O'Rourke F, Dean N, Mouradian MS, Akhtar N, Shuaib A: Atrial myxoma as a cause of stroke: case report and discussion. *CMAJ* 2003;169:1049–1051.
- Smith WS, Sung G, Starkman S, et al: Safety and efficacy of mechanical embolectomy in acute ischemic stroke: results of the MERCI trial. *Stroke* 2005;36:1432–1438.
- Roeltgen DP, Weimer GR, Patterson LF: Delayed neurologic complications of left atrial myxoma. *Neurology* 1981;31:8–13.
- Smith WS, Sung G, Saver J, et al: Mechanical thrombectomy for acute ischemic stroke: final results of the multi MERCI trial. *Stroke* 2008;39:1205–1212.

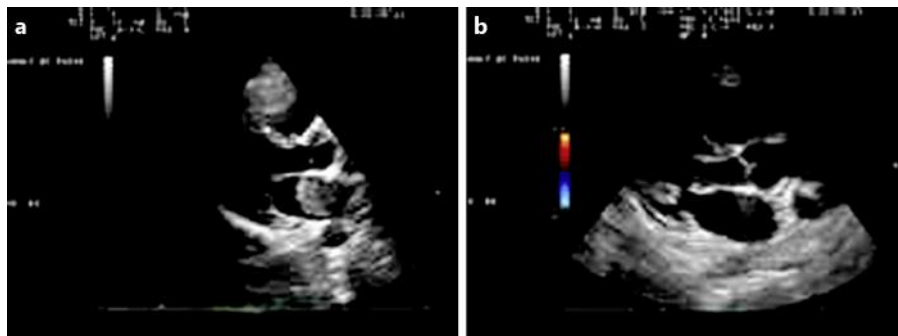


Fig. 1. **a** Echocardiography showing LA tumor. **b** Echocardiography showing tumor-free LA after tumor resection.

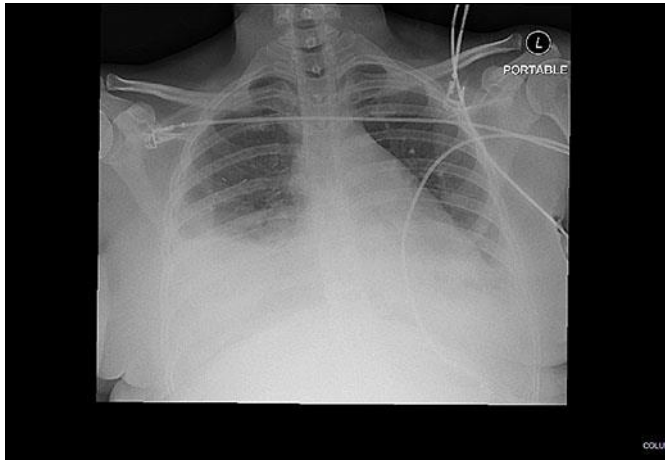


Fig. 2. Chest X-ray showing pleural effusion and an obscured costal phrenic angle.

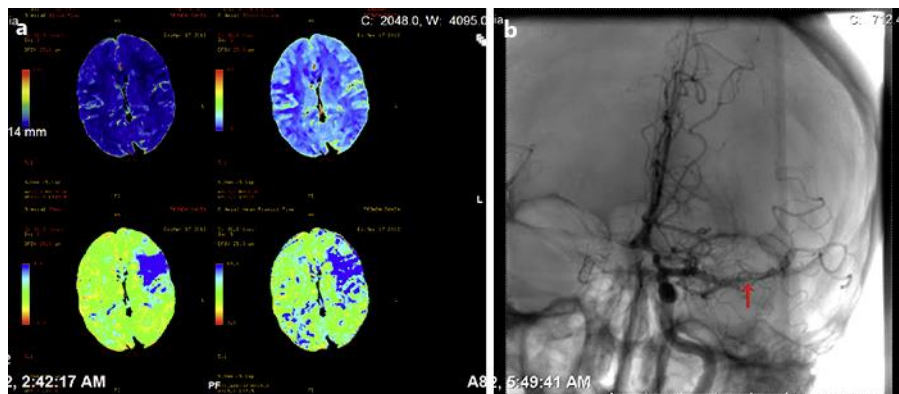


Fig. 3. **a** Hypoperfusion of the left MCA territory. **b** Perfusion CT imaging showing a decreased perfusion in M1 segment of MCA areas (arrow).