




## ORIGINAL RESEARCH

# The clinical consequences of the COVID-19 lockdown: A report from an Italian referral ENT department

Oreste Gallo MD<sup>1</sup>  | Luca Giovanni Locatello MD<sup>1</sup>  | Pietro Orlando MD<sup>1</sup> |  
Federica Martelli MD<sup>1</sup> | Chiara Bruno MD<sup>1</sup> | Maria Cilona MD<sup>1</sup> |  
Giuseppe Fancello MD<sup>1</sup> | Riccardo Mani MD<sup>1</sup> | Daniele Vitali MD<sup>1</sup> |  
Giacomo Bianco MD<sup>1</sup> | Massimo Trovati MD<sup>1</sup> | Matteo Tomaiuolo MD<sup>2</sup> |  
Giandomenico Maggiore MD<sup>1</sup> 

<sup>1</sup>Department of Otorhinolaryngology, Careggi University Hospital, Florence, Italy

<sup>2</sup>Medical Management of Emergency Department, Careggi University Hospital, Florence, Italy

**Correspondence**

Giandomenico Maggiore, Department of Otorhinolaryngology, Careggi University Hospital - Largo Brambilla, 3 - 50134 Florence, Italy.  
Email: maggiore2@virgilio.it

**Abstract**

**Objectives:** To evaluate the clinical effects of health care reorganization because of COVID-19, in a non-red zone Italian referral department of Otorhinolaryngology.

**Materials and Methods:** We retrospectively reviewed the statistics of admissions to the Emergency Department (ED) of the Careggi University Hospital, Florence, from January 1, 2020, to May 17, 2020. Data regarding elective and urgent head and neck disorders were reviewed and the most challenging cases were discussed.

**Results:** During the lockdown period, outpatient otolaryngological consultations and elective procedures decreased by 78% and 75% respectively, while emergency/urgency surgery increased by 128%. The five most emblematic clinical cases were thoroughly analyzed.

**Conclusion:** Our analysis shows how the profound rearrangement of clinical and surgical activities, along with the citizens' fear to seek medical care has probably exacerbated the management of many routine head and neck conditions.

**Level of Evidence:** 4.

**KEYWORDS**

COVID-19, emergency medicine, head and neck surgery, otorhinolaryngology, SARS-CoV-2

## 1 | INTRODUCTION

In January 2020, the novel Severe Acute Respiratory Syndrome Coronavirus-2 (SARS-CoV-2) was identified as the causative agent of the CoronaVirus Disease 2019 (COVID-19).<sup>1,2</sup> On March 11, 2020, 72 days after the first reported case, COVID-19 was declared to be a

pandemic by the World Health Organization.<sup>3</sup> As of May 27, 2020, COVID-19 confirmed cases amount to more than 5 400 000 worldwide and related deaths exceed 350 000.<sup>3</sup> SARS-CoV-2 person-to-person transmission through respiratory droplets or direct contact with infected mucosa was demonstrated and viral particles may persist viable and infectious in the air for hours and, upon certain materials, up to days.<sup>4,5</sup> In addition, the high percentage of infectious asymptomatic carriers along with the progressive scarcity of personal

Oreste Gallo and Luca Giovanni Locatello have equally contributed to the work.

This is an open access article under the terms of the Creative Commons Attribution-NonCommercial-NoDerivs License, which permits use and distribution in any medium, provided the original work is properly cited, the use is non-commercial and no modifications or adaptations are made.

© 2020 The Authors. *Laryngoscope Investigative Otolaryngology* published by Wiley Periodicals LLC on behalf of The Triological Society.

protective equipment (PPE) are contributing to its rapid diffusion across the world.<sup>6,7</sup>

Nosocomial setting certainly played an important role in SARS-CoV-2 spreading: in the period coming from 1 to 20 May, 56.7% of the new Italian COVID-19 confirmed cases were attributable to in-hospital/health care facilities transmission.<sup>8</sup> As of May 20, 2020, 11.7% of all Italian cases are constituted by health care workers (HCW) themselves, a percentage that is growing week by week.<sup>8</sup> In addition, due to this incredibly rapid contagiousness, many national health care systems have been literally overwhelmed, with the dreadful risk of disregarding many “non-COVID-19” disorders.<sup>9</sup> In this scenario and under the principles of “social distancing” and of “self-isolation,” the clinical activities of many departments were drastically reduced, elective surgical procedures were postponed and a large proportion of outpatient consultations were canceled or are being moved to telemedicine.<sup>10</sup> The fear of contracting the virus and/or of not receiving proper hospital care was associated with many deleterious medical and social consequences and some authors have wittily spoken of “covidlateral” damages of the pandemic.<sup>11</sup> As an example, it was recently estimated that even modest delays in oncological surgery can negatively affect survival.<sup>12,13</sup>

Many excellent guidelines and frameworks have been recently published as a reference guide to reorganize the practice of Otolaryngology-Head and Neck Surgery but, as we are coming out of the acute phase of the pandemic, it is now time to take stock of its clinical consequences.<sup>14,15</sup> The aim of the present article is to analyze the direct and indirect effects of COVID-19 on the clinical activity of our Department in a third referral Italian hospital. Lastly, we describe some emblematic cases of patients who had a delay in accessing the Emergency Department (ED) or even denied to undergo surgery because of fear of infection with unfavorable yet preventable outcomes.

## 2 | MATERIALS AND METHODS

We retrospectively reviewed the official statistical data of all patients admitted to the ED of Careggi University Hospital, Florence, Italy from January 1, 2020, to May 17, 2020. It is a third-level referral hospital and hub trauma center for the central Italy where logistics, clinical, and surgical activity were profoundly reorganized and a distinct pathway of care for COVID-19 confirmed cases was established since the beginning of the pandemic: the interested reader is referred to another publication for a detailed description of these changes.<sup>16</sup> We separately retrieved and analyzed COVID-19-related accesses (defined as any patient presenting with fever, cough, sore throat, respiratory failure, or new-onset smell/taste disorder) from non-COVID-19 accesses. Secondly, we extracted prelockdown accesses (January 1, 2020–March 8, 2020, weeks 1-10) from those since the introduction of nationwide distancing measures by our Government to present (March 9, 2020–May 17, 2020, weeks 11-20).<sup>17</sup> Then, we retrospectively reviewed all the outpatient and inpatient activity of the Department of Otorhinolaryngology during the same periods and

performed the same comparisons. In detail, as per the directives of the Italian Ministry of Health and the institutional guidelines, the following modifications have been implemented since the beginning of the lockdown period:

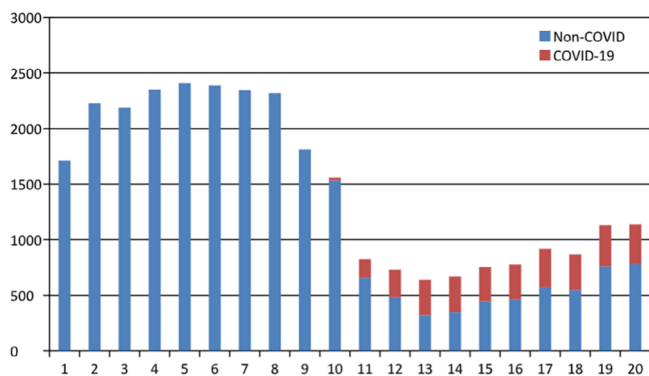
- Every patient is obliged to obtain a SARS-CoV-2 nasopharyngeal swab about 24 hours before being hospitalized (note that the kit used in our hospital for a SARS-CoV-2 RT-PCR has a turnaround time of approximately 6 hours);
- Operating rooms are reserved only for nondeferable surgery (see below);
- Multidisciplinary cancer team consultations are conducted by teleconference meetings;
- Routine in-office consultations are maintained or postponed on the basis of a telephone triage: all consultations for non-acute and non-complicated benign/functional disorders and for neoplastic disorders with a negative follow-up >5 years, and without new/worsening symptoms or suspicious findings reported on the most recent imaging examination are postponed;
- HCW are requested to constantly wear PPE (gloves, mask, face shield, and gown) while at work, and regardless of the virological status of the patient;
- All waiting rooms have been provided with an alcohol-based sanitizer dispenser, and available seats are kept two meters away from one another;
- On arrival, body temperature is checked, a surgical face mask must be worn at all times, and any unnecessary (i.e., except for minor patients and people with disabilities) accompanying person is not allowed into the pavilion;
- Relatives are kept informed every day about the patient's clinical conditions by telephone calls.

All surgical procedures were reclassified according to the possibility of delaying them without provoking harm to the patient: for less than 24 hours (emergency, for example, severe bleeding), for less than 48 hours (urgency, e.g., orbital complications from sinusitis with no improvement after medical management), for less than 7 days (semi-urgency, e.g., histology-proven malignancy deemed to be suitable for a primary surgical treatment by our multidisciplinary cancer team, laryngeal lesions suspected to be malignant, pituitary tumors with initial visual impairment, etc.).<sup>18</sup>

For the case series, the following selection criteria were applied to extract the patients:

- Semi-urgency or emergency/urgency surgical procedures only;
- Patients who reported to have avoided seeking timely medical care because of fear for being infected by SARS-CoV-2 in hospital;
- Patients who did not receive surgery because of the COVID-19 associated lockdown measures.

Institutional Review Board was obtained (17104/OSS) and written informed consent was always requested before every procedure and images were adequately modified in order not to allow the patient's



**FIGURE 1** Bar chart: On the x axis, week number from the beginning of 2020; on the y axis, overall number of admissions to our ED. Starting from the tenth week, a stratification between patients coming to the ED for COVID-19-associated symptoms and for other symptoms is given

identification. Given the eminently illustrative aim of the present work, only standard descriptive statistical analysis was performed.

### 3 | RESULTS

From January 1, 2020, to May 17, 2020, the total number of accesses to the ED amounted to 29 806 patients. Remarkably, in the pre-lockdown period (January 1, 2020–March 8, 2020, weeks 1-10) accesses were 21 317 while, during the lockdown phase (March 9, 2020–May 3, 2020, weeks 11-18) and the first two post-lockdown weeks (May 4, 2020–May 17, 2020, weeks 19-20), the total number of accesses dropped down to 8489 (2.51 times less). 3067 out of 8489 patients came to ED complaining of COVID-19-associated symptoms and obtained a pharyngeal swab. 379 (12.2%) tested positive at RT-PCR for SARS-CoV-2 viral detection. On the other hand, patients referred to the ED for “non-COVID-19” symptoms were only 5422, 75% less than those registered in the pre-lockdown period (Figure 1).

As regards the otorhinolaryngological activity during lockdown period (March 9, 2020–May 3, 2020, weeks 11-18) and during the first two post-lockdown weeks (May 4, 2020–May 17, 2020, weeks 19-20) 295 in-office consultations were postponed (64%) while 164 were regularly performed (36%, all for neoplastic or acute/complicated inflammatory disorders). Concerning surgical activity, 98 elective and 9 emergency procedures were performed from January 1, 2020, to March 8, 2020. During the lockdown period and during the first two post-lockdown weeks, 22 patients underwent elective semi-urgency surgery (Table 1) while 9 patients were treated as emergency or urgency (Table 2). The volume of elective procedures decreased by 78% while, the number of emergency/urgency procedures increased by 128% in the weeks 11 to 18 compared to the pre-lockdown period. All elective patients obtained a pharyngeal swab 24 hours before hospitalization and they were all negative for SARS-CoV-2. Even in the group of emergency/urgency, it was always possible to obtain a negative swab: 4/9 (44.4%) were already hospitalized

and with a negative swab, 5/9 (55.6%) obtained a pharyngeal swab before to underwent surgery.

It must be noticed that, unfortunately, on March 8, 2020, a head and neck surgeon from our team tested positive for SARS-CoV-2 and he was subsequently hospitalized to the intensive care unit (ICU) for a severe pneumonia; most of the staff was put in quarantine by the authorities and the ward was temporarily closed. Three otolaryngologists were not directly exposed and, thus, they managed to guarantee the essential levels of care while remaining on-call for the following 14 days. At the end of the quarantine period, all the members of the staff obtained pharyngeal swabs and RT-PCR for viral RNA detection: we all tested negative while the infected surgeon finally recovered and he was discharged home after 32 days.

By reviewing clinical records of the nine patients in Table 2, who referred to our service for conditions requiring emergency/urgency surgery, three (33.3%) had a delayed access to ED (mean delay = 8.3 days). As a comparison, if we look at our surgical series in the last 5 years from our digital records, we treated only two cases of severe necrotizing fasciitis and one Pott's puffy tumor (i.e., less than 1 a year). Two patients reported fear for contracting SARS-CoV-2 (cases 1 and 4), while one added he was also worried not to receive sufficient care because of the “overwhelmed hospital” (case 2). Taking into account only the patients who were requested to undergo non-deferrable procedures, 2/24 (8.3%) patients who were already scheduled for surgery refused hospitalization and they were postponed. One of them refused surgery because of fear for COVID-19 (case 3), whereas the other one because of forbidden interregional movements (case 5).

Five cases fulfilled the aforementioned selection criteria and they are briefly presented in the following paragraphs.

#### 3.1 | Case 1 (\*)

A 77-year old male, with type II diabetes mellitus and receiving tocilizumab because of giant cell arteritis, came to our ED complaining of fever and a neck swelling. In the previous 8 days because of acute left submandibular infection, he was empirically treated at home with amoxicillin/clavulanic acid. On admission, body temperature was 38.6°C, BP was 90/50 mmHg and HR was 150 bpm, his neck was swollen with ecchymotic areas. A CT scan of the head and neck region and of the chest confirmed acute submandibular sialadenitis complicated by neck and mediastinal necrotizing fasciitis (Figure 2A,B). IV meropenem and linezolid were started and we urgently performed a bilateral neck incision with extensive debridement and drainage of purulent material while concurrent thoracotomy was performed to drain mediastinal fluid. After a 5-hour procedure, the patient was moved to the ICU where he, unfortunately, died 3 hours later.

#### 3.2 | Case 2 (\*\*)

A 67-year old male retired physician came to ED for altered mental status. In the past 7 days, he complained of nasal congestion and

**TABLE 1** Patients who underwent elective surgery from March 23, 2020 to May 17, 2020 (weeks 12-20)

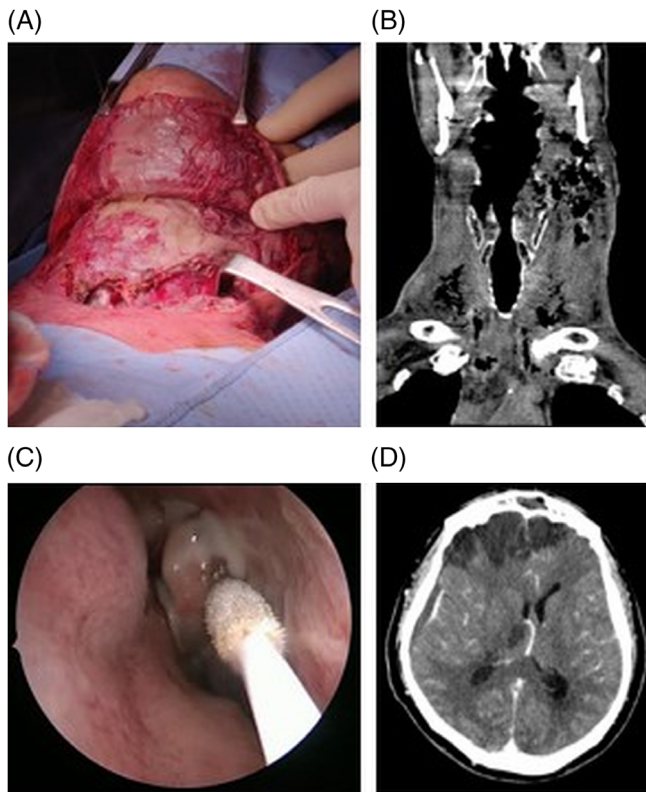
Sex	Age	Primary disease	Procedure(s)
M	85	cT4aN0 laryngeal cancer	Total laryngectomy, SND
M	68	cT3N0 laryngeal cancer	Open partial supracricoid laryngectomy + SND
M	76	cT1aN0 glottic cancer	Laser-CO <sub>2</sub> cordectomy type III
F	58	Submandibular mass with nondiagnostic FNAC	Surgical excision
M	46	Pituitary adenoma with optic nerve compression	Endoscopic tumor excision
M	78	rcT1aN0 glottic carcinoma	Laser-CO <sub>2</sub> cordectomy type III
M	75	cT4aN0 ethmoidal intestinal-type adenocarcinoma	Endoscopic tumor excision
F	48	Pituitary adenoma compressing optic nerve	Endoscopic tumor excision
M	71	Glottic leukoplakia	Laser-CO <sub>2</sub> cordectomy type I
F	65	Papilloma of the uvula	Simple transoral excision
F	53	cT1N0 squamous cell carcinoma of the tongue	Partial glossectomy + SND
F	74	cT2N0 squamous cell carcinoma of the labial commissure	Excision, SND, and reconstruction with antibrachial flap
F	68	Unilateral nasal mass suspicious for hemangioma	Endoscopic excision
M	86	Laryngeal leukoplakia	Laser-CO <sub>2</sub> cordectomy type I
M	62	T3 N0 submandibular gland tumor with suspicious FNAC	Tumor excision
F	75	Laryngeal leukoplakia	Laser-CO <sub>2</sub> cordectomy type I
M	78	Mandibular fracture related to osteoradionecrosis	Curettage, fracture reduction and fixation, sliding graft
M	71	Pituitary adenoma with worsening vision	Endoscopic tumor excision
M	54	Nasal meningoencephalocele	Transnasal endoscopic repair by gasket seal technique
M	80	Trigeminal schwannoma invading ethmoid and middle cranial fossa	Endoscopic tumor excision
M	67	rcT2N0 squamous cell carcinoma of the tongue	Transoral hemiglossectomy
M	79	cT3N0 ethmoidal intestinal-type adenocarcinoma	Transnasal endoscopic tumor excision

**TABLE 2** List of patients who underwent emergency surgery from March 8, 2020 to May 17, 2020 (weeks 10-20). For patients with (\*) further details are given in the text

Sex	Age	Primary disease	Complication	Procedure(s)
M	66	Chronic rhinosinusitis with nasal polyps (grade III)	Brain abscess (**)	Endoscopic Sinus Surgery (Draf III + sphenoid sinusotomy + ethmoidectomy + maxillary antrostomy)
M	78	Nasopharyngeal non-Hodgkin lymphoma	Acute airway obstruction	Surgical Tracheostomy
F	75	Chronic rhinosinusitis without nasal polyps	Fronto-orbital mucocele (***)	Endoscopic Sinus Surgery (Draf IIb + sphenoid sinusotomy + ethmoidectomy + maxillary antrostomy)
F	62	CSF leak	Acute Bacterial Meningitis	Endoscopic repair with fascia lata graft
M	59	rT4N0 tongue cancer undergoing palliative care	Massive oral bleeding	External carotid artery ligation, tracheostomy
M	41	Pharyngeal Leishmaniasis	Massive pharynx hemorrhage and necrosis	Pharyngeal cauterization
M	55	Facial trauma	Acute dyspnea	Tracheostomy
M	72	Odontogenic abscess	Trismus	Surgical drainage
M	77	Acute sialadenitis of the submandibular gland	Necrotizing fasciitis (*)	Debridement, drainage

purulent discharge that were self-treated at home with empiric antibiotic therapy. Even when fever (up to 40°C) developed, the patient refused to go immediately to the hospital because of fear of contagion. An urgent CT scan of the paranasal sinuses and the brain

revealed acute frontal rhinosinusitis complicated by a cerebral abscess in the right hemisphere (Figure 2C,D). A broad-spectrum antibiotic therapy with piperacillin/tazobactam and vancomycin was administered, and he underwent urgent endoscopic surgical drainage of

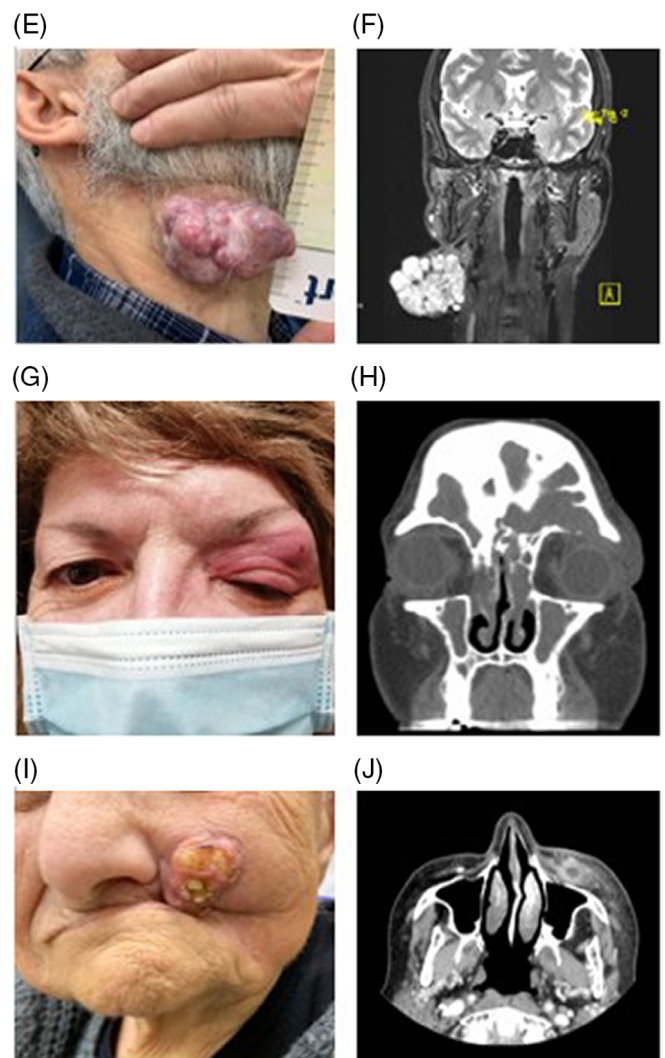


**FIGURE 2** Case 1: A, an intraoperative view of the transcervical drainage of the purulent fluids extensively involving all the fascial planes of the neck; B, coronal view of the CT scan shows an impressive involvement of both the neck and upper thorax. Case 2: C, an endoscopic view of the left nasal fossa with purulent material coming from the frontal infundibulum; D, axial CT scan shows the extensive involvement of the cerebral frontal lobes

purulent material. Then, bilateral temporal decompressive craniotomy was performed with the evacuation of a right subdural empyema extending to the contralateral hemisphere. The culture of nasal samples did not detect any microbial pathogen, while neurosurgical samples were positive for *Streptococcus intermedius*. On day 59, the patient was finally discharged although focal neurological deficits and a generalized personality change still persist.

### 3.3 | Case 3

A 60-year old male was scheduled for the excision of a right paramandibular painless, stony-hard, irregular-shaped, 8 × 6 cm sized mass that had been kept growing in the last 20 years (Figure 3E,F). Notably, he had already received surgery twice for a right parotid pleomorphic adenoma in 1979 and, because of a recurrence, in 1997. Despite repeated explanations concerning the increased risk of a malignant transformation in case of a recurrent pleomorphic adenoma, he refused to undergo surgery as he was literally “terrified” by an eventual SARS-CoV-2 contagion.



**FIGURE 3** Case 3: E, right paramandibular, stony-hard, irregular-shaped, 8 × 6 cm mass; F, coronal CT scan shows a heterogeneous, polylobed mass. Case 4: G, swelling, erythema, and ptosis of left superior eyelid with a Pott's puffy tumor; H, coronal CT scan reveals an acute frontal rhinosinusitis complicated by orbital involvement. Case 5: I, squamous cell carcinoma of the skin of the cheek; L, axial CT scan shows the cutaneous mass involving deep tissues

### 3.4 | Case 4 (\*\*\*)

A 76-year old female came to ED complaining of swelling, erythema, and ptosis of her left superior eyelid; despite proper counseling, she refused hospitalization and was discharged at home with oral antibiotic therapy. Three weeks later, she came back to ED with diplopia, periorbital pain, and a Pott's puffy tumor that started to appear 10 days before. Strikingly, she admitted she did not seek medical advice because of in-hospital contagion fear. CT scan of the paranasal sinuses and orbits revealed acute frontal rhinosinusitis complicated by orbital involvement (Figure 3G,H). IV piperacillin/tazobactam and vancomycin was administered, a Draf IIB procedure with a medial orbital decompression was performed and a drainage was placed for 3 weeks

in her left frontal sinus. After surgery, her clinical condition progressively improved and she was discharged 4 days later.

### 3.5 | Case 5

A 79-year old female was scheduled for the excision of an rT4N0 squamous cell carcinoma of the skin (Figure 3I,L). This was the fourth recurrence and as she lived in another region (Italian government forbade transfers among different regions), she went to another hospital where it was decided to deliver external radiation therapy. While waiting for the beginning of the treatment, she, unfortunately, died because of a tumor-related complications.

## 4 | DISCUSSION

The rapidly increasing demand for hospitalization overstretched many health care systems: with over 4 million positive cases and more than 400 000 deaths, COVID-19 is one of the greatest pandemics in recent history.<sup>19</sup> COVID-19 pandemic has inevitably put a hard strain on many departments of head and neck surgery with unprecedented challenges.<sup>20</sup> While in the past weeks, many high-quality guidelines on how to reorganize head and neck services have been published, the present work is one of the first appraisal of the actual indirect clinical consequences of COVID-19 on our specialty.<sup>21-23</sup> Between the end of March and the middle of April, in the red zones of Northern Italy, thousands of new COVID-19 cases were diagnosed every day, overloading EDs and ICUs and, as a consequence, the whole regional health care system.<sup>24</sup> Fortunately, in the rest of the peninsula, the impact was much less dramatic. This has allowed the other non-red zones to do a substantial reorganization of hospitals' activity and better control many COVID-19 indirect side effects. These structural changes have been fundamental in order to cope with the increasing number of severely ill patients due to COVID-19 and to reduce at minimum the risk of in-hospital transmission both to patients and to HCW.<sup>16</sup>

In view of the reduction of elective surgery, the increase of head and neck emergency/urgency procedures that we registered can simply reflect the conversion into "COVID-19 centers" of many non-referral hospitals in Tuscany and the centralization of emergencies to our ED, as it happened in other centers.<sup>25</sup> As a matter of fact, other authors have reported a reduction in (general) surgical emergencies during the lockdown period but this probably depends on the logistical aspects of health care reorganization during the pandemic and on many other preexisting factors (number of patients yearly served, etc.).<sup>26</sup> In addition, our experience suggests how the fear of infringing social distancing rules or of being infected may even convert common disorders into challenging surgical emergencies.

In such dramatic context, otolaryngologists-head and neck surgeons are known to be particularly at risk for SARS-CoV-2 infection,

as several aerosol-generating procedures are daily performed.<sup>14</sup> To reduce HCWs' exposure to aerosolized particles, some authors have proposed alternative approaches to surgery when feasible, such as radiotherapy for many head and neck cancers.<sup>15</sup> The consequences of this treatment shift are yet unknown but, in this perspective, an interesting model has estimated a catastrophic impact that a 3-month or a 6-month delay to surgery may have on survival rates of several cancers (–17% and –30%, respectively).<sup>27</sup> More specifically, for a stage III laryngeal cancer diagnosed in the population aged 50-59, a six-month delay would yield a net reduction of 35.4% in terms of survival.<sup>27</sup>

Apart from cancer patients, another "covidlateral" effect derived from those surgical procedures that cannot just be postponed. By surfing on the internet and/or watching the terrific news, many citizens have probably thought that hospitals were an important source of contagion and that they were so overwhelmed that there was no chance to be treated. Accordingly, they often chose to stay at home with inappropriate, if any, treatments. Our experience parallels the one depicted by our Italian colleagues in several departments of Pediatrics: because the usual health care provider was unavailable and/or hospital access was even discouraged, many young patients did not receive timely care with a dramatic rise in morbidity and mortality.<sup>28</sup>

As with any preliminary report on a novel subject, our work is not without limitations. As already stated, we have never experienced the tragic case burden of our colleagues in Northern Italy where, reasonably, more severe disruption of the health care system was registered.<sup>29</sup> Secondly, while we strove to give a preliminary full picture of the effects of COVID-19 on a head and neck surgery service, we admit that otologic and lateral skull base procedures were essentially excluded given they represent only a very small fraction of our Institutional activities. Because mastoidectomy is a high-risk aerosol-generating procedure that can become non-deferrable in some cases of complicated acute otitis media or cholesteatoma, future reports are needed.<sup>30,31</sup>

## 5 | CONCLUSIONS

COVID-19 pandemic has profoundly affected both urgent and elective activity of a head and neck surgery service in an Italian non-red zone. The obligation to stay home, the fear of being infected, and of not receiving adequate care may have all concurred to the deleterious clinical consequences that we experienced in the past months. Our paradigmatic cases show some of the indirect side-effects of the pandemic and, despite a great deal of efforts against SARS-CoV-2, the citizens' fear of coming to the hospital may represent a second enemy we must fight, in the light of the timeless motto "faster treatment, better outcomes."

### ACKNOWLEDGMENT

To all the staff at our Department which has brilliantly faced this unprecedented situation.

**CONFLICT OF INTEREST**

All authors declare they have nothing to disclose.

**ETHICAL APPROVAL**

All procedures performed in studies involving human participants were in accordance with the ethical standards of the institutional and/or national research committee and with the 1964 Helsinki declaration and its later amendments or comparable ethical standards.

**INFORMED CONSENT**

Informed consent was obtained from all individual participants included in the study. This research did not receive any specific grant from funding agencies in the public, commercial, or not-for-profit sectors.

**ORCID**

Oreste Gallo  <https://orcid.org/0000-0003-3426-7179>

Luca Giovanni Locatello  <https://orcid.org/0000-0002-1879-5580>

Giandomenico Maggiore  <https://orcid.org/0000-0002-2741-4460>

**BIBLIOGRAPHY**

- Wu F, Zhao S, Yu B, et al. A new coronavirus associated with human respiratory disease in China. *Nature*. 2020;579:265-269. <https://doi.org/10.1038/s41586-020-2008-3>.
- Lango MN. How did we get here? Short history of COVID-19 and other coronavirus-related epidemics. *Head & Neck*. 2020;42(7):1535-1538. <http://dx.doi.org/10.1002/hed.26275>.
- World Health Organization. *Coronavirus disease (COVID-19) Dashboard*. <https://www.who.int/emergencies/diseases/novel-coronavirus-2019> (accessed May 27, 2020).
- Chan JFW, Yuan S, Kok KH, et al. A familial cluster of pneumonia associated with the 2019 novel coronavirus indicating person-to-person transmission: a study of a family cluster. *The Lancet*. 2020;395(10223):514-523. [http://dx.doi.org/10.1016/S0140-6736\(20\)30154-9](http://dx.doi.org/10.1016/S0140-6736(20)30154-9).
- van Doremalen N, Bushmaker T, Morris DH, et al. Aerosol and surface stability of SARS-CoV-2 as compared with SARS-CoV-2. *N Engl J Med*. 2020;382:1564-1567. <https://doi.org/10.1056/NEJMc2004973>.
- Li R, Pei S, Chen B, et al. Substantial undocumented infection facilitates the rapid dissemination of novel coronavirus (SARS-CoV-2). *Science*. 2020;368(6490):489-493. <https://doi.org/10.1126/science.abb3221>.
- Artenstein AW. In pursuit of PPE. *N Engl J Med*. 2020;382:e46. <https://doi.org/10.1056/NEJMc2010025>.
- Infectious disease department and informatic service COVID-19 Task Force, Superior Institute of Health. COVID epidemic. National update: May 14, 2020. [https://www.epicentro.iss.it/coronavirus/bollettino/Bollettino-sorveglianza-integrata-COVID-19\\_20-maggio-2020.pdf](https://www.epicentro.iss.it/coronavirus/bollettino/Bollettino-sorveglianza-integrata-COVID-19_20-maggio-2020.pdf) (accessed May 28, 2020).
- Kansagra AP, Goyal MS, Hamilton S, Albers GW. Collateral effect of Covid-19 on stroke evaluation in the United States. *N Engl J Med*. 2020;383:400-401. <https://doi.org/10.1056/NEJMc2014816>.
- Remuzzi A, Remuzzi G. COVID-19 and Italy: what next? *Lancet*. 2020;395(10231):1225-1228. [https://doi.org/10.1016/S0140-6736\(20\)30627-9](https://doi.org/10.1016/S0140-6736(20)30627-9).
- Hawkins SC, McClure SF, Jones W. Special COVID-19 coverage: death is an expected COVID-19 effect; Covidlateral damage is not. *Emerg Med News*. 2020;42(5A). <https://doi.org/10.1097/01.EEM.000066844.38435.9b>.
- Kutikov A, Weinberg DS, Edelman MJ, Horwitz EC, Uzzo RG, Fisher RI. A war on two fronts: cancer Care in the Time of COVID-19. *Ann Intern Med*. 2020;172(11):756-758. <https://doi.org/10.7326/M20-1133>.
- Torzilli G, Vigano L, Galvanin J, et al. A snapshot of elective oncological surgery in Italy during COVID-19 emergency: pearls, pitfalls and perspectives. *Ann Surg*. 2020;272(2):e112-e117.
- Vukkadala N, Qian ZJ, Holsinger FC, Patel ZM, Rosenthal E. COVID-19 and the otolaryngologist: preliminary evidence-based review. *Laryngoscope*. 2020.
- Maniakas A, Jozaghi Y, Zafereo ME, Sturgis EM, et al. Head and neck surgical oncology in the time of a pandemic: subsite-specific triage guidelines during the COVID-19 pandemic. *Head Neck*. 2020.
- Alemanno G, Tomaiuolo M, Peris A, Batacchi S, Nozzoli C, Prosperi P. Surgical perspectives and pathways in an emergency department during the COVID-19 pandemic. *Am J Surg*. 2020;220:50-52.
- All of Italy facing coronavirus lockdown. BBC News. March 9, 2020. <https://www.bbc.com/news/world-europe-51810673> (last accessed June 3, 2020).
- Argenziano M, Fischkoff K, Smith CR. Surgery Scheduling in a Crisis. *N Eng J Med*. 2020;382(23):e87. <http://dx.doi.org/10.1056/nejmc2017424>.
- Wu JT, Leung K, Leung GM. Nowcasting and forecasting the potential domestic and international spread of the 2019-nCoV outbreak originating in Wuhan, China: a modelling study. *Lancet*. 2020;395:689-697. [https://doi.org/10.1016/S0140-6736\(20\)30260-9](https://doi.org/10.1016/S0140-6736(20)30260-9).
- De Bernardi F, Turri-Zanoni M, Battaglia P, Castelnovo P. How to reorganize an ear, nose, and throat outpatient service during the COVID-19 outbreak: report from Northern Italy. *Laryngoscope*. 2020.
- Givi B, Schiff BA, Chinn SB, et al. Safety recommendations for evaluation and surgery of the head and neck during the COVID-19 pandemic. *JAMA Otolaryngol-Head Neck Surg*. 2020;146(6):579-584.
- Day AT, Sher DJ, Gordin A. Head and neck oncology during the COVID-19 pandemic: reconsidering traditional treatment paradigms in light of new surgical and other multilevel risks. *Oral Oncol*. 2020;105:104684. <https://doi.org/10.1016/j.oraloncology.2020.104684>.
- Topf MC, Shenson JA, Holsinger FC, et al. A framework for prioritizing head and neck surgery during the COVID-19 pandemic. *Head Neck*. 2020;42:1159-1167.
- Nacoti M, Ciocca A, Giupponi A, et al. At the epicenter of the COVID-19 pandemic and humanitarian crises in Italy: changing the perspectives on preparation and mitigation. *NEJM Catalyst New Engl J Med*. 2020. <https://catalyst.nejm.org/doi/abs/10.1056/CAT.20.0080>.
- Karligkiotis A, Arosio AD, Battaglia P, et al. Changing paradigms in sinus and skull base surgery as the COVID-19 pandemic evolves: Preliminary experience from a single Italian tertiary care center. *Head Neck*. 2020;42(7):1610-1620. <http://dx.doi.org/10.1002/hed.26320>.
- Patriti A, Eugeni E, Guerra F. What happened to surgical emergencies in the era of COVID-19 outbreak? Considerations of surgeons working in an Italian COVID-19 red zone. *Updates Surg*. 2020;72(6):309-310.
- Sud A, Jones M, Broggio J, et al. Collateral damage: the impact on outcomes from cancer surgery of the COVID-19 pandemic. *Ann Oncol*. 2020;31:1065-1074. <https://doi.org/10.1016/j.annonc.2020.05.009>.
- Lazzerini M, Barbi E, Apicella A, Marchetti F, Cardinale F, Trobia G. Delayed access or provision of care in Italy resulting from fear of COVID-19. *Lancet Child Adolesc Health*. 2020;4(5):e10-e11. [https://doi.org/10.1016/S2352-4642\(20\)30108-5](https://doi.org/10.1016/S2352-4642(20)30108-5).

29. Faggioli S, Lorini FL, Remuzzi G. Adaptations and lessons in the province of Bergamo. *N Engl J Med*. 2020;382:e71.
30. Chen JX, Workman AD, Chari DA, et al. Demonstration and mitigation of aerosol and particle dispersion during mastoidectomy relevant to the COVID-19 era. *Otol Neurotol*. 2020.
31. Topsakal V, Van Rompaey V, Kuhweide R, et al. Prioritizing otological surgery during the COVID-19 pandemic. *B-ENT*. 2020;10.

**How to cite this article:** Gallo O, Locatello LG, Orlando P, et al. The clinical consequences of the COVID-19 lockdown: A report from an Italian referral ENT department. *Laryngoscope Investigative Otolaryngology*. 2020;5:824–831. <https://doi.org/10.1002/liv2.446>