



Contents lists available at ScienceDirect

Journal of Hand Surgery Global Online

journal homepage: [www.JHSGO.org](http://www.JHSGO.org)

Original Research

## Peripheral Nerve Injury After Upper-Extremity Surgery Performed Under Regional Anesthesia: A Systematic Review



Max Lester Silverstein, MD, \* Ruth Tevlin, MD, \* Kenneth Elliott Higgins, MD, † Rachel Pedreira, MD, \* Catherine Curtin, MD \* , ‡

\* Division of Plastic and Reconstructive Surgery, Stanford Hospital and Clinics, Palo Alto, CA

† Department of Anesthesiology, University of Vermont Larner College of Medicine, Burlington, VT

‡ Department of Surgery, Palo Alto Veterans Hospital, Palo Alto, CA

### ARTICLE INFO

#### Article history:

Received for publication February 10, 2022

Accepted in revised form April 25, 2022

Available online June 4, 2022

#### Key words:

Brachial plexus

Nerve injury

PNI

Regional anesthesia

**Purpose:** Peripheral nerve injury (PNI) is a known adverse event following upper-limb surgery performed under brachial plexus regional anesthesia (RA). When PNI is noted after surgery, patients and providers often have questions about which factors might have contributed to this complication. This systematic review evaluates the literature on hand and shoulder surgeries performed under ultrasound-guided, plexus RA to identify factors potentially associated with PNI, including the surgery location and block type. We hypothesized that shoulder surgery might be associated with an increased risk of PNI compared to hand surgery.

**Methods:** A systematic review of the relevant literature was performed in accordance with the Preferred Reporting Items for Systematic Reviews and Meta-Analyses guidelines. Only prospective studies on the use of ultrasound-guided, preoperative, brachial plexus RA for hand or shoulder surgery on adult patients were included. Study groups were categorized according to surgery location and block type and compared across a number of factors via univariate and multivariate analyses.

**Results:** A total of 3,037 abstracts were screened; 192 full-text articles were independently reviewed by 2 of the authors; and 53 studies were included in the systematic review analysis. Following hand surgery, PNI was reported at an average rate of  $1.35\% \pm 3.21\%$  across 836 subjects in 40 study groups; after shoulder surgery, the average rate was  $0.50\% \pm 1.57\%$  across 3,383 subjects in 15 study groups. There was no statistically significant correlation between the incidence of PNI and surgery location ( $P = .70$ ) or any of the most common approaches for brachial plexus anesthesia in the multivariate analysis.

**Conclusions:** This systematic review of over 50 articles on upper-limb surgery performed under RA shows no association between the incidence of PNI and the location of surgery or type of brachial plexus block.

**Type of study/level of evidence:** Diagnostic II.

Published by Elsevier Inc. on behalf of The American Society for Surgery of the Hand. This is an open access article under the CC BY-NC-ND license (<http://creativecommons.org/licenses/by-nc-nd/4.0/>).

Regional anesthesia (RA) of the brachial plexus is a valuable technique in upper-extremity surgery. Compared to general

anesthesia, RA can improve postoperative pain, speed rehabilitation, and reduce the incidence of postoperative nausea and vomiting following both hand and shoulder surgery.<sup>1–4</sup> However, RA carries a risk of iatrogenic nerve injury, a rare but potentially devastating complication for affected patients.<sup>5,6</sup> Despite several studies on the topic, the exact incidence of nerve injury caused by plexus RA remains unclear, with estimates ranging from 0.01% to 14%.<sup>7–10</sup>

Surgical nerve injury is a dreaded postoperative complication occurring either secondary to direct intraoperative injury or, more commonly, as an indirect result of traction on or contusion to the nerve.<sup>11</sup> Certain factors increase the risk of surgical nerve injury, such as patient positioning, duration of the

**Declaration of interests:** R.T. was supported by the Plastic Surgery Research Council Research Fellowship Grant and the Stanford University Transplant and Tissue Engineering Center of Excellence Research Grant. No benefits in any form have been received or will be received by the other authors related directly or indirectly to the subject of this article. The views expressed in this article are those of the authors and do not necessarily reflect the position or policy of the Department of Veterans Affairs or the United States government.

**Corresponding author:** Catherine Curtin, MD, Division of Plastic and Reconstructive Surgery, Stanford University Medical Center, 770 Welch Road, Suite 400, Stanford Hospital and Clinics, Palo Alto, CA 94304.

E-mail address: [c Curtin@stanford.edu](mailto:c Curtin@stanford.edu) (C. Curtin).

<https://doi.org/10.1016/j.jhsg.2022.04.011>

2589-5141/Published by Elsevier Inc. on behalf of The American Society for Surgery of the Hand. This is an open access article under the CC BY-NC-ND license (<http://creativecommons.org/licenses/by-nc-nd/4.0/>).

surgery, retraction technique, and anatomy of the surgical field.<sup>10–13</sup>

Whether caused by needle-nerve contact during RA administration or by surgical trauma itself, postoperative peripheral nerve injury (PNI) can range from neurapraxia, which resolves spontaneously over the course of a few months, to complete nerve transection or neurotmesis.<sup>14</sup> When PNI occurs following surgery performed under RA, anesthesiologists, and surgeons often try to discern whether the complication is most likely a result of the surgery itself or the block. This quandary was studied recently by Droog et al<sup>7</sup> in their trial of 297 patients, which did not identify any specific risk factors for nerve injury following distal upper-extremity surgery performed under RA.

A large body of data on iatrogenic nerve complications exists in the surgery and anesthesiology literature on upper-extremity surgery performed under brachial plexus RA. The studies, which report nerve complications as a nonprimary end point, present an opportunity to more robustly answer the following question: can PNI be reliably associated with certain types of upper-limb surgery or block procedures? Given our clinical experience, we hypothesized that the location of surgery (shoulder surgery, in particular) would be associated with an increased risk of PNI. In this systematic review, we evaluated the literature on hand and shoulder surgeries performed under ultrasound-guided plexus RA to identify factors potentially associated with PNI, including the surgery location and block type.

## Materials and Methods

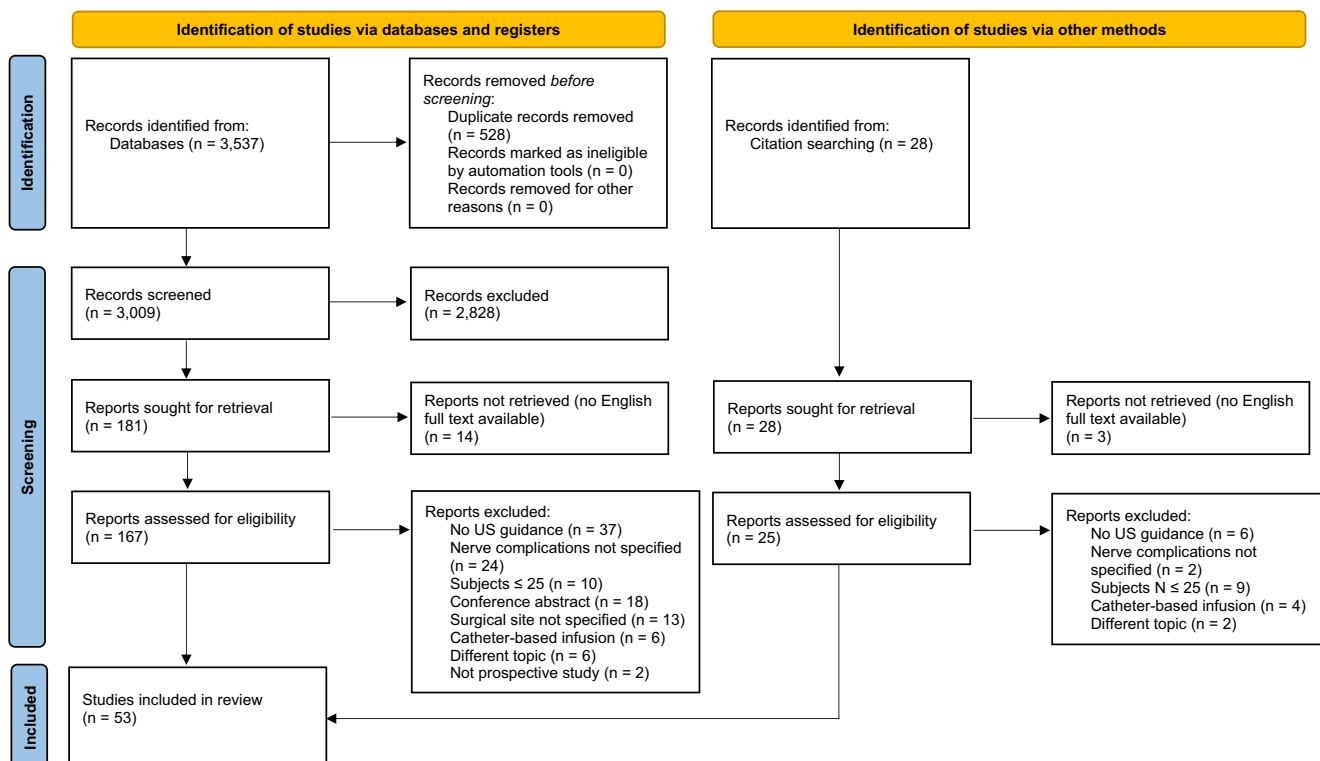
A systematic review of the relevant literature was performed in accordance with the Preferred Reporting Items for Systematic Reviews and Meta-Analyses guidelines (Fig.).<sup>15</sup>

## Search strategy and eligibility criteria

PubMed, the Cochrane Library databases, EMBASE, and Scopus were searched in August 2020 for articles published between 1980 and 2020 using key words related to brachial plexus anesthesia, hand or shoulder surgeries, and nerve injuries. The references of relevant studies and prior systematic reviews were reviewed for additional studies. Duplicate and non-English articles were excluded, as were nonoriginal articles (eg, letters, reviews, meta-analyses) and abstract-only publications.

Only prospective studies (levels of evidence I and II) on the use of preoperative, brachial plexus RA for hand or shoulder surgery on adult patients were included. For the purposes of this review, “hand surgery” encompassed any upper-extremity surgery distal to the elbow, and “shoulder surgery” was strictly surgery of the shoulder joint or rotator cuff muscles. Only studies using the most common brachial plexus block approaches—interscalene, supraclavicular, infraclavicular, axillary, and suprascapular—were included. Studies with  $\leq 25$  subjects per treatment group were excluded. Articles were also excluded if they did not report postoperative nerve complications, if they did not specify the surgical site (ie, “upper-extremity surgery”) or if their primary focus was on the use of an adjuvant medication to improve block efficacy.

Only studies in which RA was performed using ultrasound guidance (vs nerve stimulation) were included, given evidence that ultrasound may improve the efficacy and reduce the complications of brachial plexus block.<sup>16–21</sup> However, studies were not excluded if nerve stimulation was used only as an adjunct to ultrasound guidance. Studies were excluded if RA was administered via a continuous catheter infusion (vs injected boluses), as the use of catheters in brachial plexus blockade has been associated with a higher incidence of neurologic injuries.<sup>22</sup> Finally, studies were excluded if RA was performed in the emergency department or if



**Figure.** Preferred Reporting Items for Systematic Reviews and Meta-Analyses flow diagram for systematic reviews. From Page et al.<sup>15</sup> For more information, visit <http://www.prisma-statement.org/>. US, ultrasound.

surgery was performed outside the operating room, because of the unique challenges of those environments.

### Study selection and data extraction

A total of 3,037 abstracts were screened following removal of duplicates; 192 full-text articles were independently reviewed by 2 of the authors (R.T. and C.C.). There were no disagreements on study inclusion. In total, 53 articles matched the criteria for systematic review and were included in the analysis. A third author (M.L.S.) extracted data relevant to the surgery location; block type, drug, and volume; use of adjunctive nerve stimulation; and the incidences of transient paresthesias and PNI.

### Outcomes

Studies were categorized according to the level of blinding and randomization. In double-blind randomized controlled trials (RCTs), both patients and researchers assessing postoperative outcomes were blinded to the type of RA. In single-blind RCTs, only patients were blind to the block approach. In unblinded RCTs, both patients and researchers were aware of the RA method. In all RCTs, patients were randomly assigned to 1 of 2 or more intervention groups or placebo; in cohort studies, no randomization occurred.

For the analysis, each study group with a certain [surgery location] × [block approach] combination was considered a unique entity (ie, if a single study on hand surgery included 30 patients who underwent axillary block and a separate 30 patients treated with infraclavicular block, those subjects were analyzed as 2 separate study groups of 30 patients each). In 3 cases, within-article study groups were treated separately on the basis of whether or not an adjunctive nerve stimulator was used.<sup>23–25</sup> This method was used to maintain as much within-group homogeneity as possible.

A nerve injury was defined in this review as a new-onset motor or sensory deficit, persistent paresthesia, allodynia, or dysesthesia in the operated limb. Nerve symptoms confined to a very distal part of the upper extremity following hand surgery were excluded as representing surgical trauma that could not realistically be attributed to the brachial plexus block procedure.

Nerve complications reported either during the block procedure or within 24 hours following surgery were further classified as transient paresthesias. Only nerve complications present ≥30 days after surgery were classified as true PNIs. Nerve symptoms that resolve in <30 days likely represent neurapraxia, or nerve dysfunction without anatomic disruption, and confer little long-term disability to patients. Conversely, symptoms persisting after 1 month are much more likely to represent axonotmesis or neurotmesis, which are disruptive nerve injuries that carry more serious, and often permanent, prognoses.<sup>14,26–30</sup>

### Statistical analysis

A univariate analysis was performed to compare the hand-surgery and shoulder-surgery study groups across a number of relevant variables, including the use of epinephrine, the volume of drug used in RA, and adjunctive use of nerve stimulation. The incidences of transient paresthesias and PNI were also compared and calculated as unweighted averages of the incidences reported per study. Categorical variables were compared using the Pearson's chi-square test; continuous variables were compared using an unpaired Student *t* test. A multiple linear regression model was used to identify variables that could be independently associated with the incidence of PNI. Statistical significance was defined as a 2-tailed *P* value of <.05, reflecting the probability of a type I error. An 80%

power analysis was performed using a superiority margin of a 2% difference in the rate of PNI.

### Results

A total of 53 articles were included in this systematic review: 38 hand studies and 15 shoulder studies (Table S1, available on the Journal's website at [www.jhsgo.org](http://www.jhsgo.org)).<sup>18–20,21,23–25,31–76</sup> These 53 articles comprised 73 discrete, surgery-block combination study groups (54 hand and 19 shoulder groups) and 6,579 total subjects (2,875 hand and 3,704 shoulder subjects; Table 1). The large majority of studies in both groups were RCTs (94.4% hand and 78.9% shoulder RCTs); most were single-blind. Hand surgeries were performed under axillary (35.2%), infraclavicular (35.2%), or supraclavicular (29.6%) block. The majority of shoulder surgeries were performed under interscalene (73.7%) or suprascapular (15.8%) block. There was no statistically significant difference in the use of nerve stimulation ( $P = .42$ ) when comparing hand- and shoulder-surgery studies, but epinephrine was used more often in hand-surgery plexus RA (59.3% vs 31.6%, respectively;  $P = .04$ ), and a significantly greater volume of an RA drug was injected prior to hand surgery ( $32.4 \pm 8.9$  cc vs  $26.6 \pm 15.2$  cc, respectively;  $P = .05$ ; Table 1).

There was no statistically significant difference in the incidences of transient paresthesias (nerve symptoms reported within 24 hours of the block) or PNI (nerve symptoms reported ≥30 days after surgery) when comparing hand versus shoulder surgery ( $P = .50$  and .34, respectively; Table 2). Following hand surgery, PNI was reported at an average rate of  $1.35\% \pm 3.21\%$  across 836 subjects in 40 study groups; the average incidence after shoulder surgery was  $0.50\% \pm 1.57\%$  across 3,383 subjects in 15 study groups.

None of the variables tested in the multivariate analysis were associated with the incidence of postoperative PNI (Table 3). Most notably, the location of surgery (hand vs shoulder) had no statistically significant correlation with PNI ( $P = .70$ ). The study was adequately powered, with both groups surpassing the sample size required (107 subjects) to detect a 2% difference in the rate of PNI. Similarly, the occurrence of transient paresthesias within 24 hours of the block procedure did not translate to a higher risk of PNI at ≥30 days after surgery ( $P = .25$ ). Each of the 4 most common block approach types was also tested; none carried an independent association with the incidence of PNI (Table 3).

### Discussion

Following a surgical complication, patients and care providers try to understand what occurred. A PNI after an upper-limb surgery performed under RA often leads to speculation as to whether the injury occurred as a result of the brachial plexus block or surgical trauma. Although a clinical examination and/or EMG can provide diagnostic information, a definitive understanding of the etiology of PNI is often impossible.

The results of this systematic review argue against the notion that a new PNI following upper-limb surgery can be reliably ascribed to either the surgery or the block procedure. Our study revealed no statistically significant difference in the incidence of PNI following hand surgery compared to the incidence following shoulder surgery performed under brachial plexus block. Moreover, across the 53 included studies, neither the surgery location nor the RA approach was an independent predictor of PNI. While individual included studies have compared certain block approaches and found different nerve complication rates, those studies have been very small (82 subjects on average) given the low incidence of nerve complications overall ( $1.35\% \pm 3.21\%$  following hand surgery and  $0.50\% \pm 1.57\%$  after shoulder surgery in our review). By

**Table 1**  
Study Characteristics

Characteristic	Hand (n = 54)	Shoulder (n = 19)	Total (N = 73)	P Value
Unique studies	38	15	53	
Total subjects	2,875	3,704	6,579	
Subjects per study	53.2 (24.6)	194.9 (323.0)	90.1 (174.5)	
Mean (SD)	40.0 (26.0, 122.0)	67.0 (26.0, 1,319.0)	44.0 (26.0, 1,319.0)	
Median (range)	6 (11.1%)	5 (26.3%)	11 (15.1%)	
Study types	36 (66.7%)	10 (52.6%)	46 (63.0%)	
Double-blind RCT	9 (16.7%)	0 (0.0%)	9 (12.3%)	
Single-blind RCT	3 (5.6%)	4 (21.1%)	7 (9.6%)	
Unblinded RCT	19 (35.2%)	0 (0.0%)	19 (26.0%)	
Cohort study	19 (35.2%)	0 (0.0%)	19 (26.0%)	
Block types	0 (0.0%)	14 (73.7%)	14 (19.2%)	
AX	16 (29.6%)	1 (5.3%)	17 (23.3%)	
ICL	0 (0.0%)	1 (5.3%)	1 (1.4%)	
ISB	0 (0.0%)	3 (15.8%)	3 (4.1%)	
SCL	32 (59.3%)	6 (31.6%)	38 (52.1%)	.038
SSAX				.050
SSC	32.4 (8.9)	26.6 (15.2)	30.8 (11.1)	
Epinephrine used	12 (22.2%)	6 (31.6%)	18 (24.7%)	.416
Volume injected, cc	38	15	53	
Mean (SD)	287553.2 (24.6)	3704194.9 (323.0)	657990.1 (174.5)	
Nerve stimulator adjunct	40.0 (26.0, 122.0)	67.0 (26.0, 1319.0)	44.0 (26.0, 1319.0)	

AX, axillary; ICL, infraclavicular; ISB, interscalene; SCL, supraclavicular; SSAX, suprascapular-axillary; SSC, suprascapular.

**Table 2**  
Incidence of Nerve Complications

Incidence of Nerve Complications	Hand (n = 54)	Shoulder (n = 19)	Total (N = 73)	P Value
Incidence of transient paresthesias				.500
Study groups reporting	50	13	63	
Subjects	2,601	2,066	4,667	
Mean (SD)	0.0941 (0.1276)	0.0682 (0.1005)	0.0888 (0.1222)	
Incidence of PNI				.335
Study groups reporting	40	15	55	
Subjects	836	3,383	4,219	
Mean (SD)	0.0135 (0.0321)	0.0050 (0.0157)	0.0112 (0.0287)	

**Table 3**  
Multiple Linear Regression Analysis

Factor	Incidence of PNI		
	Coefficient	95% CI	P Value
Hand vs shoulder surgery	0.01	−0.05 to 0.07	.697
Nerve stimulator adjunct	−0.01	−0.03 to 0.01	.247
Epinephrine used	0.01	−0.01 to 0.03	.263
Volume injected	−0.00	−0.00 to 0.00	.068
Incidence of transient paresthesias	0.05	−0.04 to 0.14	.290
AX block	0.02	−0.01 to 0.04	.178
ICL block	0.02	−0.01 to 0.04	.160
ISB block	−0.02	−0.08 to 0.05	.598
SCL block	−0.02	−0.11 to 0.06	.559
Observations		50	
R <sup>2</sup> /R <sup>2</sup> adjusted		0.173/−0.013	

Multiple linear regression analysis for factors that could affect the incidence of PNI. AX, axillary; CI, confidence interval; ICL, infraclavicular; ISB, interscalene; SCL, supraclavicular.

aggregating the findings in over 50 studies on the topic, this systematic review offers a more complete picture of the associations between certain types of upper-extremity surgery or brachial plexus RA and PNI, or the lack thereof.

Peripheral nerve injury is a broad term that encompasses a wide range of insults to peripheral nerves. The Seddon classification system remains most commonly used, and divides PNIs into 3 major categories (neurapraxia, axonotmesis, and neurotmesis).<sup>14,26</sup> The mildest form of PNI, neurapraxia, is typically a result of mild

compression or traction on a nerve; symptoms (eg, paresthesias, motor or sensory weakness, allodynia, dysesthesia) resolve within days or weeks and do not result in a lasting disability.<sup>27</sup> The more severe types of PNI associated with RA are axonotmesis and neurotmesis, in which disruption of the nerve architecture occurs. Axonotmesis is commonly caused by stretch or crush injuries and can take months or years for a full or partial recovery.<sup>77,78</sup> Neurotmesis is defined by complete disruption of the nerve, which will not recover without surgical intervention. In this study, nerve injuries were classified according to their long-term relevance. Paresthesias and other nerve symptoms reported during the block procedure or within 24 hours of surgery can be indicative of mild neurapraxias.<sup>27,28</sup> Conversely, symptoms persisting at 30 days are much more likely to represent structural injuries—axonotmesis or neurotmesis—that confer real morbidity to patients and may require intervention.<sup>14,26–30</sup> Patients who experience a long-lasting PNI are at high risk of physical disability, emotional problems, and the development of complex regional pain syndrome, highlighting the importance of prompt evaluation of persistent postoperative nerve symptoms.<sup>79,80</sup>

There are several mechanisms by which RA administration can result in PNI. Direct needle-nerve contact is common during brachial plexus block.<sup>81</sup> Indeed, before the widespread adoption of ultrasound, anesthesiologists often used nerve stimulators to locate branches of the brachial plexus by contacting the nerves and asking patients to report paresthesias. Even with the use of ultrasound, patients frequently report paresthesias during block procedures, and direct needle trauma is likely the etiology in some cases of

PNI.<sup>82</sup> Chemical neurotoxicity is another mechanism that has been proposed for RA-induced PNI. All local anesthetics are potentially neurotoxic, and some may cause both focal demyelination and axonal destruction, per animal studies.<sup>83–85</sup> Additionally, supplemental epinephrine has been proposed to induce nerve ischemia because of vasoconstriction of supplying blood vessels, though we did not identify a correlation between the use of epinephrine and PNI in our analysis (Table 3).<sup>86</sup> Finally, hematoma and bleeding are not uncommon following brachial plexus block and can cause compression within the brachial fascial compartments, resulting in ischemic changes and axonal death.<sup>87,88</sup>

Surgery can cause PNI through a variety of mechanisms: crushing, stretching, contusion, laceration, transection, or incorporation of a nerve in the suture repair. Shoulder surgery, in particular, occurs in a region heavily innervated by branches of the brachial plexus. The suprascapular nerve may lie within 1 cm of the glenoid rim. The axillary nerve passes 5–6 cm distal to the lateral edge of the acromion and near the deltoid split commonly used as an approach to the shoulder joint. The musculocutaneous nerve is commonly located 1–3.8 cm medial to the lower edge of the coracoid, making inadvertent nerve injury quite imaginable.<sup>11,88,89</sup> Additionally, both of the most common positions for shoulder surgery—lateral decubitus and beach chair—have been associated with nerve injuries caused by traction or nerve compression.<sup>90–92</sup>

In hand and forearm surgery, the musculocutaneous, median, ulnar, and radial nerves are subject to similar risks of injury because of traction, contusion, and laceration. One might assume it would be easier to distinguish between nerve injuries caused by RA at the brachial plexus and those caused by these more distal surgeries. However, injuries because of brachial plexus block sometimes present in the distal distributions of its branches, mimicking more distal surgical injuries. Studies have reported nerve injuries caused by the axillary approach to the brachial plexus block presenting only in the distal distributions of the median or ulnar nerve; other studies posit that block-induced hematoma may accumulate in the medial brachial fascial compartment through which the median and ulnar nerves travel to the elbow level, producing symptoms in the distal arm or hand.<sup>82,87,88,93</sup> As a result, physicians are often unable to confidently discriminate between PNI caused by brachial plexus block and surgically induced PNI, whether surgery occurred at the shoulder or the hand.

Given the ambiguity surrounding the etiology in many cases of PNI, anesthesiologists and surgeons often attribute postoperative nerve injuries to either the block procedure or the surgery based on personal experience, anecdotal evidence, nonspecific findings on ultrasound or magnetic resonance imaging, or poorly supported notions about the safety of 1 technique over another. This review should help provide more systematic information about postoperative PNIs. We did not find that shoulder surgery was associated with a greater risk of PNI compared to hand surgery, as was our initial perception from clinical experience. Our results indicate that physicians should avoid making assumptions about the location and etiology of a postoperative PNI based solely on the surgical approach or block procedure. Instead, practitioners should be aware that the possible causes of iatrogenic PNIs are numerous and sometimes multifactorial, and should use diagnostic tools such as electrodiagnostic testing and physical examination to locate the site of nerve trauma if symptoms persist longer than a month.<sup>94,95</sup>

There are several limitations to our study. A meta-analysis is the preferred method for extracting conclusions from a body of literature, but this was not possible here because of the lack of standardized control or comparison groups among the included studies. The strength of this systematic review is in its aggregation of complication data from a large collection of studies comparing various approaches to the brachial plexus. This variety, however,

means that few studies performed exactly the same interventions or used identical control groups, making a meta-analysis impossible. Similarly, there was heterogeneity in the way studies defined nerve complications and the time points at which patients were evaluated. To address that issue, we attempted to sort nerve symptoms into generalized categories of transient paresthesia (noted within 24 hours of surgery) and more clinically relevant PNIs (reported  $\geq 30$  days after surgery), though the authors understand this is a simplified solution. Finally, in any systematic review, some level of between-study heterogeneity is accepted to allow investigators to use the power of combined data to make more comprehensive conclusions; this review is no different.

## References

- Hadzic A, Williams BA, Karaca PE, et al. For outpatient rotator cuff surgery, nerve block anesthesia provides superior same-day recovery over general anesthesia. *Anesthesiology*. 2005;102(5):1001–1007.
- Ritchie ED, Tong D, Chung F, Norris AM, Miniaci A, Vairavanathan SD. Suprascapular nerve block for postoperative pain relief in arthroscopic shoulder surgery: a new modality? *Anesth Analg*. 1997;84(6):1306–1312.
- Chan VW, Peng PW, Kaszas Z, et al. A comparative study of general anesthesia, intravenous regional anesthesia, and axillary block for outpatient hand surgery: clinical outcome and cost analysis. *Anesth Analg*. 2001;93(5):1181–1184.
- Hadzic A, Arliss J, Kerimoglu B, et al. A comparison of infraclavicular nerve block versus general anesthesia for hand and wrist day-case surgeries. *Anesthesiology*. 2004;101(1):127–132.
- Sites BD, Taenzer AH, Herrick MD, et al. Incidence of local anesthetic systemic toxicity and postoperative neurologic symptoms associated with 12,668 ultrasound-guided nerve blocks: an analysis from a prospective clinical registry. *Reg Anesth Pain Med*. 2012;37(5):478–482.
- Neal JM, Barrington MJ, Brull R, et al. The second ASRA practice advisory on neurologic complications associated with regional anesthesia and pain medicine: executive summary 2015. *Reg Anesth Pain Med*. 2015;40(5):401–430.
- Droog W, Lin DY, van Wijk JJ, et al. Is it the surgery or the block? Incidence, risk factors, and outcome of nerve injury following upper extremity surgery. *Plast Reconstr Surg Glob Open*. 2019;7(9):e2458.
- Dwyer T, Henry PD, Cholvisudhi P, Chan VW, Theodoropoulos JS, Brull R. Neurological complications related to elective orthopedic surgery: part 1: common shoulder and elbow procedures. *Reg Anesth Pain Med*. 2015;40(5):431–442.
- Borgeat A, Ekatothramis G, Kalberer F, Benz C. Acute and nonacute complications associated with interscalene block and shoulder surgery: a prospective study. *Anesthesiology*. 2001;95(4):875–880.
- Sviggum HP, Jacob AK, Mantilla CB, Schroeder DR, Sperling JW, Hebl JR. Perioperative nerve injury after total shoulder arthroplasty: assessment of risk after regional anesthesia. *Reg Anesth Pain Med*. 2012;37(5):490–494.
- Boardman ND III, Cofield RH. Neurologic complications of shoulder surgery. *Clin Orthop Relat Res*. 1999;368(368):44–53.
- Candido KD, Sukhani R, Doty R II, et al. Neurologic sequelae after interscalene brachial plexus block for shoulder/upper arm surgery: the association of patient, anesthetic, and surgical factors to the incidence and clinical course. *Anesth Analg*. 2005;100(5):1489–1495.
- Verdecchia N, Johnson J, Baratz M, Orebaugh S. Neurologic complications in common wrist and hand surgical procedures. *Orthop Rev (Pavia)*. 2018;10(1):7355.
- Seddon HJ. Three types of nerve injury. *Brain*. 1943;66(4):237–288.
- Page MJ, McKenzie JE, Bossuyt PM, et al. The PRISMA 2020 statement: an updated guideline for reporting systematic reviews. *BMJ*. 2021;372:n71.
- Kapral S, Krafft P, Eibenberger K, Fitzgerald R, Gosch M, Weinstabl C. Ultrasound-guided supraclavicular approach for regional anesthesia of the brachial plexus. *Anesth Analg*. 1994;78(3):507–513.
- Ootaki C, Hayashi H, Amano M. Ultrasound-guided infraclavicular brachial plexus block: an alternative technique to anatomical landmark-guided approaches. *Reg Anesth Pain Med*. 2000;25(6):600–604.
- Williams SR, Chouinard P, Arcand G, et al. Ultrasound guidance speeds execution and improves the quality of supraclavicular block. *Anesth Analg*. 2003;97(5):1518–1523.
- Brull R, Lupu M, Perlas A, Chan VW, McCartney CJ. Compared with dual nerve stimulation, ultrasound guidance shortens the time for infraclavicular block performance. *Can J Anaesth*. 2009;56(11):812–818.
- Tran DQ, Clemente A, Tran DQ, Finlayson RJ. A comparison between ultrasound-guided infraclavicular block using the "Double Bubble" sign and neurostimulation-guided axillary block. *Anesth Analg*. 2008;107(3):1075–1078.
- Zencirci B. Comparison of nerve stimulator and ultrasonography as the techniques applied for brachial plexus anesthesia. *Int Arch Med*. 2011;4(1):4.

22. Holbrook HS, Parker BR. Peripheral nerve injury following interscalene blocks: a systematic review to guide orthopedic surgeons. *Orthopedics*. 2018;41(5):e598–e606.
23. Azmin F, Choy Y. Regional infraclavicular blocks via the coracoid approach for below-elbow surgery: a comparison between ultrasound guidance with, or without, nerve stimulation. *South Afr J Anaesth Analg*. 2013;19(5):263–269.
24. Imasogie N, Ganapathy S, Singh S, Armstrong K, Armstrong P. A prospective, randomized, double-blind comparison of ultrasound-guided axillary brachial plexus blocks using 2 versus 4 injections. *Anesth Analg*. 2010;110(4):1222–1226.
25. Chan VW, Perlas A, McCartney CJ, Brull R, Xu D, Abbas S. Ultrasound guidance improves success rate of axillary brachial plexus block. *Can J Anaesth*. 2007;54(3):176–182.
26. Sunderland S. A classification of peripheral nerve injuries producing loss of function. *Brain*. 1951;74(4):491–516.
27. Choi EJ, Choi YM, Jang EJ, Kim JY, Kim TK, Kim KH. Neural ablation and regeneration in pain practice. *Korean J Pain*. 2016;29(1):3–11.
28. Alvites R, Rita Caseiro A, Santos Pedrosa S, et al. Peripheral nerve injury and axonotmesis: state of the art and recent advances. *Cogent Med*. 2018;5(1):1466404.
29. Burnett MG, Zager EL. Pathophysiology of peripheral nerve injury: a brief review. *Neurosurg Focus*. 2004;16(5):E1.
30. Campbell WW. Evaluation and management of peripheral nerve injury. *Clin Neurophysiol*. 2008;119(9):1951–1965.
31. Ambi U, Bhanupriya P, Hulkund SY, Prakashappa DS. Comparison between perivascular and perineural ultrasound-guided axillary brachial plexus block using levobupivacaine: a prospective, randomised clinical study. *Indian J Anaesth*. 2015;59(10):658–663.
32. Arcand G, Williams SR, Chouinard P, et al. Ultrasound-guided infraclavicular versus supraclavicular block. *Anesth Analg*. 2005;101(3):886–890.
33. Bloc S, Mercadal L, Garnier T, et al. Comfort of the patient during axillary blocks placement: a randomized comparison of the neurostimulation and the ultrasound guidance techniques. *Eur J Anaesthesiol*. 2010;27(7):628–633.
34. Boivin A, Nadeau MJ, Dion N, Lévesque S, Nicole PC, Turgeon AF. Ultrasound-guided single-injection infraclavicular block versus ultrasound-guided double-injection axillary block: a noninferiority randomized controlled trial. *Anesth Analg*. 2016;122(1):273–278.
35. Brenner D, Iohom G, Mahon P, Shorten G. Efficacy of axillary versus infraclavicular brachial plexus block in preventing tourniquet pain: a randomised trial. *Eur J Anaesthesiol*. 2019;36(1):48–54.
36. Casati A, Danelli G, Baciarello M, et al. A prospective, randomized comparison between ultrasound and nerve stimulation guidance for multiple injection axillary brachial plexus block. *Anesthesiology*. 2007;106(5):992–996.
37. Choudhary N, Kumar A, Kohli A, et al. Single-point versus double-point injection technique of ultrasound-guided supraclavicular block: a randomized controlled study. *J Anaesthesiol Clin Pharmacol*. 2019;35(3):373–378.
38. Desgagnés MC, Lévesque S, Dion N, et al. A comparison of a single or triple injection technique for ultrasound-guided infraclavicular block: a prospective randomized controlled study. *Anesth Analg*. 2009;109(2):668–672.
39. Ertikin A, Argun C, Misirlioğlu M, Aydın M, Arkan M, Kadioğulları N. Comparison between the two-injection technique and the four-injection technique in axillary brachial plexus block with articaine. *Turk J Anaesthesiol Reanim*. 2017;45(5):289–296.
40. Frederiksen BS, Koscielniak-Nielsen ZJ, Jacobsen RB, Rasmussen H, Hesselbjerg L. Procedural pain of an ultrasound-guided brachial plexus block: a comparison of axillary and infraclavicular approaches. *Acta Anaesthesiol Scand*. 2010;54(4):408–413.
41. Fredrickson MJ, Kilfoyle DH. Neurological complication analysis of 1000 ultrasound guided peripheral nerve blocks for elective orthopaedic surgery: a prospective study. *Anaesthesia*. 2009;64(8):836–844.
42. Fredrickson MJ, Patel A, Young S, Chinchawal S. Speed of onset of “corner pocket supraclavicular” and infraclavicular ultrasound guided brachial plexus block: a randomised observer-blinded comparison. *Anaesthesia*. 2009;64(7):738–744.
43. Grape S, Pawa A, Weber E, Albrecht E. Retroclavicular vs supraclavicular brachial plexus block for distal upper limb surgery: a randomised, controlled, single-blinded trial. *Br J Anaesth*. 2019;122(4):518–524.
44. Hussien RM, Ibrahim DA. Ultrasound guided axillary brachial plexus block versus supraclavicular block in emergency crushed hand patients: a comparative study. *Open Anesthesiol J*. 2018;12(1):34–41.
45. Kavrut Ozturk N, Kavakli AS. Comparison of the coracoid and retroclavicular approaches for ultrasound-guided infraclavicular brachial plexus block. *J Anesth*. 2017;31(4):572–578.
46. Kii N, Yamauchi M, Takahashi K, Yamakage M, Wada T. Differential axillary nerve block for hand or forearm soft-tissue surgery. *J Anesth*. 2014;28(4):549–553.
47. Koscielniak-Nielsen ZJ, Frederiksen BS, Rasmussen H, Hesselbjerg L. A comparison of ultrasound-guided supraclavicular and infraclavicular blocks for upper extremity surgery. *Acta Anaesthesiol Scand*. 2009;53(5):620–626.
48. Liu FC, Liou JT, Tsai YF, et al. Efficacy of ultrasound-guided axillary brachial plexus block: a comparative study with nerve stimulator-guided method. *Chang Gung Med J*. 2005;28(6):396–402.
49. Luo Q, Yao W, Chai Y, et al. Comparison of ultrasound-guided supraclavicular and costoclavicular brachial plexus block using a modified double-injection technique: a randomized non-inferiority trial. *Biosci Rep*. 2020;40(6).
50. Luo Q, Yao W, Shu H, Zhong M. Double-injection technique assisted by a nerve stimulator for ultrasound-guided supraclavicular brachial plexus block results in better distal sensory-motor block: a randomised controlled trial. *Eur J Anaesthesiol*. 2017;34(3):127–134.
51. Sauter AR, Dodgson MS, Stubhaug A, Halstensen AM, Klaastad Ø. Electrical nerve stimulation or ultrasound guidance for lateral sagittal infraclavicular blocks: a randomized, controlled, observer-blinded, comparative study. *Anesth Analg*. 2008;106(6):1910–1915.
52. Sinha C, Kumar N, Kumar A, Kumar A, Kumar A. Comparative evaluation of two approaches of infraclavicular brachial plexus block for upper-limb surgeries. *Saudi J Anaesth*. 2019;13(1):35–39.
53. Sivashanmugam T, Ray S, Ravishankar M, Jaya V, Selvam E, Karmakar MK. Randomized comparison of extrafascial versus subfascial injection of local anesthetic during ultrasound-guided supraclavicular brachial plexus block. *Reg Anesth Pain Med*. 2015;40(4):337–343.
54. Stav A, Reyman L, Stav MY, et al. Comparison of the supraclavicular, infraclavicular and axillary approaches for ultrasound-guided brachial plexus block for surgical anesthesia. *Rambam Maimonides Med J*. 2016;7(2).
55. Strub B, Sonderegger J, Von Campe A, Grünert J, Osterwalder JJ. What benefits does ultrasound-guided axillary block for brachial plexus anaesthesia offer over the conventional blind approach in hand surgery? *J Hand Surg Eur Vol*. 2011;36(9):778–786.
56. Subramanyam R, Vaishnav V, Chan VW, Brown-Shreves D, Brull R. Lateral versus medial needle approach for ultrasound-guided supraclavicular block: a randomized controlled trial. *Reg Anesth Pain Med*. 2011;36(4):387–392.
57. Techasuk W, González AP, Bernucci F, Cupido T, Finlayson RJ, Tran DQ. A randomized comparison between double-injection and targeted intracluster-injection ultrasound-guided supraclavicular brachial plexus block. *Anesth Analg*. 2014;118(6):1363–1369.
58. Tedore TR, YaDeau JT, Maalouf DB, et al. Comparison of the transarterial axillary block and the ultrasound-guided infraclavicular block for upper extremity surgery: a prospective randomized trial. *Reg Anesth Pain Med*. 2009;34(4):361–365.
59. Vazin M, Jensen K, Kristensen DL, et al. Low-volume brachial plexus block providing surgical anesthesia for distal arm surgery comparing supraclavicular, infraclavicular, and axillary approach: a randomized observer blind trial. *BioMed Res Int*. 2016;2016:7094121.
60. Wong SS, Chan WS, Fang C, et al. Infraclavicular nerve block reduces post-operative pain after distal radial fracture fixation: a randomized controlled trial. *BMC Anesthesiol*. 2020;20(1):130.
61. Yazer MS, Finlayson RJ, Tran DQ. A randomized comparison between infraclavicular block and targeted intracluster injection supraclavicular block. *Reg Anesth Pain Med*. 2015;40(1):11–15.
62. Abdallah FW, Wijesundera DN, Laupacis A, et al. Subomohyoid anterior suprascapular block versus interscalene block for arthroscopic shoulder surgery: a multicenter randomized trial. *Anesthesiology*. 2020;132(4):839–853.
63. Ayyanagouda B, Hosalli V, Kaur P, Ambi U, Hulkund SY. Hemi-diaphragmatic paresis following extrafascial versus conventional intrafascial approach for interscalene brachial plexus block: a double-blind randomised, controlled trial. *Indian J Anaesth*. 2019;63(5):375–381.
64. Desroches A, Klouche S, Schlur C, Bauer T, Waitzenegger T, Hardy P. Suprascapular nerve block versus interscalene block as analgesia after arthroscopic rotator cuff repair: a randomized controlled noninferiority trial. *Arthroscopy*. 2016;32(11):2203–2209.
65. Dhir S, Sondekoppam RV, Sharma R, Ganapathy S, Athwal GS. A comparison of combined suprascapular and axillary nerve blocks to interscalene nerve block for analgesia in arthroscopic shoulder surgery: an equivalence study. *Reg Anesth Pain Med*. 2016;41(5):564–571.
66. Kapral S, Greher M, Huber G, et al. Ultrasonographic guidance improves the success rate of interscalene brachial plexus blockade. *Reg Anesth Pain Med*. 2008;33(3):253–258.
67. Kim DH, Lin Y, Beathe JC, et al. Superior trunk block: a phrenic-sparing alternative to the interscalene block: a randomized controlled trial. *Anesthesiology*. 2019;131(3):521–533.
68. Lim YC, Koo ZK, Ho VW, Chang SS, Manohara S, Tong QJ. Randomized, controlled trial comparing respiratory and analgesic effects of interscalene, anterior suprascapular, and posterior suprascapular nerve blocks for arthroscopic shoulder surgery. *Korean J Anesthesiol*. 2020;73(5):408–416.
69. Liu SS, Gordon MA, Shaw PM, Wilfred S, Shetty T, Yadeau JT. A prospective clinical registry of ultrasound-guided regional anesthesia for ambulatory shoulder surgery. *Anesth Analg*. 2010;111(3):617–623.
70. Liu SS, Zayas VM, Gordon MA, et al. A prospective, randomized, controlled trial comparing ultrasound versus nerve stimulator guidance for interscalene block for ambulatory shoulder surgery for postoperative neurological symptoms. *Anesth Analg*. 2009;109(1):265–271.
71. Malik T, Mass D, Cohn S. Postoperative analgesia in a prolonged continuous interscalene block versus single-shot block in outpatient arthroscopic rotator cuff repair: a prospective randomized study. *Arthroscopy*. 2016;32(8):1544–1550.e1.
72. Okoroha KR, Lynch JR, Keller RA, et al. Liposomal bupivacaine versus interscalene nerve block for pain control after shoulder arthroplasty: a prospective randomized trial. *J Shoulder Elbow Surg*. 2016;25(11):1742–1748.
73. Patel MA, Gadsden JC, Nedeljkovic SS, et al. Brachial plexus block with liposomal bupivacaine for shoulder surgery improves analgesia and reduces

- opioid consumption: results from a multicenter, randomized, double-blind, controlled trial. *Pain Med.* 2020;21(2):387–400.
74. Rajpal G, Winger DG, Cortazzo M, Kentor ML, Orebaugh SL. Neurologic outcomes after low-volume, ultrasound-guided interscalene block and ambulatory shoulder surgery. *Reg Anesth Pain Med.* 2016;41(4):477–481.
  75. Singh A, Kelly C, O'Brien T, Wilson J, Warner JJ. Ultrasound-guided interscalene block anesthesia for shoulder arthroscopy: a prospective study of 1319 patients. *J Bone Joint Surg Am.* 2012;94(22):2040–2046.
  76. Wang CJ, Ge YL, Gao J, et al. Comparison of single- and triple-injection methods for ultrasound-guided interscalene brachial plexus blockade. *Exp Ther Med.* 2018;15(3):3006–3011.
  77. Payton OD, Jackson O, Di Fabio RP. *Manual of Physical Therapy.* Churchill Livingstone; 1989.
  78. Tubbs RS, Rizk E, Shoja MM, Loukas M, Barbaro N, Spinner RJ. *Nerves and Nerve Injuries: Vol 2: Pain, Treatment, Injury, Disease and Future Directions.* Elsevier Science; 2015.
  79. Chemnitz A, Dahlin LB, Carlsson IK. Consequences and adaptation in daily life—patients' experiences three decades after a nerve injury sustained in adolescence. *BMC Musculoskelet Disord.* 2013;14:252.
  80. Murray PM, Hammert WC. *American Society for Surgery of the Hand. Hand Surgery Update VI.* American Society for Surgery of the Hand; 2016.
  81. Woolley EJ, Vandam LD. Neurological sequelae of brachial plexus nerve block. *Ann Surg.* 1959;149(1):53–60.
  82. Kim HJ, Park SH, Shin HY, Choi YS. Brachial plexus injury as a complication after nerve block or vessel puncture. *Korean J Pain.* 2014;27(3):210–218.
  83. Yamashita A, Matsumoto M, Matsumoto S, Itoh M, Kawai K, Sakabe T. A comparison of the neurotoxic effects on the spinal cord of tetracaine, lidocaine, bupivacaine, and ropivacaine administered intrathecally in rabbits. *Anesth Analg.* 2003;97(2):512–519.
  84. Radwan IA, Saito S, Goto F. The neurotoxicity of local anesthetics on growing neurons: a comparative study of lidocaine, bupivacaine, mepivacaine, and ropivacaine. *Anesth Analg.* 2002;94(2):319–324.
  85. Whitlock EL, Brenner MJ, Fox IK, Moradzadeh A, Hunter DA, Mackinnon SE. Ropivacaine-induced peripheral nerve injection injury in the rodent model. *Anesth Analg.* 2010;111(1):214–220.
  86. Neal JM. Effects of epinephrine in local anesthetics on the central and peripheral nervous systems: neurotoxicity and neural blood flow. *Reg Anesth Pain Med.* 2003;28(2):124–134.
  87. O'Keefe DM. Brachial plexus injury following axillary arteriography. Case report and review of the literature. *J Neurosurg.* 1980;53(6):853–857.
  88. Tsao BE, Wilbourn AJ. Infraclavicular brachial plexus injury following axillary regional block. *Muscle Nerve.* 2004;30(1):44–48.
  89. Rebouças F, Filho RB, Filardis C, Pereira RR, Cardoso AA. Anatomical study of the musculocutaneous nerve in relation to the coracoid process. *Rev Bras Ortop.* 2010;45(4):400–403.
  90. Rojas J, Familiari F, Bitzer A, Srikumaran U, Papalia R, McFarland EG. Patient positioning in shoulder arthroscopy: which is best? *Joints.* 2019;7(2):46–55.
  91. Pitman MI, Nainzadeh N, Ergas E, Springer S. The use of somatosensory evoked potentials for detection of neuropraxia during shoulder arthroscopy. *Arthroscopy.* 1988;4(4):250–255.
  92. Berjano P, González BG, Olmedo JF, Perez-España LA, Munilla MG. Complications in arthroscopic shoulder surgery. *Arthroscopy.* 1998;14(8):785–788.
  93. Finucane BT, Tsui BCH. Complications of brachial plexus anesthesia. In: Finucane BT, ed. *Complications of Regional Anesthesia.* Springer; 2007:121–148.
  94. Robinson LR. Traumatic injury to peripheral nerves. *Muscle Nerve.* 2000;23(6):863–873.
  95. Robinson LR. How electrodiagnosis predicts clinical outcome of focal peripheral nerve lesions. *Muscle Nerve.* 2015;52(3):321–333.