

## Case Report

Wenjie Long, Zhiling He\*, Xia Wang, Huanlin Wu, Yahui Chen, Zhongqi Yang

# Successful drug-eluting stent implantation in a male patient with dextrocardia: a case report

<https://doi.org/10.1515/med-2017-0067>

Received August 11, 2017; accepted November 29, 2017

**Abstract:** Situs inversus with dextrocardia is a rare condition, with complete transposition of all the body organs, including the heart. Percutaneous coronary intervention (PCI) in these patients is technically difficult because of the mirror image of organs. Here, we describe a 56-year-old man with coronary heart disease with known situs inversus with dextrocardia and coronary percutaneous intervention was performed for stenosis in the right coronary artery. A drug eluting stent was implanted at this site successfully. This case suggested that the interventional management of such patients follows the same general rules as for non-dextrocardia patients, but the manipulation of the catheter and projection position choices need to be taken into consideration to obtain optimal benefits for the patient.

**Keywords:** Coronary angiography, Coronary artery disease, Dextrocardia, Drug-eluting stent, Situs inversus

## 1 Introduction

Dextrocardia is a rare congenital anomaly that includes complete situs inversus, with complete transposition of all the body organs, including the heart [1]. Prevalence of coronary artery disease in this setting is not precisely

known, but considered to be similar to that in the general population [2]. Meanwhile, interventional management in such individuals is seldom reported in the literature, probably due to the rarity of this condition. Apart from standard general guidelines, special technical aspects should be considered in percutaneous coronary angioplasty of these patients, e.g. the opposite direction of manipulation of catheters. In addition, with respect to coronary imaging, mirror images are usually needed, i.e. equivalent right-sided views to produce the usual left-sided images and vice versa, without changing cranial or caudal angulations [3].

## 2 Case report

A 56-year-old hypertensive and dyslipidemia male patient with known dextrocardia (complete situs inversus type) diagnosed with coronary artery disease (CAD) four years ago, was admitted to our hospital due to aggravated symptoms of physical activity-related chest tightness and shortness of breath. The chest X-ray showed dextrocardia with a right-sided stomach air bubble. Apex located right chest, aortic arch and descending aorta were also on the right (Fig. 1A). Coronal computed tomography (CT) scan showed complete situs inversus (Fig. 1B). Moreover, the patient was diagnosed with coronary artery disease and underwent coronary angiography (CAG) four years ago, which found 50% diameter stenosis of the right coronary artery (RCA).

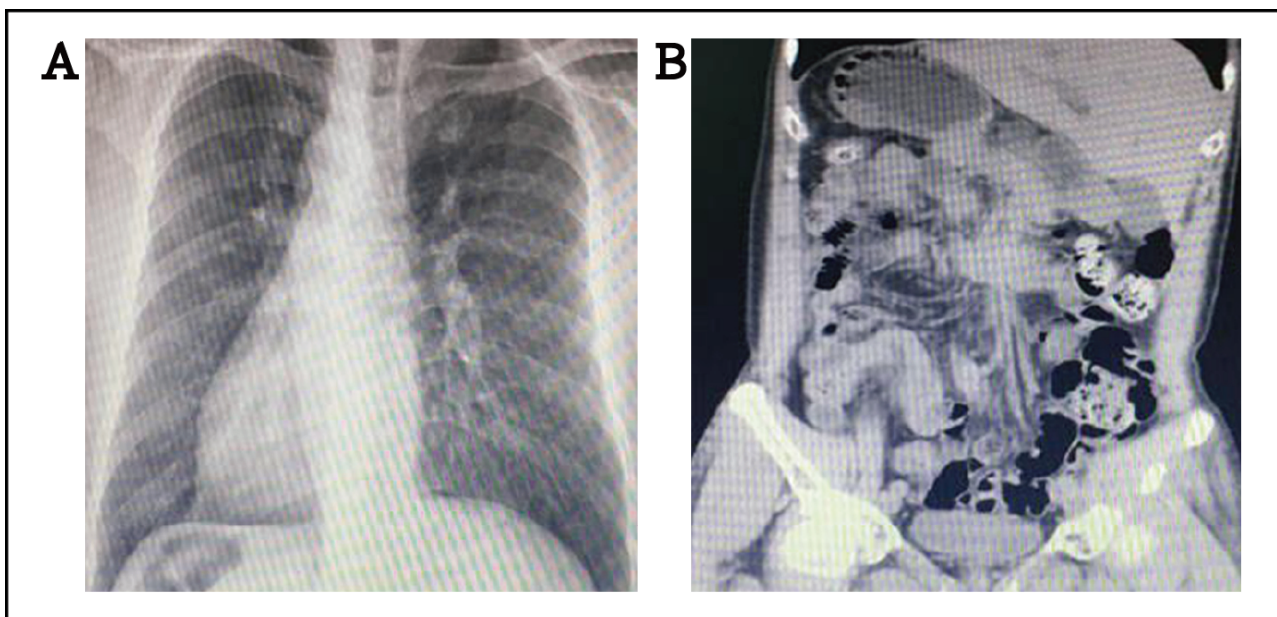
Considering the patient's previous history, coronary angiography was performed. The patient was fully informed of the risks and benefits prior to our intervention. Cardiac catheterization was performed via the right radial artery. The left coronary artery (LCA) was cannulated with clockwise rotation of the catheter, while taking the right anterior oblique 45° projection position. The catheter was rotated counterclockwise for cannulating the right coronary artery, instead of the usual clockwise approach. During the RCA angiography, the projected position needed to be changed to the left anterior oblique 45° projection position, while the head and foot projection position did not need to change.

\*Corresponding author: **Zhiling He**, Department of Cardiology, Guangdong Provincial Hospital of Chinese Medicine, Dade Road No.111, Guangzhou, Guangdong 510000, China, E-mail: hezhiling2000@163.com

**Wenjie Long**, No. 1 Clinical College, Lingnan Medical Research Center, Guangzhou University of Chinese Medicine, Jichang road No.12, Guangzhou, Guangdong 510000, China

**Xia Wang, Huanlin Wu, Yahui Chen**, Department of Cardiology, Guangdong Provincial Hospital of Chinese Medicine, Dade Road No.111, Guangzhou, Guangdong 510000, China

**Zhongqi Yang**, Department of Geriatrics, Lingnan Medical Research Center, The First Affiliated Hospital of Guangzhou University of Chinese Medicine, Jichang Road No.16, Guangzhou, Guangdong 510000, China

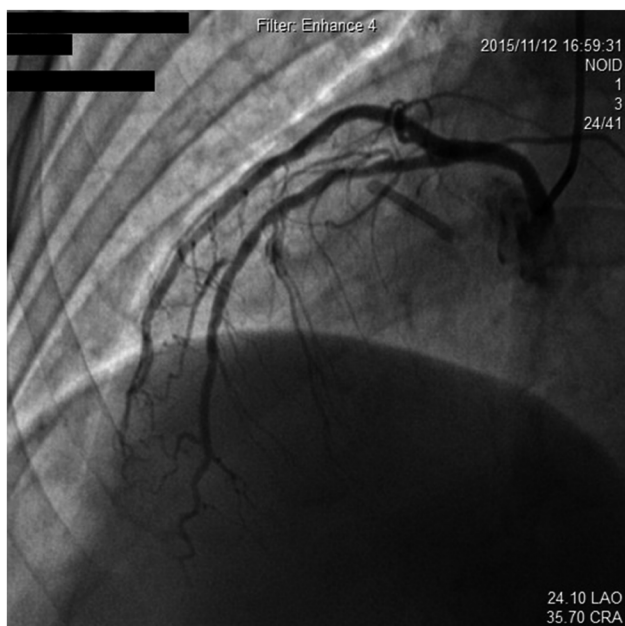


**Figure 1:** (A) Chest X-ray showing dextrocardia with a right aortic arch, right-sided stomach air bubble; (B) coronal CT scan showing the complete situs inversus. CT: computed tomography.

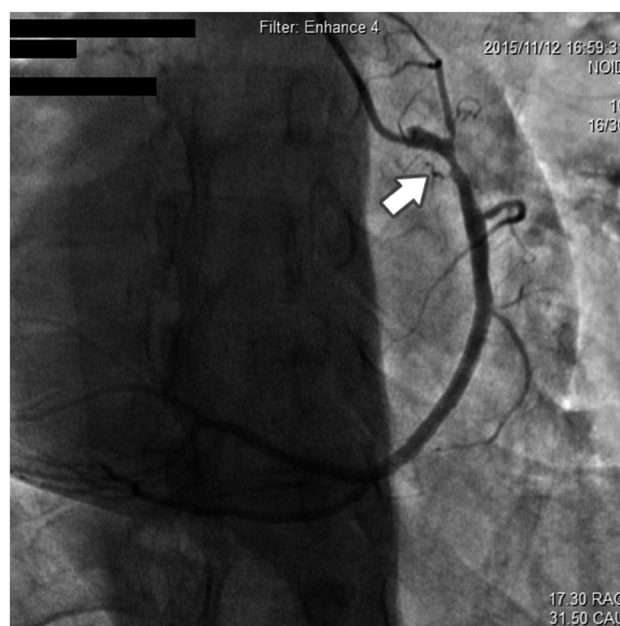
Regarding angiographic findings, no hemodynamically significant stenosis of left anterior descending artery (LAD), left main coronary artery (LM), left circumflex artery (LCX), and antegrade TIMI III flow was found ( Fig. 2). The RCA, as a dominant vessel, was thick with 80% diameter stenosis ( Fig. 3). Assuming this site to be the cause of discomfort, we proceeded with surgical intervention to open the occluded RCA. After balloon pre-dilatation, a Xience V® 3.0 × 23 mm (Abbott Vascular, Santa Clara, CA, USA) drug-eluting stent was

subsequently implanted at the lesion site (Fig.4A), using an inflation pressure of 16 atm for 20s. The intervention was successful, achieving optimal antegrade TIMI III flow without residual stenosis (Fig. 4B). The patient’s recovery post-angioplasty was uneventful.

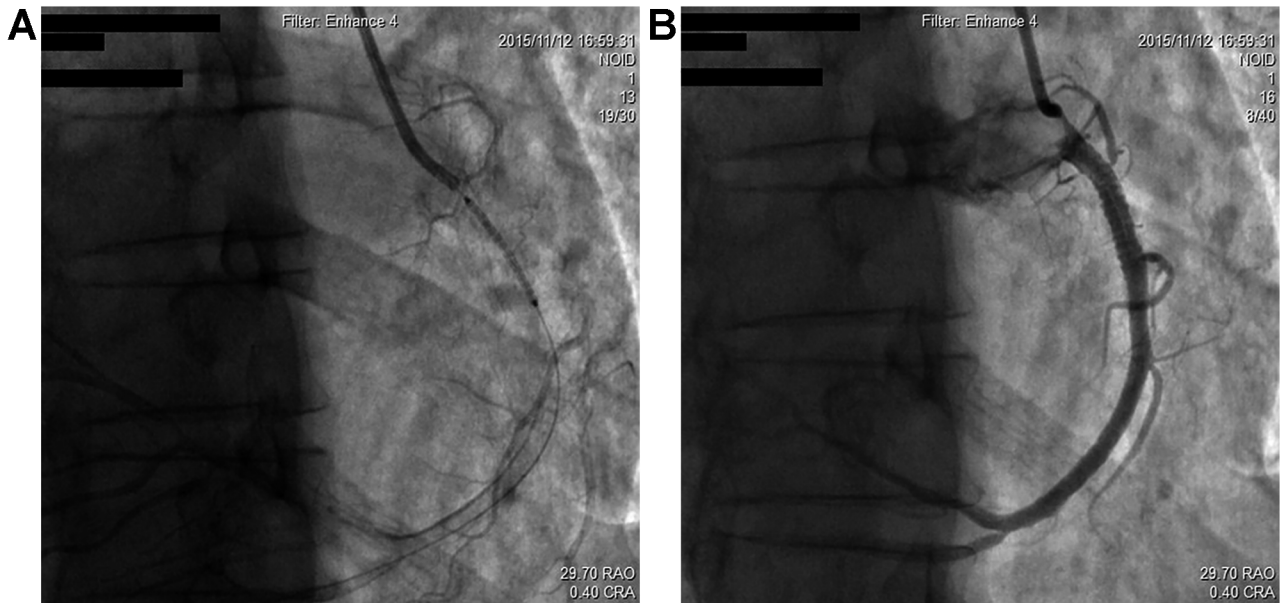
No complications occurred during hospitalization, and the patient received dual antiplatelet therapy (DAPT) with aspirin and clopidogrel for at least a year. He remained free of the symptoms of chest tightness and shortness of breath, and was well at 10 months telephone



**Figure 2:** Coronary angiography showing no lesion in LAD.



**Figure 3:** RCA showing nearly 80% of proximal segment stenosis.



**Figure 4:** A drug-eluting stent was subsequently implanted at the lesion site and the intervention achieved optimal antegrade TIMI III flow without residual stenosis.

follow-up. This case report was approved by the Ethics Committee of our institution. Informed consent has been obtained from all individuals included in this study.

### 3 Discussion

Dextrocardia, usually describing the localization of the heart mainly in the right chest with the cardiac long axis directing to the right and inferiorly, occurs rarely with a frequency of 1/10 000 in the general population [4]. Although patients with dextrocardia constitute a minor portion of the general population, the incidence of coronary artery disease in this setting is likely similar to that in the general population [5]. Coronary angiography for dextrocardia was first reported in 1974 in a patient who underwent left ventricular aneurysmectomy [6]. Coronary artery bypass surgery in a patient with dextrocardia was described in 1982 [7]. Percutaneous coronary intervention in dextrocardia with situs inversus was first reported in 1987 [8].

However, published literature about percutaneous intervention in patients with dextrocardias is scarce in public databases, due to the rarity of this condition. The interventional management of such individuals follows the same general rules as for non-dextrocardia patients, but some technical details should be taken into consideration in order to obtain optimal benefits for the patient.

In the case reported here, we performed cardiac catheterization via the radial arterial approach rather than the femoral one, which had no advantage over the radial

arterial approach in this situation [3].

Optimal management could be achieved with the use of standard catheters, but their manipulation must be in the opposite direction, with the JR4 catheter rotated counterclockwise to cannulate the left anatomical RCA.

Mirror images are needed, i.e. equivalent right-sided views to produce the usual left-sided images and vice versa, without changing cranial or caudal angulations. However, some physicians chose to use horizontal (right-to-left) image inversion during image processing, so that the images obtained were effectively normalized [9]. We simply used equivalent right-sided views to produce the usual left-sided images and vice versa. Thus, the cameras in the LAO cranial position yielded a mirror image of the RAO cranial view.

In the case described here, we applied the aforementioned technique for coronary artery imaging, and performed angioplasty for stenosis in the RCA with standard wire, balloons and stent, with a satisfactory angiographic outcome.

In conclusion, the interventional management of dextrocardia patients follows the same general rules as for non-dextrocardia patients, but some technical details, such as the mirror image, different manipulation of the catheter and projection position choices should be taken into consideration to obtain optimal benefits for the patient.

**Acknowledgements:** This work was supported by the Specific Research Fund for TCM Science and Technology of Guangdong Provincial Hospital of Chinese Medicine

(Number: YN2016QL08). We are grateful to Professor Licheng Zhao from Guangzhou University of Chinese Medicine for his inspiring guidance to this work. We also thanks to Miss Jingyi Xu for her help on writing.

**Conflict of interests:** All authors declare that they have no any conflict of interests.

## References

- [1] Perloff J.K., The cardiac malpositions, *Am. J. Cardiol.*, 2011, 108, 1352-1361, DOI: 10.1016/j.amjcard.2011.06.055
- [2] Dhanjal T.S., Davison P., Cotton J.M., Primary percutaneous coronary intervention for acute myocardial infarction in a patient with dextrocardia, *Cardiol J.*, 2009, 16, 168-171
- [3] Macdonald J.E., Gardiner R., Chauhan A., Coronary angioplasty via the radial approach in an individual with dextrocardia, *Int. J. Cardiol.*, 2008, 131, e10-11, DOI: 10.1016/j.ijcard.2007.07.035
- [4] Cakar M.A., Gunduz H., Can Y., Vatan M.B., Percutaneous coronary intervention in a patient with situs inversus and dextrocardia, *Anadolu Kardiyol. Derg.*, 2012, 12, 437-438, DOI: 10.5152/akd.2012.129
- [5] Menozzi M., Guiducci V., Pignatelli G., Giacometti P., Manari A., Coronary stenting using the radial approach in two women with situs viscerum inversus and acute myocardial infarction, *Cardiovasc. Revasc. Med.*, 2012, 13, 128-132, DOI: 10.1016/j.carrev.2010.06.006
- [6] Richardson R.L., Yousufuddin M., Eubanks D.R., Ventricular aneurysm, arrhythmia and open heart operation in a patient with dextrocardia, *Am. Surg.*, 1974, 40, 666-669
- [7] Irvin R.G., Ballenger J.F., Coronary artery bypass surgery in a patient with situs inversus, *Chest*, 1982, 81, 380-381, DOI: 10.1378/chest.81.3.380
- [8] Moreyra A.E., Saviano G.J., Kostis J.B., Percutaneous transluminal coronary angioplasty in situs inversus, *Cathet. Cardiovasc. Diagn.*, 1987, 13, 114-116, DOI: 10.1002/ccd.1810130208
- [9] Yabe Y., Tsukahara R., Percutaneous transluminal coronary angioplasty for culprit lesions in patients with post myocardial infarction angina based on dextrocardia and anomalous coronary arteries. Case reports and methods, *Angiology*, 1995, 46, 431-440, DOI: 10.1177/000331979504600511