



Gastroschisis Following Treatment with High-Dose Methimazole in Pregnancy: A Case Report

Dyah Purnamasari¹ · Susie Setyowati² · Em Yunir¹ · Anandhara Indriani Khumaedi³ · Dante Saksono Harbuwono¹

Published online: 23 May 2019
© The Author(s) 2019

Abstract

Hyperthyroidism in pregnancy is associated with a increased incidence of low birth weight, preterm birth and admission to the neonatal intensive care unit. However, available treatment options are limited. In this report, we present a case of fetal gastroschisis with a history of intrauterine exposure to methimazole. A 37-year-old woman was diagnosed with Grave's disease 3 years before her pregnancy. She had a poor response to propylthiouracil and required high-dose methimazole before her pregnancy. During the first trimester, she received methimazole 120 mg/day. After her 12th week of pregnancy, she received block-and-replace therapy (levothyroxine [LT4] 50 µg/day) because of the risk of hypothyroidism, and the dose of methimazole was downtitrated to 60 mg/day. Fetal ultrasonography showed fetal growth retardation and gastroschisis at gestational week 33. The relationship between the very high doses of methimazole in the first trimester of pregnancy and the incidence of gastroschisis in this patient was not fully understood because evidence of a relationship between the use of antithyroid drugs in the first trimester and congenital abnormalities in the fetus is lacking. Furthermore block-and-replace therapy is not recommended in pregnancy because it requires a higher dose of methimazole. We recommend preconception counseling and early screening of thyroid function. The counseling should include the best timeline for pregnancy and a discussion of the risks and benefits of hyperthyroidism treatment options.

Introduction

The management of hyperthyroidism during pregnancy remains controversial. It is a challenging task for physicians, as it requires in-depth clinical analysis. Clinicians face a dilemma over whether to avoid the detrimental effects of thyrotoxicosis or the unwanted consequences of treatment. Thyrotoxicosis during pregnancy is associated with a higher incidence of low birth weight, preterm birth and admission to the neonatal intensive care unit [1]. Unfortunately, safe and effective treatment options remain limited

Key Points

Block-and-replace therapy is not recommended for the treatment of hyperthyroidism in pregnancy.

Female patients of reproductive age with hyperthyroidism require high-dose antithyroid drugs (ATDs) to achieve euthyroid status. Therefore, it is recommended that patients be counseled for alternative therapies—surgery and radioiodine therapy—before planning a pregnancy.

It is still possible for congenital abnormalities to be caused by methimazole as Naranjo's score shows congenital abnormalities are probably due to an adverse drug reaction. However, most current epidemiological studies remain inconclusive regarding the impact of methimazole use during the first trimester of pregnancy.

✉ Dyah Purnamasari
dyah_p_irawan@yahoo.com

¹ Division of Endocrinology and Metabolism, Department of Internal Medicine, Faculty of Medicine, Universitas Indonesia, Cipto Mangunkusumo National General Hospital, Jakarta, Indonesia

² Department of Internal Medicine, Gatot Subroto Army Hospital, Jakarta, Indonesia

³ Department of Internal Medicine, Faculty of Medicine, Universitas Indonesia, Cipto Mangunkusumo National General Hospital, Jakarta, Indonesia

for this condition. Radioactive iodine therapy is contraindicated for pregnancy, and surgery is limited for certain conditions because of its high morbidity [2]. Antithyroid drugs (ATDs) remain the treatment of choice for managing thyrotoxicosis in pregnancy, but several cautions are recommended, especially during the first trimester. Both methimazole and propylthiouracil are believed to have teratogenic effects, especially when used in early pregnancy. Study by Seo et.al showed that the highest risk of congenital abnormalities is possessed by pregnant women who are treated with a combination of propylthiouracil and methimazole in the early trimester of pregnancy. An increased risk of congenital abnormalities is also related to the successive use of methimazole alone, propylthiouracil alone, and no history of ATD [3]. Meanwhile, another epidemiological study has shown that the use of ATDs in pregnancy does not increase the risk of congenital abnormalities [4]. We present a case of fetal gastroschisis with a history of intrauterine exposure to high-dose methimazole.

Case Presentation

A 37-year-old woman who was 33 weeks pregnant was referred to the Dr. Cipto Mangunkusumo National General Hospital (RSCM) after an ultrasound examination during gestational week 28 was suspicious for fetal gastroschisis. The patient was diagnosed with Graves' disease in 2010 and had been treated with methimazole 120 mg/day, gradually reduced to 20 mg/day. In 2011, the patient discontinued the treatment because her symptoms improved.

In March 2013, the patient started to experience hyperthyroidism symptoms, including palpitations, sweating, and easy fatigue. The patient then received propylthiouracil 900 mg/day. After a month, the therapy was switched to methimazole 90 mg/day because her response to propylthiouracil was poor. In May 2013, laboratory results showed high free thyroxine (FT4) levels of 8.8 ng/L (normal value: 0.70–1.48 ng/dL). Therefore, the methimazole was increased to 120 mg/day. Within a month of this treatment, the patient was confirmed as being 4 weeks pregnant. However, as her symptoms had improved, the patient did not visit the hospital until August 2013, when she was 12 weeks pregnant. In August 2013, laboratory results showed that her FT4 had dropped to 0.11 ng/L. The methimazole was subsequently reduced to 60 mg/day, and she was given additional levothyroxine (LT4) 50 µg/day. The methimazole was reduced to 40 mg/day at gestational week 20 and to 20 mg/day at week 24. Figure 1 shows the treatment history and FT4 values during pregnancy. Clinically, the patient remained in a euthyroid state during the rest of her pregnancy, even though her FT4 level was 2.77 mg/dL before delivery.

During her week-28 antenatal care, an ultrasound detected gastroschisis. The patient was referred to RSCM for further evaluation and treatment. The ultrasound at gestational week 33 confirmed the presence of gastroschisis with restricted fetal growth and nuchal cord. A cesarean section was performed at gestational week 36, followed by placement of a Bogota bag during the first hour after birth. However, the baby died of septic shock after 20 days of intensive care.

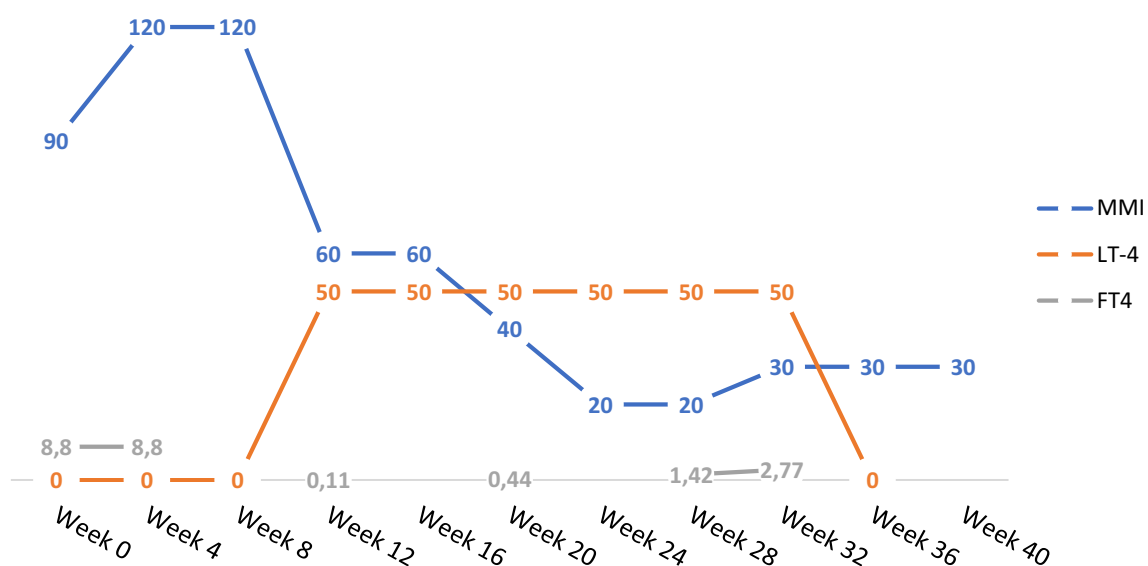


Fig. 1 Timeline history of drug administration. *FT4* free thyroxine, *LT4* levothyroxine, *MMI* methimazole

Discussion

Current Management of Hyperthyroidism in Pregnancy

Graves' disease is the most common cause of hyperthyroidism in pregnancy, followed by other causes of hyperthyroidism such as toxic multinodular goiter, toxic adenoma, trophoblastic tumors, and struma ovarii [5]. Hyperthyroidism and pregnancy are closely related. Untreated hyperthyroidism increases the risk of preeclampsia, heart failure, miscarriage/fetal death, and low birth weight [6]. Meanwhile, hormonal changes and immune regulation during pregnancy may lead to remission in some patients during the late second trimester and the third trimester. In combination, these risks and that of hypothyroidism and/or the teratogenic effect of ATDs on the fetus increases the need for caution in the administration of ATDs during pregnancy [7, 8].

Ideally, management of hyperthyroidism should be initiated before the start of pregnancy during preconception counseling. This should be encouraged to minimize the impact of uncontrolled hyperthyroidism and the risk of teratogenicity and side effects from the use of ATDs during pregnancy [5]. Women with Graves' disease are advised to achieve a euthyroid condition or remission before planning a pregnancy. If pregnancy occurs under hyperthyroid conditions, several important points need to be considered for the management of hyperthyroidism during pregnancy. ATDs are the main choice in the management of hyperthyroidism in pregnancy. The main difference between the management of hyperthyroidism in pregnant and nonpregnant women is the ATD dose and the FT4 target. The ATD dose is lower in pregnant than nonpregnant women to maintain the target FT4 at the upper limit of the normal range. However, the treatment of hyperthyroidism in nonpregnant women requires the optimum ATD dose until target clinical symptoms and FT4 and thyroid-stimulating hormone (TSH) levels are achieved. In pregnancy, the ATD dose should be lowered immediately clinical euthyroid status is achieved and/or the FT4 level has reached the upper normal range, even if TSH levels remain low. Subclinical conditions for hyperthyroidism in pregnant women with Graves' disease often do not require ATD therapy [8].

Block-and-replace therapy is not recommended in pregnancy because it requires increased ATD doses because of the administration of LT4, thus increasing the risk of teratogenicity of ATD on the fetus and hepatotoxicity in the mother [5]. To avoid hypothyroidism during ATD therapy, periodic clinical and laboratory monitoring is recommended every 4–6 weeks during pregnancy or more frequently according to the clinical status of the patient. If hyperthyroid conditions are difficult to control with ATDs or the mother

experiences ATD-related allergies and toxic effects, then the next option is surgery performed in the second trimester of pregnancy [8].

Experts continue to debate the choice of ATD in pregnant women with Graves' disease, and it continues to be investigated. The 2017 American Thyroid Association guidelines recommend propylthiouracil as the first-choice ATD during the first trimester of pregnancy. Unfortunately, there is no available recommendation to continue propylthiouracil or replace with methimazole during the second and third trimesters of pregnancy. The guideline is further supported by epidemiological studies that show a lower incidence of congenital abnormalities with propylthiouracil exposure than with methimazole. Pregnant women with hyperthyroidism who have received methimazole before pregnancy are recommended to switch from methimazole to propylthiouracil during the first trimester [8]. There is no specific recommendation for the second and third trimesters. However, if hyperthyroidism is difficult to control with ATDs, then definitive therapy can be chosen, in the form of surgery during the second trimester [8].

Prevalence and Pathophysiology of Gastroschisis

Gastroschisis is a rare defect in the abdominal wall in which the intestines, liver, and other visceral organs are located outside the abdominal cavity and without a membranous sac. This defect results from a failure of umbilical coelom formation, resulting in rupture and hole formation, most commonly on the right side of the umbilicus [9]. Gastroschisis occurs in 1 in 4000 births or 2–3 per 10,000 live births and is usually associated with young maternal age and a history of alcohol intake and tobacco consumption during pregnancy [9, 10]. Congenital abnormalities due to ATDs (methimazole and propylthiouracil) are reported as percentages of live births with a history of exposure to ATD in the first trimester, making it difficult to compare the numbers. Unfortunately, the underlying mechanism of this teratogenic effect in human embryo has not been established.

Evidence regarding methimazole exposure and gastroschisis is limited, but abdominal wall abnormalities have been reported in fetuses with a history of intrauterine methimazole exposure. Omphalocele and omphalos vitreal duct anomalies were found in 1–14% of babies exposed to methimazole during the first trimester, and this number was significantly higher when compared with propylthiouracil-exposed (0–0.35%) and general population (0.48%) pregnancies [11, 12]. This disorder is often accompanied by other methimazole-related anomalies, such as aplasia cutis congenital [13]. Omphalocele may occur as a result of failure of the lateral fold to fuse in the midline, resulting in a small opening in the midline that allows the intestine to herniate [14]. However, gastroschisis occurs due to amniotic rupture

along the umbilical cord in pars flaccida between gestational weeks 8–11 [15]. Gastroschisis is not related to chromosome malformation and does not result in premature halt of fetal development. The development of gastroschisis is related to a history of substance abuse, such as alcohol, tobacco, and recreational vasoconstrictive agents [14]. To date, only one study has reported the presence of gastroschisis and gestational methimazole exposure [16].

Previous studies have shown the increased risk of teratogenic defects due to methimazole exposure during the first trimester of pregnancy [11, 12]. Andersen et al. [11] reported a 9.12% increase in birth defects due to exposure to methimazole. This percentage is higher than those associated with propylthiouracil, which accounts for a 7.98% increase in birth defects [11]. Yoshihara et al. [12] also reported that intrauterine exposure to methimazole increased the odds of birth defects twofold when compared with controls (odds ratio 2.28; 95% confidence interval 1.54–3.33; $p=0.0002$) regardless of maternal thyroid status. Although study by Andersen et al. [11] and Seo et al. [3] showed a higher risk of birth defect when exposed to ATDs in early pregnancy, epidemiological study by Anderson et al. [4] has not consistently supported these findings. Findings from two large-scale epidemiological studies, in Sweden (2017) [4] and South Korea (2018) [3], mean the impact of ATDs on congenital abnormalities in infants remains controversial. The study in South Korea [3] demonstrated the effects of ATD exposure during the first trimester of pregnancy, showing that exposure to methimazole alone increased the risk of congenital births when compared with propylthiouracil alone, methimazole and propylthiouracil or no ATD exposure history. There was an absolute increase in the prevalence of congenital abnormalities per 1000 live births of 8.81 cases with propylthiouracil, 17.05 cases with methimazole, 16.53 for both methimazole and propylthiouracil, and 1.87 with no ATD exposure [3].

A previous study of 684,340 live births by Andersen et al. [4] showed no significant difference in the incidence of congenital abnormalities in children born to groups of mothers who received ATDs during pregnancy (methimazole 6.8% vs. propylthiouracil 6.4%) and who did not receive ATDs (8.0%). In this study, the incidence of congenital abnormalities in children with a history of mothers receiving two types of ATD (propylthiouracil and methimazole) did not differ from those in children with mothers who had never been exposed to ATDs [4]. In 2013, Andersen et al. [11] found the most common congenital abnormalities after fetal exposure to methimazole or propylthiouracil in the early trimester of pregnancy included neurological disorders; abnormalities of the eyes, face and neck area and digestive, urinary, circulatory and musculoskeletal systems. The study also found that the incidence of congenital abnormalities due to methimazole was higher than that for propylthiouracil.

The congenital abnormalities due to propylthiouracil mostly affected the ears, face and neck area, whereas the use of methimazole in pregnancy was related to abnormalities in the internal organs [11]. Another study also showed that the condition of hyperthyroidism itself increases the risk of congenital abnormalities. The risk of congenital abnormalities due to exposure to ATDs during pregnancy is one of the considerations in determining the type and dose of ATD during pregnancy. In this case, Naranjo's algorithm of adverse drug reaction showed a possible relationship between gastroschisis and methimazole, as shown in Table 1 [17].

High-Dose Methimazole During Pregnancy and Consideration of Surgical Therapy

Management of hyperthyroidism in pregnancy remains challenging because of the detrimental effects of thyrotoxicosis on both the mother and the fetus as well as the potential teratogenic effect of ATDs. Our illustrative patient received high-dose methimazole during the first week of pregnancy, which was then tapered as the pregnancy progressed, which placed the fetus at high risk of developing congenital malformations or drug-induced hypothyroidism.

Generally, methimazole is more effective than other ATDs at achieving an euthyroid state. However, the efficacy of treatment is not the only consideration when treating hyperthyroidism in pregnancy. The management of this patient was complicated because of the need for high-dose methimazole and her suboptimal response to propylthiouracil, even before the start of the pregnancy, making propylthiouracil a less favorable treatment option. Before pregnancy, her thyrotoxicosis did not improve after a month of treatment with propylthiouracil 900 mg. This case shows the need for preconception counseling for female patients of reproductive age with Graves' disease. Patients need to achieve normal thyroid function with a minimum ATD dose and/or remission before pregnancy to avoid the effects of hyperthyroidism and ATD in pregnancy. If hyperthyroidism cannot be controlled with ATDs in early pregnancy, surgery for definitive therapy in the second trimester of pregnancy should be considered [2].

Both methimazole and propylthiouracil have shown increased risks of birth defects, but the congenital defects due to propylthiouracil were less severe than those due to methimazole [13]. Patients with gestational Grave's disease may experience a worsening of symptoms during the first trimester due to the effects of human chorionic gonadotropin [7]. However, this condition is followed by remission in the second and third trimesters, so dose adjustment should be considered at that stage. Hyperthyroidism during pregnancy may contribute to the restricted growth of the fetus observed at week 33. Usually pregnancy correlates with remission status of Grave's disease. Human placenta

Table 1 Naranjo's algorithm of adverse drug reactions

Question	Yes	No	Do not know	Score
1. Are there previous conclusive reports on this reaction?	+1	0	0	0
2. Did the adverse event appear after the suspected drug was administered?	+2	-1	0	2
3. Did the adverse reaction improve when the drug was discontinued or a specific antagonist was administered?	+1	0	0	0
4. Did the adverse event reappear when the drug was readministered?	+2	-1	0	0
5. Are there alternative causes (other than the drug) that could on their own have caused the reaction?	-1	+2	0	-1
6. Did the reaction reappear when a placebo was given?	-1	+1	0	0
7. Was the drug detected in blood (or other fluids) in concentrations known to be toxic?	+1	0	0	0
8. Was the reaction more severe when the dose was increased or less severe when the dose was decreased?	+1	0	0	0
9. Did the patient have a similar reaction to the same or similar drugs in any previous exposure?	+1	0	0	0
10. Was the adverse event confirmed by any objective evidence?	+1	0	0	0
Total score				1

lactogen will decrease the lymphocyte function and attenuate the autoimmune process in pregnancy, especially after the late second trimester. Our patient is a relatively rare and difficult case. During the first trimester, she had high FT4 levels of 8.8 ng/L despite receiving methimazole 90 mg/day and required methimazole during the entire duration of her pregnancy. High FT4 levels despite receiving high-dose methimazole might denote an intense autoimmune process in the mother that was not controlled by oral ATDs or may be influenced by the use of LT4 (block-and-replace therapy), so she was given a higher dose of methimazole. Difficulty maintaining normal thyroid function with low-dose ATD is associated with a risk of disease relapse or ATD failure [8]. Moreover, measurement of thyroid antibody levels was important for this patient since it may predict remission and the risk of disease relapse.

A therapeutic dose of ATD in pregnancy is usually lower than that in nonpregnant women since clinicians need to minimize the risk of fetal hypothyroidism. The initial methimazole dose in nonpregnant hyperthyroid patients is usually 20–40 mg/day, and in pregnancy it is uncommon to initiate methimazole > 30 mg. This patient was receiving methimazole 90 mg/day when she found out she was 4 weeks pregnant. At that time, her FT4 level was still very high at 8.8 ng/dL despite taking methimazole 90 mg/day regularly, thus the doctor increased the methimazole dose to 120 mg/day and asked the patient to check thyroid hormone levels in 1 month (8 weeks of gestation). Unfortunately, this patient only came to the doctor at 12 weeks of gestation, and the FT4 level was very low at 0.11 ng/dL. The methimazole dose this patient was receiving was too high, thus, after taking methimazole 90–120 mg/day in the first trimester, the FT4 level dropped to 0.11 ng/dL at 12 weeks of gestation. At this point, the patient faced two potential risks: hypothyroidism and congenital malformation in the fetus due to the high-dose ATD. After the FT4 level dropped to

0.11 ng/dL, the methimazole dose was tapered from 120 to 60 mg, which is still a high dose. In pregnancy, ATDs should be stopped when the FT4 level reaches the lower limit range and the patient is clinically euthyroid regardless of the TSH level, and the thyroid hormone level should be evaluated within 2–4 weeks. From 12 to < 20 gestational weeks, the patient did not come to the doctor for thyroid hormone evaluation and continued to receive methimazole 60 mg/day, thus the FT4 level remained low (0.44 ng/dL) at 20 weeks of gestation. At that time, the doctor decreased the methimazole dose to 40 mg/day and maintained LT4 at 50 µg. After 1 month, the FT4 level was within the normal range and the methimazole dose was tapered to 20 mg/day until the patient was referred to RSCM.

Besides the detrimental effect of hyperthyroidism and the teratogenicity of ATDs, FT4 levels should be closely monitored in gestational hyperthyroidism to prevent hypothyroidism. The therapeutic target of hyperthyroidism in pregnancy differs from that in nonpregnant women. During pregnancy, the target FT4 is at the upper limit level to minimize the risk of hypothyroidism in the fetus [8]. Hypothyroidism during the first 20 weeks of pregnancy gives rise to a potential risk of miscarriage, fetal distress, preterm delivery, poor vision, and neurological development delay [18, 19]. The higher the ATD dose, the more frequently thyroid function tests should be monitored. This patient received a very high dose of methimazole, but thyroid function tests were not regularly checked. At this point, proper education would have been beneficial to improve the patient's self-awareness and compliance.

In this case, surgery was considered as a definitive therapy for hyperthyroidism because such a high ATD dose was required to achieve remission. However, we did not perform surgery because of the patient's poor compliance and our limited experience of performing surgery in a pregnant patient with hyperthyroidism.

Block-and-Replace Therapy for Hyperthyroidism During Pregnancy

The administration of block-and-replace therapy during the second and third trimester also increases the risk of developing hypothyroidism in pregnancy. Block-and-replace therapy was not recommended in the illustrated case because of the lack of evidence for its safety and efficacy in pregnancy. The fetal thyroid is more sensitive to the effects of ATDs than is the maternal thyroid, but maternal LT4 does not readily permeate the blood–placenta barrier. Thus, the fetus will experience the effects of ATDs and be unable to maintain the thyroxine level by outsourcing the maternal LT4. A study [2] showed that the administration of block-and-replace therapy in pregnancy increases the risk of neonatal goiter and hypothyroidism. Furthermore, block-and-replace therapy was associated with a need for a higher methimazole dosage in pregnancy, thus increasing the risk of congenital malformation due to ATD, such as choanal atresia, esophageal atresia with tracheal fistula, jejunal atresia/stenosis, kidney cysts, omphalocele, and cardiac defects (ventricular and atrial septal defects) in the first trimester [13]. However, a causal relationship between abdominal wall defects and hypothyroidism is not yet clear and might be biased by the presence of ATD teratogenicity. This patient started block-and-replace therapy from 12 weeks of gestation due to her low FT4 level until 36 weeks of gestation, when she came to RSCM.

The doctor found abnormalities in ultrasonography examination at gestational week 28 and referred her to RSCM. The patient came to RSCM at 32 gestational weeks, at which time FT4 had already increased to 2.77 ng/dL. In general, pregnant women with Grave's disease would experience relief of symptoms during the second and third trimesters, at which point approximately 20–30% would be able to cease using thyroid medication [7, 8]. The increased FT4 level at 32 gestational weeks in this patient might be due to the use of LT4 50 µg at that time, which supports that block-and-replace therapy increases the dose requirements of ATD in pregnant women with hyperthyroidism.

Plan for Managing Postpartum Patients

To prevent the effects of hyperthyroidism and ATDs in subsequent pregnancies, patients are advised to undergo definitive therapy before planning their next pregnancy. Treatment options for preconception definitive therapy are radioiodine ablative therapy and surgery. If a woman plans to receive ablative therapy, conception should be postponed until 6 months post-ablation. This should prevent transplacental crossing of thyroid autoantibodies

(TRAb), which can increase the effectiveness of radiation and prevent it affecting the fetus. Although TRAb levels do not increase after surgery, pregnancy should be postponed until a stable euthyroid state is achieved for those patients who are scheduled to undergo surgery. The patient is advised to undergo definitive therapy for Grave's disease before planning the next pregnancy, since hyperthyroidism is difficult to manage with ATDs.

Conclusion

As a recommendation, fertile women with thyrotoxicosis should be counseled regarding the detrimental effects of hyperthyroidism, the therapy choices, and the risk of adverse effects from ATDs. Preconception counseling should review the risks and benefits of all treatment options and the patient's desired timeline for conception. A definitive therapy should be considered in this population as part of preconception counseling. The incidence of congenital malformation in this case might be related to several factors, such as hyperthyroidism, hypothyroidism during ATD therapy, and the use of (a high dose of) methimazole in pregnancy. Previous reports have shown an association between fetal abdominal wall deformities and a history of intrauterine exposure to methimazole in the first trimester. Although the patient received very high doses of methimazole, the causal relationship between methimazole use and gastroschisis cannot be clearly defined in this case since maternal hyperthyroidism itself also carries a high risk of congenital malformation in the fetus. However, further analysis is still needed to confirm the relationship between gastroschisis and the use of methimazole in pregnancy.

Author contributions DP was involved in brainstorming, acquisition of data, drafting of the article and critical revision for intellectual content. AIK and SS were involved in brainstorming, acquisition of data, and drafting of the article. EY and DSH were involved in brainstorming and critical revision for intellectual content. All authors are accountable for the article and to ensure that all questions regarding the accuracy or integrity of the article are investigated and resolved.

Compliance with Ethical Standards

Funding This research did not receive any specific grant from any funding agency in the public, commercial or not-for-profit sector.

Conflict of interest Dyah Purnamasari, Susie Setyowati, Anandhara Indriani Khumaedi, Em Yunir, and Dante Saksano Harbuwono have no conflicts of interest that are directly relevant to the content of this study.

Patient consent Written informed consent was obtained from the next of patient's kin for publication of this case report and any accompany-

ing images. A copy of the written consent may be requested for review from the corresponding author.

Open Access This article is distributed under the terms of the Creative Commons Attribution-NonCommercial 4.0 International License (<http://creativecommons.org/licenses/by-nc/4.0/>), which permits any noncommercial use, distribution, and reproduction in any medium, provided you give appropriate credit to the original author(s) and the source, provide a link to the Creative Commons license, and indicate if changes were made.

References

- Korelitz JJ, McNally DL, Masters MN, Li SX, Xu Y, Rivkees SA. Prevalence of thyrotoxicosis, antithyroid medication use, and complications among pregnant women in the United States. *Thyroid*. 2012;23(6):758–65.
- Ross DS, Burch HB, Cooper DS, Greenlee MC, Laurberg P, Maia AL, et al. 2016 American Thyroid Association guidelines for diagnosis and management of hyperthyroidism and other causes of thyrotoxicosis. *Thyroid*. 2016;26(10):1343–421.
- Seo GH, Kim TH, Chung JH. Antithyroid drugs and congenital malformations a nationwide Korean cohort study. *Ann Intern Med*. 2018;168(6):405–13.
- Andersen SL, Lönn S, Vestergaard P, Törring O. Birth defects after use of antithyroid drugs in early pregnancy: a Swedish nationwide study. *Eur J Endocrinol*. 2017;177(4):369–78.
- Marx H, Amin P, Lazarusi J. Hyperthyroidism and pregnancy. *BMJ*. 2008;336:663–7.
- Cooper D, Laurberg P. Hyperthyroidism in pregnancy. *Lancet Diabetes Endocrinol* [Internet]. 2013;1:238–49. [https://doi.org/10.1016/S2213-8587\(13\)70086-X](https://doi.org/10.1016/S2213-8587(13)70086-X).
- Neale D, Burrow G. Thyroid disease in pregnancy. *Obstet Gynecol Clin N Am*. 2004;31(4):893–905.
- Alexander EK, Pearce EN, Brent GA, Brown RS, Chen H, Dosiou C, et al. 2017 Guidelines of the American Thyroid Association for the diagnosis and management of thyroid disease during pregnancy and postpartum. *Thyroid*. 2017;27:315–89.
- Feldkamp ML, Carey JC, Sadler TW. Research review development of gastroschisis: review of hypotheses, a novel hypothesis, and implications for research. *Am J Med Genet Part A*. 2007;639–52.
- Melov SJ, Tsang I, Cohen R, Badawi N, Walker K, Soundappan SSV, et al. Complexity of gastroschisis predicts outcome: epidemiology and experience in an Australian tertiary centre. *BMC Pregnancy Childbirth*. 2018;18(1):1–9.
- Andersen SL, Olsen J, Wu CS, Laurberg P. Birth defects after early pregnancy use of antithyroid drugs: a Danish nationwide study. *J Clin Endocrinol Metab*. 2013;98(11):4373–81.
- Yoshihara A, Noh JY, Yamaguchi T, Ohye H, Sato S, Sekiya K, et al. Treatment of Graves' disease with antithyroid drugs in the first trimester of pregnancy and the prevalence of congenital malformation. *J Clin Endocrinol Metab*. 2012;97(7):2396–403.
- Laurberg P, Andersen SL. Antithyroid drug use in early pregnancy and birth defects: time windows of relative safety and high risk? *Eur J Endocrinol*. 2014;171(1):R13–20.
- Frolov P, Alali J, Klein MD. Clinical risk factors for gastroschisis and omphalocele in humans: a review of the literature. *Pediatr Surg Int*. 2010;26(12):1135–48.
- Bargy F, Beaudoin S. Comprehensive developmental mechanisms in gastroschisis. *Fetal Diagn Ther*. 2014;36(3):223–30.
- Guignon AM, Mallaret MP, Jouk PS. Carbimazole-related gastroschisis. *Ann Pharmacother*. 2003;37(6):829–31.
- Naranjo CA, Busto U, Sellers EM, Sandor P, Ruiz I, Roberts EA, et al. A method for estimating the probability of adverse drug reactions. *Clin Pharmacol Ther*. 1981;30(2):239–45.
- Su PY, Huang K, Hao JH, Xu YQ, Yan SQ, Li T, et al. Maternal thyroid function in the first twenty weeks of pregnancy and subsequent fetal and infant development: a prospective population-based cohort study in China. *J Clin Endocrinol Metab*. 2011;96(10):3234–41.
- Zhang Y, Wang H, Pan X, Teng W, Shan Z. Patients with subclinical hypothyroidism before 20 weeks of pregnancy have a higher risk of miscarriage: A systematic review and meta-analysis. *PLoS One*. 2017;12(4):1–13.