




Original Article

# Clinical outcomes of procedures combining endovascular embolization with a direct surgical approach in a hybrid operating room for the treatment of refractory dural arteriovenous fistulas

Naoki Kato<sup>1</sup>, Toshihiro Ishibashi<sup>1</sup>, Fumiaki Maruyama<sup>1</sup>, Katharina Otani<sup>2</sup>, Shota Kakizaki<sup>1</sup>, Gota Nagayama<sup>1</sup>, Ayako Ikemura<sup>1</sup>, Shunsuke Hataoka<sup>1</sup>, Issei Kan<sup>1</sup>, Tomonobu Kodama<sup>1</sup>, Yuichi Murayama<sup>1</sup>

<sup>1</sup>Department of Neurosurgery, Jikei University, <sup>2</sup>Department of Advanced Therapies Innovation, Siemens Healthcare K.K., Tokyo, Japan.

E-mail: \*Naoki Kato - nao-kth@jikei.ac.jp; Toshihiro Ishibashi - t-ishibashi@jikei.ac.jp; Fumiaki Maruyama - fumimaru1016@gmail.com; Katharina Otani - katharina.otani@siemens-healthineers.com; Shota Kakizaki - skakizaki0916@gmail.com; Gota Nagayama - gotanagayama88@yahoo.co.jp; Ayako Ikemura - ayako.udgw613@gmail.com; Shunsuke Hataoka - shunsukehataoka@gmail.com; Issei Kan - ikan@jikei.ac.jp; Tomonobu Kodama - kodama@jikei.ac.jp; Yuichi Murayama - ymurayama@jikei.ac.jp



**\*Corresponding author:**

Naoki Kato,  
Department of Neurosurgery,  
Jikei University, Tokyo, Japan.

nao-kth@jikei.ac.jp

Received : 17 May 2021

Accepted : 15 July 2021

Published : 30 August 2021

**DOI**

10.25259/SNI\_486\_2021

**Quick Response Code:**



## ABSTRACT

**Background:** We reviewed the clinical outcomes of a procedure that combines endovascular embolization and a direct surgical approach in a hybrid operating room (OR) for the treatment of refractory dural arteriovenous fistulas (dAVFs).

**Methods:** All patients with intracranial dAVFs who underwent a procedure combining endovascular embolization and direct surgical approach with biplane angiography or a robotic C-arm system in a hybrid OR between February 2004 and June 2020 were considered. Borden grading, occlusion rate, pre-and post-operative modified Rankin Scale (mRS) scores, and complications were retrospectively investigated. The pre-and post-operative mRS scores were compared using the Wilcoxon signed-ranks test.

**Results:** We evaluated 14 arteriovenous fistulas (AVFs) in consecutive 13 patients. Of these, ten AVFs were previously treated with endovascular embolization, ten were located in the transverse-sigmoid sinus, and four in the cortical vein. The Borden grade was II in two AVFs and III in 12 AVFs. Immediate occlusion of the AVF was achieved in 13 AVFs, and gradual occlusion was observed in one case. The median preoperative mRS was 1 (0–3), whereas the median postoperative mRS was 0 (0–1) which indicated marked improvement ( $P = 0.006$ ). Complications including postoperative transient visual disturbance and intraprocedural extravasation were observed in only two cases.

**Conclusion:** The combination of endovascular embolization and direct surgical approach in a hybrid OR could achieve sufficient occlusion of refractory AVFs with acceptable complication rates and improved symptoms.

**Keywords:** Angiography, Arteriovenous fistula, Hybrid operating room, Robotic C-arm

## INTRODUCTION

Dural arteriovenous fistulas (dAVFs) are usually treated with an endovascular approach, including transarterial embolization (TAE) or transvenous embolization (TVE).<sup>[7,11]</sup> In particular, the use of

This is an open-access article distributed under the terms of the Creative Commons Attribution-Non Commercial-Share Alike 4.0 License, which allows others to remix, tweak, and build upon the work non-commercially, as long as the author is credited and the new creations are licensed under the identical terms.

©2021 Published by Scientific Scholar on behalf of Surgical Neurology International

liquid embolic agents has broadened the field of indication for endovascular embolization for the treatment of dAVFs. However, if the arteriovenous fistulas (AVFs) are of non-sinus type, the treatment might be challenging because adequate access to the shunt points is restricted for endovascular embolization. Similarly, it is difficult to treat recurrent AVFs after multiple interventions, because of loss of endovascular access caused by previous embolization. As incomplete obliteration of the dAVFs can cause recurrence, complete occlusion of the shunt points is needed to obtain favorable outcomes.<sup>[2,8,17,20]</sup> Recently, a surgical hybrid operating room (OR) equipped with an angiographic system has become a useful tool for the surgical treatment of vascular diseases because it can accommodate both endovascular embolization and microsurgery simultaneously.<sup>[4,5,12]</sup> To achieve complete occlusion of the AVFs, we developed a combined surgical technique of endovascular embolization and direct surgery in the hybrid OR.<sup>[2,3,9,19,20]</sup> In this case series, we reviewed the clinical outcomes of refractory AVF patients who underwent procedures combining endovascular embolization and direct surgical approach and evaluated the outcome of this method.

## MATERIALS AND METHODS

### Patient population

This study was approved by the institutional review board (IRB) of the university hospital (reference # 29-228 [8844]). Informed consent for treatment and image acquisition in the hybrid OR was obtained from each patient. As per IRB's request, we posted a notice describing the study and gave the patients the opportunity to refuse participation. The IRB waived the requirement for specific informed consent for this study because the data were obtained from routine workflow and investigated retrospectively. We reviewed data for all patients treated for AVFs at our institution between February 2004 and June 2020 and selected those patients treated by a procedure combining endovascular embolization and a direct surgical approach.

### Procedure

All patients who underwent a combined surgical procedure were treated in a hybrid OR equipped with a biplane digital subtraction angiography (DSA) or a robotic C-arm system (Artis dBA, Artis Zee, Artis Q, Artis zeego, and ARTIS pheno; Siemens Healthcare GmbH, Forchheim, Germany) under general anesthesia. The patients were positioned in the supine or prone position, and diagnostic DSA was performed following fixation of the patient's head. After craniotomy on the shunt point or draining vein of the AVF, the dura mater was opened to expose a sufficient area for safe catheterization of the microcatheter. The microcatheter was directly inserted into the draining vein using microsurgical techniques

under a microscope with an integrated indocyanine green (ICG) videoangiography (Zeiss OPMI Pentero 900, Carl Zeiss Meditec, Oberkochen, Germany). A virtual three-dimensional (3D) DSA road map was obtained from the post-processing of DSA performed before craniotomy (Syngo 3D Roadmap, Siemens Healthcare GmbH, Forchheim, Germany) to facilitate the navigation of the microcatheter. Subsequently, the microcatheter was delivered to a vessel neighboring the shunt point using intraoperative live DSA or a virtual 3D DSA road map. After adequate delivery of the microcatheter, detachable coils were placed to occlude the shunt flow. As per the requirement, liquid embolic agents, such as n-butyl-2-cyanoacrylate (NBCA) (Histoacryl; B. Braun - AESCULAP, Tokyo, Japan) or ethylene vinyl alcohol copolymer (EVOH) (Onyx; Medtronic, Minneapolis, Minnesota, USA), were injected under careful inspection through the continuous acquisition of fluoroscopy. After confirmation of the shunt occlusion, the skull and the scalp incisions were closed. Thereafter, postoperative DSA was conducted under general anesthesia before extubation to verify complete occlusion of the dAVE.

For this case series, the disappearance of the AVFs during the procedure was reviewed from the operative records. Data on age, sex, preoperative symptoms, location of the AVF, Borden classification, presence of previous treatment, modified Rankin Scale (mRS), and postoperative course were retrieved from the patients' medical records retrospectively.

### Clinical outcomes

Patients were followed-up using magnetic resonance imaging (MRI) the next day, and subsequently 3, 6, and 12 months post-embolization, followed by every other year. Additionally, DSA was performed 6 or 12 months after treatment. Complete occlusion of the AVF was defined as the disappearance of a high-intensity signal around the treated shunt point by the time of flight on MRI or the disappearance of shunt flow on postoperative DSA. Complications related to treatment were defined as events that occurred during the procedure or during the hospitalization period.

### Statistical analysis

The preoperative and postoperative mRS scores were compared using the Wilcoxon signed-rank test. All analyses were performed using statistical software (StatView version 5.0, SAS institute, North Carolina, USA).

## RESULTS

We reviewed 174 AVF procedures. Of these, 150 procedures were endovascular embolizations, and nine were only direct surgeries. The remaining 14 procedures (13 patients; 10 male; and 3 female) met the inclusion criteria for the combined

procedures and the median age was 61 (range 43–81 years). Of these, 10 AVFs were previously treated 1–5 times (median, 1.0). Preoperative mRS was 0 in two AVFs, 1 in six AVFs, 2 in five AVFs, and 3 in one AVF. Ten AVFs were located in the transverse-sigmoid sinus and four in the cortical vein. The Borden grade was II in two AVFs and III in 12 AVFs. Nine of the 14 craniotomy locations were temporo-occipital. The agents used for embolization were coil, EVOH, NBCA, or a combination of these. Immediate occlusion of the AVF was achieved in 13 AVFs, where a gradual occlusion, 4 months after the treatment, was observed in one AVF. [Table 1] summarizes the AVF characteristics, procedure outcomes, and occlusion results of the AVFs after the treatment.

The mRS scores improved from a median preoperative mRS score of 1 to a median postoperative mRS of 0 ( $P = 0.006$ ) [Figure 1]. Complications associated with the treatment were observed in two patients (two AVFs), one with postoperative transient visual disturbance, and the other with asymptomatic intraprocedural extravasation. The mean follow-up period per AVF was 74.4 months (8–146 months), and recurrence after the combined procedure was not observed.

## ILLUSTRATIVE CASES

### Case 1

A patient with a left convexity dAVF was previously treated with endovascular embolization of the middle meningeal arteries and occipital arteries using EVOH and could not be occluded. During the procedure combining endovascular embolization and direct surgical approach, intraoperative DSA acquisitions were conducted using the robotic C-arm setup. The obtained images indicated that the residual AVF was fed by the middle cerebral artery and draining vein [Figure 2a

and b]. After exposure of the AVF, ICG videoangiography was performed to visualize the AVF structure [Figure 2c and d]. A microvascular clip (MH series; Bearmedic, Tokyo, Japan) was applied to the main draining vein to occlude the drainage root to the superior sagittal sinus [Figure 3a], but intraoperative DSA revealed incomplete occlusion of the AVF due to the remaining drainage root to other cortical veins [Figure 3b]. Subsequently, a microcatheter (Marathon; Medtronic, Minneapolis, MN, USA) was introduced into the main drainage vein with careful venotomy during temporary occlusion of the vein using two microvascular clips. Following insertion, the tip of the microcatheter was advanced to the center of the AVF, and 0.52 ml EVOH was slowly injected using DSA images in order to avoid the outflow of the EVOH to normal cortical veins [Figure 3c and d]. Finally, complete occlusion of the AVF was confirmed by ICG videoangiography and intraoperative DSA [Figure 3e and f].

### Case 2

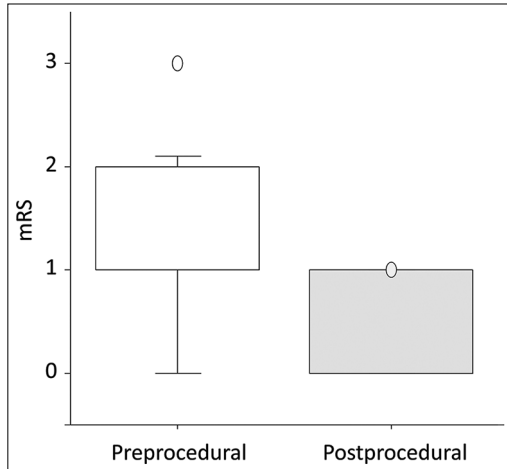
A patient with a dAVF of the right latero-cavernous sinus was previously treated with endovascular embolization in another institute and failed to be occluded [Figure 4a]. Intraoperative DSA was performed under anesthesia to obtain 3D DSA images for the guidance of the virtual 3D DSA road map [Figure 4b and c]. After exposure of the AVF, a distal access catheter (DAC) (TACTICS; Technocrat, Aichi, Japan) was carefully inserted into the main drainage vein [Figure 4d]. Following DAC insertion, a microcatheter (SL-10; Stryker, Fremont, California, USA) was advanced to the venous pouch of the AVF. Eight coils were placed through the microcatheter, using a virtual 3D DSA road map [Figure 4e]. Postoperative magnetic resonance angiography confirmed complete AVF occlusion [Figure 4f].

**Table 1:** AVF and procedure characteristics.

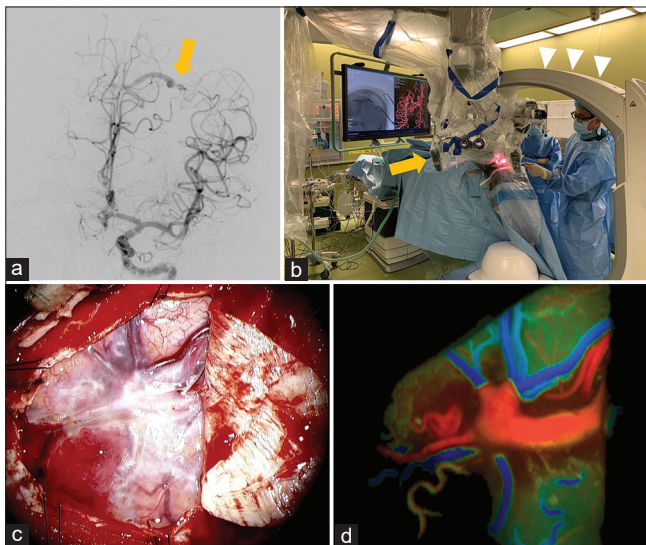
ID	Location	Preoperative symptom	Number of previous EVS	Borden classification	Craniotomy	Embolic agents	Occlusion
1	TS	Syncope	0	III	Temporo-occipital	NBCA+Coil	+
2	TS	Dysesthesia	2	III	Temporo-occipital	Coil	+
3	TS	Epilepsy	0	III	Temporo-occipital	Coil	+
4	TS	Tinnitus	1	III	Temporo-occipital	Coil	+
5	Cortical	Incidental	1	III	Temporo-occipital	Coil	+
6	TS	Tinnitus	1	III	Occipital	Coil	+
7	TS	Exophthalmos	2	II	Temporo-occipital	Coil	+
8	TS	Incidental	0	III	Temporo-occipital	Coil	+
9	TS	Dysesthesia	1	III	Temporo-occipital	Coil	+
10	TS	Tinnitus	0	III	Temporo-occipital	EVOH + coil	+
11	Cortical	Convulsion	2	III	Frontal	EVOH	+
12	TS	Dementia	5	II	Occipital	EVOH	+
13	Cortical	Chemosis	1	III	Fronto-temporal	Coil	±*
14	Cortical	Epilepsy	1	III	Frontal	EVOH	+

AVF: Arteriovenous fistula, TS: transverse-sigmoid sinus; EVS: endovascular surgery; NBCA: n-butyl-2-cyanoacrylate; EVOH: ethylene vinyl alcohol copolymer. \*Occlusion 4 months after treatment





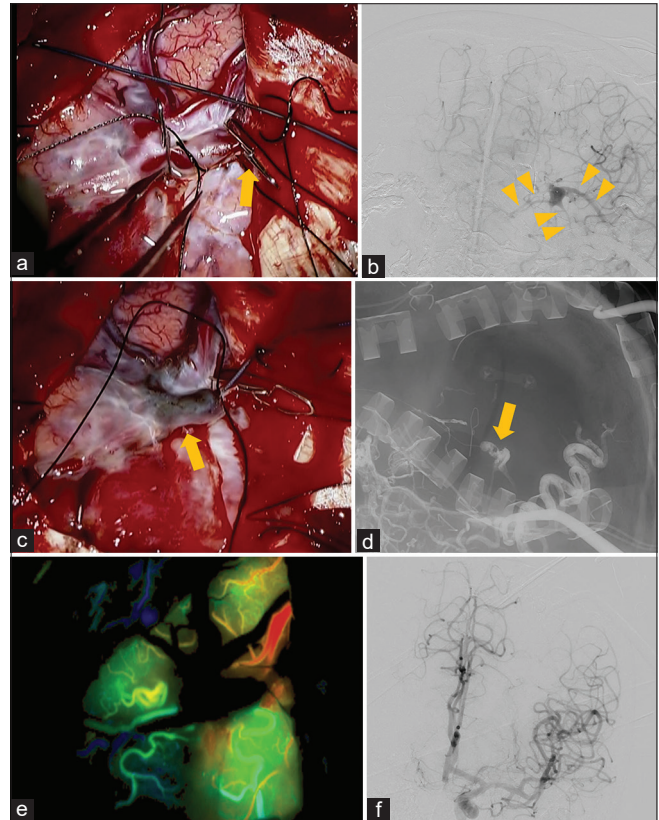
**Figure 1:** The Wilcoxon signed-ranks test of pre- and post-operative mRS. mRS: modified Rankin Scale.



**Figure 2:** Illustrative case 1 demonstrating setup and exposure of arteriovenous fistula (AVF). (a) Digital subtraction angiography showing an AVF fed by the middle cerebral artery and draining vein into the superior sagittal sinus (arrow). (b) A photograph showing the position of a robotic C-arm (arrowheads), and a microscope (arrow). (c) Intraoperative photo of microscope showing the exposed AVF. (d) Color-coded map of indocyanine green videoangiography reveals increased velocity of blood flow in the arterialized draining vein of the AVF.

## DISCUSSION

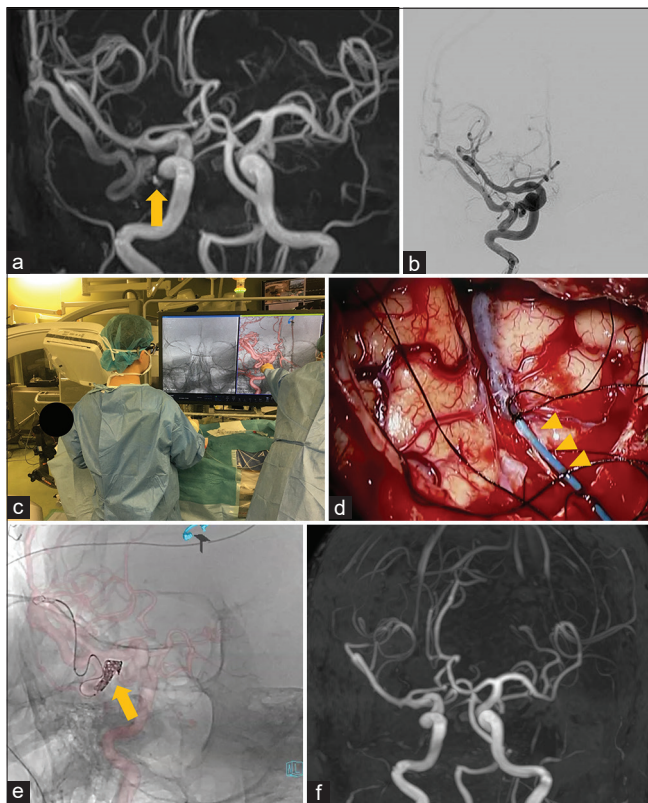
In this case series, we reviewed the clinical outcomes of procedures combining endovascular embolization with a direct surgical approach for the treatment of refractory intracranial dAVFs having complex structures. With the combined procedure, we achieved improvement in all cases and curative treatment in most cases. With the aid of the hybrid OR, both endovascular embolization and



**Figure 3:** Illustrative case 1 demonstrating step-by-step occlusion of the arteriovenous fistula (AVF). (a) Intraoperative photo of microscope showing the draining vein occluded by a microvascular clip (arrow). (b) Intraoperative digital subtraction angiography (DSA) after occlusion of the main draining vein disclosed residual shunts and other multiple draining veins which cannot be recognized on preoperative DSA (arrowheads). (c) The cast of ethylene vinyl alcohol copolymer (EVOH) injected via microcatheter is visible under the microscope (arrow) and (d) intraoperative DSA (arrow). (e) Complete occlusion of the AVF is confirmed by indocyanine green videoangiography after the EVOH injection and (f) repeated intraoperative DSA.

microsurgery were conducted in a single session in the same room. Although complications were observed, the morbidities were transient or asymptomatic. No case of mortality was observed.

At present, dAVFs are majorly treated with endovascular embolization including TVE or TAE.<sup>[7,20]</sup> Especially, the use of EVOH expanded the role of endovascular embolization in dAVF patients and previous studies reports that complete occlusion of AVFs can be achieved in around 80–90% of patients by only endovascular embolization.<sup>[6,10,11]</sup> However, it might be difficult to apply the endovascular approach if the AVF is non-sinus type or does not have a suitable vessel for catheter delivery. The latter may occur when the AVF was previously treated with multiple preceding TAE or TVE.<sup>[20]</sup> In this case series, refractory AVFs or AVFs associated with



**Figure 4:** Illustrative case 2 demonstrating exposure of arteriovenous fistula (AVF) and its step-by-step occlusion. (a) Dural AVF is disclosed by magnetic resonance angiography (MRA) (arrow) and (b) digital subtraction angiography (DSA). (c) After fixation of the patient's head, intraoperative DSA by a robotic C-arm is performed to create virtual three-dimensional (3D) DSA road map for following catheter delivery. (d) After craniotomy, a distal access catheter (DAC) is introduced in an arterialized draining vein (arrowheads). (e) A microcatheter is advanced through the DAC and detachable coils are placed in the venous pouch neighboring the shunt point under the guidance of a virtual 3D DSA road map (arrow). (f) Complete occlusion of the AVF is verified by postoperative MRA.

cortical cerebral vein were the main candidates for the combined procedure because the combined procedures enabled accessing the target vein or sinus as well as shunt points under careful microsurgical technique.<sup>[14]</sup> Use of a DAC inserted in the main drainage root had the important role of providing stable access to the shunt points through the lumen. Then the DAC could work as a guiding catheter which enabled surgeons to control a microcatheter easily under conditions similar to standard endovascular embolization. Moreover, the setup in the hybrid OR provided an advantage of treating the patients not only in the supine position but also in the prone position. With this technique, occlusion rates were considered comparable with those achieved with endovascular embolization only even for AVFs that were recurrent or had complex structures.<sup>[3,6,9,10]</sup>

However, this technique has some drawbacks. Bleeding can occur from abnormal vessels within the skull or skin surrounding the AVFs,<sup>[20]</sup> especially from the cortical veins arterialized by the AVFs and punctures of the vessel. Therefore, during the insertion of a catheter into the target vein, special care of temporary occlusion of the target vessel using microvascular clips (usually used for bypass surgery) is required for safe catheter placement. Other known complications associated with this technique include increased brain edema at the surgical site and postoperative hemorrhage.<sup>[17,20]</sup> Therefore, careful hemostasis during craniotomy is necessary.

In this technique, we used virtual guidance of 3D DSA road map images acquired by a biplane or robotic angiographic C-arm system to evaluate the live images of AVFs.<sup>[13]</sup> This imaging technique was easily included in our workflow and allowed us to detect the appropriate location of target vessels for direct catheter insertion or placement of the coils. In contrast to catheter-directed DSA, the 3D DSA road map function enabled surgeons to recognize the location of shunt points continuously even when the surgical bed or C-arm was moved or rotated.<sup>[13]</sup>

Intraoperative ICG and fluorescein videoangiography are also established modalities to evaluate AVF structure or confirm sufficient occlusion of the shunt points, though they have some shortcomings.<sup>[8,18]</sup> AVFs can only be evaluated on a limited surface in one direction, and ICG videoangiography cannot be performed continuously during embolization of the dAVF. We consider that intraoperative DSA in the hybrid OR can compensate for these points.<sup>[15]</sup> Newer robotic C-arms can facilitate better image guidance during surgery, as they provide a larger field of view and more working space as well as a longer radius of gyration. The latter further helps avoid collision of equipment and patients and enables the easier setting of the surgery.<sup>[1]</sup>

Procedures combining endovascular embolization with a direct surgical approach can only be performed in a hybrid OR, which requires a substantial monetary investment. As the costs of a hybrid OR depend on its utilization rate, it is difficult to assess the cost-effectiveness of isolated procedures.<sup>[16]</sup> Furthermore, the combined procedure described in this work requires medical resources for both endovascular treatment and direct surgery during each procedure. In the short term, this will negatively affect the cost-effectiveness of the proposed approach. However, we believe that long-term cost-effectiveness considerations will be favorable because further retreatment can be avoided if the combined procedure achieved curable occlusion.

Our study had some limitations. Only a few cases from a single center were included in the study. In future, studies with larger numbers of patients are needed to validate this technique.



## CONCLUSION

The combination of craniotomy and endovascular embolization in a hybrid OR resulted in a good occlusion rate of the AVFs, even in cases where the endovascular access was obliterated by previous embolization or the draining vessels were cortical veins. Although the study involved a small patient population, the outcome was favorable, and the complication rate was low. This technique can be an effective modality for the treatment of refractory intracranial AVFs.

## Declaration of patient consent

Institutional Review Board (IRB) permission obtained for the study.

## Financial support and sponsorship

Siemens Healthcare K.K.

## Conflicts of interest

This study was partially supported by a research grant (ID C00221026) from Siemens Healthcare K.K. Katharina Otani is an employee of Siemens Healthcare K.K.

## REFERENCES

- Cheng YF, Chen HC, Ke PC, Hung WH, Cheng CY, Lin CH, *et al.* Image-guided video-assisted thoracoscopic surgery with artis pheno for pulmonary nodule resection. *J Thorac Dis* 2020;12:1342-9.
- Dye JA, Buchanan CC, Gonzalez NR. Integrated open surgical and endovascular embolization treatment of a paracavernous venous plexus fistula: Case report. *J Neurosurg* 2015;122:933-8.
- Endo S, Kuwayama N, Takaku A, Nishijima M. Direct packing of the isolated sinus in patients with dural arteriovenous fistulas of the transverse-sigmoid sinus. *J Neurosurg* 1998;88:449-56.
- Grüter BE, Mendelowitsch I, Diepers M, Remonda L, Fandino J, Marbacher S. Combined endovascular and microsurgical treatment of arteriovenous malformations in the hybrid operating room. *World Neurosurg* 2018;117:e204-14.
- Grüter BE, Strange F, Burn F, Remonda L, Diepers M, Fandino J, *et al.* Hybrid operating room settings for treatment of complex dural arteriovenous fistulas. *World Neurosurg* 2018;120:e932-9.
- Gross BA, Albuquerque FC, Moon K, McDougall CG. Evolution of treatment and a detailed analysis of occlusion, recurrence, and clinical outcomes in an endovascular library of 260 dural arteriovenous fistulas. *J Neurosurg* 2017;126:1884-93.
- Hiramatsu M, Sugiu K, Hishikawa T, Nishihiro S, Kidani N, Takahashi Y, *et al.* Results of 1940 embolizations for dural arteriovenous fistulas: Japanese registry of neuroendovascular therapy (JR-NET3). *J Neurosurg* 2019;28:1-8.
- Kato N, Tanaka T, Suzuki Y, Sakamoto H, Arai T, Hasegawa Y, *et al.* Multistage indocyanine green videoangiography for the convexity dural arteriovenous fistula with angiographically occult pial fistula. *J Stroke Cerebrovasc Dis* 2012;21:918.e1-5.
- Kuwayama N, Kubo M, Yamamoto H, Abdelaal M, Kurimoto M, Hirashima Y, *et al.* Combined surgical and endovascular treatment of high-risk intracranial dural arteriovenous fistulas. *J Clin Neurosci* 2002;9 Suppl 1:11-5.
- Maus V, Drescher F, Goertz L, Weber A, Weber W, Fischer S. Endovascular treatment of intracranial dural arteriovenous fistulas: A german single-center experience. *Cerebrovasc Dis Extra* 2020;10:84-93.
- Moenninghoff C, Pohl E, Deuschl C, Wrede K, Jabbarli R, Radbruch A, *et al.* Outcomes after onyx embolization as primary treatment for cranial dural arteriovenous fistula in the past decade. *Acad Radiol* 2020;27:e123-31.
- Murayama Y, Arakawa H, Ishibashi T, Kawamura D, Ebara M, Irie K, *et al.* Combined surgical and endovascular treatment of complex cerebrovascular diseases in the hybrid operating room. *J Neurointerv Surg* 2013;5:489-93.
- Murayama Y, Irie K, Saguchi T, Ishibashi T, Ebara M, Nagashima H, *et al.* Robotic digital subtraction angiography systems within the hybrid operating room. *Neurosurgery* 2011;68:1427-32; discussion 1433.
- Murayama Y, Saguchi T, Ishibashi T, Ebara M, Takao H, Irie K, *et al.* Endovascular operating suite: Future directions for treating neurovascular disease. *J Neurosurg* 2006;104:925-30.
- Pandey P, Steinberg GK, Westbroek EM, Dodd R, Do HM, Marks MP. Intraoperative angiography for cranial dural arteriovenous fistula. *AJNR Am J Neuroradiol* 2011;32:1091-5.
- Patel S, Lindenberg M, Rovers MM, van Harten WH, Ruers TJM, Poot L, *et al.* Understanding the costs of surgery: A bottom-up cost analysis of both a hybrid operating room and conventional operating room. *Int J Health Policy Manag* 2020;27:1-9.
- Priola SM, Ku JC, Pasarikovski CR, Yang VX, da Costa L. Angio-architecture of complex cranial dural arteriovenous fistulas: A single centre retrospective review of treatment modalities and outcomes. *J Clin Neurosci* 2020;76:87-99.
- Shah KJ, Cohen-Gadol AA. The application of FLOW 800 ICG videoangiography color maps for neurovascular surgery and intraoperative decision making. *World Neurosurg* 2019;122:e186-97.
- Shen SC, Tsuei YS, Chen WH, Shen CC. Hybrid surgery for dural arteriovenous fistula in the neurosurgical hybrid operating suite. *J Neurointerv Surg* 2015;7:e6.
- Sugiyama T, Nakayama N, Ushikoshi S, Kazumata K, Okamoto M, Ito M, *et al.* Complication rate, cure rate, and long-term outcomes of microsurgery for intracranial dural arteriovenous fistulae: A Multicenter series and systematic review. *Neurosurg Rev* 2020;44:435-50.

**How to cite this article:** Kato N, Ishibashi T, Maruyama F, Otani K, Kakizaki S, Nagayama G, *et al.* Clinical outcomes of procedures combining endovascular embolization with a direct surgical approach in a hybrid operating room for the treatment of refractory dural arteriovenous fistulas. *Surg Neurol Int* 2021;12:439.