



Since January 2020 Elsevier has created a COVID-19 resource centre with free information in English and Mandarin on the novel coronavirus COVID-19. The COVID-19 resource centre is hosted on Elsevier Connect, the company's public news and information website.

Elsevier hereby grants permission to make all its COVID-19-related research that is available on the COVID-19 resource centre - including this research content - immediately available in PubMed Central and other publicly funded repositories, such as the WHO COVID database with rights for unrestricted research re-use and analyses in any form or by any means with acknowledgement of the original source. These permissions are granted for free by Elsevier for as long as the COVID-19 resource centre remains active.



Available online at www.sciencedirect.com

ScienceDirect

journal homepage: www.e-jmii.com



Short Communication

Anosmia and olfactory tract neuropathy in a case of COVID-19



Chia-Wen Li ^a, Ling-Shan Syue ^a, Yi-Shan Tsai ^b, Min-Chi Li ^{a,c},
Ching-Lung Lo ^a, Chin-Shiang Tsai ^a, Po-Lin Chen ^{a,c},
Wen-Chien Ko ^{a,c}, Nan-Yao Lee ^{a,c,*}

^a Center for Infection Control and Department of Internal Medicine, National Cheng Kung University Hospital, College of Medicine, National Cheng Kung University, Tainan, Taiwan

^b Radiology, National Cheng Kung University Hospital, College of Medicine, National Cheng Kung University, Tainan, Taiwan

^c Department of Medicine, College of Medicine, National Cheng Kung University, Tainan, Taiwan

Received 28 April 2020; received in revised form 20 May 2020; accepted 22 May 2020

Available online 20 June 2020

KEYWORDS

Anosmia;
Ageusia;
COVID-19

Abstract Coronavirus Disease-19 (COVID-19) has been in a global pandemic currently and relating symptoms were reported variously around the world. We reported a previously healthy man of COVID-19 presenting with anosmia as the obvious symptom with relevant radiological findings on brain magnetic resonance imaging.

Copyright © 2020, Taiwan Society of Microbiology. Published by Elsevier Taiwan LLC. This is an open access article under the CC BY-NC-ND license (<http://creativecommons.org/licenses/by-nc-nd/4.0/>).

In the current pandemic of Coronavirus Disease-19 (COVID-19), it is well known that the patients infected with severe acute respiratory syndrome coronavirus 2 (SARS-CoV-2) may be asymptomatic or have diverse manifestations, mainly respiratory tract or flu-like symptoms. The first confirmed case of severe acute respiratory syndrome coronavirus 2 (SARS-CoV-2) infection in Taiwan was imported from Wuhan, China on January 21, 2020. More concerns on sense

of smell related to COVID-19 were raised since March, 2020 around the world.¹ We describe the first adult with COVID-19 presenting with recent onset of anosmia in Taiwan, who raised the clinicians' attention to the newly recognized symptom of COVID-19.

Case report

A 21-year-old male without past medical history, presented with five-day of loss of smell without other respiratory tract discomfort or fever. He ever visited a local otolaryngology clinic, but the symptom persisted. Prior to his presentation to the hospital, he had visited Frankfurt, Osnabrück,

* Corresponding author. Department of Medicine, College of Medicine, National Cheng Kung University, No. 1, University Road, Tainan, 701. Taiwan.

E-mail address: nanyao@mail.ncku.edu.tw (N.-Y. Lee).

Munster, Berlin, and München of Germany from February 24th to March 07, 2020. Upon his arrival of the quarantine station of the hospital on March 16th, fever up to 38 °C was detected, and chest X-ray (CXR) film showed infiltration over left lower lung near the cardiac apex. Given traveling history and pulmonary infiltration on chest film, he was admitted to the negative-pressure isolation room.

On examination, his oxygen saturation was 99% on ambient air and respiratory rate was 20 breaths per minute. Laboratory examinations showed white blood cell count 6500 per μL (normal 3400–9500 per μL) and lymphocyte count 1554 per μL . The patient received oral oseltamivir and gemifloxacin as empirical therapy for influenza and community-acquired pneumonia. COVID-19 was diagnosed by real-time reverse transcription polymerase chain reaction (RT-PCR) testing that detected SARS-CoV-2 from nasopharyngeal swab. Hydroxychloroquine (200 mg twice per day) was prescribed for seven days (from March 22nd to 29th, 2020), as shown in Table 1. He could smell the food (such as banana and oranges) and the cleansing detergent since March 22nd, 2020 (12 days after the onset of anosmia). Since March 28th, 2020, the RT-PCR test for SARS-CoV-2 was negative in four consecutive nasopharyngeal swabs. He was discharged after 23-day of hospitalization with partial recovery of sense of smell. At the day of discharge, brain magnetic resonance imaging (MRI) was done. The coronal 3D turbo spin echo MRI image disclosed smaller right olfactory bulb (Fig. 1A) and coronary T2-weighted MRI image with fat suppression revealed linear hyperintensities inside bilateral olfactory nerves (Fig. 1B), suggestive of bilateral olfactory neuropathy.

SARS-CoV-2 serology

We retrospectively tested this patient's serum for SARS-CoV IgG/IgM using 2019-nCoV IgG/IgM Rapid Test Cassette (Dynamiker Biotechnology Co., Ltd, Tianjin, China). Tests for serum SARS CoV-2 antibody on March 17 and March 20 showed negative results. The test from serum on March 23

started to show weak positive (13 days after the onset of anosmia), which was also compatible with the date of symptoms in recovery, as shown in Table 1. The following test from serum on April 4th revealed both positive results for IgG and IgM.

Discussion

Currently, the clinical symptoms and signs of COVID-19 were increasingly recognized and have been adapted to diagnostic criteria in many countries.^{2–4} However, in mid-March of 2020, as this case complained such “unusual” symptom and recalled no symptoms of upper respiratory tract infection, the diagnostic RT-PCR was conducted based on his traveling history and pulmonary infiltration on his CXR film. Afterwards, increasing cases of COVID-19 were noted to have anosmia, ageusia, or both in Taiwan, and the reporting criteria of COVID-19 were adopted to include anosmia and ageusia by the Center of Disease Control of Taiwan on March 30, 2020. In a recent multicenter study in Europe,⁵ as high as 85.6% and 88.0% of mild-to-moderate COVID-19 patients reported olfactory and gustatory dysfunction, respectively, if active surveillance was conducted.

The pathogenesis of anosmia and ageusia in the cases of COVID-19 was not well studied. Previous studies reported that decreased volume of the olfactory bulb in the patients with postinfectious olfactory loss might be related to the symptoms severity and the duration of olfactory loss.⁶ A patient with COVID-19 in Paris, France experienced acute loss of olfactory function without nasal obstruction, and was found to have bilateral inflammatory obstruction of olfactory clefts of nasal cavity on computed tomography and MRI.⁷ However, the anomalies of the olfactory bulbs and tracts, which were present in our case, were absent in the French's case. In addition to the radiological findings in central nervous system, the recently recognized olfactory receptor family on human airway smooth muscle cells, which are

Table 1 Clinical course, laboratory findings, and antimicrobial treatment in the case of COVID-19.

	March											April																
	11	12	13	14	15	16	17	18	19	20	21	22	23	24	25	26	27	28	29	30	31	1	2	3	4	5	6	7
Hospital day						1	2	3	4	5	6	7	8	9	10	11	12	13	14	15	16	17	18	19	20	21	22	23
RT-PCR testing of SARS-CoV-2																												
Nasopharyngeal swab						+					+		-	-		+	-		-	-	-		-					
SARS-CoV-IgM							-				-		+															+
SARS-CoV-IgG							-				-		+															+
Blood leukocyte count (μL)						6,500							6,200															
Blood lymphocyte count (μL)						1,554							1,587															
Symptoms/signs																												
Anosmia																												
Rhinorrhea																												
Fever																												
Treatment																												
Oseltamivir																												
Gemifloxacin																												
Hydroxychloroquine																												
Mecobalamin																												

↓Sense of smell started to be improving

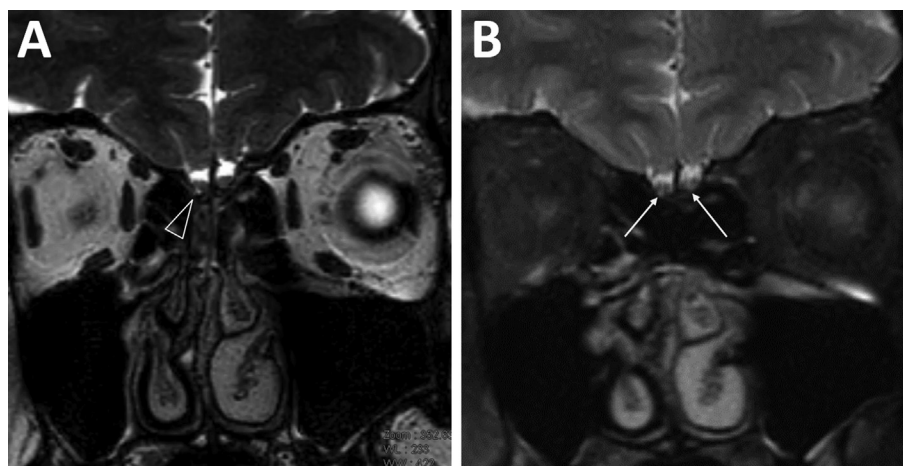


Figure 1. Magnetic resonance imaging of brain at 28 days after the onset of anosmia as the manifestation of COVID-19. The coronal 3D turbo spin echo image disclosed smaller right olfactory bulb (1A, hallow white arrowhead) and coronal 1 mm slice thickness T2-weighted MRI image with fat suppression revealed linear hyperintensities inside bilateral olfactory nerves (1B, white arrows), indicative of bilateral olfactory neuropathy.

impaired by the virus, may play a role of the development of anosmia.⁸ Meanwhile, SARS-CoV-2 belongs to genera Betacoronavirus, same as severe acute respiratory syndrome coronavirus (SARS-CoV) in 2003, which has been reported to cause olfactory neuropathy.⁹ Both virus have many similarities and also have differences in their genomic and phenotypic structure as well.¹⁰ The pathogenesis of SARS-CoV might be possibly applied to study current SARS-CoV-2 in terms of anosmia and ageusia.

A recent survey from China showed that the antibodies against SARS-CoV-2 could be detected in the middle and later stage of the disease.¹¹ The seropositivities of serum IgM and IgG were notably detected from the 9th day and 11th day after symptoms onset, respectively.¹¹ Hence, while real-time PCR assays from respiratory tract specimens currently remain the standard diagnostic tool for COVID-19, the serological testing could be able to serve as a supplemental tool and both testing results should be interpreted simultaneously to provide thorough disease course of COVID-19.¹² Besides, in our patient, we found his recovery from the symptoms consistent with the appearance of serum antibodies to SARS-CoV-2. The similar disease course could also be seen on a previously reported patient, who developed SARS-CoV-2 IgG right after her symptoms resolved.¹³

In conclusion, we reported a previously healthy man of COVID-19 presenting with anosmia as the obvious symptom with possibly relevant radiological findings on brain MRI. With viral clearance in nasopharyngeal swabs, anosmia partially improved. Clinical features and pathogenesis of anosmia and ageusia warrant more studies.

Funding

This study was supported by the grants from National Cheng Kung University Hospital, Tainan, Taiwan (NCKUH-10902066).

Declaration of Competing Interest

The author declares no conflicts of interest.

References

- Walker a, Hopkins C, Surda P. The use of google trends to investigate the loss of smell related searches during COVID-19 outbreak. *Int Forum Allergy Rhinol* 2020. <https://doi.org/10.1102/air.22580>.
- Rodriguez-Morales AJ, Cardona-Ospina JA, Gutierrez-Ocampo E, Villamizar-Mena R, Holguin-Rivera Y, Escalera-Antezana JP, et al. Clinical, laboratory and imaging features of COVID-19: a systematic review and meta-analysis. *Trav Med Infect Dis* 2020;101623. <https://doi.org/10.1016/j.tmaid.2020.101623>.
- Russell B, Moss C, Rigg A, Hopkins C, Papa S, Van Hemelrijck M. Anosmia and ageusia are emerging as symptoms in patients with COVID-19: what does the current evidence say? *Eccancer-medicalscience* 2020;14:ed98. <https://doi.org/10.3332/ecancer.2020.ed98>.
- Vaira LA, Salzano G, Deiana G, De Riu G. Anosmia and ageusia: common findings in COVID-19 patients. *Laryngoscope* 2020. <https://doi.org/10.1002/lary.28692>.
- Lechien JR, Chiesa-Estomba CM, De Siati DR, Horoi M, Le Bon SD, Rodriguez A, et al. Olfactory and gustatory dysfunctions as a clinical presentation of mild-to-moderate forms of the coronavirus disease (COVID-19): a multicenter European study. *Eur Arch Oto-Rhino-Laryngol* 2020. <https://doi.org/10.1007/s00405-020-05965-1>.
- Yao L, Yi X, Pinto JM, Yuan X, Guo Y, Liu Y, et al. Olfactory cortex and olfactory bulb volume alterations in patients with post-infectious olfactory loss. *Brain Imaging Behav* 2018;12:1355–62.
- Eliezer M, Hautefort C, Hamel AL, Verillaud B, Herman P, Houdart E, et al. Sudden and complete olfactory loss function as a possible symptom of COVID-19. *JAMA Otolaryngol Head Neck Surg* 2020. <https://doi.org/10.1001/jamaoto.2020.0832>.
- An SS, Liggett SB. Taste and smell GPCRs in the lung: evidence for a previously unrecognized widespread chemosensory system. *Cell Signal* 2018;41:82–8.

9. Hwang CS. Olfactory neuropathy in severe acute respiratory syndrome: report of a case. *Acta Neurol Taiwan* 2006;15:26–8.
10. Mousavizadeh L, Ghasemi S. Genotype and phenotype of COVID-19: their roles in pathogenesis. *J Microbiol Immunol Infect* 2020. <https://doi.org/10.1016/j.jmii.2020.03.022>.
11. Xiang F, Wang X, He X, Peng Z, Yang B, Zhang J, et al. Antibody detection and dynamic characteristics in patients with COVID-19. *Clin Infect Dis* 2020. <https://doi.org/10.1093/cid/ciaa461>.
12. Tang YW, Schmitz JE, Persing DH, Stratton CW. The laboratory diagnosis of COVID-19 infection: current issues and challenges. *J Clin Microbiol* 2020. <https://doi.org/10.1128/JCM.00512-20>.
13. Lee NY, Li CW, Tsai HP, Chen PL, Syue LS, Li MC, et al. A case of COVID-19 and pneumonia returning from Macau in Taiwan: clinical course and anti-SARS-CoV-2 IgG dynamic. *J Microbiol Immunol Infect* 2020;53(3):485–7. <https://doi.org/10.1016/j.jmii.2020.03.003>.