



Contents lists available at ScienceDirect

International Journal of Surgery Case Reports

journal homepage: www.casereports.com

Pneumatosis cystoides intestinalis presenting as bowel perforation, a rare entity



Philippe Hanna^a, Radwan Kassir^{b,*}, Tarek Debs^c, Bashir Bassile^a, Patrick Saint-Eve^a, Bachir Elias^a

^a Department of General Surgery, CHR Metz-Thionville, Bel-Air hospital, Thionville 57126, France

^b Department of General Surgery, CHU Nord Hospital, Jean Monnet University, Avenue Albert Raimond, 42270 Saint Etienne, France

^c Department of General Surgery, Archet 2 Hospital, University Hospital of Nice, Nice, France

ARTICLE INFO

Article history:

Received 8 August 2015

Received in revised form

23 December 2015

Accepted 25 December 2015

Available online 7 January 2016

Keywords:

Pneumatosis

Bowel perforation

Abdominal pain

Laparotomy

ABSTRACT

INTRODUCTION: Pneumatosis cystoides intestinalis (PCI) is an uncommon condition. This following article describes a case of primary PCI presenting as acute abdomen due to perforation of a small bowel cyst.

PRESENTATION OF CASE: This following article describes the case of an 88 year-old woman admitted at the hospital with peritonitis and consequently operated for a presumed bowel ischemia and perforation. However surgical exploration revealed perforated PCI.

DISCUSSION: The pathophysiology of secondary PCI is poorly understood. Gas produced by Gas-forming bacteria may enter the mucosal barrier due and consequently this gas accumulates within the bowel wall. Also malnutrition can prevent the digestion of carbohydrates, which leads to increased bacterial fermentation, and production of large volumes of gas leading to distention and ischemia and subsequently the submucosal dissection of gas. Colonoscopy is helpful in excluding other colonic lesions and it shows the submucosal cysts that have a typical dual appearance: multiple white small cysts coupled to a sub-atrophic mucosa or larger cysts (up to 3 cm) with a reddened overlying mucosa.

CONCLUSION: The treatment unless complicated should be conservative even in the presence of pneumoperitoneum, after excluding complications.

© 2016 The Authors. Published by Elsevier Ltd. on behalf of IJS Publishing Group Ltd. This is an open access article under the CC BY-NC-ND license (<http://creativecommons.org/licenses/by-nc-nd/4.0/>).

1. Introduction

Pneumatosis cystoides intestinalis (PCI) is an uncommon condition, characterized by the presence of multiple gas-filled cysts within the submucosa or subserosa of the gastrointestinal tract [1], it was first described by Du Vernoy in autopsy specimens in 1730 [2]. It is not a disease by itself, it is a radiological or exploratory entity, and in most cases it is secondary to one of the numerous underlying causes, PCI with no clear underlying cause is called primary or idiopathic [3].

This following article describes a case of primary PCI presenting as acute abdomen due to perforation of a small bowel cyst.

2. Presentation of case

An 88 year-old hypertensive female patient, who has been previously operated from an appendectomy and an open cholecystectomy, presented to the emergency department for acute onset of severe abdominal pain, nausea and vomiting. The patient noted

that she was suffering from watery diarrhea and mild abdominal pain for the last 15 days. Upon examination, the abdomen was distended, with severe rebound tenderness in the left lower quadrant.

Laboratory tests showed leukocytosis, high C reactive protein level, altered renal function. However the liver function test and pancreatic enzymes were normal. A CT scan of the abdomen and pelvis without intravenous contrast was performed and showed signs of intestinal pneumatosis, pneumoperitoneum and mild amount of ascetic fluid (Fig. 1).

Considering the patient physical exam, and the high suspicion of bowel ischemia and perforation, an urgent laparotomy was performed. Numerous gas filled cysts were identified in the small bowel wall involving the jejuno-ileal junction and most of the ileum, compatible with the aspect of pneumatosis cystoides intestinalis, in addition a perforation of one of the cysts was identified at the level of the mid ileum (Fig. 2). Resection of the perforated loop with latero-lateral stapled ileo-ileal anastomosis was performed.

Postoperative course was smooth, the patient resumed bowel function and regular diet soon after the operation. However the patient faces for several days diarrhea that resolved progressively. 9 months post operation she was readmitted to our institution for hip fracture.

* Corresponding author. Fax: +33 4 77 12 70 15.

E-mail address: Radwankassir42@hotmail.fr (R. Kassir).

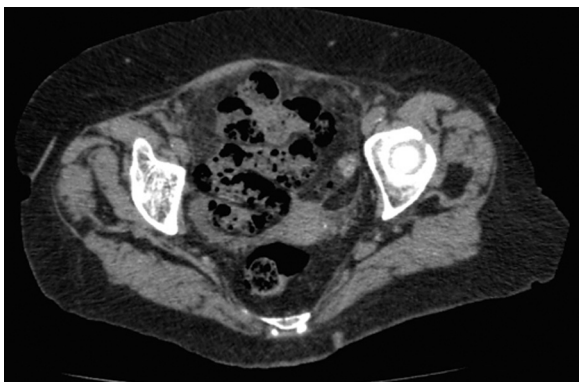


Fig. 1. CT of the abdomen and pelvis showing aspect of intestinal pneumatosis.



Fig. 2. Picture of the operative field showing, (A) multiple cysts of the small bowel, (B) area of bowel resection.

3. Discussion

PCI is most frequently found in the ileum, followed by the colon, and in nearly 20% of cases both in the small and the large intestine [4], however recent studies revealed increasing incidence in the colon due to increase use of colonoscopy and barium enemas [1]. In our case, the patient presented diffuse involvement of the small bowel; however the large bowel was preserved.

PCI may be asymptomatic and discovered incidentally, however the most common symptoms are abdominal pain and diarrhea (53%), followed by abdominal distention, nausea and vomiting, bloody stool, mucus stool and constipation. Nearly 16% of PCI patients has complications such as intestinal obstruction and perforation [5].

PCI can be divided into primary and idiopathic (15%) or secondary (85%). No identifiable underlying or predisposing factor has been identified responsible for the onset of the primary or idiopathic type [1].

The pathophysiology of secondary PCI is poorly understood; there are several theories based on the numerous predisposing factors. In the mechanical theory predisposing factors such as bowel obstruction, gastroenteric tumor, colonoscopy—may result in intestinal wall injury or increased intra-luminal pressure that serves as the driving force for intramural gas accumulation. Chronic pulmonary diseases such as chronic obstructive pulmonary disease, asthma, and interstitial pneumonia result in alveolar rupture that leads to pneumomediastinum that dissects along the aorta and then along the mesenteric vessels to the bowel wall. Gas produced by Gas-forming bacteria may enter the mucosal barrier due and consequently this gas accumulates within the bowel wall. Also malnutrition can prevent the digestion of carbohydrates, which leads to increased bacterial fermentation, and production of large volumes of gas leading to distention and ischemia and subsequently

the submucosal dissection of gas. Finally PCI is also associated with connective tissue disease, hormonal therapy and chemotherapy [5].

In our case we could not identify any specific predisposing factor, so we considered the patient as developing primary PCI, and the patient presented directly with bowel perforation that is an uncommon complication, after having diarrhea for 2 weeks.

CT is the most sensitive tool for diagnosis, in addition to showing the presence of air in the bowel wall, it also show findings that may indicate a potential causes of PCI such as bowel wall thickening, altered contrast mucosal enhancement, dilated bowel, soft tissue stranding, ascites, and the presence of portal air [6].

Colonoscopy is helpful in excluding other colonic lesions and it shows the submucosal cysts that have a typical dual appearance: multiple white small cysts coupled to a sub-atrophic mucosa or larger cysts (up to 3 cm) with a reddened overlying mucosa [7].

The appropriate therapy is related to the underlying cause of PCI. The majority of patients without pronounced symptoms are cured without any treatments. If the symptoms are pronounced, a conservative approach to treatment is allowed, such as gastrointestinal decompression, intestinal “rest”, parenteral nutrition, and fluid and electrolyte supplementation, antibiotics and oxygen [5].

Surgical therapy is a second-line therapy, reserved for complications such as intestinal obstruction and perforation, or cases with precancerous conditions [8]. The surgical decision should not rely only on the radiologic picture of pneumoperitoneum, but should be coupled to the clinical symptoms [9]. In our case the patient was operated due to a presumed bowel ischemia, perforation and localized peritonitis, however perforated PCI was found during the operation and was treated by segmental bowel resection.

4. Conclusion

PCI is a rare entity, however it is a very challenging condition for diagnosis and treatment, especially that it may present with multiple pathologies, the treatment unless complicated should be conservative even in the presence of pneumoperitoneum, after excluding complications.

Conflict of interest

The authors declare no conflict of interest.

Funding

No source of funding for our research.

Consent

Written informed consent was obtained from the patient for publication of this case report and accompanying images.

Author contribution

Philippe Hanna, Radwan Kassir, Tarek Debs: writing.
Bashir Bassile, Patrick Saint-Eve, Bachir Elias: reviewed and revised the paper.

References

- [1] M.S. Morris, A.C. Gee, S.D. Cho, K. Limbaugh, S. Underwood, B. Ham, M.A. Schreiber, Management and outcome of pneumatosis intestinalis, *Am. J. Surg.* 195 (2008) 679–682, Discussion 682–683.
- [2] J.G. Du Vernoy, Aerintestinorum tam sub extima quam intima tunica inclusus: observationes anatomicae: comment, *Acad. Acient. Imp. Petropol.* 5 (1730) 213–225.
- [3] S.D. St Peter, M.A. Abbas, K.A. Kelly, The spectrum of pneumatosis intestinalis, *Arch. Surg.* 138 (2003) 68–75.

- [4] J. Jamart, Pneumatosis cytoides intestinalis. A statistical study of 919 cases, *Acta Hepatogastroenterol. (Stuttg.)* 26 (1979) 419–422.
- [5] L.L. Wu, Yun-Sheng Yang, Yan Dou, Qing-Sen Liu, A systemic analysis of pneumatosis cystoids intestinalis, *World J. Gastroenterol.* 19 (August (30)) (2013) 4973–4978.
- [6] L.M. Ho, E.K. Paulson, W.M. Thompson, Pneumatosis intestinalis in the adult: benign to life-threatening causes, *AJR Am. J. Roentgenol.* 188 (2007) 1604–1613.
- [7] F.I. Luks, M.A. Chung, M.L. Brandt, J. Hertecant, C.C. Roy, H. Blanchard, A.L. Bensoussan, Pneumatosis and pneumoperitoneum in chronic idiopathic intestinal pseudoobstruction, *J. Pediatr. Surg.* 26 (1991) 1384–1386.
- [8] H. Zhang, S.L. Jun, T.V. Brennan, Pneumatosis intestinalis: not always a surgical indication, *Case Rep. Surg.* 2012 (2012) 719713.
- [9] F. Azzaroli, L. Turco, L. Ceroni, S. SartoniGalloni, F. Buonfiglioli, C. Calvanese, G. Mazzella, Pneumatosis cystoides intestinalis, *World J. Gastroenterol.* 17 (November (44)) (2011) 4932–4936.

Open Access

This article is published Open Access at scimedirect.com. It is distributed under the [IJSCR Supplemental terms and conditions](#), which permits unrestricted non commercial use, distribution, and reproduction in any medium, provided the original authors and source are credited.