



NOTE

Internal Medicine

Fibrinous pericarditis secondary to bacterial infection in a cat

Michihito TAGAWA^{1)*}, Chihiro KURASHIMA¹⁾, Genya SHIMBO¹⁾,
Hiroshi OMURA¹⁾, Kenji KOYAMA²⁾, Noriyuki HORIUCHI²⁾,
Yoshiyasu KOBAYASHI²⁾, Keiko KAWAMOTO³⁾ and Kazuro MIYAHARA¹⁾

¹⁾Veterinary Medical Center, Obihiro University of Agriculture and Veterinary Medicine, Obihiro, Hokkaido 080-8555, Japan

²⁾Department of Basic Veterinary Science, Obihiro University of Agriculture and Veterinary Medicine, Obihiro, Hokkaido 080-8555, Japan

³⁾Diagnostic Center for Animal Health and Food Safety, Obihiro University of Agriculture and Veterinary Medicine, Obihiro, Hokkaido 080-8555, Japan

J. Vet. Med. Sci.

79(6): 957–961, 2017

doi: 10.1292/jvms.17-0051

Received: 2 February 2017

Accepted: 24 April 2017

Published online in J-STAGE:

5 May 2017

ABSTRACT. A three-year-old spayed domestic short-haired cat presented for evaluation of weight loss, cardiomegaly and pleural effusion. Echocardiographic examination demonstrated a thickened pericardium with mild pericardial effusion and a large volume of pleural effusion characterized by exudate. Although the cat was treated with antibiotics, the clinical symptoms did not improve. The cat developed dyspnea and died on day 7. Necropsy revealed a large amount of modified transudates ascites, pleural effusion and markedly dilated pericardium. Histopathological examination revealed severe exudation of fibrin and granulation tissue in a thick layer of the epicardium. The cat was diagnosed with fibrinous pericarditis secondary to bacterial infection.

KEY WORDS: cardiomegaly, cat, fibrinous pericarditis, *Moraxella osloensis*

Pericardial disease is not commonly encountered in cats [6]. Previous studies have reported that the overall incidence of pericardial disease in cats ranges from 1 to 2.3% [6, 22], with congestive heart failure secondary to cardiomyopathy being the most common cause in cats [9]. Other causes of pericardial disease in cats include neoplasia, trauma, peritoneopericardial diaphragmatic hernia, feline infectious peritonitis (FIP), disseminated intravascular coagulation, renal failure and infective pericarditis [9, 27, 29]. Infective pericarditis has rarely been reported in cats, and the reported causes of this disease include dental infection, pneumonia, abscess, peritonitis, pyometra or idiopathic [14, 17, 19, 22]. In these cases, the long-term use of appropriate antibiotics could induce clinical remission [14, 19]. However, fibrinous pericarditis, which is well recognized in cattle, has a poor prognosis [4] and has rarely been reported in cats and dogs [20, 23].

In the present study, we described the clinical and histological findings of a feline case of fibrinous pericarditis presumably caused by *Moraxella osloensis*.

A three-year-old spayed domestic short-haired cat, weighing 3.3 kg, presented to a primary care veterinarian with a one-week history of lethargy, anorexia, dyspnea and weight loss. The cat was group fed, liver indoors, and had no history of trauma. Thoracic radiography revealed cardiomegaly and pleural effusion. Due to lack of response to antibiotics, the cat was referred to the Veterinary Medical Center, Obihiro University of Agriculture and Veterinary Medicine (VMC-OUAVM).

At the time of presentation, salient physical examination findings were tachycardia (224 beats per min), tachypnea (32 breaths per min), lethargy and thin body condition (3/9). The remaining physical examination was unremarkable. Initial laboratory data revealed the following abnormalities; anemia (hematocrit, 24.4%; reference limits, 34–51%), neutrophilia ($32.2 \times 10^3/\mu\text{l}$; reference limits, $2.3\text{--}9.8 \times 10^3/\mu\text{l}$), hypoalbuminemia (2.2 g/dl; reference limits, 2.5–3.9 g/dl), hyperglobulinemia (5.2 g/dl; reference limits, 2.6–5.0 g/dl) and low blood urea nitrogen (8 mg/dl; reference limits, 14–28 mg/dl). Feline immunodeficiency virus (FIV) antibody and feline leukemia virus (FeLV) antigen test (IDEXX Laboratories, Westbrook, ME, U.S.A.) were negative. Thoracic radiography revealed an enlarged, globoid cardiac silhouette with a large volume of pleural effusion and dorsal deviation of the trachea (Fig. 1). Echocardiographic examination demonstrated a thickened pericardium with mild pericardial effusion and a large volume of pleural effusion (Fig. 2). Following appropriate aseptic skin preparation, thoracocentesis was performed using a 21-gauge needle, and approximately 100 ml of pleural effusion was removed. Fluid analysis revealed an exudate

*Correspondence to: Tagawa, M., Veterinary Medical Center, Obihiro University of Agriculture and Veterinary Medicine, Inada, Obihiro, Hokkaido 080-8555, Japan. e-mail: mtagawa@obihiro.ac.jp

©2017 The Japanese Society of Veterinary Science



This is an open-access article distributed under the terms of the Creative Commons Attribution Non-Commercial No Derivatives (by-nc-nd) License. (CC-BY-NC-ND 4.0: <https://creativecommons.org/licenses/by-nc-nd/4.0/>)

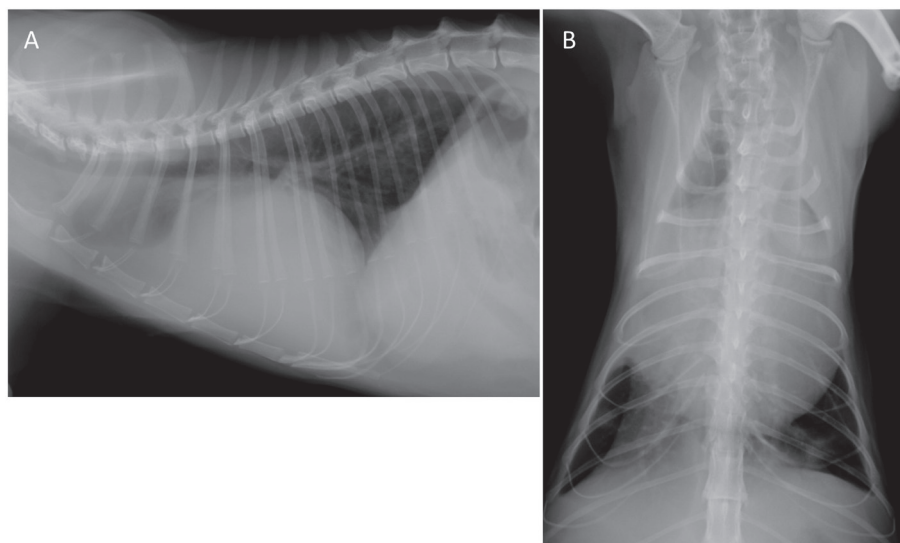


Fig. 1. Lateral (A) and dorsoventral radiographs (B) showing the enlarged, globular cardiac silhouette with pleural effusion and dorsal deviation of the trachea. These radiographs were acquired after the removal of the pleural effusion.

effusion with a total nucleated cell count of 162,000 cells/ μ l, consisting of 30% macrophages and 70% degenerative neutrophils, and a total protein level of 3.8 g/dl. Although the pleural effusion was submitted for aerobic and anaerobic bacterial culture tests, both cultures eventually returned negative. Fine-needle aspiration of the thickened pericardium was performed, and cytologic evaluation indicated a large amount of degenerative neutrophils with fewer macrophages, lymphocytes and fibroblasts. No neoplastic cells or bacteria were identified. FIP virus polymerase chain reaction (PCR) performed using the pleural effusion sample tested negative, and feline coronavirus titer was medium (1:200) (IDEXX Laboratories).

The cat was treated with ampicillin (20 mg/kg IV q12h) and intravenous lactated Ringer's solution (3 mg/kg/hr). However, the clinical symptoms did not improve, and thoracic radiography revealed a recurrence of the pleural effusion on day 6 of hospitalization. Thoracocentesis was performed again, and approximately 100 ml of pleural effusion was removed. The cat was hypothermic (35.9°C), and enrofloxacin (5 mg/kg SC q24h), furosemide (2 mg/kg SC q12h) and benazepril hydrochloride (0.83 mg/kg PO q24h) were added to the treatment regimen. Despite these measures, the cat developed dyspnea and died on day 7.

Necropsy revealed a large volume of modified transudates cloudy abdominal (total nucleated cell count of 3,200 cells/ μ l, and total protein level of 3.5 g/dl) and pleural effusion (total nucleated cell count of 4,400 cells/ μ l, and total protein level of 3.0 g/dl). The heart was encapsulated by a pale-yellow, fibrinous substance (Fig. 3). In the cross section of the heart, the epicardium was covered with an approximately 0.5- to 1.0-cm layer of fibrin (Fig. 4). The fibrinous layer adhered to the epicardium strongly and could not be separated easily. In addition, there was a 1.5-cm abscess adhered to the pericardium and cranial segment of the left cranial lung lobe. Histopathological examination revealed severe exudation of fibrin with neutrophil infiltration around the epicardium. In particular, an organized granulation tissue was noted between the surface of the epicardium and the fibrinous layer (Fig. 5). Bacterial colonies were also seen in the fibrinous layer (Fig. 6A). Special stains revealed that the bacterial colony consisted of small cocci that were negatively stained with Gram's stain (Fig. 6B and 6C). Based on these findings, the cat was diagnosed with fibrinous pericarditis secondary to bacteria. Aerobic and anaerobic bacterial cultures were performed using samples from the abscess, pericardial fibrinous layer, pleural effusion and ascites. The aerobic culture performed using the abscess sample showed the growth of *Moraxella osloensis*, a gram-negative coccus, and the anaerobic culture showed the growth of *Bacteroides pyogenes*, a gram-negative bacillus. *Moraxella osloensis* was also detected in the ascites sample. In addition, *Brevundimonas vesicularis*, a gram-negative bacillus, was detected in the abscess, ascites and pleural effusion samples. Taking into account the

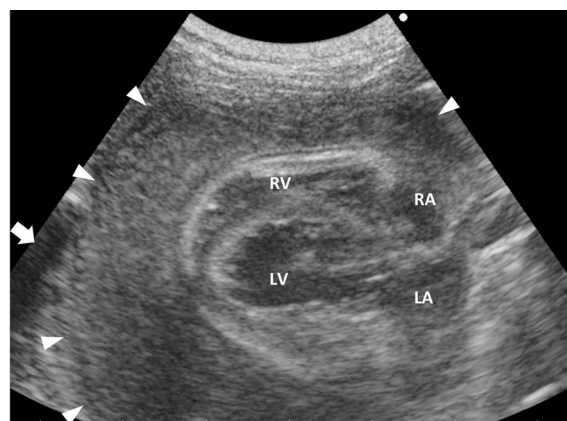


Fig. 2. Echocardiographic examination demonstrates a thickened pericardium (arrowheads) with a hypoechoic pleural effusion (arrow). LA, left atrium; LV, left ventricle; RA, right atrium; RV, right ventricle.

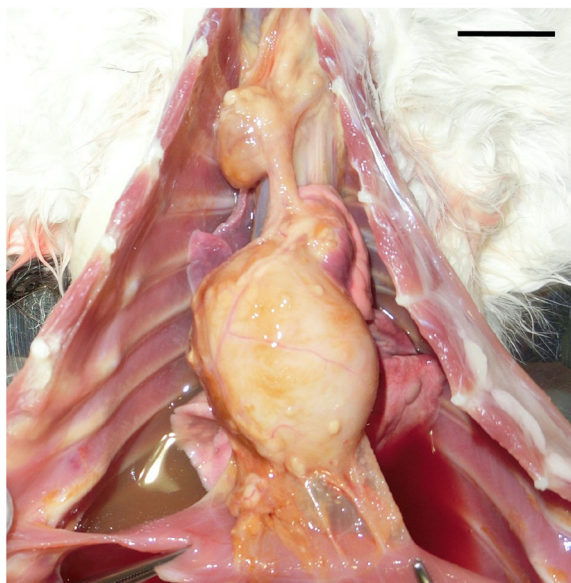


Fig. 3. Gross examination reveals a large amount of opaque, tan ascites and pleural effusion and markedly thickened pericardium. Bar=2 cm.

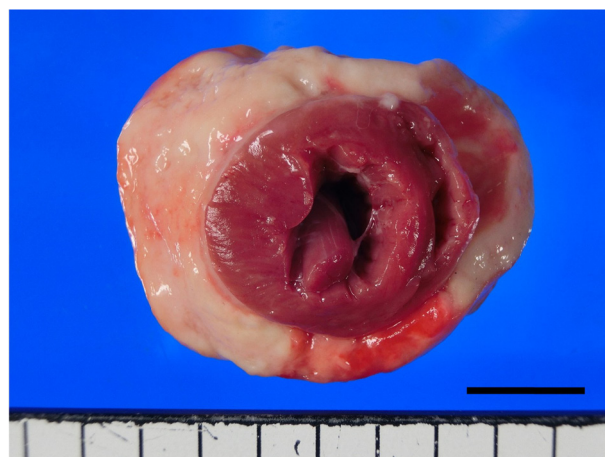


Fig. 4. The epicardium is covered with an approximately 0.5- to 1.0-cm, pale-yellow and thick layer of fibrin. Bar=1 cm.

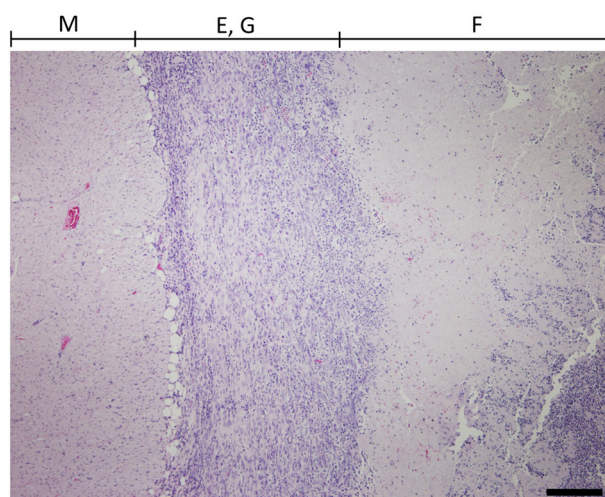


Fig. 5. Histopathological examination of the myocardium (M), thick layer of the epicardium (E), granulation tissue (G) and severe exudation of fibrin (F) with neutrophil infiltration in the case. Bar=200 μ m. Hematoxylin-eosin stain.

morphological characteristics of the bacteria observed in the fibrinous layer, *Moraxella osloensis* was suspected as the causative agent.

A previous report documented the case of cat that developed bacterial pericarditis secondary to bacteremia from a dental procedure, which was caused by a common oropharyngeal microorganism, *Peptostreptococcus* [14]. Another case report described bacterial pericarditis in a cat with pyometra and hematogenous spread of *Escherichia coli* [17]. In addition, *Enterobacteriaceae* and *Staphylococcus* spp. infections resulted in septic pericarditis in another cat [26]. Furthermore, *Pasteurella multocida*, *Actinomyces canis*, and *Fusobacterium* and *Bacteroides* spp. were detected in the pericardial fluid of a cat with septic pericarditis [19]. In the present report, *Moraxella osloensis*, *Bacteroides pyogenes* and *Brevundimonas vesicularis* were detected from the abscess, ascites and pleural effusion. *Moraxella osloensis* is a normal commensal of the upper respiratory tract in humans [8], and *Moraxella* spp. are commonly detected in the healthy feline oral cavity [24].

Bacteroides spp. have been isolated from the oral flora of cats [15], and *Bacteroides pyogenes* has been detected in cat bite wounds in a human patient [16]. *Brevundimonas vesicularis* has been isolated from the external environment [28]. It was reported that *Moraxella osloensis* and *Brevundimonas vesicularis* could induce bacteremia and/or infective endocarditis in immunocompromised human patients [8, 16, 28]. In this study, histopathological examination revealed gram-negative, small cocci in the fibrinous layer. Although *Moraxella osloensis* was not isolated from the bacterial cultures of the pericardium in the present case, *Moraxella osloensis* was suspected as the causative agent based on the morphologic appearance and gram staining of the bacteria in the fibrinous pericardium. The cat reported here was not infected with FIV and FeLV, which are known to cause immunosuppression in cats. On the other hand, a part of the cat's left lung was abscessed and adhered to the pericardium, suggesting a possible respiratory origin of the bacteria. Although the infection course of these pathogens is unidentified, it was suggested that inflammatory processes in adjacent lung parenchyma might produce the abscess and cause the spread to the pericardium.

Previously published reports on bacterial pericarditis in cats have shown that retention of the pericardial fluid is the main constituent, and fibrin exudation is not as severe as seen in the present case. Based on the necropsy and histopathological examination findings, we diagnosed this cat with fibrinous pericarditis due to bacterial infection. Fibrinous pericarditis, which is well recognized in cattle, has rarely been reported in dogs, horses and pigs [1, 4, 5, 23]. In cats, only one case of the fibrinous pericarditis caused by FIP has been reported [20]. Feline coronavirus titer of the case was medium (1:200). Therefore, we suggested that antibody titers measured in the serum be interpreted cautiously, and that medium titers do not have any value in

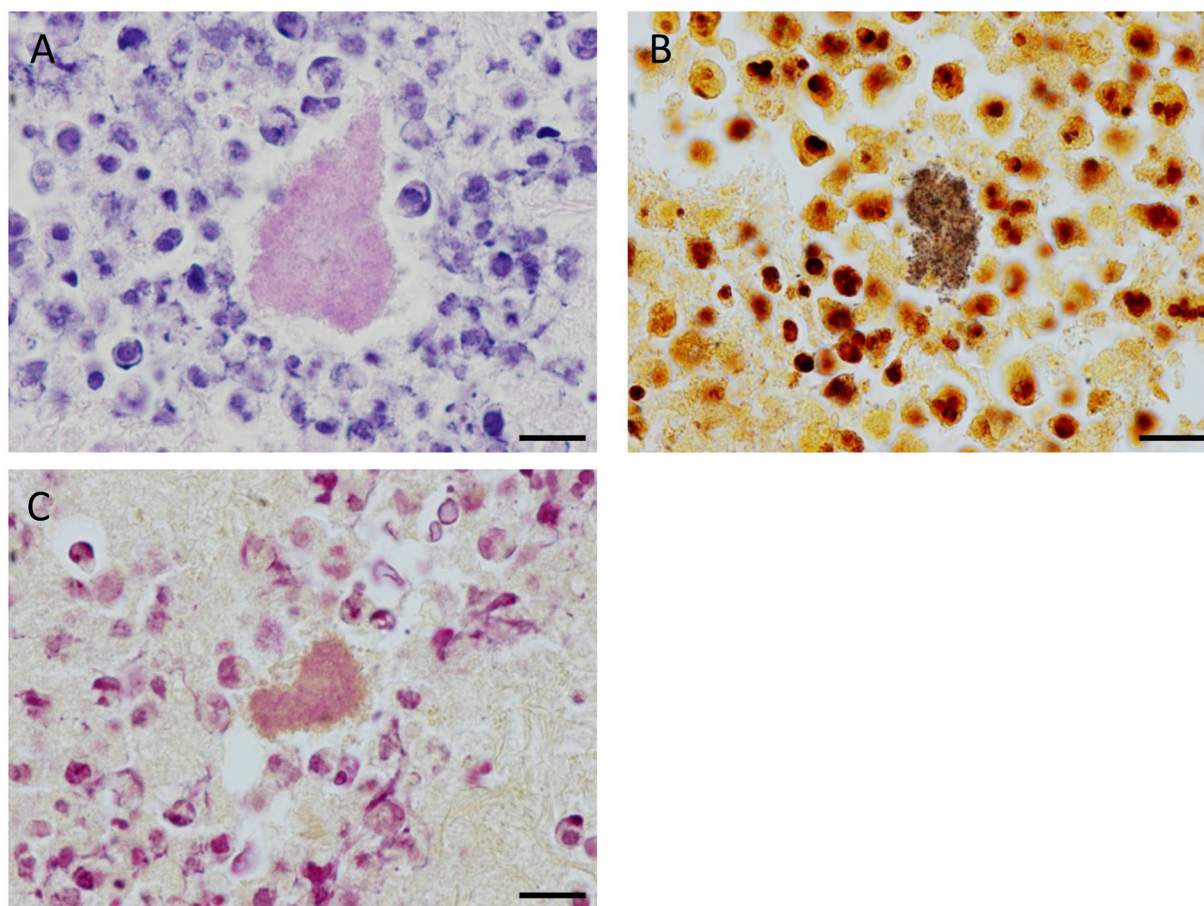


Fig. 6. Bacterial colony observed in the fibrinous layer attached to the epicardium. Small cocci are ambiguously observed. Hematoxylin-eosin stain (A). Same bacterial colony stained with Warthin-Starry stain. Cocci are distinctly observed (B). Same bacterial colony stained with Gram's stain. The cocci are negatively stained (C). Bar=10 μ m.

diagnosing FIP [10]. In addition, many healthy cats exposed to the feline enteric coronavirus have titers ranging from 1:100 to 1:400 [21]. PCR examination for the detection of FIP using a pleural effusion sample was negative. Compared with serological tests, PCR provides the obvious advantage of directly detecting the infection, together with higher sensitivity and specificity in case of cell-free body cavity effusion [7, 10]. Moreover, the histopathological findings of the pericardium in the present case were not identical to the typical findings of FIP infection.

The appropriate therapeutic approach for infective pericarditis in cats is unclear because of the low incidence and small number of published case reports. In general, therapy for infective pericarditis requires pericardiocentesis for drainage of the purulent effusion and the administration of antimicrobial agents [3]. Appropriate antibiotic therapies have reportedly resulted in complete resolution of the pericardial effusion in two cats [14, 19]. In contrast, pericardiectomy is the treatment of choice for dogs and cats with evidence of infectious pericardial disease [2, 17, 25]. In human medicine, pericardiectomy is typically reserved for people who develop constrictive pericarditis [13]. Doppler echocardiography and cardiac catheterization have also been used for the diagnosis of constrictive pericarditis in cats [18, 25]. In this case, aerobic and anaerobic bacterial cultures using pleural effusion samples were performed at the time of presentation to VMC-OUAVM. However, no bacteria were cultured and antibiotic selection based on susceptibility testing could not be performed. Because empirically administered antibiotics could not improve the clinical symptoms in the present case, broad-spectrum antibiotics should have been started immediately. In this case, a large amount of ascites and pleural effusion characterized by modified transudates were seen at necropsy. It was thought that fluid administration converted the exudative effusion to a modified transudate. In addition, severe fibrin exudation and subsequent organization resulted in constrictive pericarditis and induced decompensation and congestive heart failure. It might be necessary to use cardiotoxic agents for the purpose of improvement of the heart failure, and pericardiectomy might be suitable in such cases. Effusive-constrictive pericarditis induced by coccidioidomycosis and several neoplastic pericardial diseases have been reported in dogs [11, 12]. However, these findings were not seen on histological examination in the present case.

In conclusion, fibrinous pericarditis is a rare in cats, and empirical administration of antibiotics without surgical management could be insufficient for the treatment of the fibrinous pericarditis. This report described a rarely case of fibrinous pericarditis in a cat secondary to bacterial infection. Based on the morphological characteristics of the bacteria, *Moraxella osloensis* was suspected

as the causative agent.

REFERENCES

1. Armstrong, S. K., Raidal, S. L. and Hughes, K. J. 2014. Fibrinous pericarditis and pericardial effusion in three neonatal foals. *Aust. Vet. J.* **92**: 392–399. [[Medline](#)] [[CrossRef](#)]
2. Aronson, L. R. and Gregory, C. R. 1995. Infectious pericardial effusion in five dogs. *Vet. Surg.* **24**: 402–407. [[Medline](#)] [[CrossRef](#)]
3. Brook, I. and Frazier, E. H. 1996. Microbiology of acute purulent pericarditis. A 12-year experience in a military hospital. *Arch. Intern. Med.* **156**: 1857–1860. [[Medline](#)] [[CrossRef](#)]
4. Braun, U. 2009. Traumatic pericarditis in cattle: clinical, radiographic and ultrasonographic findings. *Vet. J.* **182**: 176–186. [[Medline](#)] [[CrossRef](#)]
5. Buttenschon, J., Friis, N. F., Aalbaek, B., Jensen, T. K., Iburg, T. and Mousing, J. 1997. Microbiology and pathology of fibrinous pericarditis in Danish slaughter pigs. *Zentralbl. Veterinarmed. A* **44**: 271–280. [[Medline](#)] [[CrossRef](#)]
6. Davidson, B. J., Paling, A. C., Lahmers, S. L. and Nelson, O. L. 2008. Disease association and clinical assessment of feline pericardial effusion. *J. Am. Anim. Hosp. Assoc.* **44**: 5–9. [[Medline](#)] [[CrossRef](#)]
7. Doenges, S. J., Weber, K., Dorsch, R., Fux, R. and Hartmann, K. 2016. Comparison of real-time reverse transcriptase polymerase chain reaction of peripheral blood mononuclear cells, serum and cell-free body cavity effusion for the diagnosis of feline infectious peritonitis. *J. Feline Med. Surg.* pii: 1098612X15625354. [Epub ahead of print].
8. Gagnard, J. C., Hidri, N., Grillon, A., Jesel, L. and Denes, E. 2015. *Moraxella osloensis*, an emerging pathogen of endocarditis in immunocompromised patients? *Swiss Med. Wkly.* **145**: w14185. [[Medline](#)]
9. Hall, D. J., Shofer, F., Meier, C. K. and Sleeper, M. M. 2007. Pericardial effusion in cats: a retrospective study of clinical findings and outcome in 146 cats. *J. Vet. Intern. Med.* **21**: 1002–1007. [[Medline](#)] [[CrossRef](#)]
10. Hartmann, K., Binder, C., Hirschberger, J., Cole, D., Reinacher, M., Schroo, S., Frost, J., Egberink, H., Lutz, H. and Hermanns, W. 2003. Comparison of different tests to diagnose feline infectious peritonitis. *J. Vet. Intern. Med.* **17**: 781–790. [[Medline](#)] [[CrossRef](#)]
11. Heinritz, C. K., Gilson, S. D., Soderstrom, M. J., Robertson, T. A., Gorman, S. C. and Boston, R. C. 2005. Subtotal pericardectomy and epicardial excision for treatment of coccidioidomycosis-induced effusive-constrictive pericarditis in dogs: 17 cases (1999–2003). *J. Am. Vet. Med. Assoc.* **227**: 435–440. [[Medline](#)] [[CrossRef](#)]
12. Kerstetter, K. K., Krahwinkel, D. J. Jr., Millis, D. L. and Hahn, K. 1997. Pericardiectomy in dogs: 22 cases (1978–1994). *J. Am. Vet. Med. Assoc.* **211**: 736–740. [[Medline](#)]
13. Little, W. C. and Freeman, G. L. 2006. Pericardial disease. *Circulation* **113**: 1622–1632. [[Medline](#)] [[CrossRef](#)]
14. Lobetti, R. G. 2007. Anaerobic bacterial pericardial effusion in a cat. *J. S. Afr. Vet. Assoc.* **78**: 175–177. [[Medline](#)] [[CrossRef](#)]
15. Love, D. N., Malik, R. and Norris, J. M. 2000. Bacteriological warfare amongst cats: what have we learned about cat bite infections? *Vet. Microbiol.* **74**: 179–193. [[Medline](#)] [[CrossRef](#)]
16. Madsen, I. R. and Justesen, U. S. 2011. Bacteremia with *Bacteroides pyogenes* after a cat bite. *J. Clin. Microbiol.* **49**: 3092–3093. [[Medline](#)] [[CrossRef](#)]
17. Majoy, S. B., Sharp, C. R., Dickinson, A. E. and Cunningham, S. M. 2013. Septic pericarditis in a cat with pyometra. *J. Vet. Emerg. Crit. Care. (San Antonio)* **23**: 68–76. [[CrossRef](#)]
18. Murphy, L. A., Russell, N. J., Dulake, M. I. and Nakamura, R. K. 2014. Constrictive pericarditis following surgical repair of a peritoneopericardial diaphragmatic hernia in a cat. *J. Feline Med. Surg.* **16**: 708–712. [[Medline](#)] [[CrossRef](#)]
19. Nicole, L. and Katherine, F. S. 2015. Bacterial pericarditis in a cat. *J. Feline Med. Surg. Open Reports.* **1**: 2055116915603077.
20. Oliveira, L. B., Susta, L., Rech, R. R. and Howerth, E. W. 2014. Pathology in practice. Effusive FIP with fibrinous epicarditis in a cat. *J. Am. Vet. Med. Assoc.* **245**: 899–901. [[Medline](#)]
21. Pedersen, N. C. 2014. An update on feline infectious peritonitis: diagnostics and therapeutics. *Vet. J.* **201**: 133–141. [[Medline](#)] [[CrossRef](#)]
22. Rush, J. E., Keene, B. W. and Fox, P. R. 1990. Pericardial disease in the cat: a retrospective evaluation of 66 cases. *J. Am. Anim. Hosp. Assoc.* **26**: 39–46.
23. Stafford Johnson, J. M., Martin, M. W. and Stidworthy, M. F. 2003. Septic fibrinous pericarditis in a cocker spaniel. *J. Small Anim. Pract.* **44**: 117–120. [[Medline](#)] [[CrossRef](#)]
24. Sturgeon, A., Pinder, S. L., Costa, M. C. and Weese, J. S. 2014. Characterization of the oral microbiota of healthy cats using next-generation sequencing. *Vet. J.* **201**: 223–229. [[Medline](#)] [[CrossRef](#)]
25. Thomason, J. D., Radlinsky, M. G., Rapoport, G., Howerth, E. W., Acevedo, K. F., Fallaw, T. L. and Calvert, C. A. 2012. Doppler echocardiographic diagnosis and surgical therapy of constrictive pericarditis in a cat. *J. Feline Med. Surg.* **14**: 276–279. [[Medline](#)] [[CrossRef](#)]
26. Wolff, C. A., Fischetti, A. J. and Bond, B. R. 2010. What is your diagnosis? Pericardial effusion and dilated cardiomyopathy. *J. Am. Vet. Med. Assoc.* **236**: 735–736. [[Medline](#)] [[CrossRef](#)]
27. Wright, K. N., Gompf, R. E. and DeNovo, R. C. Jr. 1999. Peritoneal effusion in cats: 65 cases (1981–1997). *J. Am. Vet. Med. Assoc.* **214**: 375–381. [[Medline](#)]
28. Yang, M. L., Chen, Y. H., Chen, T. C., Lin, W. R., Lin, C. Y. and Lu, P. L. 2006. Case report: infective endocarditis caused by *Brevundimonas vesicularis*. *BMC Infect. Dis.* **6**: 179. [[Medline](#)] [[CrossRef](#)]
29. Zoia, A., Hughes, D. and Connolly, D. J. 2004. Pericardial effusion and cardiac tamponade in a cat with extranodal lymphoma. *J. Small Anim. Pract.* **45**: 467–471. [[Medline](#)] [[CrossRef](#)]