

Regression of Intracranial Meningioma during Treatment with α_1 -Adrenoceptor Blocker

Einar August Hoegestoel¹ Jon Berg-Johnsen^{1,2}

¹Department of Neurosurgery, Oslo University Hospital Rikshospitalet, Oslo, Norway

²Faculty of Medicine, University of Oslo, Oslo, Norway

Address for correspondence Einar August Hoegestoel, MD, Department of Neurosurgery, Oslo University Hospital Rikshospitalet, Oslo, Norway (e-mail: eiaand@ous-hf.no).

J Neurol Surg Rep 2016;77:e62–e65.

Abstract

Background Regression of meningioma has been reported after hemorrhage or hormonal withdrawal. Here, we report a case of an incidentally diagnosed meningioma that regressed in association with α_1 -adrenoceptor antagonist.

Case report A 59-year old male patient with an incidentally diagnosed lateral sphenoid wing meningioma was followed with serial magnetic resonance imaging. The tumor with a maximum diameter of 43 mm showed progressive regression, and after 3 years the size was reduced to 22% of the initial volume. During follow-up the patient was treated with an α_1 -adrenoceptor antagonist (tamsulosin) for benign prostatic hyperplasia. Possible mechanisms are discussed, including our main hypothesis of reduced mitogenic effects through phospholipase C-signal transduction.

Conclusion This is the first report of regression of an incidentally diagnosed meningioma associated with α_1 -adrenoceptor antagonist treatment.

Keywords

- ▶ meningioma
- ▶ intracranial
- ▶ regression
- ▶ α_1 -blocker

Introduction

Meningiomas account for approximately 30% of all primary intracranial tumors, and the majority are benign. The growth rate is variable in these tumors, and after radiographic diagnosis a large proportion of meningiomas frequently plateau in size and either stop growing or grow very slowly.¹ Asymptomatic solitary meningiomas are therefore typically managed with clinical and radiographic follow-up.

The relationship between meningiomas and sex hormones is well known, and a growing number of reports have illustrated regression of meningiomas after hormonal withdrawal.^{2–4} Regression after intratumoral hemorrhage has also been reported,⁵ whereas spontaneous regression is probably extremely rare.⁶

Here, we report regression of a meningioma associated with α_1 -blocker treatment for benign prostatic hyperplasia (BPH), a drug that has previously not been linked directly to regression of meningioma. The patient did not present with, or went through, intratumoral hemorrhage, which would explain the regression.

Case Report

A 59-year-old male patient had experienced slight memory problems and unspecific visual disturbances. Neurological examination revealed no focal deficits. The initial magnetic resonance imaging (MRI) showed a lateral sphenoid wing meningioma on the right side with a maximum diameter of 43 mm, and the estimated tumor volume was 29.9 cm³ (▶Fig. 1A–C). The tumor showed all typical characteristics of a meningioma including extra-axial location, contrast enhancement, and dural tail. There was minimal peritumoral edema. The tumor was considered an incidental finding, the surgery was not recommended and the patient was followed with serial MRI. The first control MRI after 12 months demonstrated that the tumor was reduced by 50% to 14.8 cm³ (▶Fig. 1D–F). On the second MRI after 24 months the tumor had shrunken further to 10.0 cm³ (not shown). On the last MRI after 37 months the tumor was reduced further to 6.7 cm³, that is a reduction of 78% from the initial volume (▶Fig. 1G–I). The tumor volume measured from serial MRI is plotted in ▶Fig. 2.

received
August 31, 2015
accepted after revision
December 3, 2015

DOI <http://dx.doi.org/10.1055/s-0035-1571204>.
ISSN 2193-6358.

© 2016 Georg Thieme Verlag KG
Stuttgart · New York

License terms



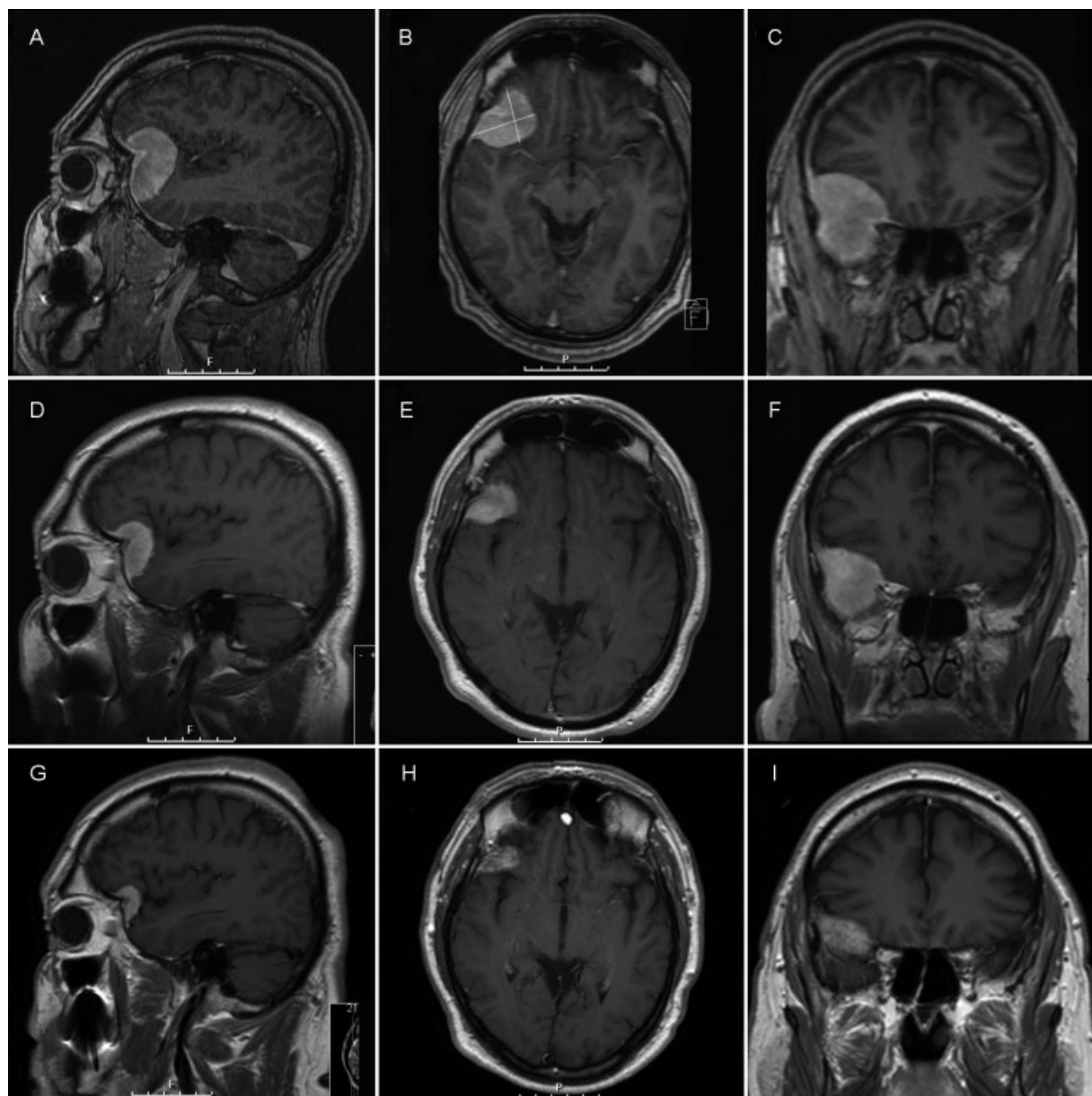


Fig. 1 T1 weighted with gadolinium MRI findings in our patient. (A–C) At diagnosis (October, 2010) showing a right-sided typical sphenoid wing meningioma with a maximum diameter of 43 mm and an estimated tumor volume of 29.9 cm³. (D–F) After 12 months (October, 2011), the tumor volume was reduced to 14.8 cm³. (G–I) After 37 months (November, 2013), the tumor volume was reduced further to 6.7 cm³. MRI, magnetic resonance imaging.

The patient did not receive any steroid medication before or during the follow-up. He had not been treated for any malignant disease. During the follow-up, however, the patient was treated with an α_1 -adrenoceptor antagonist (tamsulosin) for BPH.

Discussion

Data regarding the natural history of untreated meningiomas have been published in several studies, but evidence-based guidelines for treatment of patients with small meningiomas are still lacking. In patients selected for observation, Sughrue et al found that 51% of untreated meningiomas < 2.5 cm in

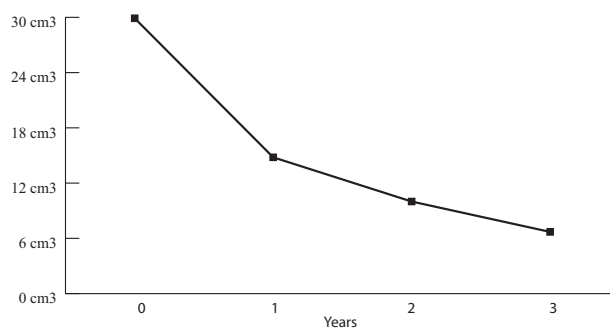


Fig. 2 The tumor volume measured from serial MRI. MRI, magnetic resonance imaging.

largest diameter demonstrate no growth over a follow-up period of 4.6 years, and that an additional 26% grew < 10% per year.⁷ Since most meningiomas are benign tumors, the principal reason to treat meningiomas is to relieve symptoms related to tumor compression of surrounding neurological structures, or to arrest growth in small asymptomatic tumors documented to be growing on serial imaging.

There are several lines of evidence suggesting that progesterone may impact meningioma growth. The fact that intracranial meningiomas arise in women at 2 to 3 times the incidence for men, along with modulation of meningioma biology during pregnancy, suggests a plausible link. Hormone receptor analyses have revealed that, unlike breast cancer, meningiomas are commonly strongly progesterone receptor-positive, but only rarely and weakly estrogen receptor-positive.⁸ Progesterone receptors are expressed predominantly in benign meningiomas with low proliferation indices.⁹

Whereas progesterone-agonist treatment may promote growth in meningiomas,^{10,11} treatment with the antiprogesterone receptor agent mifepristone may induce regression.¹²⁻¹⁴ It has been suggested that multiple meningiomas possess more hormonal dependency than an isolated meningioma since there is a higher female preponderance (sex ratio 8.8/1 in multiple meningiomas vs. 2-3/1 in solitary meningiomas). Regression of multiple tumors has been observed after cessation of long-term progesterone agonist therapy.⁴

Regression of a meningioma has been reported in an 80-year-old male patient with BPH following change of medication from chlormadinone acetate (a progestin steroid with an antiandrogen and antigonadotropic effect) to naftopidil (α_1 -adrenoceptor antagonist).² The cessation of the progesterone agonist was interpreted as the explanation for the effect on tumor, but in light of the present case report, we propose that the observed regression could as well be due to the introduced α_1 -blocker or a combination of the two drugs.

The α_1 -receptor is a mediator of contraction in smooth muscles, and can be found in skin, sphincters, gastrointestinal tract, nerves, and brain. Stimulation of the receptor regulates growth and proliferation of various cells. α_1 -blockers are used in the treatment of BPH, heart failure, and hypertension. A possible explanation for an induced regression of meningioma by α_1 -blockade could be decreased effect of receptor activation that maintains growth and sustains the size of the tumor.^{15,16} Whether meningiomas express adrenoceptors, however, has not been extensively investigated. The first logical step would therefore be to perform receptor analysis to investigate whether meningiomas express adrenoceptors to any extent or other receptors that may represent targets for designed drug therapy. Biopsies from all patients operated for meningiomas at our hospital are stored and are available for later investigations. Some recent studies show that the α_1 -adrenoceptor antagonist naftopidil induces apoptosis in malignant mesothelioma cells by activating caspase-8 in association with upregulated tumor necrosis factor- α and increased FasL secretion followed by the effector caspase-3.¹⁷ Studies of α_1 -adrenoceptor blockade and tumor treatment

have mainly been done on prostate cancer, renal cell tumors, malignant pleural mesothelioma, and bladder tumors.^{18,19}

Due to the high incidence of meningiomas and the large proportion of small tumors that do not grow, a relatively large group of patients are currently followed for incidental meningiomas without treatment. The encouraging observation in our patient warrants further appropriate evaluation of α_1 -adrenoceptor blockade in a prospective trial with accurate volumetric assessment in a preselected population with incidental meningiomas. Men above the age of 60 would for natural reasons be good candidates, but since α_1 -blockers have a low adverse effect profile a study group should not necessarily be that restricted. We are able to match our national drug registry with the cancer registry and thereby identify eligible patients.

This report of regression of an asymptomatic meningioma associated with α_1 -antagonist treatment is a reminder that treatment of incidental meningiomas must be based on thorough consideration of the patient's medication history, especially in elderly men undergoing endocrine therapy for prostate disease and women treated for uterine cancer. Whereas surgery and occasionally radiation therapy are standard treatment for solitary meningiomas, these treatment modalities are not suitable for meningiomatosis. The prospect of medical treatment is furthermore tempting in multiple meningiomas and recurrent disease, since surgery and radiation often are insufficient.

Conclusion

Although approximately 50% of incidentally diagnosed meningiomas do not grow, genuine spontaneous regression is extremely rare. However, a few cases of regression after progestative hormonal treatment withdrawal have been reported. Furthermore, regression of a meningioma has been reported in a male after changing the medication for BPH from progesterone agonist therapy to α_1 -blocker. We here report regression of a meningioma to 22% of the initial volume after 3 years during treatment with α_1 -adrenoceptor antagonist, indicating an association between the adrenoceptor blocking and the observed regression of the meningioma.

Addendum

After the last MRI (3-years follow-up), α_1 -blocker treatment was discontinued. The patient will be followed with serial MRI. If the meningioma should regrow, we have to consider putting the patient back on α_1 -adrenoceptor blocker or should we alternatively operate the tumor to study its receptor expression?

Note

An abstract of this case history was presented at the Annual Meeting of the Norwegian Neurosurgical Society; October 26, 2014; Norway.

References

- 1 Yoneoka Y, Fujii Y, Tanaka R. Growth of incidental meningiomas. *Acta Neurochir (Wien)* 2000;142(5):507–511
- 2 Shimizu J, Matsumoto M, Yamazaki E, Yasue M. Spontaneous regression of an asymptomatic meningioma associated with discontinuation of progesterone agonist administration. *Neurol Med Chir (Tokyo)* 2008;48(5):227–230
- 3 Gonçalves AMG, Page P, Domigo V, Méder J-F, Oppenheim C. Abrupt regression of a meningioma after discontinuation of cyproterone treatment. *AJNR Am J Neuroradiol* 2010;31(8):1504–1505
- 4 Vadivelu S, Sharer L, Schulder M. Regression of multiple intracranial meningiomas after cessation of long-term progesterone agonist therapy. *J Neurosurg* 2010;112(5):920–924
- 5 de Almeida JPC, Petteys RJ, Sciubba DM, Gallia GL, Brem H. Regression of intracranial meningioma following intratumoral hemorrhage. *J Clin Neurosci* 2009;16(9):1246–1249
- 6 Hirota K, Fujita T, Akagawa H, Onda H, Kasuya H. Spontaneous regression together with increased calcification of incidental meningioma. *Surg Neurol Int* 2014;5:73
- 7 Sughrue ME, Rutkowski MJ, Aranda D, Barani IJ, McDermott MW, Parsa AT. Treatment decision making based on the published natural history and growth rate of small meningiomas. *J Neurosurg* 2010;113(5):1036–1042
- 8 Wen PY, Quant E, Drappatz J, Beroukheim R, Norden AD. Medical therapies for meningiomas. *J Neurooncol* 2010;99(3):365–378
- 9 Wolfsberger S, Doostkam S, Boecher-Schwarz HG, et al. Progesterone-receptor index in meningiomas: correlation with clinicopathological parameters and review of the literature. *Neurosurg Rev* 2004;27(4):238–245
- 10 Bergoglio MT, Gómez-Balaguer M, Almonacid Folch E, Hurtado Murillo F, Hernández-Mijares A. Symptomatic meningioma induced by cross-sex hormone treatment in a male-to-female transsexual. *Endocrinol Nutr* 2013;60(5):264–267
- 11 Gruber TJ, Fabiano AJ, Deeb G, Lele SB, Fenstermaker RA. Intracranial meningiomas in patients with uterine sarcoma treated with long-term megestrol acetate therapy. *World Neurosurg* 2011;76(5):477.e16–477.e20
- 12 Grunberg SM, Weiss MH, Spitz IM, et al. Treatment of unresectable meningiomas with the antiprogestone agent mifepristone. *J Neurosurg* 1991;74(6):861–866
- 13 Koide SS. Mifepristone. Auxiliary therapeutic use in cancer and related disorders. *J Reprod Med* 1998;43(7):551–560
- 14 Touat M, Lombardi G, Farina P, Kalamarides M, Sanson M. Successful treatment of multiple intracranial meningiomas with the antiprogestone receptor agent mifepristone (RU486). *Acta Neurochir (Wien)* 2014;156(10):1831–1835
- 15 Kyprianou N, Vaughan TB, Michel MC. Apoptosis induction by doxazosin and other quinazoline α_1 -adrenoceptor antagonists: a new mechanism for cancer treatment? *Naunyn Schmiedeberg Arch Pharmacol* 2009;380(6):473–477
- 16 Gotoh A, Nagaya H, Kanno T, Nishizaki T. Antitumor action of $\alpha(1)$ -adrenoceptor blockers on human bladder, prostate and renal cancer cells. *Pharmacology* 2012;90(5–6):242–246
- 17 Masachika E, Kanno T, Nakano T, Gotoh A, Nishizaki T. Naftopidil induces apoptosis in malignant mesothelioma cell lines independently of α_1 -adrenoceptor blocking. *Anticancer Res* 2013;33(3):887–894
- 18 Mikami K, Nagaya H, Gotoh A, et al. Naftopidil is useful for the treatment of malignant pleural mesothelioma. *Pharmacology* 2014;94(3–4):163–169
- 19 Harris AM, Warner BW, Wilson JM, et al. Effect of α_1 -adrenoceptor antagonist exposure on prostate cancer incidence: an observational cohort study. *J Urol* 2007;178(5):2176–2180