



Since January 2020 Elsevier has created a COVID-19 resource centre with free information in English and Mandarin on the novel coronavirus COVID-19. The COVID-19 resource centre is hosted on Elsevier Connect, the company's public news and information website.

Elsevier hereby grants permission to make all its COVID-19-related research that is available on the COVID-19 resource centre - including this research content - immediately available in PubMed Central and other publicly funded repositories, such as the WHO COVID database with rights for unrestricted research re-use and analyses in any form or by any means with acknowledgement of the original source. These permissions are granted for free by Elsevier for as long as the COVID-19 resource centre remains active.



Short Communication

Evidence from two cases of asymptomatic infection with SARS-CoV-2: Are 14 days of isolation sufficient?

Ren Wan^{a,*}, Zhi-Qun Mao^a, Li-Yi He^b, Yue-Chun Hu^b, Wei-Chen^c^a Department of Radiology, Hunan Provincial People's Hospital (The First Affiliate Hospital of Hunan Normal University), Changsha 410005, Hunan Province, China^b Department of Radiology, The Center Hospital of Loudi City, Loudi 417000, Hunan Province, China^c The Academician Workstation of Loudi Central Hospital, Loudi 417000, Hunan Province, China

ARTICLE INFO

Article history:

Received 28 February 2020

Received in revised form 14 March 2020

Accepted 17 March 2020

ABSTRACT

Among 78 laboratory-confirmed cases, we found two asymptomatic infections. One patient was discharged within 14 days after treatment. Another patient was discharged 25 days after treatment, and his RT-PCR test was still positive on the 15th day. We found that there may be virus carriers in the asymptomatic population with an epidemiological contact history. After 14 days of isolation, those with asymptomatic infection may still carry the virus, which means a risk of transmission, presenting a new challenge for the management of home isolation.

© 2020 The Author(s). Published by Elsevier Ltd on behalf of International Society for Infectious Diseases. This is an open access article under the CC BY-NC-ND license (<http://creativecommons.org/licenses/by-nc-nd/4.0/>).

The outbreak and spread of novel coronavirus (SARS-CoV-2) that began in Wuhan, China, has attracted worldwide attention (Li et al., 2020; Lipsitch et al., 2020; Zou et al., 2020). As of 24:00 on February 24, 2020, a total of 77 658 confirmed cases had been reported in China, and 641 742 cases of close contacts had been tracked, including 87 902 cases under medical observation. Most close contacts were still subject to home isolation, especially in Wuhan, the center of the epidemic.

Isolation at home is mainly suitable for people who have been healthy in the past, have no history of underlying diseases, and have mild or no symptoms (WHO, 2020). Considering the incubation period of SARS-CoV-2, it is recommended to home isolate for 14 days. However, it is unclear whether those who do not experience symptoms during their 14 days of isolation continue to carry the virus.

Of the 78 laboratory-confirmed patients collected from multiple centers, we found two asymptomatic infections.

Case 1

On January 22, 2020, a 36-year-old radiology technician performed a chest CT scan on a patient who had returned from Wuhan. A day later, the patient was diagnosed with Covid-19. All the health workers who had been in contact with the patient were

tested via real-time reverse-transcription polymerase chain reaction (RT-PCR), and the 36-year-old radiology technician was shown to be positive. He was immediately isolated on February 7. He stated that he had no symptoms, and his chest CT was negative on admission. Laboratory evaluation showed a myoglobin level of 86.7 ng/ml (reference range, 0–70), an alanine aminotransferase level of 55 U/L (reference range, 0–50), and a uric acid level of 459 μmol/L (reference range, 150–428). During the period of isolation, he underwent two chest radiographs, both of which were negative. Kaletra (lopinavir/ritonavir) was given as antiviral treatment. On February 14 and 16 the results of RT-PCR testing were negative, and he was discharged. None of his close contacts was infected.

Case 2

On January 26, 2020, a 45-year-old woman, following 4-days of fever and cough, was diagnosed with Covid-19 by a local public hospital. She claimed that she had dinner with a business partner from Wuhan 10 days earlier. The local Centre for Disease Control (CDC) performed RT-PCR tests on her close contacts, and the results showed that her 19-year-old son was positive. Her son stated that he had no symptoms and he was immediately isolated on January 27. Laboratory tests, including routine blood tests, erythrocyte sedimentation rate (ESR), C-reactive protein, and three types of myocardial enzyme spectrum were all negative. During isolation, he underwent two chest X-rays, both of which were negative. Kaletra (lopinavir/ritonavir) and ribavirin were given as antiviral treatments. On February 11, the 15th day of isolation, he

* Corresponding author.

E-mail address: wanrenradiology@163.com (R. Wan).

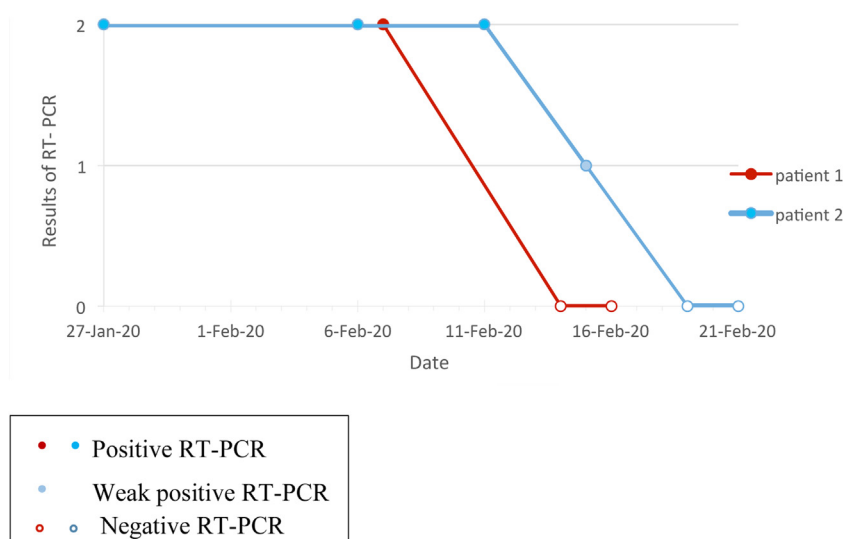


Figure 1. Timeline of RT-PCR testing.

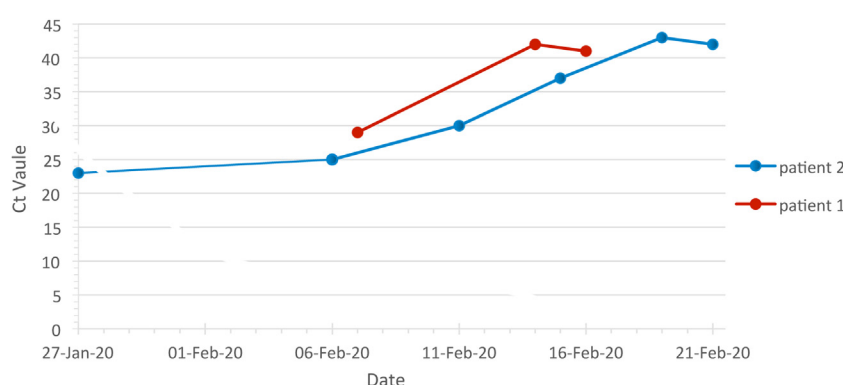


Figure 2. Viral load detected in throat swabs. This shows cycle threshold (Ct) values for ORF1ab, from reverse-transcriptase polymerase chain reaction (RT-PCR) assays, detected in throat swabs obtained from the two patients. Ct values of 29.96, 26.64, 23.32, and 20 correspond to 1.0×10^4 , 1.0×10^5 , 1.0×10^6 , and 1.0×10^7 copies per milliliter, respectively, and represent positive samples. Negative samples are represented by Ct values of more than 40.

underwent a third RT-PCR test, and the result was still positive. On February 15, the 19th day of isolation, he underwent a fourth RT-PCR test, which produced a weak positive result. On February 21, the 25th day of isolation, his RT-PCR test proved negative for the second time and he was discharged (Figure 1). There were no symptoms during his treatment.

We discovered that, after 14 days of isolation, there were still virus carriers in the asymptomatic population, which meant a risk of transmission (Bai et al., 2020; Hoehl et al., 2020). Due to the large numbers of close contacts and relatively limited medical resources, it is impossible for all contacts to attend hospital for RT-PCR detection, which presents a new challenge regarding home isolation (Figure 2).

Author declarations

All authors declare no conflicts of interest and no funding sources. The work was approved by the ethics committee of the hospital and the patients' families signed informed consent forms.

References

- Bai Y, Yao L, Wei T, et al. Presumed asymptomatic carrier transmission of Covid-19. *JAMA*. Published online February 21, 2020 2020; doi:<http://dx.doi.org/10.1001/Jama.2020.2565>.
- Hoehl S, Rabenau H, Berger A, et al. Evidence of SARS-CoV-2 infection in returning travelers from Wuhan, China. *N Engl J Med* 2020; doi:<http://dx.doi.org/10.1056/NEJMc2001899>.
- Li Q, Guan X, Wu P, et al. Early transmission dynamics in Wuhan, China, of novel coronavirus-infected pneumonia. *N Engl J Med*. 2020; doi:<http://dx.doi.org/10.1056/NEMo2001316>.
- Lipsitch M, Swerdlow DL, Finelli L. Defining the epidemiology of Covid-19-studies needed. *N Engl J Med* 2020; doi:<http://dx.doi.org/10.1056/NEJMp2002125>.
- WHO. Coronavirus disease (COVID-19) advice for the public. Available at: 2020. <https://www.who.int/emergencies/diseases/novel-coronavirus-2019/advice-for-public>.
- Zou L, Ruan F, Huang M, et al. SARS-CoV-2 viral load in upper respiratory specimens of infected patients. *N Engl J Med* 2020; doi:<http://dx.doi.org/10.1056/NEJMc2001737>.