

Four Hands Surgery for Intracerebral Hemorrhage using Orbeye: Educational Values and Ergonomic Advantages – A Technical Note

Abstract

We have developed a new educational approach to microsurgery in which a trainee and supervisor can cooperate with “4 hands” using the exoscope. We evaluated 4-hands surgery for intracranial hemorrhage (ICH) using the exoscope to validate the educational value and ergonomic advantages of this method. Thirty consecutive patients who underwent surgery for ICH using the exoscope between December 2018 and May 2020 were studied retrospectively. All operations were performed by a team comprising a supervisor (assistant) and a trainee (main operator). The assistant set the visual axis of the exoscope, and adjusted focus and magnification as a scopist. After setting the ORBEYE, the supervisor helped retract the brain and withdraw and irrigate the hematoma using suction tubes or brain retractors. Moreover, the trainee evacuated the hematoma with a suction tube and coagulated using bipolar forceps. Patient background and results of treatment were evaluated. Intraoperative postures of the operators were observed, and schemas compared with the use of a conventional microscope were developed. All microsurgical procedures were accomplished by a trainee with a supervisor using only the exoscope. During the surgery, the surgeons could work in a comfortable posture, and the supervisor and trainee could cooperate in microsurgical procedures using their four hands. The results of the present case series concerning evacuation of ICH were not inferior to those described in previous reports. To increase opportunities for education in microsurgery, 4-hands surgery for ICH using the exoscope appears feasible and safe and offered excellent educational value and ergonomic advantages.

Keywords: Craniotomy, evacuation, exoscope, intracranial hemorrhage, ORBEYE

Introduction

Young neurosurgeons have frequently encountered difficulty gaining sufficient opportunities to acquire skills in microneurosurgery because of recent advances in internal medicine, endovascular therapy, and endoscopic surgery for cerebrovascular disease.^[1-3] Surgery for intracranial hemorrhage (ICH) has been reported as the basis of microneurosurgery and can provide an educational resource.^[4] In microsurgeries using ORBEYE, the posture of the assistant is comfortable enough to assist in the surgery.^[5-10] This can increase the opportunities in microsurgical education for the trainee. We evaluated a 4-hands surgery for ICH using ORBEYE to validate the educational value and ergonomic advantage of this method.

Methods

Ethics approval for the study was obtained from our institutional review

board (approval number 191205). Evacuation of ICH was performed with the patient's informed consent. The surgical inclusion criteria were ICH confirmed on brain computed tomography with hemorrhage volume >20 ml on admission and cases within 48 h of onset. Patient background and results of treatment were investigated. Thirty consecutive patients who underwent ICH evacuation using ORBEYE between December 2018 and May 2020 were investigated retrospectively. All operations were performed by a team comprising a supervisor (as an assistant) and a trainee (as the main operator). ORBEYE, a high-resolution (4K), 3-dimensional (3D) exoscope, was set and used during intradural manipulation. The assistant set the visual axis of the exoscope, and adjusted focus and magnification as a scopist. After setting the ORBEYE, the assistant (supervisor) helped retract the brain and withdraw and irrigate the

**Tomoaki Murakami,
Shingo Toyota,
Takuya Suematsu,
Yuki Wada,
Kanji Nakagawa,
Takeshi Shimizu,
Kanji Mori,
Takuyu Taki**

*Department of Neurosurgery,
Kansai Rosai Hospital,
Amagasaki, Hyogo, Japan*

Address for correspondence:

*Dr. Shingo Toyota,
Department of Neurosurgery,
Kansai Rosai Hospital, 3-1-69
Inabaso, Amagasaki 660-8511,
Hyogo, Japan.
E-mail: stshto@aol.com*

Access this article online

Website: www.asianjns.org

DOI: 10.4103/ajns.AJNS_148_21

Quick Response Code:



How to cite this article: Murakami T, Toyota S, Suematsu T, Wada Y, Nakagawa K, Shimizu T, *et al.* Four hands surgery for intracerebral hemorrhage using orbeye: Educational values and ergonomic advantages – A technical note. *Asian J Neurosurg* 2021;16:634-7.

Submitted: 11-Apr-2021

Revised: 04-May-2021

Accepted: 30-May-2021

Published: 14-Sep-2021

This is an open access journal, and articles are distributed under the terms of the Creative Commons Attribution-NonCommercial-ShareAlike 4.0 License, which allows others to remix, tweak, and build upon the work non-commercially, as long as appropriate credit is given and the new creations are licensed under the identical terms.

For reprints contact: WKHLRPMedknow_reprints@wolterskluwer.com

hematoma using suction tubes or brain retractors. Moreover, the operator (the trainee) evacuated the hematoma with a suction tube and coagulated using bipolar forceps. The postures of the main operator and the assistant when the visual axis of the ORBEYE were set in the 0, 3, 6, and 9 o'clock directions during hematoma evacuation were observed, and schemas were developed and compared with the use of a conventional surgical microscope.

Results

In all 30 cases, all microsurgical procedures were performed using only ORBEYE. The patient background characteristics and results of treatment are shown in Table 1.

All microsurgical procedures by the trainee were accomplished with the supervisor using ORBEYE. Educational assistance and oversight by the supervisor were provided in all cases [Figure 1]. Because the supervisor's hands could move freely in the surgical field, the trainee and the supervisor could perform 4-hand microsurgery cooperatively in all the cases [Figure 2]. During microsurgical manipulation in all directions (0, 3, 6, and 9 o'clock directions) of the hematoma, the operator and the assistant bent their elbow joints moderately, facing the monitor, and could perform a stable operation in a comfortable posture [Figure 3].

Discussion

Recently, introduction of the exoscope into the neurosurgery has been expected to have ergonomic and educational merits.^[5-16] No case series of ICH evacuation using an exoscope have been reported. In the present case series, mean intraoperative blood loss, rate of rebleeding, rate of complications related to the operation, and the mortality

rate were 38.5 ± 57.9 ml, 0%, 6.6%, and 6.6%, respectively, whereas in previous reports, they were 53.7–605.6 ml,^[17,18] 8%–18%,^[18,19] 8%–58.9%,^[20,21] and 9%–25%,^[17,19-21] respectively. Thus, the results of the present case series were not inferior to previous reports.^[17-21]

In the general endoscopic surgery, a scopist is expected to have enough knowledge and experience to ensure

Table 1: Patient's characteristics

Parameters	n (%)
Age (years), mean±SD	70.7±13.3
Gender male	19 (63.3)
Location of ICH	
Subcortical	12 (40)
Putaminal	10 (33.3)
Cerebellar	4 (13.3)
Others	4 (13.3)
Etiology	
Hypertensive	23 (76.6)
Hemorrhagic cerebral infarction	3 (10)
Amyloid angiopathy	3 (10)
Moya Moya disease	1 (3.3)
Preoperative volume of hematoma (ml), mean±SD	64.0±31.7
Postoperative volume of hematoma (ml), mean±SD	8.8±20.6
Removal rate (%), mean±SD	90.8±17.5
Operative time (min), mean±SD	203.4±61.0
Intraoperative bleeding loss (ml), mean±SD	38.5±57.9
Hospital stay (days), mean±SD	26.6±13.5
mRS on admission - mRS at discharge, median (IQR)	0 (0-1)
Complication	2 (6.6)
Mortality	2 (6.6)

ICH - Intracerebral hemorrhage; mRS - Modified Rankin Scale; IQR - Interquartile range; SD - Standard deviation

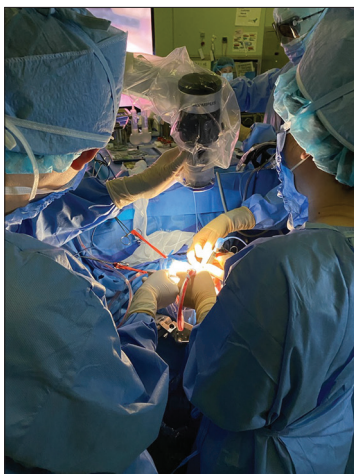

Figure 1: The whole operative view for the hematoma evacuation using ORBEYE. The operator (the trainee, right side) and the assistant (the supervisor, left side) bend their elbow joints moderately, facing the monitor, and they can perform a stable operation in a comfortable posture. The assistant (the supervisor) helps retract the brain using brain retractors and sets the visual axis of ORBEYE and adjusts focus and magnification as a scopist

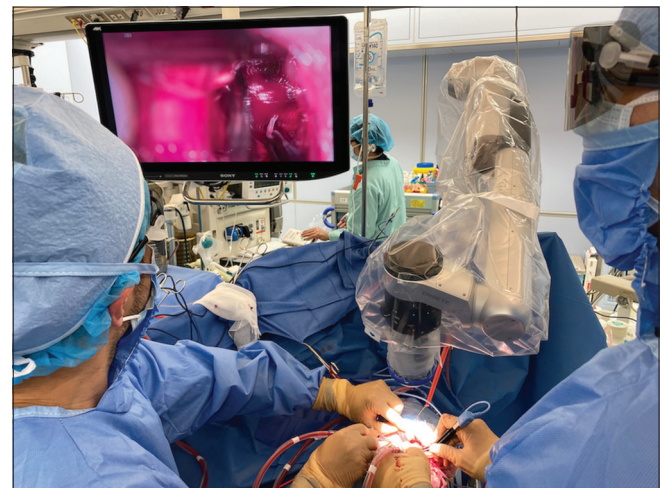

Figure 2: The whole operative view of 4-hands surgery for the hematoma evacuation using ORBEYE. The operator (the trainee, right side) and the assistant (the supervisor, left side) bend their elbow joints moderately, facing the monitor, and they can perform a stable operation in a comfortable posture. The operator (the trainee) evacuated the hematoma with a suction tube and coagulated using bipolar forceps. The assistant (the supervisor) helps retract the brain using brain retractors and withdraw and irrigate the hematoma using suction tubes or brain retractors

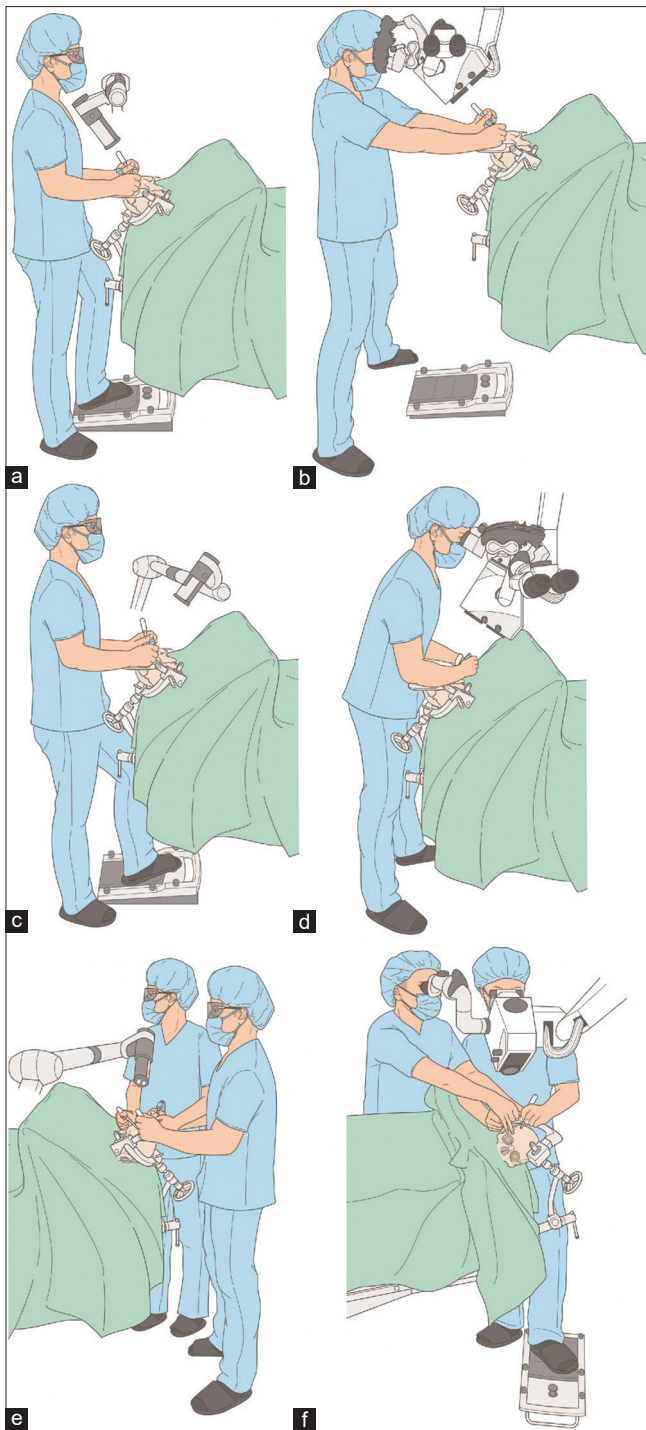


Figure 3: Comparison between the ORBEYE and the conventional microscope. In the 12 o'clock direction: (a) Using the ORBEYE, the operator bends the elbow moderately. (b) Using the microscope, the operator stretches the elbow excessively. In the 6 o'clock direction: (c) Using the ORBEYE, the operator bends the elbow moderately. (d) Using the microscope, the operator bends the elbow excessively. In the 9 o'clock direction: (e) Using the ORBEYE, the assistant bends the elbow moderately. (f) Using the microscope, the assistant scope can sometimes hinder the angle of the microscope

the operative field.^[22] In the neurosurgery, we are also expected to have those, in performing the microsurgery using the exoscope. To improve efficiency of operative

education, in our institution, we established the policy that a supervisor ensured the operative field and set the visual axis as a scopist, including manipulation of exoscope, and a trainee dedicated operative procedure for ICH evacuation. Schemas showing that a trainee (main operator) and a supervisor (assistant) can cooperatively perform 4-hand microsurgery in a comfortable posture have been developed [Figure 2]. Using ORBEYE, a trainee and a supervisor bend the elbow joint more comfortably during microsurgical manipulation in all directions (12, 3, 6, and 9 o'clock directions) of the hematoma, compared to using a conventional microscope [Figure 3]. Thus, the supervisor can help the trainee every step of the way. Furthermore, the sharing of the 3D operative field using ORBEYE is also useful as an educational tool.^[14] In the present series, the trainee and supervisor could share the 3D operative field with comfortable postures. Therefore, ORBEYE appears to have excellent educational value.

Conclusion

Exoscopic 4-hands evacuation of ICH is feasible and safe and provides excellent educational value and ergonomic advantages, increasing the opportunities for education in microsurgery.

Acknowledgments

Dr. Toyota, Dr. Taki, and I contributed to the conception and design of the study. Dr. Toyota, Dr. Suematsu, Dr. Wada, Dr. Nakagawa, Dr. Shimizu, Dr. Mori, Dr. Taki, and I recruited the patients and performed exoscopic 4-hands evacuation of ICH using ORBEYE. Dr. Toyota, Dr. Taki, and I contributed to writing and revising the manuscript.

Financial support and sponsorship

Nil.

Conflicts of interest

There are no conflicts of interest.

References

- Ikawa F, Hidaka T, Kurokawa Y, Yonezawa U, Kobayashi S. Present Situation of Therapy for Cerebral Aneurysm in Japan: According to the Data of our Institute, the Japan Standard Stroke Registry Study, and the Japan Neurosurgical Society. *Surg Cereb Stroke* 2015;43:262-6.
- Qureshi AI, Vazquez G, Tariq N, Suri MF, Lakshminarayan K, Lanzino G. Impact of International Subarachnoid Aneurysm Trial results on treatment of ruptured intracranial aneurysms in the United States. *Clinical article. J Neurosurg* 2011;114:834-41.
- Lai L, Morgan MK. The impact of changing intracranial aneurysm practice on the education of cerebrovascular neurosurgeons. *J Clin Neurosci* 2012;19:81-4.
- Inoue T. As a young neurosurgeon in training: The importance of thorough microsurgical training and professionalism. *JPN J Neurosurg* 2012;21:4-8.
- Izumo T, Ujifuku K, Baba S, Morofuji Y, Horie N, Matsuo T. Initial experience of ORBEYE™ surgical microscope for carotid endarterectomy. *Asian J Neurosurg* 2019;14:839-42.

6. Langer DJ, White TG, Schulder M, Boockvar JA, Labib M, Lawton MT. Advances in intraoperative optics: A brief review of current exoscope platforms. *Oper Neurosurg (Hagerstown)* 2020;19:84-93.
7. Murai Y, Sato S, Yui K, Morimoto D, Ozeki T, Yamaguchi M, *et al.* Preliminary clinical microneurosurgical experience with the 4K3-dimensional microvideoscope (ORBEYE) system for microneurological surgery: Observation study. *Oper Neurosurg (Hagerstown)* 2019;16:707-16.
8. Nossek E, Schneider JR, Kwan K, Kulason KO, Du V, Chakraborty S, *et al.* Technical aspects and operative nuances using a high-definition 3-dimensional exoscope for cerebral bypass surgery. *Oper Neurosurg (Hagerstown)* 2019;17:157-63.
9. Shimizu T, Toyota S, Nakagawa K, Murakami T, Mori K, Kishima H, *et al.* Retrosigmoid approach in the supine position using ORBEYE: A consecutive series of 14 cases. *Neurol Med Chir (Tokyo)* 2021;61:55-61.
10. Iwata T, Toyota S, Kudo A, Nakagawa K, Shimizu T, Murakami T, *et al.* Microsurgery “Under the Eaves” using ORBEYE: A case of dural arteriovenous fistula of the anterior cranial fossa. *World Neurosurg* 2020;138:178-81.
11. Ahmad FI, Mericli AF, DeFazio MV, Chang EI, Hanasono MM, Pederson WC, *et al.* Application of the ORBEYE three-dimensional exoscope for microsurgical procedures. *Microsurgery* 2020;40:468-72.
12. Bakhsheshian J, Strickland BA, Jackson C, Chaichana KL, Young R, Pradilla G, *et al.* Multicenter investigation of channel-based subcortical trans-sulcal exoscopic resection of metastatic brain tumors: A retrospective case series. *Oper Neurosurg (Hagerstown)* 2019;16:159-66.
13. Beez T, Munoz-Bendix C, Beseoglu K, Steiger HJ, Ahmadi SA. First clinical applications of a high-definition three-dimensional exoscope in pediatric neurosurgery. *Cureus* 2018;10:e2108.
14. Oertel JM, Burkhardt BW. Vitom-3D for exoscopic neurosurgery: Initial experience in cranial and spinal procedures. *World Neurosurg* 2017;105:153-62.
15. Muhammad S, Lehecka M, Niemelä M. Preliminary experience with a digital robotic exoscope in cranial and spinal surgery: A review of the Synaptive Modus V system. *Acta Neurochir (Wien)* 2019;161:2175-80.
16. Nishiyama K. From exoscope into the next generation. *J Korean Neurosurg Soc* 2017;60:289-93.
17. Xu X, Chen X, Li F, Zheng X, Wang Q, Sun G, *et al.* Effectiveness of endoscopic surgery for supratentorial hypertensive intracerebral hemorrhage: A comparison with craniotomy. *J Neurosurg* 2018;128:553-9.
18. Shi J, Cai Z, Han W, Dong B, Mao Y, Cao J, *et al.* Stereotactic catheter drainage versus conventional craniotomy for severe spontaneous intracerebral hemorrhage in the basal ganglia. *Cell Transplant* 2019;28:1025-32.
19. Brouwers HB, Raffeld MR, van Nieuwenhuizen KM, Falcone GJ, Ayres AM, McNamara KA, *et al.* CT angiography spot sign in intracerebral hemorrhage predicts active bleeding during surgery. *Neurology* 2014;83:883-9.
20. Zhou H, Zhang Y, Liu L, Han X, Tao Y, Tang Y, *et al.* A prospective controlled study: Minimally invasive stereotactic puncture therapy versus conventional craniotomy in the treatment of acute intracerebral hemorrhage. *BMC Neurol* 2011;11:76.
21. Kellner CP, Song R, Pan J, Nystal DA, Scaggiante J, Chartrain AG, *et al.* Long-term functional outcome following minimally invasive endoscopic intracerebral hemorrhage evacuation. *J Neurointerv Surg* 2020;12:489-94.
22. Nakanishi R, Fukunaga Y, Mukai T, Nagasaki T, Yamaguchi T, Akiyoshi T, *et al.* Educational system for acquiring appropriate laparoscopic colorectal surgical skills: Analysis in a Japanese high-volume cancer center. *Surg Endosc* 2021;35:2660-6.