

Neuroimaging and other investigations in patients presenting with headache

Callum W. Duncan

Department of Neurology, Aberdeen Royal Infirmary, Foresterhill, Aberdeen, AB25 2ZN, UK

Abstract

Headache is very common. In the United Kingdom, it accounts for 4.4% of primary care consultations, 30% of referrals to neurology services and 0.5–0.8% of alert patients presenting to emergency departments. Primary headache disorders account for the majority of patients and most patients do not require investigation. Warning features (red flags) in the history and on examination help target those who need investigation and what investigations are required. This article summarizes the typical presentations of the common secondary headaches and what neuroimaging and other investigations are appropriate for each headache type.

Key Words

Intracranial hypotension, lumbar puncture, neuroimaging, raised intracranial pressure, thunderclap headache

For correspondence:

Dr. Callum William Duncan, Consultant Neurologist, Department of Neurology, Ward 40, Aberdeen Royal Infirmary, Foresterhill, Aberdeen, AB25 2ZN, UK. E-mail: callum.duncan@nhs.net

Ann Indian Acad Neurol 2012;15:23-32

Introduction

Headache is very common. It is estimated to have a lifetime prevalence of over 90% in the United Kingdom,^[1] accounting for 4.4% of consultations in primary care,^[2] 30% of out-patient referrals to neurological services,^[3] and 0.5–0.8% of alert patients presenting to the emergency department.^[4–6] It is classified into primary and secondary headache disorders.^[7] Primary headache disorders, such as tension-type headache (TTH), migraine and cluster headache, are not associated with underlying pathology. They are benign, but are often disabling. Secondary headache disorders are attributed to an underlying pathological cause (structural, vascular, infective, inflammatory or drug induced).^[7]

Primary headache disorders account for more than 90% of headache presenting to primary care.^[8] If the headache is severe enough for a patient to attend an emergency department, a secondary cause is more likely, but primary headaches disorders still account for 60% of this group.^[5] Not all secondary headache has a sinister underlying pathology; 13–18% of patients presenting to the emergency department

have a sinister cause for their headache.^[5,6] The most common secondary headache is medication overuse headache.

A sinister underlying cause is very unlikely in stable episodic headache and investigation is not required for the majority of patients.^[9] Neuroimaging and other investigations should be targeted at those patients with a potentially sinister underlying cause (for example subarachnoid hemorrhage (SAH), cerebral tumour) or where it is important in the diagnostic process (for example, spontaneous intracranial hypotension). Neuroimaging used incorrectly can be falsely reassuring (for example in giant cell arteritis and idiopathic intracranial hypertension), and indiscriminate use of neuroimaging, where the likelihood of finding a relevant abnormality is low, has a significant chance of revealing an incidental finding, which then complicates patient management and may heighten patient anxiety.^[10]

Red Flags

Warning symptoms or “red flags” can be useful in targeting which patients require investigation [Table 1].^[9,11] Some red flags, such as thunderclap headache and new progressive headache with focal symptoms and/or abnormal neurological examination, should always prompt urgent investigation. Other red flags, such as new headache in a person older than 50, change in headache characteristics and change in headache frequency, may not require immediate investigation, but warrant monitoring and a low threshold for investigation [Table 1]. Kernick *et al.*^[11] propose an interesting traffic light system for patients where an underlying brain tumor is being considered in primary care. Red flags (estimated risk of an

Access this article online

Quick Response Code:



Website:

www.annalsofian.org

DOI:

10.4103/0972-2327.99995

underlying tumour >1%) require urgent investigation, orange flags (estimated risk of an underlying tumour 0.1–1%) require careful monitoring and a low threshold for investigation, and yellow flags (estimated risk of an underlying tumour <0.1%, but greater than the population risk of 0.01%) require appropriate management and follow-up.

Thunderclap Headache

Thunderclap headache is “a severe and explosive headache with peak intensity at onset – as sudden and as unexpected as a clap of thunder.”^[12] It is frequently associated with serious intracranial vascular disorders^[12], in particular SAH, but both primary and other secondary headache disorders can present with thunderclap headache^[13] [Table 2]. There are no reliable features that can differentiate primary thunderclap headache from SAH^[14,15] and all patients with new sudden onset severe

Table 1: Red flags for secondary headache

New or changed headache >age 50
New headache in a patient with a history of cancer or immunosuppression
Change in headache pattern or frequency
Thunderclap onset
New focal neurological symptoms
New non-focal neurological symptoms
New abnormal neurological examination
Headache waking the patient up
Headache precipitated by exertion or valsalva
Headache that changes with posture
Neck stiffness or fever
Jaw claudication or visual disturbance

Table 2: Differential diagnosis of thunderclap headache

Primary headaches	Investigation
Primary thunderclap headache	
Migraine	
Cluster headache	
Primary exertional headache	
Primary orgasmic headache	
Secondary headaches	
Subarachnoid hemorrhage	CT +/- LP or CTA
Reversible cerebral	CT + CTA +/- LP +/- MRI
Vasoconstriction syndrome	
Intracerebral, intraventricular, subdural or	CT +/- MRI
Extradural hemorrhage	
Carotid or vertebral artery dissection	CT + CTA +/- MRI including fat sat views
Cerebral venous sinus thrombosis	CT + CTV +/- MRI
Infection e.g. meningitis, encephalitis	LP, may need CT before LP
Acute hydrocephalus e.g. colloid cyst	CT or MRI
Intracranial tumour, including pituitary apoplexy	CT or MRI
Metabolic e.g. pheochromocytoma	Urinary catecholamines
Spontaneous intracranial hypotension	MRI

headache (maximal within seconds to minutes) require investigation.^[13] A “clinical decision rule” has been developed with the intention targeting investigation in sudden severe headache, allowing some patients not to be investigated.^[16] It is currently undergoing validation, but there is concern that the use of “rigid rules” in this situation is too simplistic.^[17]

Subarachnoid hemorrhage

When headache is the only symptom, it is estimated that 1 in 10 patients who present with a sudden severe headache has a SAH.^[15,18] If the headache is accompanied by focal signs and/or reduced conscious level, this may rise to as high as 1 in 4.^[18] Most SAH (85%) is aneurysmal.^[18] Despite improvements in the management of SAH, there is still a 50% case fatality rate for aneurysmal SAH and 20% of survivors remain dependant.^[19] The highest risk of re-bleeding is in the first few days, and if the aneurysm is left untreated there is a 20–40% risk of re-bleeding in the first month,^[20] reducing gradually to 3% per year by 6 months.^[18] Of the remaining patients with SAH, 10% are non-aneurysmal perimesencephalic and 5% have a variety of other causes, e.g., cocaine use, pituitary apoplexy and vertebral arterial dissection.^[18]

Most patients with SAH have a headache that is sudden in onset (instantaneous to seconds). However, in a fifth of patients, the onset may be longer (1–5 minutes).^[14] The longest time for a headache to reach its maximum and still be a SAH is unknown; however, headache taking 10 minutes or more to reach its maximum is unlikely to be SAH.^[21] The headache is usually diffuse, but can occasionally be focal. Patients often describe it as the most severe headache they have ever had. The duration of headache is usually at least days and may last for weeks. It is unknown how short a headache can be and still be a SAH. The “expert view” is that it should last at least an hour or two.^[21] Other symptoms commonly present in patients with SAH include: nausea, vomiting, photophobia, neck stiffness, loss of consciousness and seizures. Examination may be normal, particularly in those who just have headache, and no patient should be considered “too well” to have a SAH.^[21]

Investigation of subarachnoid hemorrhage

Unenhanced computed tomography (CT) of the brain [Figure 1] is the essential investigation in suspected SAH.^[22] It is important

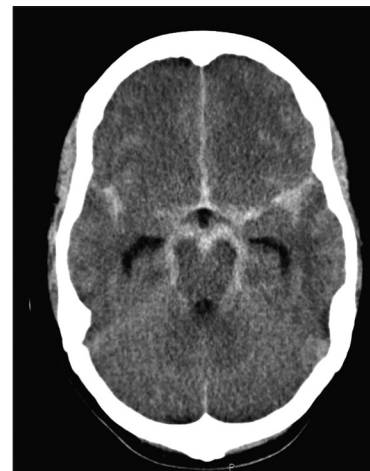


Figure 1: Subarachnoid hemorrhage

to perform a CT as soon as practical after headache onset because subarachnoid blood rapidly degrades. By 12 hours 2% of scans will be negative, 7% will be negative by 24 hours, 50% will be negative after 1 week and subarachnoid blood is almost completely reabsorbed within 10 days.^[13,22] Computed tomography quantifies the amount and distribution of blood and will show complications associated with SAH, such as hydrocephalus and ischemia.^[22] The pattern of hemorrhage may also give an indication as to the likely location of the underlying aneurysm.^[18,22]

Patients with a normal CT brain scan require a lumbar puncture (LP), to include measurement of opening pressure, red and white cells, protein and glucose, and spectrophotometry to look for the presence of xanthochromia (bilirubin and oxyhemoglobin). Unless an alternative diagnosis, such as meningitis, is suspected this should be delayed for at least 6, but preferably 12 hours from headache onset to allow blood to degrade to bilirubin.^[13] Bilirubin is only synthesized *in vivo* and is the crucial result. The sample sent for xanthochromia should be protected from light to prevent degradation of bilirubin in transit. Oxyhemoglobin can be synthesized *in vitro* and is present if there has been a traumatic tap, prolonged storage or agitation of blood-stained CSF *in vitro*.^[23] A decrease in the amount of red blood cells across consecutive tubes does not distinguish a traumatic tap from SAH.^[18] Bilirubin is detectable in 100% up to 2 weeks from headache onset and a normal unenhanced CT brain scan and negative LP performed within 2 weeks of headache onset is sufficient to exclude SAH.^[13] Beyond 2 weeks, xanthochromia may be negative and a negative CT and LP cannot reliably exclude SAH. Angiography is, therefore, required in all patients presenting more than 2 weeks after headache onset. Xanthochromia is, however, still present in 91% at 3 weeks and 71% at 4 weeks^[24] and it is still worth performing a LP, in addition to angiography, in patients presenting more than 2 weeks after headache onset.

Once subarachnoid hemorrhage is confirmed, either on CT or LP, angiography is required to look for an underlying cerebral aneurysm. Computed tomography angiography (CTA) has become the initial investigation of choice.^[13,22] Aneurysms >3 mm diameter can be reliably detected using modern scanners.^[22] The sensitivity of CTA ranges from 82 to 96% in different studies, but may approach 100% depending on the aneurysm. The lower values are associated with aneurysms <3 mm, but this may be improving with newer techniques.^[22] Ideally, a CTA should be performed immediately after a positive unenhanced CT, or a normal CT and positive LP, to look for a causative aneurysm.^[25] This allows the interventional neuroradiologist or neurosurgeon to plan treatment without delay, expediting treatment and reducing the risk of morbidity and mortality. The main use of magnetic resonance angiography (MRA) is in the follow-up of proven aneurysms. In aneurysms >3 mm, it has a sensitivity of about 94%, but only 38% in those <3 mm.^[22]

If an aneurysm is not detected on CTA and the distribution of blood is suggestive of an aneurysmal bleed, a conventional catheter angiogram is required.^[13,22] Catheter angiography is still considered the optimal investigation to look for a

cerebral aneurysm. The combined risk of transient ischemia or permanent stroke has been estimated to be 1.8% following catheter angiography, although this may now be substantially lower.^[22,26] If a catheter angiogram is negative and an aneurysmal SAH is still considered likely, a repeat catheter angiogram should be considered at 10–14 days.^[22] Depending on the clinical history and pattern of SAH on CT, an MRI brain and/or spine may need to be considered, e.g., looking for an cortical or spinal arterio-venous malformation (AVM) or dural fistula.

Perimesencephalic SAH has a specific pattern of blood confined to the cisterns around the midbrain. The clinical course of perimesencephalic SAH is milder and patients recover quickly. The prognosis is good and the risk of recurrence low. If a CTA excludes a vertebral artery aneurysm, which mimics a perimesencephalic blood pattern in 5%, and the clinical course and pattern of blood on CT are typical, then further investigation is not required, the patient can be reassured and treatment stopped.^[18]

Other causes of thunderclap headache

In the majority of patients, thunderclap headache is benign and once SAH has been excluded, investigation can stop.^[15] There is, however, a wide differential diagnosis [Table 2] and all patients with suspected subarachnoid hemorrhage should have a comprehensive history and examination to screen for other secondary causes.^[13] Further targeted investigation may be required depending on history and examination findings.

Reversible cerebral vasoconstriction syndrome

It is not uncommon for patients with primary thunderclap headache to have recurrent sudden severe headaches. Twenty-five out of 103 patients with thunderclap headache, prospectively followed up for 1 year, had at least 1 recurrent thunderclap headache.^[15] Patients presenting with frequent thunderclap headaches over the course of a few days or weeks require more extensive investigation. Reversible Cerebral Vasoconstriction Syndrome (RCVS)^[27] presents with multiple thunderclap headaches, occurring every day or so, and settling over approximately 3 weeks. It is associated with segmental narrowing and dilation of one or more cerebral arteries on cerebral angiography, “string of beads.” which by definition resolves by 3 months and may be precipitated in the post-partum period or by ingestion of vasoactive substances (e.g., cannabis, cocaine, SSRIs, triptans). Seizures and focal neurological deficits, which may be permanent, can occur in the first few weeks and at least one trigger is reported by 80% of patients (sexual activity, straining, emotion, physical effort, coughing, sneezing, urinating, bathing, showering, sudden head movement).

Patients presenting with frequent recurrent thunderclap headaches over a few days or weeks should, therefore, have CTA or MRA to look for the typical “string of beads” pattern. A plain, unenhanced CT is usually normal. MRI is more sensitive and is abnormal in about one-third of patients, showing cortical SAH, changes consistent with posterior reversible encephalopathy, infarcts or hematomas. In patients with blood pressure surges during headache, urine should be collected to measure for catecholamines, to exclude a pheochromocytoma.^[27,28]

Other vascular causes of thunderclap headache

Intra-cerebral, intra-ventricular, subdural and extradural hemorrhage may also present with thunderclap headache. The diagnosis should be relatively straightforward on the basis of history, examination and unenhanced CT. Depending on the distribution of blood in patients with intra-cerebral hemorrhage, MRI and / or cerebral angiography may be required to identify an underlying vascular or neoplastic lesion.^[29]

Cervical artery dissection should be suspected if there is pain in the face, around the eye, in the neck or side of the head (carotid) or back of the head and neck (vertebral), particularly if there has been recent neck injury or manipulation.^[30] In carotid artery dissection, there may be an ipsilateral Horner's syndrome due to involvement of the sympathetic chain, or involvement of the ipsilateral lower cranial nerves, particularly the hypoglossal. A bruit may be audible on auscultation over the artery. Dissections resolve spontaneously, occasionally within days, and imaging should be performed as soon as possible after symptom onset. The usual complication of arterial dissection is stroke, due to occlusion of the artery or embolization of thrombus that has accumulated on the dissection flap. This may occur at the same time as the dissection or be delayed by hours or days. Occasionally, vertebral artery dissection results in SAH.

The imaging modality used depends on local expertise and experience. CT and CTA may be more useful than MRI and MRA except for the detection of acute ischemic stroke.^[31] The typical appearances are a long and tapering "rats tail," double-lumen, intimal flap or hematoma within the wall lumen. An occluded artery is non-specific and cannot confirm an arterial dissection. A fat saturation sequence on MRI is useful in detecting vertebral artery dissection.^[30]

Pituitary apoplexy, arterial hemorrhage within a pituitary tumour, should be suspected when sudden severe headache is associated with a drop in visual acuity or ophthalmoplegia.^[30] CT or MRI will show hemorrhage in the pituitary fossa, although this is more easily missed on CT. Blood may extend into the adjacent cavernous sinus and imaging may show diffuse hemorrhage in the basal cisterns, mimicking a SAH. A serum pituitary profile should be sent if pituitary apoplexy is considered.

Headache, including thunderclap headache, may be the only presentation of cerebral venous thrombosis.^[32] The lateral sinus is most commonly involved if headache is the sole feature. An elevated opening pressure on LP may be the only clue to the diagnosis, and an opening pressure should always be measured when doing an LP in thunderclap headache. The opening pressure is not always elevated and so a normal opening does not exclude cerebral venous sinus thrombosis. Venography, either computed tomography venography (CTV) or magnetic resonance venography (MRV), should be considered in all patients with risk factors for venous thrombosis.

Non-vascular causes of thunderclap headache

A colloid cyst of the third ventricle [Figure 3d], hypertensive crisis, meningitis and spontaneous intracranial hypotension may also present with sudden severe headache.

Infection of the Central Nervous System

Central nervous system (CNS) infection should be considered in all patients who present with headache and fever.

Meningitis

The classical presentation of meningitis (inflammation of the meninges) is with headache, fever, neck stiffness and altered mental status.^[33] All of these features are not present in every patient, particularly early on, and there should be a low threshold for investigation. In a prospective study of 696 patients with proven bacterial meningitis, only 44% had the "classical triad" (fever, neck stiffness and altered mental status), although 95% had 2 out of 4 of headache, fever, neck stiffness and altered mental status.^[34] Bruzinski's sign (flexion of the hips and knees on passive flexion of the neck) and Kering's sign (resistance to passive knee extension when the leg is passively flexed at the hip and knee) have high specificity, but low sensitivity and their absence should not be used to exclude meningitis.^[35]

Patients, particularly those with acute bacterial meningitis, can deteriorate quickly and rapid assessment, investigation and treatment is vital. The first priority is to ensure the patient is clinically stable. Patients in septic shock should be given empirical antibiotics and stabilized before investigation is carried out. In the rest, the priority is rapid clinical assessment and investigation. Ideally, empirical antibiotics should be given after a diagnostic LP; however, if there is going to be a significant delay then antibiotics should be given immediately. A useful algorithm can be found at www.britisheinfectionsociety.org.^[36]

LP is the key investigation and, unless there is a contraindication, should be carried out without delay. It can confirm the diagnosis and identify the causative organism, allowing determination of antibiotic sensitivities and rationalization of treatment. CSF should be sent for microscopy, culture and sensitivity, protein and glucose. The glucose sample should be sent in a glucose tube along with a matched serum sample. Latex particle agglutination antigen tests against *N meningitidis*, *S pneumoniae* and *H influenzae* can be useful if available. Routine blood tests, CRP and blood cultures should be sent at the same time. In bacterial meningitis, CSF is turbid, there is a polymorphic leukocytosis, with a high or very high white cell count, raised protein and reduced CSF glucose (<50% paired serum glucose). Gram stain may identify the organism in 50–95% of cases and CSF culture will be positive in 80% of untreated cases.^[33]

As long as it will not delay treatment, a CT should be performed in most patients before performing an LP. If a focal abnormality is present, an LP can be potentially dangerous by causing disruption of the normal intracranial compensation mechanisms and lead to brainstem herniation: "coning." For this reason, patients who have a focal deficit on neurological examination (excluding cranial nerve palsies), new-onset seizures, papilledema, depressed conscious level or are immuno-compromised (features of raised intracranial pressure may be masked) must have imaging before LP.^[36] A CT brain scan is the preferred imaging modality due to its accessibility and speed. If the fever is mild and the onset of the headache sudden, then subarachnoid hemorrhage should be

excluded. If there is going to be a significant delay for imaging, then an LP can be performed without imaging if none of the contraindications listed above are present.

Table 3 summarizes CSF findings in bacterial meningitis, viral meningitis, tuberculous meningitis and fungal meningitis. Early in the course of viral meningitis, the white cell count may be normal or neutrophils may predominate. In tuberculous meningitis, the protein may be very high and the glucose very low. In fungal meningitis, the CSF opening pressure may be very high.

Non-infective causes of meningitis should be considered, particularly when an infective cause is not identified and the patient not improving.^[37] Drug-induced meningitis is uncommon, but important to recognize. Non-steroidal anti-inflammatory drugs, COX-II inhibitors, antimicrobials (trimethoprim and penicillins), intravenous immunoglobulin (IVIG), immunosuppressants (methotrexate, azathioprine) and vaccinations have all been associated. The CSF pattern is non-specific, but polymorphs may predominate, and drug-induced aseptic meningitis is important to consider when there is a polymorph leucocytosis and normal glucose. Eosinophils can also predominate, particularly in IVIG-induced meningitis. Sarcoidosis, Behcet's disease, systemic lupus erythematosus and Sjogren's syndrome can cause inflammatory meningitis. Other system involvement should be looked for and autoantibody screen, serum ACE, chest X-ray and MRI should be considered early if an inflammatory cause is considered likely. Carcinoma (most commonly small cell lung cancer and breast cancer), lymphoma and leukemia can all cause meningitis. MRI is abnormal in around 60%, showing leptomeningeal enhancement.^[37] CSF commonly shows a lymphocytic pleocytosis, elevated protein and reduced glucose, but malignant cells are often harder to identify and several CSF samples may be required.

Viral encephalitis

The classical presentation of viral encephalitis is with a flu-like prodrome, followed by progressive headache, fever, nausea, vomiting and altered consciousness, often associated with seizures and/or focal neurological deficits.^[38] Alteration in higher mental function may range from lethargy and drowsiness to disorientation and confusion, and eventually coma. Seizures may be the initial presenting complaint, and viral encephalitis should be considered in any patient presenting with seizures and fever or with a seizure (or series of seizures) from which they do not recover.

In a patient who is mildly confused with no focal signs, imaging is not required and a lumbar puncture should be performed without delay. If there are associated focal signs, new seizures or depressed conscious level, then a CT brain scan is required prior to lumbar puncture. The CSF pattern is the same as that described for viral meningitis [Table 3]. Where available, CSF should be sent for viral PCR. The causative virus varies with geographical location. Herpes Simplex (HSV) is the commonest cause worldwide, and if there is going to be a significant delay then Aciclovir should be given first.

In HSV encephalitis, the CT may initially be normal or may show subtle fronto-temporal swelling. Later, there is hypodensity or high signal change if hemorrhage occurs. MRI is more sensitive [Figure 2a], but may also be normal if performed early. Electroencephalopathy (EEG) may show periodic lateralized epileptiform discharges (PLEDs)^[39] [Figure 2b]. In the correct clinical context, these are suggestive of HSV encephalitis, but are non-specific and can occur in a variety of acute neurological conditions: other infections, stroke, neoplastic lesions and inflammatory conditions. If there is no evidence of infection, then other causes of encephalitis need to be considered, particularly auto-immune encephalitis such as anti voltage gated potassium channel encephalitis^[40] and anti-NMDA receptor encephalitis.^[41]

Raised Intracranial Pressure (ICP)

The skull is a fixed volume container. The Monro-Kellie hypothesis^[42] states that the sum of the volumes of the normal intracranial contents (blood, CSF and brain) and any additional component (hematoma, tumor) is constant. An increase in the volume of any of the components must be compensated for by a reduction in one or more of the other components or the ICP will rise. The intracranial blood volume and CSF are the two components that can compensate for an increase in volume of another component, for example, an expanding brain tumor. Once the compensatory mechanisms are exhausted, there is a rapid rise in ICP. The rate at which the volume changes, determines the ability of the compensatory mechanisms to cope. A slow growing meningioma [Figure 3a] may achieve a considerable size before causing symptoms, and is more likely to present with a seizure or focal signs, whereas a fast-growing glioblastoma [Figure 3b] will often present with features of raised ICP.

ICP can rise for a number of reasons [Figure 3]. There may be a new "space-occupying lesion" such as a primary or secondary

Table 3: CSF constituents in meningitis and encephalitis

	Normal	Bacterial meningitis	Viral meningitis or encephalitis	Tuberculous meningitis	Fungal meningitis
Opening pressure	110-25 cmCSF	High	Normal/high	High	High/very high
Color	Clear	Cloudy	Clear	Cloudy/yellow	Clear/cloudy
WBC/mm ³	<5*	High-very high	Slightly increased	Slightly increased	Normal-high
Differential	Lymphocytes	Neutrophils	Lymphocytes	Lymphocytes	Lymphocytes
CSF/plasma glucose	Normal	Low (<50%)	Normal	Low-very low (<30%)	Normal-low
Protein (g/L)	<0.45*	High	Normal-high	High-very high	Normal-high
		>1	0.5-1	1.0-5.0	0.2-5.0

RBC = red blood count, WBC = white blood count, *The CSF white cell count and protein are falsely elevated in a bloody tap (subtract 1 WBC/mm³ for every 700 RBC/mm³ and 0.1 g/L for every 1000 RBC/mm³)

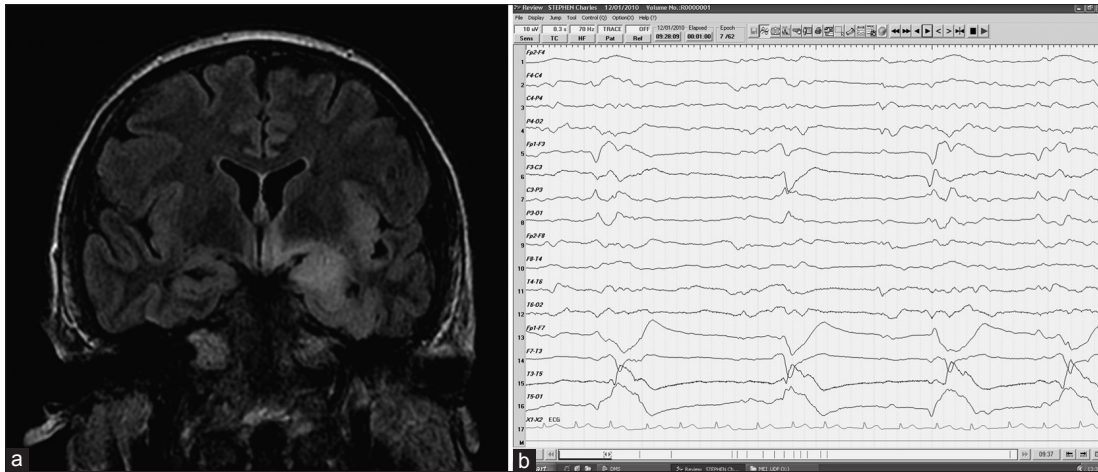


Figure 2: (a) MRI showing left fronto-temporal changes and (b) EEG showing periodic lateralized epileptiform discharges (PLEDs) in Herpes Simplex Encephalitis

tumour [Figure 3b], hematoma or abscess [Figure 3c]; an area of swelling, e.g., in encephalitis, after a large ischemic stroke or venous infarction in venous sinus thrombosis; or elevation in CSF pressure [Figure 3d]. Elevated CSF pressure may be focal as in obstructive hydrocephalus due to aqueduct stenosis or diffuse as in communicating hydrocephalus or intracranial hypertension. An LP is safe and can be therapeutic in communicating hydrocephalus and intracranial hypertension, but is potentially dangerous where there is focal raised pressure such as in obstructive hydrocephalus or a “space-occupying lesion.” If there is focal raised pressure, removal of CSF may decompensate the intracranial compensation mechanisms, leading to shift and transtentorial herniation: “coning.”

Symptoms suggestive of raised intracranial pressure

In an audit of patients with intracerebral tumors, headache was the commonest first symptom (23.5%) and was present in almost half by the time of presentation (46.5%).^[43] However, it was rarely the only symptom, and at presentation most patients (86%) had focal symptoms or signs (hemiparesis, hemisensory disturbance, diplopia) and/or more non-focal symptoms (confusion, personality change). Only 6 out of 310 patients (1.9%) had isolated headache with a normal examination and no clinical pointer to an underlying lesion. Headache due to a focal lesion causing raised ICP almost invariably causes a progressive headache with associated features. Isolated headache and longstanding headache are rarely due to an underlying focal lesion, and an isolated seizure is much more likely to have a sinister underlying pathology (positive predictive value 1.2% for first seizure compared with 0.09% for isolated headache).^[44]

Classically, raised ICP headache is worse in the morning. This is attributed to a rise in ICP due to lying flat overnight.^[42] However, not all morning headache is due to raised ICP. Migraineurs commonly waken with headache, which then gets worse, and patients with medication overuse headache commonly waken with headache, which then improves on taking the overused medication.^[45] Morning headache due to raised ICP will “waken the patient up” and then gets better once the patient is up and has assumed an upright posture. Nocturnal hypoventilation, due to respiratory muscle weakness

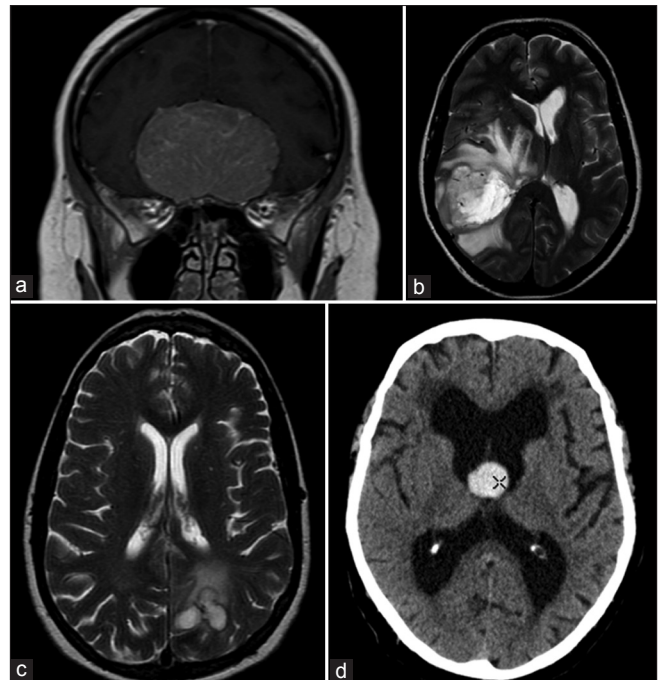


Figure 3: (a) A slow-growing meningioma may reach a considerable size before causing pressure effects, whereas (b) a comparable sized fast-growing glioblastoma results in considerable mass effect (c) cerebral abscess (d) hydrocephalus due to intermittent obstruction by a colloid cyst

or obstructive sleep apnea, is also important to consider in patients with morning headache.^[46]

When there is a long history of isolated episodic morning headache, the most likely diagnosis is migraine and investigation is not required unless there are “red flags.”^[18,9] Medication overuse (a complication of the treatment of primary headache) is the single commonest cause of secondary headache. If there is evidence of medication overuse, and there are no “red flags” then it is reasonable to withdraw medication without investigating. In a patient with a progressive history, usually over a short period of time, with new focal or non-focal symptoms, new focal signs, or if there is a history of cancer

or immunosuppression, then imaging is required to look for an underlying lesion.^[9] CT brain scan is the initial imaging modality of choice due to its accessibility in most patients. If there is a significant suspicion of a neoplastic lesion, then the CT should be contrast enhanced. MRI should be considered if the CT is normal or may be required to give further information on the lesion found on CT. In patients with headache precipitated by valsalva (coughing, sneezing, straining, stooping, exertion) MRI is required to exclude an Arnold Chiari malformation or a posterior fossa lesion.^[47]

Intracranial hypertension

Normal neuroimaging does not exclude raised ICP. Headache due to raised CSF pressure is usually episodic to begin with and gradually progresses to become daily over weeks.^[48] It has the typical features of raised ICP (worse in the morning, with exercise and valsalva) and commonly has features attributable to raised CSF pressure (pulsatile tinnitus [perception of a whooshing noise], transient visual obscurations [transient visual disturbance, ranging from slight blurring to total loss of light perception, on change in posture or valsalva maneuver], diplopia and visual blurring). Papilledema is typical and is usually bilateral; however, cases are reported without papilledema: so-called idiopathic intracranial hypertension without papilledema (IIHWOP).^[49] Other common findings on neurological examination include visual field defects, enlarged blind spots and sixth nerve palsies (unilateral or bilateral).^[48]

Idiopathic intracranial hypertension (IIH) is most commonly seen in obese women of childbearing age. It is a diagnosis of exclusion and all patients require adequate investigation to exclude a secondary cause. By definition, neuroimaging is normal in IIH and there are no imaging findings that can be used to give a positive diagnosis. Slit-like ventricles may be seen on CT and MRI, and a partially empty sella, flattening of the posterior sclera, or gadolinium enhancement of the optic disk may be seen on MRI.^[50] A lumbar puncture demonstrates an elevated opening pressure with normal CSF constituents. A CSF opening pressure >25 cm CSF is considered to be abnormal, although in some patients an opening pressure of up to 28 cm CSF may be normal.^[51] CSF should be sent for microscopy, culture and sensitivity, protein and glucose and cytology to exclude a secondary cause.

Venous sinus thrombosis must be excluded either by CTV or MRV. Other secondary causes to consider include medications (most commonly tetracyclines), infective or inflammatory meningitis, malignant meningitis (carcinoma, lymphoma or leukemia) and carbon dioxide retention due to obstructive sleep apnea or other respiratory disease.^[48]

Intracranial hypotension

The hallmark of intracranial hypotension is orthostatic headache (headache on assuming an upright posture). Intracranial hypotension is due to CSF leak, either following a diagnostic LP^[52] or occurring spontaneously.^[53] Not all orthostatic headache is due to CSF leak. It has also been associated with postural tachycardia syndrome,^[54] and with metastasis to the skull base^[55] and cervical spine.^[56]

The cause of spontaneous CSF leaks is unknown. Orthostatic headache starts or worsens after assuming an upright posture

and improves or resolves after lying down. The headache follows a new daily persistent pattern, with the patient waking up headache free followed by gradual onset headache. Usually, the headache develops within 15 minutes of assuming an upright posture and resolves within 15–30 minutes of lying down.^[53] Occasionally the headache takes hours to develop “second-half day headache” or the onset can be sudden, mimicking a SAH.^[57] The orthostatic component may disappear with time and in any patient with a new persistent headache, it is important to establish if the headache was orthostatic at the outset.

Post-LP headache usually settles with conservative management and if the onset and symptoms are typical, then investigation is usually not required.^[52] MRI is the investigation of choice for spontaneous intracranial hypotension. Subdural fluid collections, enhancement of the pachymeninges [Figure 4], and sagging of the brain are typical findings. Sagging of the brain can result in crowding of the posterior fossa and cerebellar tonsillar descent, which is presumably why some patients also describe valsalva-induced headache. Engorgement of venous structures and pituitary hyperemia may also be seen, and in up to 20% of patients there may be no abnormal findings on MRI scanning. While not diagnostic, CT may show bilateral subdural collections, providing a clue to the diagnosis. If an LP is performed, the opening pressure should be less than 6 cm CSF, although normal CSF opening pressures are reported.^[53] With a typical history and MRI findings, an LP is not required, particularly as it may aggravate the patient’s symptoms. It is important to try and identify the location of the CSF leak. Spinal MRI and CT myelography are most commonly used.

Giant Cell Arteritis

Giant Cell Arteritis (GCA) should be considered in any patient over the age of 50 who presents with new headache.^[9] The incidence increases significantly with age and patients are often much older. GCA is recognized to occur in individuals younger than 50, but this is vanishingly rare. GCA is an important diagnosis to consider because of the risk of visual loss and stroke. Some patients only have headache and there should be a low index of suspicion in patients over 50. In patients less than 50, the diagnosis should only be considered if characteristic features are present.

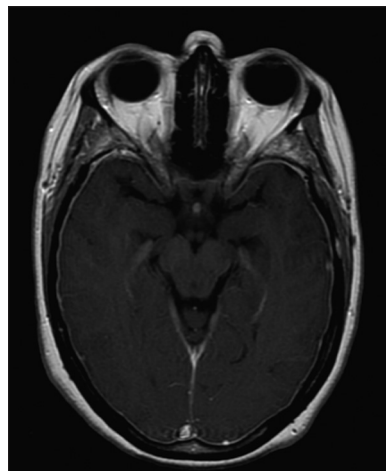


Figure 4: MRI showing pachymeningitis due to low CSF pressure

The headache has no specific features; it may be diffuse or localized, and is often bi-temporal. The two commonest presentations are with headache or with visual symptoms. Associated symptoms include scalp tenderness, fever, other constitutional symptoms, and symptoms of polymyalgia rheumatica. Jaw claudication (jaw and temple pain brought on by chewing, particularly vigorous chewing, that settles following stopping chewing) is very specific but poorly sensitive. Its presence is useful diagnostically, but its absence does not exclude GCA. Scalp tenderness has low specificity. The most useful sign is temporal artery beading, prominence or enlargement.^[58]

An erythrocyte sedimentation rate (ESR) is the best screening investigation. In a systematic review,^[58] the mean ESR in patients with biopsy-proven GCA was 88 mmHg. An ESR of less than 50 mmHg substantially reduces the likelihood of the diagnosis being GCA and a normal ESR makes it unlikely, but does not exclude it. A full blood count (FBC) looking for anemia and raised platelet count, and C-reactive protein (CRP) are useful additional blood tests.^[9]

If GCA is considered likely, steroids should be started immediately. It is important to confirm the diagnosis and a temporal artery biopsy should be performed as soon as possible. There is controversy about how long after initiation of steroids it is still useful to perform a biopsy. Convention suggests that a biopsy should be performed within 2 weeks. However, in a small prospective study,^[59] 6 out of 7 biopsies obtained between 4 and 6 weeks after starting steroids were positive. It is, therefore, still worth performing a temporal artery biopsy regardless of the duration of steroid treatment.^[59,60] Focal areas of arteritis may result in "skip lesions" and a negative biopsy with a good clinical history does not exclude GCA. However, a negative biopsy should always prompt adequate consideration of an alternative diagnosis.^[60]

Is investigation required in primary headache?

By definition, there is no secondary underlying pathology in primary headache, such as TTH, migraine, and cluster headache. Neuroimaging is required in selected patients with "red flags" to screen for secondary causes of headache [Table 1]. The chance of finding a significant underlying abnormality in patients with a stable headache pattern and a normal neurological examination in migraine is vanishingly small. A meta-analysis of neuroimaging studies^[61] estimated a 0.2% prevalence of significant intracranial abnormality. No abnormalities were found on neuroimaging in two small studies on TTH. In patients whose headaches could not be adequately classified, the risk of a significant abnormality was variable and in one study cited was as high as 6.7%. Evidence for the Trigeminal autonomic cephalalgias (TACs: cluster headache, paroxysmal hemicrania and SUNCT syndrome) is restricted to case reports. A literature review of symptomatic cases published between 1975 and 2007^[62] revealed 40 cases. These were associated with atypical phenotypes, abnormal examination, and poor treatment response though a significant minority had a typical presentation. A relatively high proportion were associated with pituitary tumors.

There is therefore good evidence that neuroimaging is not

required in stable migraine, and should be restricted to patients with "red flags." There is insufficient evidence to make recommendations in TTH or TACs. By extrapolation, it seems reasonable to not to image patients with TTH unless there are "red flags." Imaging should be considered in patients with TACs, particularly those with an atypical phenotype, abnormal examination, or poor treatment response. There should be a lower threshold for neuroimaging in patients whose headaches cannot be classified.

Incidental findings

In 350 consecutive patients scanned with CT regardless of the need for imaging, incidental findings were found in 7%.^[63] Relevant abnormalities were only found in patients where it was expected (abnormal neurological examination or warning symptoms). In two large studies performed on asymptomatic general populations with normal neurological examinations, MRI revealed incidental findings in 7% of healthy young men applying for military flying duties in the German Air Force (mean age 20)^[64] and 12% of a healthy older population in Rotterdam (mean age 63).^[65] A meta-analysis^[10] estimated that the overall prevalence of incidental findings on brain MRI was 2.7% or the "number of patients needed to scan" to get an incidental finding was 37. The commonest incidental findings were benign neoplasms and vascular abnormalities. Silent infarcts and white matter intensities were excluded from this calculation. They were common and their prevalence increased with age. White matter intensities occurred in more than 15% of the 70–89 age group.

CT Verses MRI in primary headache

MRI is more sensitive than CT,^[66] but in migraine is more likely to pick up incidental findings and not more likely to pick up clinically relevant findings.^[9,61] CT is therefore adequate in most patients, with MRI reserved for selected patients where the clinical history suggests MRI may be more useful, e.g., in patients with brainstem symptoms or with associated valsalva headache. In patients with TACs MRI is recommended.^[9]

Should patients be imaged for reassurance?

Patients increasingly expect a scan when they attend for assessment, particularly in secondary care. Explanation may suffice, but in some patients neuroimaging is required for reassurance. This has to be balanced against the risk of incidental findings and all patients should be counseled about the risk of finding an incidental abnormality before neuroimaging is organized.^[10] In a prospective randomized controlled trial of 150 patients with chronic daily headache and no "red flag" features,^[67] patients were randomized to receive no imaging or an MRI brain scan. Those randomized to a scan had significantly lower anxiety levels at 3 months, but this was not maintained and anxiety levels had returned to baseline at 1 year. There was, however, a significant reduction in healthcare costs in patients with psychiatric co-morbidity who were scanned compared to those who were not, presumably by altering the referral patterns of their primary care physicians. Anxiety levels were not increased in either the control or scan groups.

Practice points

- Most patients presenting with headache have primary headache

- Most patients do not require investigation
- Medication overuse headache (a complication of the management of primary headache) is the most common secondary headache
- “Red flags” can help target those patients who require investigation
- Thunderclap headache should be assumed to be SAH until excluded with urgent CT +/- LP
- A lumbar puncture should be performed without delay in patients with suspected meningitis
- Raised ICP headache usually presents with new persistent headache with progressive focal or non-focal symptoms and an abnormal neurological examination (Headache +)
- Low-pressure headache should be considered in patients with orthostatic headache. The orthostatic component may disappear with time
- Giant cell arteritis should be considered in any patient presenting with new headache over the age of 50 years
- Investigation of patients with headache should be balanced against the risk of incidental findings, particularly where investigation is being performed primarily for reassurance.

References

1. Boardman H, Thomas E, Croft PR, Millson DS. Epidemiology of headache in an English district. *Cephalalgia* 2003;23:129-37.
2. Latinovic R, Gulliford M, Ridsdale L. Headache and migraine in primary care: Consultation, prescription, and referral rates in a large population. *J Neurol Neurosurg Psychiatry* 2006;77:385-7.
3. Larner A. Guidelines for primary headache disorders in primary care: An “intervention” study. *Headache Care* 2006;3:1-2.
4. Locker T, Mason S, Rigby A. Headache management – Are we doing enough? An observational study of patients presenting with headache to the emergency department. *Emerg Med J* 2004;21:327-32.
5. Locker TE, Thompson C, Rylance J, Mason SM. The utility of clinical features in patients presenting with nontraumatic headache: An investigation of adult patients attending an emergency department. *Headache* 2006;46:954-61.
6. Breen DP, Duncan CW, Pope AE, Gray AJ, Al-Shahi Salman R. Emergency department evaluation of sudden severe headache. *Q J Med* 2008;101:435-43.
7. International Headache Society. The international classification of headache disorders, 2nd Ed. *Cephalalgia* 2004;24(Suppl1):8-160.
8. Tepper SJ, Dahlof CG, Dowson A, Newman L, Mansbach H, Jones M, *et al.* Prevalence and diagnosis of migraine in patients consulting their physician with a complaint of headache: Data from the landmark study. *Headache* 2004;44:856-64.
9. Scottish Intercollegiate Guidelines Network (SIGN). Diagnosis and management of headache in adults. Guideline No. 107: Available from: www.sign.ac.uk. [Last cited in 2008].
10. Morris Z, Whitely WN, Longstreth WT Jr, Weber F, Lee YC, Tsushima Y, *et al.* Incidental findings on brain magnetic resonance imaging: Systematic review and meta-analysis. *BMJ* 2009;339:b3106.
11. Kernick DP, Ahmed F, Bahra A, Dowson A, Elrington G, Fontebasso M, *et al.* Imaging patients with suspected brain tumour: Guidance for primary care. *Br J Gen Pract* 2008;58:880-5.
12. Dodick DW. Thunderclap Headache. *J Neurol Neurosurg Psychiatry* 2002;72:6-11.
13. Al-Shahi R, White PM, Davenport RJ, Lindsay KW. Subarachnoid Haemorrhage. *BMJ* 2006;333:235-40.
14. Linn FH, Rinkel GJ, Algra A, van Gijn J. Headache characteristics in subarachnoid haemorrhage and benign thunderclap headache. *J Neurol Neurosurg Psychiatry* 1998;65:791-3.
15. Landtblom AM, Fridriksson S, Boivie J, Hillman J, Johansson J, Johansson I. Sudden onset headache: A prospective study of features, incidence and causes. *Cephalalgia* 2002;22:354-60.
16. Perry JJ, Stiell IG, Sivilotti ML, Bullard MJ, Lee JS, Eisenhauer M. High risk clinical characteristics for subarachnoid haemorrhage in patients with acute headache: Prospective cohort study. *BMJ* 2010;341:c5204.
17. Marcus H, Sayer D, Harris T. Beware adopting rigid rules. *BMJ* 2010;341:c7398.
18. van Gijn J, Rinkel GJ. Subarachnoid haemorrhage: Diagnosis, causes and management. *Brain* 2001;124:249-78.
19. Hop JW, Rinkel GJ, Algra A, van Gijn J. Case-fatality rates and functional outcome after subarachnoid haemorrhage. *Stroke* 1997;28:660-4.
20. Brilstra EH, Rinkel GJ, Algra A, van Gijn J. Rebleeding, secondary ischemia, and timing of operation in patients with subarachnoid hemorrhage. *Neurology* 2000;55:1656-60.
21. Duncan C, Davenport R. Acute headache. *Medicine* 2009;37:92-5.
22. Brown SC, Brew S, Madigan J. Investigating suspected subarachnoid haemorrhage in adults. *BMJ* 2011;342:d2644.
23. Williams A. Xanthochromia in the cerebrospinal fluid. *Pract Neurol* 2004;4:174-5.
24. Vermeulen M, Hasan D, Blijenberg BG, Hijdra A, van Gijn J. Xanthochromia after subarachnoid haemorrhage needs no revisitation. *J Neurol Neurosurg Psychiatry* 1989;52:826-8.
25. White P, Macpherson R, Sellar R. The use of CT angiography in acute subarachnoid haemorrhage in Eastern Scotland. *Scott Med J* 2009;54:20-3.
26. Cloft HJ, Joseph GI, Dion JE. Risk of cerebral angiography in patients with subarachnoid haemorrhage, cerebral aneurysm and arteriovenous malformation: A meta-analysis. *Stroke* 1999;30:317-20.
27. Ducros A, Bousser MG. Reversible cerebral vasoconstriction syndrome. *Pract Neurol* 2009;9:256-67.
28. Westphal SA. Diagnosis of a pheochromocytoma. *Am J Med Sci* 2005;329:18-21.
29. Al-Shahi Salman R, Labovitz DL, Stapf C. Spontaneous intracerebral haemorrhage. *BMJ* 2009;339:b2586.
30. Warlow C, van Gijn J, Dennis M, Wardlaw J, Bamford J, Hankey G, *et al.*, editors. *Stroke: Practical management*. Third ed. Blackwell publishing; 2008.
31. Vertinsky AT, Schwartz NE, Fischbein NJ, Rosenberg J, Albers GW, Zaharchuk G. Comparison of multidetector CT angiography and MR imaging of cervical artery dissection. *AJNR Am J Neuroradiol* 2008;29:1753-60.
32. Cumurciuc R, Crassard I, Sarov M, Valade D, Bousser MG. Headache as the only neurological sign of cerebral venous thrombosis: A series of 17 cases. *J Neurol Neurosurg Psychiatry* 2005;76:1084-7.
33. Schut ES, de Gans J, van de Beek D. Community acquired bacterial meningitis in adults. *Pract Neurol* 2008;8:8-23.
34. van de Beek D, de Gans J, Spanjaard L, Weisfelt M, Reitsma JB, Vermeulen M. Clinical features and prognostic factors in adults with bacterial meningitis. *N Engl J Med* 2004;351:1849-59.
35. Thomas KE, Hasbun R, Jekel J, Quagliarello VJ. Diagnostic accuracy of Kernig’s sign, Brudzinski’s sign, and nuchal rigidity in adults with suspected meningitis. *Clin Infect Dis* 2002;35:46-52.
36. Heyderman RS, Lambert HP, O’Sullivan I, Stuart JM, Taylor BL, Wall RA. Early management of suspected bacterial meningitis and meningococcal septicaemia in adults. *J Infect* 2003;46:75-7.
37. Ginsberg L, Kidd D. Chronic and recurrent meningitis. *Pract Neurol* 2008;8:348-61.
38. Solomon T, Hart IJ, Beeching NJ. Viral encephalitis: A clinician’s guide. *Pract Neurol* 2007;7:288-305.
39. Niedermeyer E, Da Silva FL. *Electroencephalography: Basic principles, clinical applications and related fields*. Fifth ed. Lippincott Williams and Wilkins; 2005. p. 269-74.
40. Anderson NE, Barber PA. Limbic encephalitis - a review. *J Clin Neurosci* 2008;25:961-71.
41. Dalmau J, Gleichman AJ, Hughes EG, Rossi JE, Peng X, Lai M, *et al.* Anti-NMDA-receptor encephalitis: Case series and analysis of the effects of antibodies. *Lancet Neurol* 2008;7:1091-8.

42. Dunn LT. Raised intracranial pressure. *J Neurol Neurosurg Psychiatry* 2002;73(suppl 1):i23-7.
43. Grant R. Overview: Brain tumour diagnosis and management / Royal College of Physicians guidelines. *J Neurol Neurosurg Psychiatry* 2004;75:18-23.
44. Hamilton W, Kernick D. Clinical features of primary brain tumours: A case-control study using electronic primary care records. *Br J Gen Pract* 2007;57:695-9.
45. Tepper SJ, Tepper DE. Breaking the cycle of medication overuse headache. *Cleve Clin J Med* 2010;77:236-42.
46. Alberti A. Headache and Sleep. *Sleep Med Rev* 2006;10:431-7.
47. Pascual J, Iglesias F, Oterino A, Vazquez-Barquero A, Berciano J. Cough, exertional and sexual headaches: An analysis of 72 benign and symptomatic cases. *Neurology* 1996;46:1520-4.
48. Skau M, Brennum J, Gjerris F, Jensen R. What is new about idiopathic intracranial hypertension? An updated review of mechanism and treatment. *Cephalalgia* 2006;26:384-99.
49. Wang SJ, Silberstein SD, Patterson S, Young WB. Idiopathic intracranial hypertension without papilloedema: A case control study in a headache centre. *Neurology* 1998;51:245-9.
50. Brodsky MC, Vaphiades M. Magnetic resonance imaging in pseudotumor cerebri. *Ann Neurol* 1986;19:80-2.
51. Whiteley W, Al-Shahi R, Warlow CP, Zeidler M, Leuck CJ. CSF opening pressure: Reference interval and the effect of body mass index. *Neurology* 2006;67:1690-1.
52. Ahmed SV, Jayawarna C, Jude E. Post lumbar puncture headache: Diagnosis and management. *Postgrad Med J* 2006;82:713-6.
53. Schievink WI. Spontaneous spinal cerebrospinal fluid leaks and intracranial hypotension. *JAMA* 2006;295:2286-96.
54. Mokri B, Low PA. Orthostatic headaches without CSF leak in postural tachycardia syndrome. *Neurology* 2003;61:980-2.
55. Oh K, Chung CS, Lee SJ. Orthostatic headache: An unusual presentation of a skull base tumour. *Cephalalgia* 2001;21:1000-1.
56. Kim JH, Choi JY, Kim HJ, Oh K. Orthostatic headache as a presenting symptom of cervical spine metastasis. *Headache* 2008;48:161-3.
57. Schievink WI, Wijdicks EF, Meyer FB, Sonntag VK. Spontaneous intracranial hypotension mimicking aneurysmal subarachnoid haemorrhage. *Neurosurgery* 2001;48:513-7.
58. Smetana GW, Schmerling RH. Does this patient have temporal arteritis? *JAMA* 2002;287:92-101.
59. Ray-Chaudhuri N, Ah Kine D, Tijani SO, Parums DV, Carlidge N, Strong NP, *et al.* Effect of prior steroid treatment on temporal artery biopsy findings in giant cell arteritis. *Br J Ophthalmol* 2002;86:530-2.
60. Font RL, Prabhakaran VC. Histological parameters helpful in recognising steroid-treated temporal arteritis: An analysis of 35 cases. *Br J Ophthalmol* 2007;91:204-9.
61. Frishberg BM, Rosenberg JH, Matchar DB, McCory DC, Pietrzak MP, Rozen TD, *et al.* Evidence based guidelines in the primary care setting: Neuro-imaging in patients with primary headache. Available from: <http://www.aan.com/professionals/practice/pdfs/gl0088.pdf>.
62. Cittadini E, Mathary MS. Symptomatic trigeminal autonomic cephalalgias. *Neurologist* 2009;15:305-12.
63. Mitchell CS, Osborn RE, Grosskreutz SR. Computer tomography in the headache patient: Is routine evaluation really necessary? *Headache* 1993;33:82-6.
64. Weber F, Knopf H. Incidental findings in magnetic resonance imaging of the brains of healthy young men. *J Neurol Sci* 2006;240:81-4.
65. Vernooj MW, Ikram MA, Tanghe HL, Vincent AJ, Hofman A, Krestin GP, *et al.* Incidental findings on brain MRI in the general population. *N Engl J Med* 2007;357:1821-8.
66. Evers S, Afra J, Frese A, Goadsby PJ, Linde M, May A, *et al.* EFNS guideline on the drug treatment of migraine - report of an EFNS task force. *Eur J Neurol* 2006;13:560-72.
67. Howard L, Wessely S, Leese M, Page L, McCrone P, Husain K, *et al.* Are investigations anxiolytic or axiogenic? A randomised controlled trial of neuroimaging to provide reassurance in chronic daily headache. *J Neurol Neurosurg Psychiatry* 2005;76:1558-64.

How to cite this article: Duncan CW. Neuroimaging and other investigations in patients presenting with headache. *Ann Indian Acad Neurol* 2012;15:23-32.

Received: 01-11-11, **Revised:** 16-04-12, **Accepted:** 17-05-12

Source of Support: Nil, **Conflict of Interest:** Nil

Staying in touch with the journal

1) Table of Contents (TOC) email alert

Receive an email alert containing the TOC when a new complete issue of the journal is made available online. To register for TOC alerts go to www.annalsofian.org/signup.asp.

2) RSS feeds

Really Simple Syndication (RSS) helps you to get alerts on new publication right on your desktop without going to the journal's website. You need a software (e.g. RSSReader, Feed Demon, FeedReader, My Yahoo!, NewsGator and NewzCrawler) to get advantage of this tool. RSS feeds can also be read through FireFox or Microsoft Outlook 2007. Once any of these small (and mostly free) software is installed, add www.annalsofian.org/rssfeed.asp as one of the feeds.