







# Foreign Body Accidents in a Pediatric Emergency Department

Saramira Cardoso Bohadana<sup>1</sup>  Rayza Gaspar dos Santos<sup>1</sup>  Mirella Kalyne Cavalcante Magalhães<sup>1</sup>   
Regina Grigolli Cesar<sup>2</sup> 

<sup>1</sup>Department of Otorhinolaryngology, Hospital Infantil Sabará, São Paulo, SP, Brazil

<sup>2</sup>Department of Pediatrics, Medical Sciences College, Santa Casa de São Paulo, Hospital Infantil Sabará, São Paulo, SP, Brazil

**Address for correspondence** Saramira Cardoso Bohadana, MD, PhD, Rua Mato Grosso, 306, Sala 506, São Paulo, SP, 01239-040, Brazil (e-mail: sbohadana@gmail.com).

Int Arch Otorhinolaryngol 2023;27(2):e316–e323.

## Abstract

**Introduction** Foreign body accidents (FBAs) are frequent in children and can be severe, being a common cause of morbidity and mortality and a public health problem. As these accidents are multifactorial, their cause can only be determined by analyzing the clinical details and characteristics of the object. Knowing the associated mechanisms and factors is essential to determine a risk profile and have a preventive, therapeutic, and diagnostic purpose.

**Objective** The present study aimed to describe the incidence of FBAs in otorhinolaryngology according to their anatomical location, focusing on the aerodigestive system.

**Methods** This is a retrospective study performed by reviewing the medical records of 668 cases seen in the emergency department of a tertiary pediatric hospital in São Paulo, state of São Paulo, Brazil, between 2014 and 2017.

**Results** Foreign bodies (FBs) were found in the digestive system (238/668), in the nasal cavities (206/668), in the ears (182/668), in the oropharynx (34/668), and in the respiratory system (8/668). A total of 91.77% of the patients were treated in the emergency room. The main age group affected was < 5 years old, with no difference between genders. The most frequent complications affected the digestive system and the most serious occurred in cases involving the respiratory system.

**Conclusion** Multidisciplinary teams should be ready in the emergency room to provide adequate care in FBAs. Early diagnosis, FB removal in the emergency room or the surgical center and follow-up are essential. Developing prevention campaigns including a risk profile for certain products and/or materials, helping to ensure safety for consumers, is necessary. For this, a national database with compulsory notification containing relevant information on FBAs in the pediatric population should be created.

## Keywords

- ▶ accidents
- ▶ child
- ▶ foreign bodies
- ▶ respiratory system

## Introduction

A foreign body (FB) is any object or substance that inadvertently penetrates the body or its cavities.<sup>1</sup> Foreign body accidents (FBAs) are relatively frequent in children and can

be severe in some cases, being a common cause of morbidity and mortality and a public health problem.<sup>2–4</sup> Foreign body accidents can be drastic since suffocation due to aspiration and ingestion represents one of the most common causes of death in children worldwide. The estimated

received  
May 17, 2021  
accepted  
January 31, 2022

DOI <https://doi.org/10.1055/s-0042-1744255>.  
ISSN 1809-9777.

© 2023. Fundação Otorrinolaringologia. All rights reserved.  
This is an open access article published by Thieme under the terms of the Creative Commons Attribution-NonDerivative-NonCommercial-License, permitting copying and reproduction so long as the original work is given appropriate credit. Contents may not be used for commercial purposes, or adapted, remixed, transformed or built upon. (<https://creativecommons.org/licenses/by-nc-nd/4.0/>)  
Thieme Revinter Publicações Ltda., Rua do Matoso 170, Rio de Janeiro, RJ, CEP 20270-135, Brazil

number of incidents per year in patients aged between 0 and 14 years old in the European Union is  $\sim 50,000$ , of which 10% are fatal.<sup>5</sup> In the United States, the incidence of accidental death in children  $< 6$  years old due to an FBA is of  $\sim 500$  to 2000 cases, being the first cause of accidental death in this age group.<sup>2</sup>

The risk of FBA is a multifaceted problem involving epidemiological, behavioral, medical, socioeconomic, and legislative aspects. A joint effort by all these components is necessary to achieve significant prevention. Moreover, all sectors of society, especially parents, must be aware of basic health principles, essential life support, and actions that can be taken to prevent accidents, receiving support to apply these principles.<sup>6</sup>

Suffocation or obstruction of the airways is a relevant cause of accidental death in children.<sup>7</sup> In Brazil, it is the leading cause of death among accidents involving babies up to 1 year old.<sup>8</sup> In 2017, the monitoring system of the Brazilian National Institute of Metrology, Standardization and Industrial Quality (Inmetro, in the Portuguese acronym), Inmetro Consumer Accident Monitoring System (SINMAC, in the Portuguese acronym) reported that 49% of suffocations were due to objects derived from products sold to children or babies. The most affected age group was between 0 and 3 years old. The Inmetro recalled some of the most dangerous toys for children in this age group.<sup>9</sup>

The type of FB varies according to the anatomical location and to the cultural habits of each country, as well as to the socioeconomic characteristics and intellectual level of the patient. In patients with airway FBs, there is a predominance of cases involving seeds. In the United States, accidents with peanuts are common. In Lebanon, watermelon seeds prevailed. In Brazil, beans, peanuts, and corn predominate.<sup>10-12</sup> Regarding ear FBs, there is a prevalence of pieces of cotton and plastic, toys, seeds, and insects.<sup>13,14</sup> In the nasal cavities, it is common to find seeds, sponges, paper, and toys. In the oropharynx, the most common FBs are fish bones, food stalks, and pieces of chicken bones.<sup>14-16</sup>

In short, the nature of these accidents is multifactorial, and few studies have been conducted on their associated causes and circumstances. The clinical details and characteristics of the object should also be analyzed. Knowledge of the related mechanisms and factors is essential to determine a risk profile and have a preventive, therapeutic, and diagnostic purpose. Following the structure of the Susy Safe Project,<sup>2</sup> the largest worldwide database of data on injuries involving FBs, it is possible to characterize some variables associated with these incidents, such as age, gender, characteristics and location of the FB, need for hospitalization, use of anesthesia, and complications, focusing on cases involving the aerodigestive system due to the greater severity of these incidents.

In general otorhinolaryngology, the anatomical locations most frequently involved in these accidents are the external auditory canal, the nasal cavities, the oropharynx, and the larynx. As accidents involving the airways and the digestive tract have significant morbidity and mortality, they are addressed in the present study.

## Objective

The present study aimed to analyze the medical records of children involved in FBAs treated in the emergency department of a tertiary pediatric hospital in São Paulo, state of São Paulo, Brazil. The following parameters were identified: type of FB, anatomical location, complications, need for hospitalization, age, and gender. Special attention was paid to cases of FB aspiration and of ingestion of corrosive materials due to their greater severity.

## Methods

A retrospective study was conducted with a review of medical records consisting of collecting and recording clinical cases in the emergency department of a tertiary pediatric hospital in São Paulo. All patients seen at the Emergency Care Unit from January 2014 to December 2017 and with a record of CID T16, T17.0, T17.1, T17.2, T17.3, T17.4, T17.5, T17.8, T17.9, T18, T18.0, T18.1, T18.2, T18.3, T18.8, and T18.9 were considered.

Data were obtained based on clinical records collected using a standardized form specially designed to collect information related to FBAs and tabulated in an electronic spreadsheet (Microsoft Excel; Microsoft Corporation, Redmond, WA, USA), including specifications about the child and about the FB, such as age, gender, type of FB, material, anatomical region affected, treatment, complications, need for general anesthesia for foreign object removal, and hospitalization.

The frequencies described observed were compared among them and in relation to the respective expected frequencies determined according to the null hypothesis of equiprobability in the simple analysis and based on the marginal total for analysis of interactions between variables. The differences were tested using the chi-squared test. The Student *t*-test was used to compare two independent samples of ages.

Based on the project guidelines and standards, patient privacy was guaranteed. The center that provided the data is their sole owner, and they can be excluded from the database at any time.

## Results

Data from 668 cases of FBAs in patients treated from January 2014 to December 2017 were obtained.

The age of these patients ranged from 0 to 15 years old (mean: 4.3 years old; standard deviation [SD]: 2.81 years) with higher incidence in children  $< 5$  years old (472/668) ( $\chi^2 = 114.036$ ,  $df = 1$ ;  $p < 0.05$ ). The observed frequencies of FBAs by age are shown in ► **Table 1**.

Regarding gender, 350 out 668 patients were female (52.40%), with no statistical difference ( $\chi^2 = 1.533$ ; degree of freedom [DF] = 1;  $p > 0.05$ ). The Student *t*-test for independent samples reveals that the average age of female patients, of 4.1 years old (2.78 years) lower than the average age of 4.5 years old of the 318 male patients (standard deviation [SD]: 2.84 years), which was statistically significant ( $t = 2.04$ ,  $DF = 666$ ;  $p < 0.05$ ).

**Table 1** Observed frequencies of foreign body accidents by age

Age (years old)	n	%
0	36	5.39
1	88	13.17
2	128	19.16
3	121	18.11
4	99	14.82
5	64	9.58
6	42	6.29
7	17	2.54
8	22	3.29
9	12	1.80
10	14	2.10
11	10	1.50
12	3	0.45
13	5	0.75
14	4	0.60
15	3	0.45
Total	668	100.00

**Table 2** Observed frequencies of foreign body accidents by age (in years) according to gender

Age (years old)	F	M
0	24	12
1	56	32
2	68	60
3	63	58
4	42	57
5	30	34
6	21	21
7	7	10
8	16	6
9	7	5
10	4	10
11	6	4
12	1	2
13	3	2
14	1	3
15	1	2
Total	350	318

Abbreviations: F, female; M, male.

The observed frequencies of FBAs in patients < 5 years old and ≥ 5 years old did not differ as a function of gender ( $\chi^2 = 0.939$ ;  $DF = 1$ ;  $p > 0.05$ ). The corresponding data are shown in ►Fig. 1. The values observed for age (in years) versus gender are described in ►Table 2.

The type of FB is shown in ►Table 3. “Seeds” were considered separately from “Food” due to their relevance.

The locations of FBs were the digestive system (238/668), the nasal cavities (206/668), the ears (182/668), the oropharynx (34/668), and the respiratory system (8/668). They are presented in absolute and relative frequencies in the graph shown in ►Fig. 2.

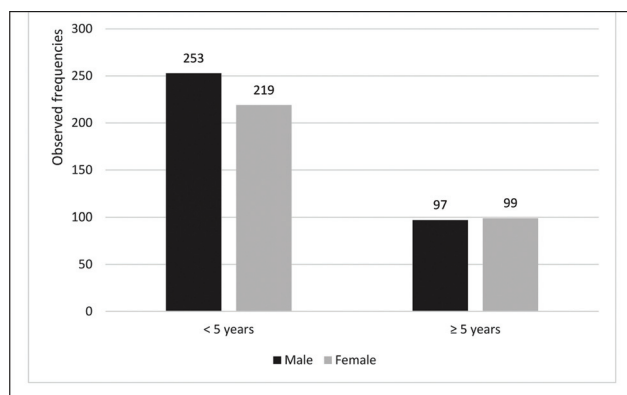
In ~ 238 cases of FBs located in the digestive system, metals (represented mainly by coins) were the most com-

mon FBs (25.63%) when compared with jewelry and beads (16.80%), plastic, rubber, and Styrofoam (16.38%) ( $\chi^2 = 6.614$ ;  $DF = 2$ ;  $p < 0.05$ ), which occupied the second and third positions, with no difference between them ( $\chi^2 = 0.013$ ;  $DF = 1$ ;  $p < 0.05$ ).

Batteries and magnets accounted for 2.99% of the cases, which corresponds to 7.98% of the cases affecting the digestive system. Of those, 19 (95%) were ingested and 1 (5%) was located in the nasal cavity. They were found in patients between 0 and 6 years old, as shown in ►Table 4. In our sample, 25% of the patients involved in FBAs with batteries were hospitalized. Endoscopic removal was necessary in 10% of the cases, and there were no complications in any of the patients evaluated.

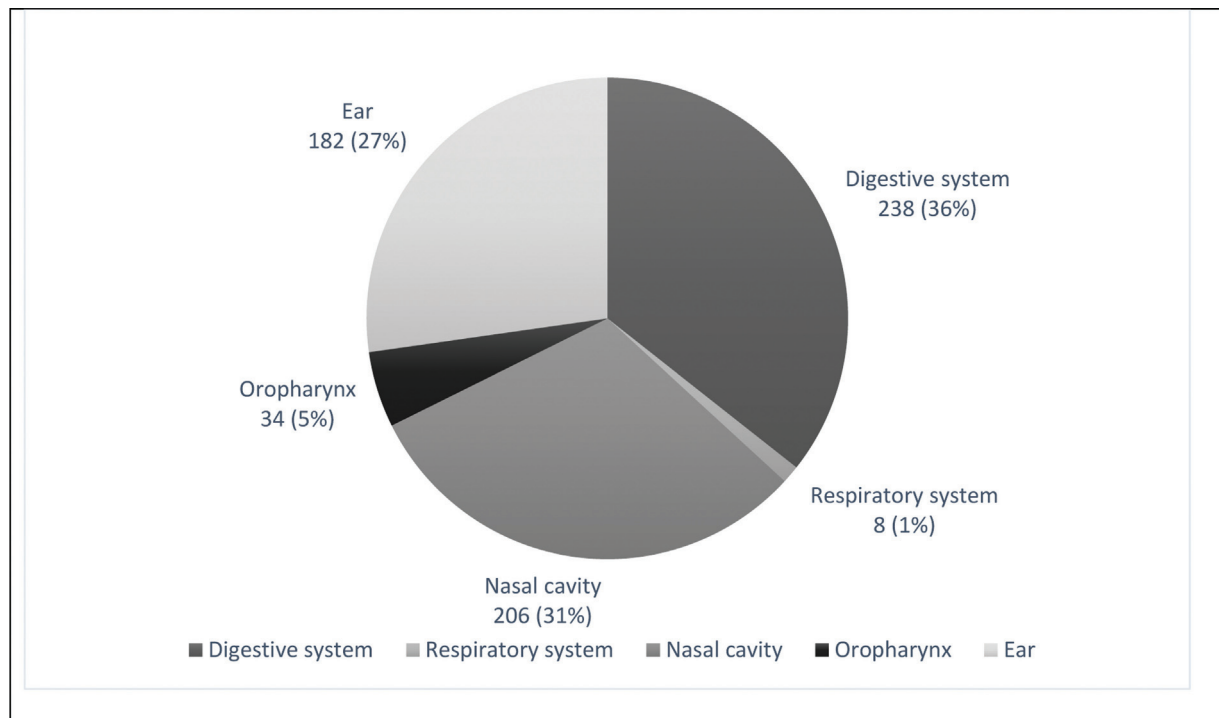
The types of FBs found in each location, including their respective observed and relative frequencies, are shown in ►Table 5.

Complications were different according to the location of the FB. They occurred in 40 out of 668 cases of FBAs (5.99%). Most (72.50%) were mild ( $n = 29$ ) when compared with moderate ( $n = 6$ ) and severe ( $n = 5$ ) ( $\chi^2 = 27.650$ ;  $DF = 2$ ;  $p < 0.05$ ), even when considering the sum of the observed frequencies of moderate and severe cases ( $n = 11$ ) ( $\chi^2 = 8.100$ ;  $DF = 2$ ;  $p < 0.05$ ), which, in turn, did not differ from each other ( $\chi^2 = 0.091$ ;  $DF = 1$ ;  $p > 0.05$ ). Complications, in general, were more frequent (55.00%) among cases of FBs located in the ears (22/40) ( $\chi^2 = 32.000$ ;  $DF = 4$ ;  $p < 0.0$ ). Conglomerate analysis of complications based on the five different FB locations based on the frequencies observed using the “farthest neighbor” clustering criterion generated the dendrogram

**Fig. 1** Distribution of the observed frequencies of foreign body accidents according to age versus gender.

**Table 3** Type of foreign body

Battery and magnet	Battery; Magnet
Bone, nail, and tooth	Chicken bone; fish bone; nail; toothpick
Costume jewelry and beads	Beads; earring; earring back; hair clip; piece of bracelet; piece of necklace; ring; strass
Cotton, thread, and tissue	Cotton; ribbon; sewing line; thread
Food	Candy; chocolate; cooked rice; pasta; piece of meat; raisin; snack
Glass, sand, and stone	Balls of silica; glass; sand; stone
Metal	Chain; clip; coin; piece of compass; piece of dental braces; piece of metal spoon; piece of nail cutter; piece of zipper; earphoneplug; yakult cap
Plastic, rubber, foam, and Styrofoam	Baloon; foam; flip-flop ornament; piece of cellphone; piece of plastic spoon; rubber; sequin; sponge; Styrofoam; ventilation tube
School supplies	Eraser; crayon; paper; sticker
Seed	Bean; corn; olive pit; peanut; seed
Toy	Lego; playdough; toy; whistle
Others	Animal food; bug; ointment; pill; wood

**Fig. 2** Foreign body locations.

shown in ► **Fig. 3**, reduced the number of comparisons, and made it possible to order complications as follows:

Ears = (nasal cavity + respiratory system)<sup>A</sup> > digestive system or oropharynx

With the following values for the tests of the differences in the comparisons, respectively:  $\chi^2 = 2.941$ ;  $DF = 1$ ;  $p > 0.05$ ) and ( $\chi^2 = 9.333$ ;  $DF = 2$ ;  $p < 0.05$ ).

► **Table 6** shows the adopted criteria for differentiating severity and its incidence.

The complications found in the ears were edema, erythema, laceration of the auditory canal, and abscess. Septal laceration and epistaxis were observed in the nasal cavities.

In the digestive system, abdominal distension, anal hyperemia, and laceration of the gastroesophageal mucosa were found. Regarding the oropharynx, posterior pharyngeal laceration and fever were identified. Patients with FBs located in the respiratory system presented petechiae in the face, bronchospasm, wheezing, stridor, cyanosis, and cardiorespiratory arrest. They were responsible for the most serious complications (12.50%). Seeds were the most common type of FBs found in severe complications (four cases with peanuts and one case with birthday balloon).

A total of 91.77% of the patients were treated in the emergency room. There was a need for hospitalization in

**Table 4** Observed frequencies of batteries and magnets by age

Age (years old)	n	%
0	2	10
1	3	15
2	3	15
3	4	20
4	5	25
5	1	5
6	2	10
<b>Total</b>	<b>20</b>	<b>100.00</b>

8.23% of the cases. Of these hospitalized patients, 56.36% corresponded to FBAs in the digestive system, 18.18% in the ears, 7.27% in the nasal cavities, 5.45% in the oropharynx, and 12.73% in the respiratory system. The use of anesthesia for removal, which may be topical or general, was necessary in 11.53% of the cases.

## Discussion

The age of the patients ranged between 0 and 15 years old, with a higher incidence in children < 5 years old, which is in line with the world literature.<sup>17,18</sup> It is important to note that this finding agrees with the fact that young children are the most involved in FBAs, making it difficult to make an early diagnosis and identify the object. Depending on the location, occasional diagnosis is common, finding FBs in the ears and nasal cavity.

Regarding the anatomical location, the most affected site in absolute numbers was the digestive tract, which will be further addressed later.

The nasal cavities were the second most frequent location in absolute numbers, although it is expected that FB removal in the emergency room can be more difficult due to the nasal anatomy and to the risk of aspiration. In our sample, only 0.6% of the patients needed to be hospitalized and received anesthesia for removal.

In our study, mainly jewelry and beads were found in the ears, followed by toys and seeds, which agrees with the literature. They are easily identified and can be removed without complications in > 90% of the cases. A study reported difficulties in 35% of the cases, with perforation of the tympanic membrane using cotton swabs being the most frequent complication in children aged between 0 and 5 years old.<sup>14,16,19,20</sup>

In the oropharynx we found mainly fish bones and pieces of chicken bones, followed by other parts of food, such as seasoning twigs. In fact, children inadvertently introduced wooden/plastic pieces and pencil tips into their mouths. These can be in the palatine tonsils, on the soft palate, the hard palate, and the base of the tongue. It is also common for fish bones to lodge in the amygdala crypts.

Respiratory system accidents were the least frequent. In the literature, it is described that the severity of airway

**Table 5** Type of foreign body at each location, including their respective observed and relative frequencies

FB type versus location	n	%
<b>Digestive system</b>		
Metal	61	25.63
Costume jewelry, and beads	40	16.81
Plastic, rubber, foam, and Styrofoam	39	16.39
Toy	29	12.18
Battery and magnet	19	7.98
Glass, sand, and stone	10	4.20
Food	9	3.78
Bone, nail, and tooth	7	2.94
School supplies	7	2.94
Seed	3	1.26
Cotton, thread, and tissue	2	0.84
Others	3	1.26
Unknown	9	3.78
<i>subtotal</i>	238	100.00
<b>Nasal cavity</b>		
Toy	37	17.96
Seed	31	15.05
Costume jewelry, and beads	29	14.08
Plastic, rubber, foam, and Styrofoam	25	12.14
Food	22	10.68
School supplies	21	10.19
Cotton, thread, and tissue	5	2.43
Glass, sand, and stone	5	2.43
Battery and magnet	1	0.49
Metal	1	0.49
Others	4	1.94
Unknown	25	12.14
<i>subtotal</i>	206	100.00
<b>Ear</b>		
Costume jewelry, and beads	72	39.56
Toy	23	12.64
Seed	21	11.54
School supplies	17	9.34
Plastic, rubber, foam, and Styrofoam	12	6.59
Cotton, thread, and tissue	7	3.85
Glass, sand, and stone	4	2.20
Metal	4	2.20
Bone, nail, and tooth	1	0.55
Food	1	0.55
Others	7	3.85
Unknown	13	7.14

**Table 5** (Continued)

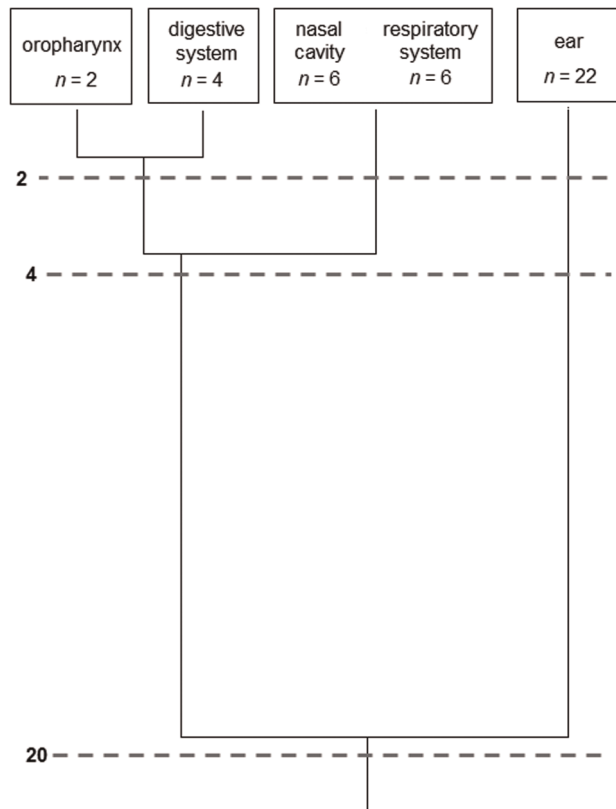
FB type versus location	n	%
<i>subtotal</i>	182	100.00
<b>Oropharynx</b>		
Bone, nail, and tooth	21	61.76
Food	4	11.76
Costume jewelry, and beads	3	8.82
Metal	3	8.82
School supplies	2	5.88
Unknown	1	2.94
<i>subtotal</i>	34	100.00
<b>Respiratory system</b>		
Seed	4	50.00
Plastic, rubber, foam, and Styrofoam	3	37.50
Bone, nail, and tooth	1	12.50
<i>subtotal</i>	8	100.00

(Continued)

obstruction symptoms depends on the location and size of the FB. Small objects tend to lodge in the bronchial tree, which causes more symptoms of bronchospasm than of stridor.<sup>18</sup> In our sample, seeds (peanuts) were more frequent in this location, which agrees with the American literature.

The risk involving balloons and party balloons should also be emphasized – in one case, the object impacted the larynx and obstructed the airway of the child. The impact was lower because his mother knew basic life support principles and identified the accident, performing unblocking maneuvers that displaced the FB to the digestive tract. The child was immediately taken to the emergency room, and general anesthesia and FB removal by upper digestive endoscopy were required. The literature reports that most cases of FBA involving balloons lead to suffocation and death before arriving at the emergency room.<sup>18</sup>

Immediate identification of the location of the FBA is essential for the treatment and the clinical evolution.<sup>3</sup> Chest X-ray in the posteroanterior and lateral views helps in the diagnosis of FB because it is an easily accessible exam; however, the identification of the object depends on its location, time of installation, and composition, reaching only 16% of tracheal FBs.<sup>4</sup> In addition, a considerable number of FBs are not radiopaque.<sup>21</sup> The most common findings on radiography are atelectasis and unilateral hyperinflation.<sup>3,22</sup> In a case series, the use of X-rays did not demonstrate the presence of FB in 10% of the cases.<sup>23</sup> This same study showed that bronchoscopy helped to provide a successful removal in 82% of the cases. Flexible and rigid bronchoscopy can be performed; the latter was the preferred procedure for the removal.<sup>3</sup> Although this test should be conducted in all suspected cases, according to the literature, FBs may not be found in between 10 and 15% of the cases. In our sample, all cases of low airways FBs were assessed by flexible and rigid bronchoscopy.



**Fig. 3** Dendrogram representing the grouping of the locations of the 40 complications of foreign body accidents based on the respective frequencies observed through hierarchical cluster analysis by the 'farthest neighbor' method, forming groups with maximum distance between the elements 2,4, and 20 cases (digits to the left of the hatched lines represent the grouping levels).

**Table 6** Severity rating

<b>Mild (72.50%)</b>	Anal hyperemia, edema and hyperemia of the external auditory canal, laceration and nasal bleeding, oropharyngeal laceration
<b>Moderate (15.00%)</b>	Abdominal distension, gastroesophageal mucosa laceration, abscess, fever, petechiae
<b>Severe (12.50%)</b>	Bronchospasm, wheezing, stridor, cyanosis, cardiorespiratory arrest

<sup>^</sup>Nasal cavity = Respiratory System (both with observed frequency = 6).

Bronchoscopy showed success rates for FB removal of >98%.<sup>18,24</sup> The procedure is performed under general anesthesia, with the patient on spontaneous ventilation with oxygen supply through a nasopharyngeal catheter. The object must be identified initially with a flexible bronchoscope. Foreign bodies that are involved by granulation tissue or located in a distal bronchus may not be identified. The rigid bronchoscope is preferred over the flexible ones for the removal procedure because it facilitates the passage of grasping, aspiration, and oxygen supply clamps. The use of



flexible fiberscopes has gained prominence for this procedure because they allow using ultrathin basket-shaped forceps passed through the working channel. In our experience, patients with strong clinical suspicion but without identification of the FB by X-ray or bronchoscopy undergo bronchography with water-soluble contrast and bronchoscopy simultaneously. Finally, the respiratory tree is designed, which allows assessing the location where the FB is impacted.

The patient is then clinically evaluated and observed for 24 hours in the intensive care unit (ICU) before hospital discharge.

Airway FBAs can develop complications even when the approach is immediate. According to statistics from the Susy Safe database, the most common complications were pneumonia, infection, asthma, and perforation.<sup>5</sup> Morbidity and mortality are higher in younger children. Delay in the diagnosis can be explained by the difficulty of the parents in detecting FBAs and by the symptoms mimicking low airway respiratory symptoms. Foreign body accidents should be suspected when the episode is characterized by choking followed by cough and cyanosis in healthy children.<sup>3,24</sup> Chest tomography may be helpful in the late diagnosis but should be used with caution to avoid delaying treatment.

In the USA, > 3,500 batteries are ingested per year. There is no single database in Brazil. Inmetro has the SINMAC, a database on accidents involving consumer goods recorded in the country. However, this database is open for reports of accidents caused by the consumer. Unfortunately, such a platform is not widely known, which makes it inaccurate. In 2019, almost half of the reports did not include the age of the victims.<sup>25,26</sup>

Batteries are metallic objects that can contain lithium, alkaline solution, zinc, or silver oxide. They are widely used in several standard electronic components for domestic use, such as watches, controls, toys, and other utensils easily accessible to children. The objects most accessible to children are remote controls (70.2%), games and toys (15.1%), calculators (7.5%), and watches (5.5%).<sup>27</sup> Batteries pose a risk to children because they can be ingested, aspirated, and inserted into the nasal cavity and ears. Injuries caused by batteries have significant morbidity and mortality. Data from the National Capital Poison Center (NCPC) in the USA revealed an increase in the incidence of battery injuries. This includes mainly tracheoesophageal fistulas, esophageal perforations, mediastinitis, and arterial fistulas, among other complications. Although the batteries most commonly involved in FBAs measure between 7.9 and 11 mm, battery size and composition are associated with greater severity and local tissue damage.<sup>28,29</sup>

The pathophysiology of the lesion depends on the compound present in the battery. Those with zinc are believed to generate a local external current that provides tissue electrolysis and generates internal hydroxide (-OH), creating a highly alkaline environment. This alkaline pH causes tissue damage and liquefactive necrosis within a few hours. In the esophagus, the lesion can be visible within 15 minutes. It has been described that, even after removal, the tissue lesion continues to progress if the site is not irrigated and the PH is

not neutralized. Injury can also occur by releasing local toxic content and necrosis by compressing adjacent structures.<sup>28</sup>

The symptoms are variable and can include vomiting, difficulty in breathing, fever, anorexia, cough, lethargy, dysphagia, irritability, sore throat, abdominal pain, and hypersalivation.<sup>28</sup>

The emergency removal of the battery, under anesthesia, is necessary and should not be postponed even if the patient is not fasting. Therefore, a quick induction sequence must be conducted. Some strategies can be adopted in advance to reduce tissue damage if removal is not possible. A total of 10 mL of sucralfate or 10 mL of honey can be ingested every 10 minutes, both of which have demonstrated a high local neutralizing effect, preventing tissue damage. This measure can be taken while still at home as soon as battery ingestion is suspected.<sup>30</sup> The object is usually removed by upper gastrointestinal endoscopy. After removal in the operating room, the endoscopist irrigates the lesion with 50 to 150 ml of 0.25% acetic acid to help neutralize the alkaline environment. Children should be hospitalized and monitored for the risk of esophageal perforation. An esophagogram may be necessary before starting the oral diet. Complications can occur days or weeks after the accident.<sup>30</sup>

In our sample, 25% of the patients involved in FBAs with batteries were hospitalized. Endoscopic removal was necessary in 10% of the cases and there were no complications in any of the patients evaluated.

## Conclusion

Assuming that FBAs are relatively common in children and that aerodigestive cases have high morbidity and mortality, multidisciplinary teams must be ready in the emergency room to provide adequate care in FBAs. This service should start with a call to a call center from the moment of the accident. This would help to guide the family better and transfer the child to the hospital. Prevention campaigns, including a risk profile for certain products and/or materials, should be developed, thus helping to guarantee the safety of customers. A national database with a compulsory notification containing relevant information on FBAs in the pediatric population should be created. Furthermore, pertinent case reports from a clinical and surgical perspective should also be used to ensure multidisciplinary training. The Susy Safe program works with the Inmetro to provide data on the type of FB that most often causes injuries to prevent these accidents from happening.

## Conflict of Interests

The authors have no conflict of interests to declare.

## References

- 1 Waksman RD, Maciel W, Gikas RMC. Crianças e Adolescentes Seguros. Guia Completo para Prevenção de Acidentes e Violências. Sociedade Brasileira de Pediatria; 2005
- 2 Sousa STEV, Ribeiro VS, Filho Jde M, Santos AM, Barbieri MA, Neto Jde F. Aspiração de corpo estranho por menores de 15 anos: experiência de um centro de referência do Brasil. 2009;35(07): 653–9. Available from: [https://cdn.publisher.gn1.link/jornaldepneumologia.com.br/pdf/2009\\_35\\_7\\_6\\_portugues.pdf](https://cdn.publisher.gn1.link/jornaldepneumologia.com.br/pdf/2009_35_7_6_portugues.pdf)

- 3 Bittencourt PFS, Camargos PAM, Scheinmann P, de Blic J. Foreign body aspiration: clinical, radiological findings and factors associated with its late removal. *Int J Pediatr Otorhinolaryngol* 2006;70(05):879–884
- 4 Mu LC, Sun DQ, He P. Radiological diagnosis of aspirated foreign bodies in children: review of 343 cases. *J Laryngol Otol* 1990;104(10):778–782
- 5 Susy Safe Working Group. The Susy Safe project overview after the first four years of activity. *Int J Pediatr Otorhinolaryngol* 2012;76. 2012 May 14;76 Suppl 1:S3-11, Epub 2012 Feb 16. PMID: 22341477 Doi: 10.1016/j.ijporl.2012.02.003
- 6 Convenção sobre os Direitos da Criança. [Internet]. Decreto nº99710 1990. Available from: [http://www.planalto.gov.br/ccivil\\_03/decreto/1990-1994/d99710.htm](http://www.planalto.gov.br/ccivil_03/decreto/1990-1994/d99710.htm)
- 7 França EB, Lansky S, Rego MAS, et al. Principais causas da mortalidade na infância no Brasil, em 1990 e 2015: estimativas do estudo de Carga Global de Doença. *Rev Bras Epidemiol* 2017;20(20, Suppl 01):46–60
- 8 Relatório traz o alerta sobre principais causas de morte de crianças a partir de um ano de idade [Internet]. 2014 [cited 2021 Apr 18]. Available from: <http://primeirainfancia.org.br/crianca-segura-e-rede-nacional-primeira-infancia-lancam-relatorio-e-trazem-o-alerta-sobre-prevencao-de-acidentes-na-primeira-infancia/#:~:text=A principal causa de mortes,trânsito representam 32%25 das mortes>
- 9 Recall de brinquedos: Inmetro notifica organismos de certificação. 2019 Available from: <https://www.gov.br/inmetro/pt-br/assuntos/noticias/recall-de-brinquedos-inmetro-notifica-organismos-de-certificacao>
- 10 Fraga AMA, Reis MC, Zambon MP, Toro IC, Ribeiro JD, Baracat ECE. Aspiração de corpo estranho em crianças: aspectos clínicos, radiológicos e tratamento broncoscópico. *Jornal Brasileiro de Pneumologia* 2008;34(02):74–82
- 11 Cassol V, Pereira AM, Zorzela LM, Becker MM, Barreto SSM. corpo estranho na via aerea de crianças. *J Pneumol* 2003;29(03):139–144
- 12 Rovin JD, Rodgers BM. Pediatric foreign body aspiration. *Pediatr Rev* 2000;21(03):86–90
- 14 Portela Ada S, Pereira CT, Pianca EG, Solés JVC, Moussalle SK. Corpo estranho em conduto auditivo e vias aéreas superiores. *Acta méd (Porto Alegre)*; 2012:1–6
- 14 Mangussi-Gomes J, Andrade JS, Matos RC, Kosugi EM, Penido Nde OENT foreign bodies: profile of the cases seen at a tertiary hospital emergency care unit. *Braz J Otorhinolaryngol*. 2013 Nov-Dec; 2013;79(06):699–703
- 15 Tiago RSL, Salgado DC, Corrêa JP, Pio MRB, Lambert EE. Corpo estranho de orelha, nariz e orofaringe: experiência de um hospital terciário. *Brazilian Journal of Otorhinolaryngology* 2006;72(02):177–181
- 16 Silva BSR, Souza LO, Camera MG, Tamiso GB, Castanheira LVR. Foreign Bodies in Otorhinolaryngology: A Study of 128 Cases. *Int. Arch. Otorhinolaryngol*. 2009;13(04):394–399
- 17 Gonçalves AC, Araújo MPB, Paiva KV, Menezes CSA, Silva AÉMCD, Santana GO, Ortolan ÉVP, Lourenção PLTA. Accidents in childhood: casuistry of a tertiary service in a medium-sized city in Brazil. *Rev Col Bras Cir* 2019;46(02):e2104
- 18 Gonçalves MEP, Cardoso SR, Rodrigues AJ. Corpo estranho em via aérea. *Pulmão RJ* 2011;2011(20):54–58
- 19 Carniol ET, Bresler A, Shaigany K, et al. Traumatic tympanic membrane perforations diagnosed in emergency departments. *JAMA Otolaryngol Head Neck Surg* 2018;144(02):136–139
- 20 Karimnejad K, Nelson EJ, Rohde RL, Costa DJ. External Auditory Canal Foreign Body Extraction Outcomes. *Ann Otol Rhinol Laryngol* 2017;126(11):755–761
- 21 Bittencourt PF, Camargos PA. Aspiração de corpos estranhos [Foreign body aspiration]. *J Pediatr (Rio J)* 2002 Jan-Feb;2002;78(01):9–18
- 22 Wood RE. Spelunking in the pediatric airways: explorations with the flexible fiberoptic bronchoscope. *Pediatr Clin North Am* 1984;31(04):785–799. Doi: 10.1016/S0031-3955(16)34645-4
- 23 Rodrigues AJ, Oliveira EQ, Scordamaglio PR, Gregório MG, Jacomelli M, Figueiredo VR. Flexible bronchoscopy as the first-choice method of removing foreign bodies from the airways of adults. *J Bras Pneumol* 2012;38(03):315–320
- 24 Black RE, Choi KJ, Syme WC, Johnson DG, Matlak ME. Bronchoscopic removal of aspirated foreign bodies in children. *Am J Surg* 1984;148(06):778–781
- 25 Sistema Inmetro de Monitoramento de Acidentes de Consumo [Internet]. 2019. Available from: <http://www.inmetro.gov.br/consumidor/pdf/sinmac-2019.pdf>
- 26 Sistema Inmetro de Monitoramento de Acidentes de Consumo [Internet]. Available from: [http://www.inmetro.gov.br/consumidor/acidente\\_consumo.asp](http://www.inmetro.gov.br/consumidor/acidente_consumo.asp)
- 27 Gibbs H, Rhoades K, Jatana KR. Clinical Guidelines and Advocacy Towards the Reduction of Pediatric Button Battery Injuries. *Clin Pediatr Emerg Med* 2020;21(02):100775. Doi: 10.1016/j.cpem.2020.100775
- 28 Litovitz T, Whitaker N, Clark L, White NC, Marsolek M. Emerging battery-ingestion hazard: clinical implications. *Pediatrics* 2010;125(06):1168–1177
- 29 Belakang AL. National Capital Poison Center. 2014:1–7. Available from: <https://www.poison.org/-/media/files/poisonorg/press/button-battery-incidents-november-2016.pdf>
- 30 Anfang RR, Jatana KR, Linn RL, Rhoades K, Fry J, Jacobs IN. pH-neutralizing esophageal irrigations as a novel mitigation strategy for button battery injury. *Laryngoscope* 2019;129(01):49–57